

CASE REPORT

Decoding unusual MR findings: Spinal cord edema in atypical cervical spondylotic myelopathy—A case report and literature review

Qingrun Zhu  | Dachuan Wang

The Second Hospital, Cheeloo College of Medicine, Shandong University, Jinan, People's Republic of China

Correspondence

Dachuan Wang, Department of Orthopedics, The Second Hospital, Cheeloo College of Medicine, Shandong University, 247 Beiyuan Street, Jinan, 250033 Shandong, People's Republic of China.

Email: wangdachuansd@163.com

Abstract

We report a case of a young man with a slow progression of cervical spondylotic myelopathy (CSM). Cervical magnetic resonance imaging (MRI) revealed a mild cervical disc bulging at C5–C6 and an area of atypically enlarged intramedullary high signal intensity extending from C4–C7 (T2-weighted) with contrast enhancement at C5–C6 (T1-weighted). Neurological and radiological diagnoses tend to favor demyelinating diseases, which interfere with the diagnosis of CSM. Patients were followed up and examined by MRI at 3 months, 1 year, and 2 years after surgery. The patient's symptoms improved immediately postoperatively. The functional result according to the modified Japanese Orthopedic Association (JOA) score improved from 10 to 13 within 3 months. He continued to improve neurologically over the first postoperative year. Two years postoperatively, a T2-weighted MRI showed that the edema signal had disappeared completely, and a fat-saturated T2-weighted MRI showed only slight abnormal signal. The numbness and weakness of the extremities had improved, and his JOA score was 16. Spinal cord edema is occasionally seen with CSM. In the case presented, the contrast enhancement was localized at the site of the greatest narrowing of the spinal canal and compression of the spinal cord. This coincidence was the best indicator of a mechanical cause of the spinal cord changes. This feature should increase physician's confidence in distinguishing CSM from intramedullary tumors and myelitis. Surgical decompression may be beneficial in improving neurologic outcomes.

KEYWORDS

cervical spondylotic myelopathy, contrast enhancement, decompression, magnetic resonance imaging, spinal cord edema

This is an open access article under the terms of the [Creative Commons Attribution-NonCommercial-NoDerivs](https://creativecommons.org/licenses/by-nc-nd/4.0/) License, which permits use and distribution in any medium, provided the original work is properly cited, the use is non-commercial and no modifications or adaptations are made.

© 2023 The Authors. *Clinical Case Reports* published by John Wiley & Sons Ltd.

1 | INTRODUCTION

Cervical spondylotic myelopathy (CSM) is the most common cause of spinal cord dysfunction in patients older than 55 years, the most commonly affected area is at C5–C6.¹ Magnetic resonance imaging (MRI) is the most useful diagnostic imaging test for CSM because it can confirm degenerative changes within the spinal cord, disclose the extent, localization, and kind of spinal cord compression, and help rule out other spinal cord disorders (e.g., tumors, syringomyelia, or cord malformation). CSM might appear as a circumscribed area of high signal intensity on T2-weighted MRI. This area is found near the compression point of the spinal cord,^{2,3} and the presence of this finding is correlated with the duration and severity of symptoms and patient outcomes.⁴ Contrast enhancement indicates a disturbance in the blood–brain barrier and is common in the diagnosis of vascular, neoplastic, or infective lesions. Therefore, contrast medium is not routinely used for imaging degenerative diseases of the spine.^{5,6} If the typical area of high signal intensity is atypically enlarged and the anamnesis of the patient does not clearly indicate a degenerative spinal disease, contrast enhancement within an area of high signal intensity is highly suggestive of an infective or neoplastic lesion. Here, we report the case of a patient with CSM in whom initial contrast enhancement of the cervical spinal cord caused some confusion during the diagnostic process.

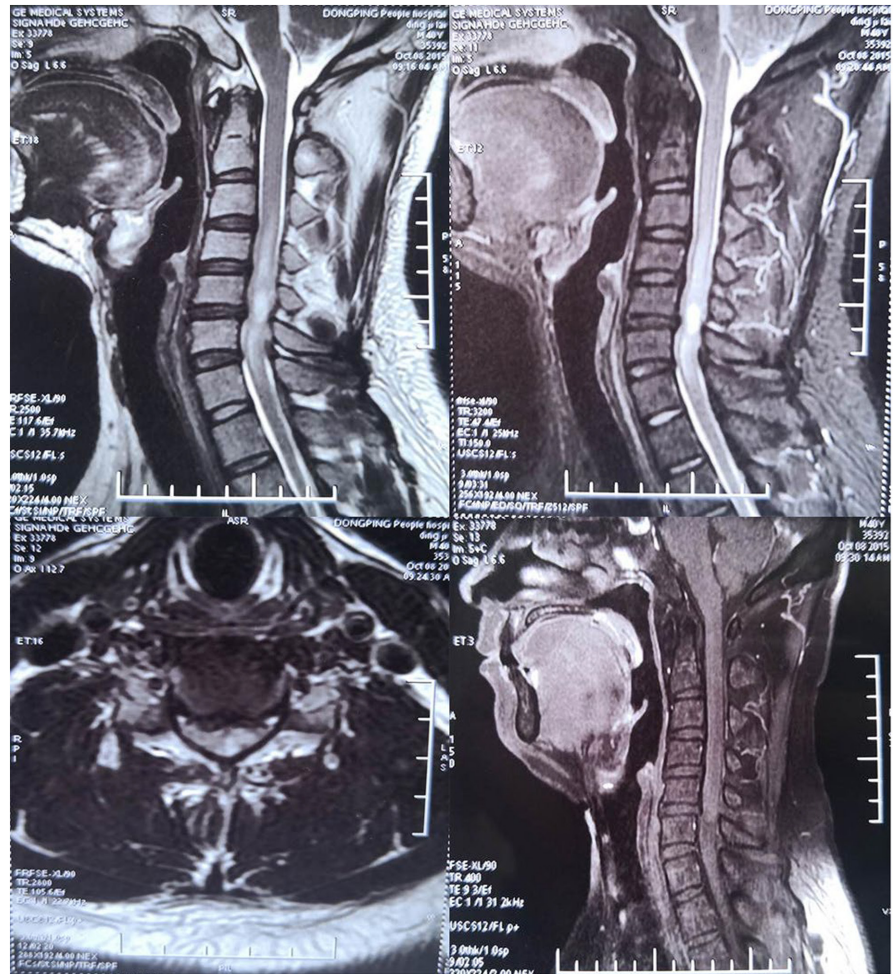
2 | CASE REPORT

A 39-year-old man presented with an 8-month history of bilateral lower limb weakness that was more severe on the left side. Two months later, the patient developed numbness in the left limb and blurred vision in the right eye. He had difficulty with fine motor actions and prickling paresthesia of his left arm and hands. His symptoms were progressive. In addition, he noticed that in his lower limbs, he had a sensation of stepping on cotton that lasted for several months. His physical examination revealed that the muscle strength in his left limb was Grade IV, the muscle tension in his limbs was normal. The bilateral Hoffman sign was (+), and tendon reflexes in the upper limbs were (++) . Bilateral knee reflexes and ankle reflexes were (+++). There was prickling paresthesia in the left limbs, his deep sensation was normal. Bilateral Babinski sign, Chaddock sign, and meningeal stimulation sign were (–), and his Japanese Orthopedic Association (JOA) score was 10. Cervical MRI revealed a mild cervical disc herniation at C5–C6 and an area of atypically enlarged intramedullary high

signal intensity extending from C4–C7 (T2-weighted) with contrast enhancement at C5–C6 (T1-weighted). (Figure 1). Electromyography indicated that the incubation period on the right side of the visual evoked potential (VEP) was longer than that on the left side, and the wave amplitude was lower. The amplitude of P40 on the right side of the somatosensory evoked potential (SEP) was lower than that on the opposite side. Lumbar puncture was performed to assess the cerebrospinal fluid (CSF) and revealed that the CSF pressure was approximately 160 mmH₂O. Oligoclonal band electrophoresis of the CSF was (–), and no microorganisms were identified. The glucose and protein content on biochemical analysis of the CSF were slightly increased. The patient underwent a tortuous process of diagnosis and treatment. He was admitted to the department of neurology and was initially diagnosed with acute myelitis based on CSF examination and electromyography. After a month of glucocorticoid shock therapy, the patient's symptoms did not improve significantly but worsened, and bilateral femoral head necrosis occurred after 3 months. Then, the patient underwent spinal surgery, and a sagittal T2-weighted MRI scan revealed high signal intensity from C4 to C7. The range and intensity of the edema signal increased. Gadolinium (Gd)-enhanced sagittal T1-weighted MRI demonstrated a mild but well-circumscribed contrast-enhanced intramedullary focus at the level of C5–C6. On conventional radiography, kyphosis was observed at C3–C6, but no signs of instability were present. (Figure 2) Careful inquiry of the patient's medical history revealed that the patient had a history of a minor cervical sprain 1 month before the onset of symptoms. Can mild cervical disc herniation cause extensive spinal cord edema and contrast enhancement? We do not have much experience.

After sufficient communication with the patient and his family, we performed single-stage C5/6 anterior cervical discectomy and fusion (ACDF). The patient's postoperative course was uncomplicated, and he had an immediate but partial improvement in his symptoms. During follow-up at 3 months after surgery, MRI showed that the spinal cord was fully decompressed, and the edema signal intensity had not weakened, but the range was reduced. The functional result according to the modified JOA score improved from 10 to 13 within 3 months. (Figure 3) A repeat MRI scan performed 1 year after surgery showed that the signal intensity and range of edema were further reduced, and the patient's clinical symptoms were further improved. (Figure 4) Two years after surgery, the patient's MRI scan showed that the T2-weighted edema signal had disappeared completely, and only slight abnormal signal remained on fat-saturated T2-weighted images. The numbness and weakness

FIGURE 1 2015.10.08. Cervical magnetic resonance imaging (MRI) revealed a mild cervical disc herniation at C5–C6 and an area of atypically enlarged intramedullary high signal intensity extending from C4–C7 (T2-weighted) with contrast enhancement at C5–C6 (T1-weighted).



in his extremities has also improved, and his JOA score was 16. (Figure 5).

3 | DISCUSSION

The extent of the high signal intensity on T2-weighted images is correlated with the patient's disease and prognosis in patients suffering from CSM.⁴ Enhancement of the spinal cord on MRI following administration of Gd has been reported in neoplastic lesions, demyelinating disorders,⁷ acute transverse myelitis,^{8,9} and acute spinal cord injury.^{10,11} However, there have been no systemic studies of Gd-enhanced MRI in patients with CSM. The combination of a highly intense lesion combined with contrast enhancement within the same area might lead to confusion during the diagnostic process even among physicians in neuroscientifically experienced medical disciplines.

Can cervical disc herniation cause extensive spinal cord edema and contrast enhancement? We do not have much experience. We reviewed some literature. Takahashi et al.¹ studied the MRI scans of 668 patients with CSM. Only 99 (14.8%) of these patients showed

circumscribed high signal intensity areas within the spinal cord. Ten of those patients received contrast medium. Only one patient displayed definitive contrast enhancement within the hyperintense area. Boet et al.¹⁰ described the case of a 50-year-old female patient with a history and clinical symptoms of CM. This patient's spinal cord was not significantly compressed at C5–C6. High signal intensity was observed at C5–C7. Although the primary diagnosis was CM, the contrast enhancement of the lesion raised the suspicion of myelitis or a tumor. The patient underwent an anterior cervical discectomy at C5–C6 and improved partially immediately after surgery. An MRI performed 12 months after admittance showed a persistent but smaller area of intramedullary contrast enhancement. Lee et al.¹¹ presented six patients with CSM whose postoperative MRI scans revealed spinal cord swelling with abnormal Gd enhancement. Cabraja et al.¹² also reported a similar case in which the lesion was felt to be neoplastic and was biopsied. The neuropathological examination of an intraoperatively frozen section excluded a tumor or myelitis and suggested an inflammatory reactive process. Neurofilament-stained axons were focally decreased.

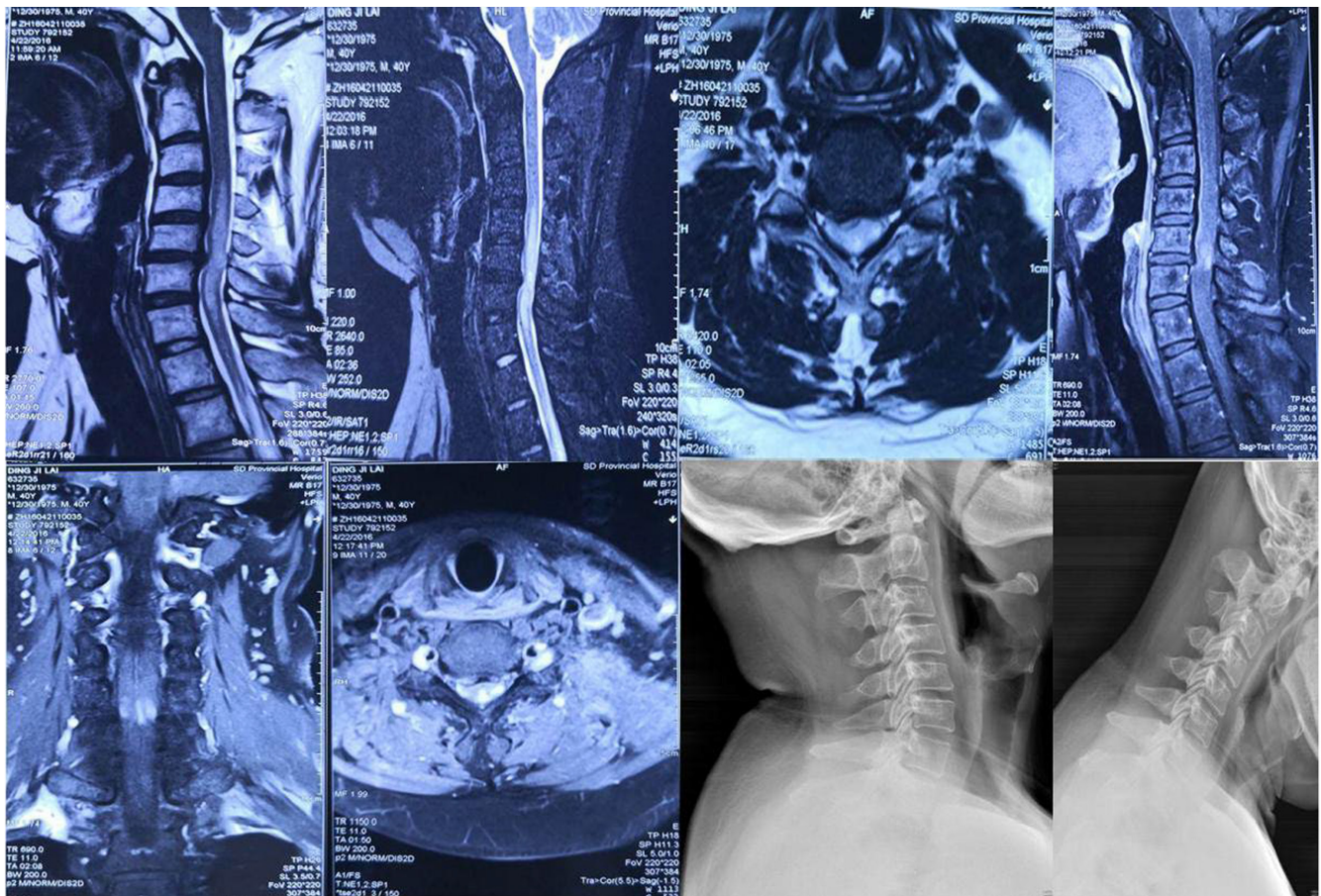


FIGURE 2 2016.04.22. T2-weighted MRI scan revealed high signal intensity from C4 to C7. The range and intensity of the edema signal increased. Gadolinium (Gd)-enhanced sagittal T1-weighted MRI demonstrated a mild but well-circumscribed contrast-enhanced intramedullary focus at the level of C5–C6. On conventional radiography, kyphosis was observed at C3–C6, but no signs of instability were present.

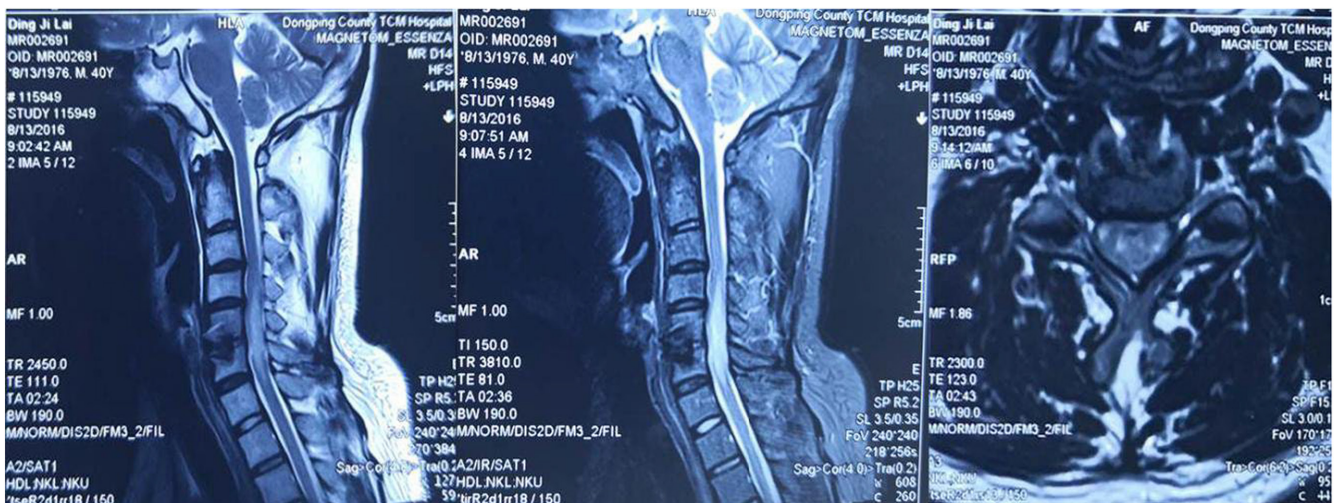

FIGURE 3 2016.08.13. During follow-up at 3 months after surgery, MRI showed that the SC was fully decompressed, and the edema signal intensity had not weakened, but the range was reduced. The functional result according to the modified JOA score improved from 10 to 13 within 3 months.

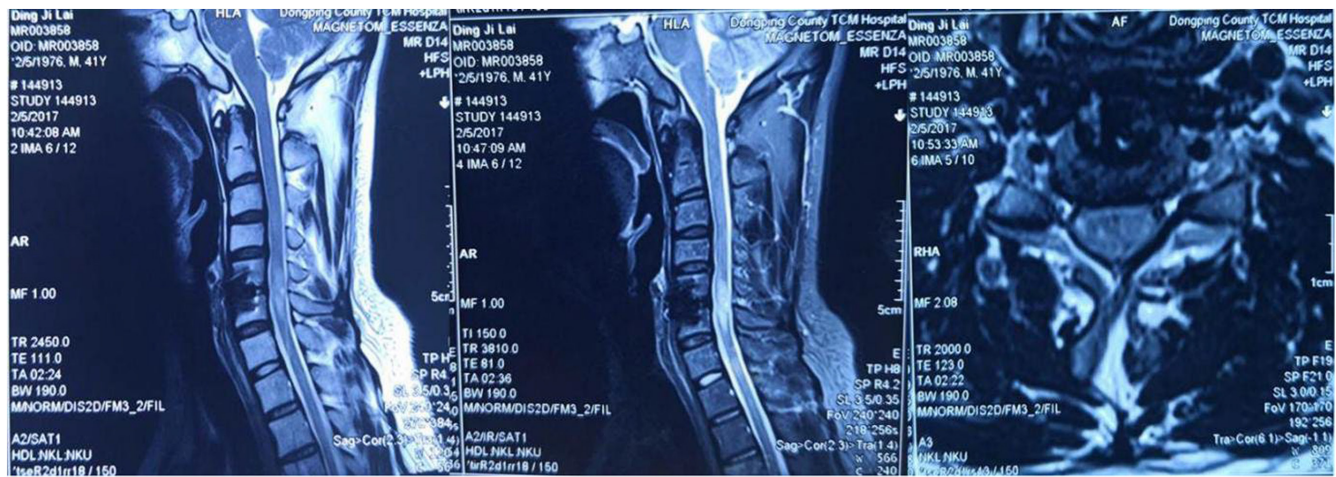

FIGURE 4 2017.02.05. A repeat MRI scan performed 9 months after surgery showed that the signal intensity and range of edema were further reduced, and the patient's clinical symptoms were further improved.

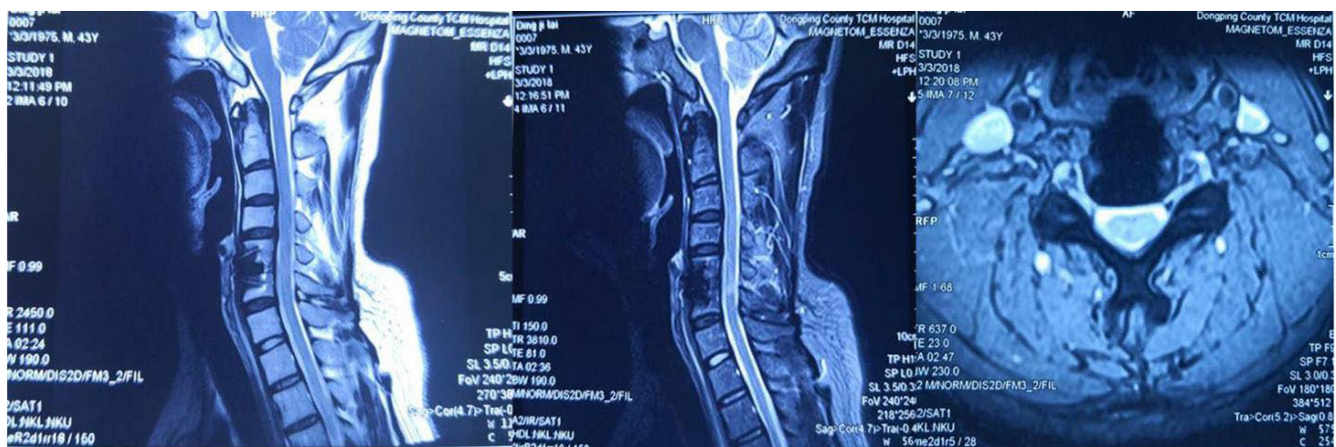

FIGURE 5 2018.03.03. Two years after surgery, the patient's MRI scan showed that the T2-weighted edema signal had disappeared completely, and only slight abnormal signal remained on fat-saturated T2-weighted images. The numbness and weakness in his extremities has also improved, and his JOA score was 16.

Mild reactive gliosis was present, and signs of active demyelination were absent. Sasamori et al.¹³ reported three cases of nonneoplastic lesions mimicking intramedullary tumors on T2-weighted MRI. Patients with spondylotic disease may also demonstrate hyperintensity attributed to spinal cord swelling while also showing some Gd enhancement.

Why does cervical disc herniation cause widespread spinal edema and contrast enhancement? It is assumed that disturbed venous circulation due to spinal cord compression was responsible for local venous hypertension at the affected level. Such venous hypertension is likely to bring about venous ischemia or hyperpermeability of the intramedullary vessels finally, thereby causing spinal cord edema at the compression site and nearby areas. The existence of intramedullary Gd enhancement can be explained by the local hyperpermeability or a break of the

blood–spinal cord barrier of the white matter vessels, most likely venous channels. Intramedullary Gd enhancement on MRI mostly involves the gray matter in arterial spinal cord infarcts.¹⁴ Hashizume et al.¹⁵ illustrated that the most serious pathological changes in the central gray matter and the ventral posterior column were in the areas of the terminal supply of the anterior spinal artery. As it was found that spinal cord damage occurred in the area with minimal compression, arterial, and venous interferences in the damaged regions possibly were responsible for these pathologic changes.^{16,17} Disturbed CSF circulation may have played a role in the development of spinal cord edema. Josephson et al.¹⁸ demonstrated spinal cord edema along with formation of intramedullary cyst in a rat model of spinal thecal sac constriction. Klekamp et al.¹⁹ achieved the inducement of subarachnoid scarring through the place of a kaolin-soaked fibrin sponge on the

posterior surface of the feline spinal cord at C1–2, finding that the intramedullary pressure exceeded the subarachnoid pressure at C-2 in this condition. They come out the conclusion that the arachnoid scarring produced an interstitial type of edema in the central gray matter and enlarged perivascular space in the posterior columns because of the change of CSF and extracellular fluid flow dynamics. In clinical practice, it has been demonstrated that the spinal cord edema occurs in patients suffering from Chiari malformation,²⁰ posterior fossa tumor, or post meningitis state.²¹ These authors attributed obstruction of CSF pathways to spinal cord enlargement with an intramedullary MRI signal abnormality. This “presyrinx state” was improved by decompressive surgery in their series. In our case, there was no visible subarachnoid space around the compressed spinal cord, as demonstrated on preoperative axial MRI. Such subarachnoid space narrowing might cause the CSF blockage around the spinal cord and induce spinal cord edema or the presyrinx state. Sasamori et al.¹³ proposed a third mechanism for spinal cord edema in cervical spondylosis. This unique condition may be associated not only with static but also dynamic factors since the degree of cord compression with the neck in neutral position does not always reflect an increased susceptibility for this condition. Dynamic MRI findings suggest that transient but repetitive cord compression is associated with spinal cord swelling and Gd enhancement in patients with chronic degenerative disorders.

4 | CONCLUSION

This case report highlights that spinal cord edema and the uptake of contrast medium is a possible incident in the slow process of a chronic CSM. It may be difficult to differentiate between CSM, neoplastic or inflammatory diseases when an intramedullary hyperintense lesion is seen. Although the relationships among intramedullary enhancement in cervical compressive myelopathy and clinical severity and outcome have yet to be elucidated, recognition of this feature should increase the physician's confidence in distinguishing CSM from intramedullary tumors and myelitis. We should take an original decompression as well as a long-term follow-up with MRI clinically into consideration. We should take an original decompression as well as a long-term follow-up with MRI clinically into consideration. Enhancing myelopathy occurs in about 7% of compressive myelopathy cases. Edematous cord with enhancing focus usually tempts us to think about neoplastic, vascular, and infective etiology. Awareness of enhancing compressive myelopathy aids in early diagnosis, treatment, and thus the better outcome.

AUTHOR CONTRIBUTIONS

Qingrun Zhu: Writing – review and editing. **Dachuan Wang:** Conceptualization.

FUNDING INFORMATION

This article received no specific grant from any funding agency in the public, commercial or not-for-profit sectors.

CONFLICT OF INTEREST STATEMENT

The authors declare that they have no competing interests.

DATA AVAILABILITY STATEMENT

The datasets used during the current study are available from the corresponding author upon reasonable request. All data and figure are truly available in this article.

CONSENT STATEMENT

Written informed consent was obtained from the patient for publication of this case report and any accompanying images.

ORCID

Qingrun Zhu  <https://orcid.org/0000-0003-1672-6378>

REFERENCES

1. Takahashi M, Yamashita Y, Sakamoto Y, Kojima R. Chronic cervical cord compression: clinical significance of increased signal intensity on MR images. *Radiology*. 1989;173:219-224.
2. Al-Mefty O, Harkey LH, Middleton TH, et al. Myelopathic cervical spondylotic lesions demonstrated by magnetic resonance imaging. *J Neurosurg*. 1988;68:217-222.
3. Mifsud V, Pullicino P. Spinal cord MRI hyperintensities in cervical spondylosis: an ischemic pathogenesis? *J Neuroimaging*. 2000;10:96-100.
4. Yukawa Y, Kato F, Yoshihara H, Yanase M, Ito K. MR T2 image classification in cervical compression myelopathy: predictor of surgical outcomes. *Spine (Phila Pa 1976)*. 2007;32:1675-1678. discussion 1679.
5. Faiss JH, Schroth G, Grodd W, Koenig E, Will B, Thron A. (1990) central spinal cord lesions in stenosis of the cervical canal. *Neuroradiology*. 1990;32:117-123.
6. Kasai Y, Uchida A. New evaluation method using preoperative magnetic resonance imaging for cervical spondylotic myelopathy. *Arch Orthop Trauma Surg*. 2001;121:508-510.
7. Larsson EM, Holtas S, Nilsson O. Gd-DTPA-enhanced MR of suspected spinal multiple sclerosis. *AJNR Am J Neuroradiol*. 1989;10:1071-1076.
8. Campi A, Filippi M, Comi G, et al. Acute transverse myelopathy: spinal and cranial MR study with clinical follow-up. *AJNR Am J Neuroradiol*. 1995;16:115-123.
9. Sanders KA, Khandji AG, Mohr JP. Gadolinium-MRI in acute transverse myelopathy. *Neurology*. 1990;40:1614-1616.
10. Boet R, Chan YL, King A, Mok CT, Poon WS. Contrast enhancement of the spinal cord in a patient with cervical spondylotic myelopathy. *J Clin Neurosci*. 2004;11:512-514.

11. Lee J, Koyanagi I, Hida K, Seki T, Iwasaki Y, Mitsumori K. Spinal cord edema: unusual magnetic resonance imaging findings in cervical spondylosis. *J Neurosurg.* 2003;99:8-13.
12. Tachibana N, Oichi T, Kato S, et al. Spinal cord swelling in patients with cervical compression myelopathy. *BMC Musculoskelet Disord.* 2019;20(1):284.
13. Sasamori T, Hida K, Yano S, Takeshi A, Iwasaki Y. Spinal cord swelling with abnormal gadolinium-enhancement mimicking intramedullary tumors in cervical spondylosis patients: three case reports and review of the literature. *Asian J Neurosurg.* 2010;5:1-9.
14. Friedman DP, Flanders AE. Enhancement of gray matter in anterior spinal infarction. *AJNR Am J Neuroradiol.* 1992;13:983-985.
15. Hashizume Y, Iijima S, Kishimoto H, Yanagi T. Pathology of spinal cord lesions caused by ossification of the posterior longitudinal ligament. *Acta Neuropathol.* 1984;63:123-130.
16. Ponzo G, Umana GE, Giuffrida M, Furnari M, Nicoletti GF, Scalia G. (2020) intramedullary craniovertebral junction metastasis leading to the diagnosis of underlying renal cell carcinoma. *Surg Neurol Int.* 2020;11:152.
17. Iwasaki Y, Abe H, Isu T, Miyasaka K. CT myelography with intramedullary enhancement in cervical spondylosis. *J Neurosurg.* 1985;63:363-366.
18. Scalia G, Costanzo R, Viola A, Bonosi L, Porzio M, et al. Intramedullary spinal cord metastases from breast cancer: a systematic review. *Anticancer Res.* 2023;43(2):523-535.
19. Liu Y-T, Yang T-C, Jung S-M, Lee C-C. Probable pathogenesis, diagnosis, and management of untreated arteriovenous malformation with cyst formation: case report and literature review. *Acta Neurol Belg.* 2018;118(4):603-605.
20. Levy EI, Heiss JD, Kent MS, Riedel CJ, Oldfield EH. Spinal cord swelling preceding syrinx development case report. *J Neurosurg.* 2000;92:93-97.
21. Sartoretti-Schefer S, Kollias S, Valavanis A. Transient oedema of the cervical spinal cord. *Neuroradiology.* 2000;42:280-284.

How to cite this article: Zhu Q, Wang D. Decoding unusual MR findings: Spinal cord edema in atypical cervical spondylotic myelopathy—A case report and literature review. *Clin Case Rep.* 2023;11:e8261. doi:[10.1002/ccr3.8261](https://doi.org/10.1002/ccr3.8261)