

Biplanar Lipoabdominoplasty: Introducing the Subscarpal Lipo Aponeurotic System

Yoram Wolf, MD*†
 Oren Weissman, MD‡
 Helena Dima, MD§
 Judith Sandbank, MD§
 Yifat Fainzilber-Goldman, MD*†

Background: Preservation of Scarpa's fascia in abdominoplasty has been previously presented. Herein we introduce the subscarpal lipo aponeurotic system (SLAS) and the technique of preserving the SLAS and its tightening in lipoabdominoplasty.

Methods: A retrospective cohort study of patients who underwent lipoabdominoplasty performed by a single plastic surgeon (YW) between 2014 and 2019 was conducted. We compared postoperative complications, aesthetic outcomes, and procedure lengths between standard and biplanar lipoabdominoplasty with SLAS tightening. Supra-scarpal fat and SLAS tissue specimens were obtained for histological analysis.

Results: In total, 179 patients underwent biplanar lipoabdominoplasty with SLAS tightening and were compared with a control group of 65 patients who underwent standard lipoabdominoplasty. Fifty-four patients (29.9%) underwent concomitant umbilical, epigastric, or postoperative ventral hernia (POVH) repair. No major complications were encountered other than one skin necrosis in a standard lipoabdominoplasty. Moderate complication rate was 10.05% in the biplanar group, compared with 16.92% in the standard lipoabdominoplasty. The average length of the procedure and overall aesthetic results were equivalent.

Conclusions: The SLAS can be individually dissected and used during abdominoplasty. No statistically significant differences were found in complication rates, length of procedure, or aesthetic outcomes between standard and biplanar lipoabdominoplasty with SLAS tightening. Further investigation is needed. Nonetheless, we postulate that patients who would benefit the most from this procedure are those with weakening of the abdominal wall, and with some fullness of the hip line, as this technique adds reinforcement to the lower abdomen and "pulls in" the flanks. (*Plast Reconstr Surg Glob Open* 2022;10:e4000; doi: 10.1097/GOX.0000000000004000; Published online 5 January 2022.)

INTRODUCTION

Abdominoplasty involves removing excessive tissue (skin and fat) and tightening of the musculo-aponeurotic laxity due to diastasis recti (DR) caused by increased intra-abdominal pressure, most commonly following pregnancy.¹ Imaging modalities (ultrasound, CT, MRI)

evaluating the efficacy of DR correction using plication techniques have demonstrated stable long-term repair.²⁻⁵

Additional techniques to achieve further tightening and reshaping of the abdominal wall and adjacent areas include Scarpa's lift,⁶ which entails preservation of Scarpa's fascia up until the level of the arcuate line and tightening it superiorly to the anterior rectus sheath. This in turn can extend some lift to the medial thigh by extending tension to Colle's fascia and providing limited indirect subcutaneous lift.⁷ Another anatomical layer is utilized when performing an externus belt maneuver that entails raising two additional fascial reins of external oblique aponeurosis, following the completion of the standard plication, and advancing them medially to provide further waist contouring.⁶

*From the *Plastic Surgery Unit, Hillel Yaffe Medical Center, Ruth and Bruce Rappaport Faculty of Medicine, Technion – Israel Institute of Technology, Haifa, Israel; †Dr. Wolf Clinic, Tel Aviv, Israel; ‡Dr. Weissman Clinic, Tel Aviv, Israel; and §Sackler School of Medicine, Tel Aviv University, Israel.*

Received for publication August 26, 2021; accepted October 25, 2021.

Copyright © 2022 The Authors. Published by Wolters Kluwer Health, Inc. on behalf of The American Society of Plastic Surgeons. This is an open-access article distributed under the terms of the Creative Commons Attribution-Non Commercial-No Derivatives License 4.0 (CCBY-NC-ND), where it is permissible to download and share the work provided it is properly cited. The work cannot be changed in any way or used commercially without permission from the journal.

DOI: 10.1097/GOX.0000000000004000

Disclosure: The authors have no financial interests to declare in relation to the content of this article.

Related Digital Media are available in the full-text version of the article on www.PRSGlobalOpen.com.

In this study we describe the anatomy of another distinct layer, previously verified using CT imaging, underlying Scarpa's fascia, overlying the anterior rectus sheath medially and external oblique fascia laterally. We termed this layer the subscarpal lipo aponeurotic system (SLAS). On abdominal CT scan images, the SLAS is presented as a circumferential layer extending all the way to the spinous process adhesion line posteriorly (Fig. 1).

Herein we describe the surgical technique of preserving the SLAS and elevating it as a flap as part of the biplanar lipoabdominoplasty procedure. (See Video 1 [online], which displays an animation of the SLAS used in biplanar abdominoplasty.) The SLAS flap presented is elevated independently of both Scarpa's fascia and the abdominal musculature fascia, to cover the rectus abdominis (RA) fascia following its plication providing further abdominal tightening.

MATERIALS AND METHODS

The patients included in this retrospective cohort study underwent lipoabdominoplasty performed by a single plastic surgeon (YW—senior author), between December 2014 and November 2019. Exclusion criteria included absence of photograph images, absence of significant data in the medical record, and mini, fleur-de-lis, circumferential and floating umbilicus abdominoplasties. We compared a group of 179 patients, who underwent biplanar lipoabdominoplasty (with SLAS preservation, elevation and tightening), with a group of 65 patients who underwent standard lipoabdominoplasty. Demographic and clinical data obtained from patients' files included age, gender, smoking status, pre-surgical body mass index (BMI), number of childbirths and history of cesarean section, bariatric surgery, and previous abdominoplasty procedure (Table 1). The degree of DR, amount of excess skin, skin quality, and lower abdominal bulge was determined upon physical examination; the assessment was performed on a five-point Likert scale (Table 2). Operative variables included lipo-aspirate volume, resection weight, the use of drains or mesh, need for hernia repair, and the length of the procedure (Table 3). Minimal standard follow-up visits, including physical examination and routine photography, are performed on days 1, 5, 14, 30, and

Takeaways

Question: What is the SLAS and is biplanar abdominoplasty beneficial and safe?

Findings: The SLAS is a distinct layer of the abdominal wall with unique characteristics. Biplanar abdominoplasty is a proper and safe alternative to standard abdominoplasty and more beneficial for some patients, with proper patient selection.

Meaning: Biplanar abdominoplasty is a pertinent technique for abdominal wall reinforcement.

90 postoperatively. Aesthetic assessment was evaluated on the last recorded follow-up photographs. Average follow-up time was 2.7 months postoperatively in both groups. Postoperative variables included the amount of follow-up visits, the length of follow up, early and late complication rates, including hematoma and seroma formation, dehiscence, SSI and skin or umbilical necrosis (Table 4), and aesthetic outcome (Table 5). Aesthetic outcomes were evaluated blindly, on a five-point Likert scale, by an external observer, based on patients' images. Three indicators were examined, including overall result, lower bulge residue, and scar quality.

Statistical Analysis

We compared the demographic and clinical data (Table 1), physical examination (Table 2), operative variables (Table 3), postoperative variables (Table 4), and aesthetic outcomes (Table 5) between the two groups: biplanar and standard abdominoplasty groups. For quantitative variables such as age and BMI, *T* test or Mann Whitney U tests were used to compare the groups. For categorical parameters such as marital status and complications, Fisher exact test or Pearson chi squared test were used to compare the groups. A *P* value less than 0.05 was considered significant. SPSS version 27 was used for all statistical analysis.

Operative Procedure

Surgical planning was in the standing position, and included the lower and presumed upper incision lines

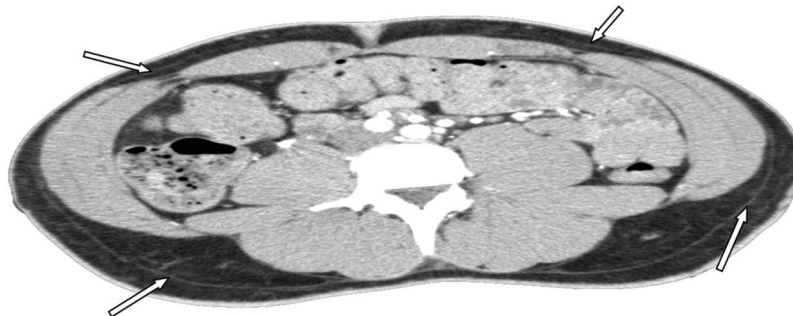


Fig. 1. On abdominal CT scan images, the SLAS is presented as a circumferential layer extending all the way to the spinous process adhesion line posteriorly: underlying Scarpa's fascia, overlying the anterior rectus sheath medially, and external oblique fascia laterally. The arrows indicate Scarpa's fascia.

Table 1. Demographic and Clinical Data

	Biplanar	Standard Abdominoplasty	P
No. patients	179 (73.4%)	65 (26.6%)	
Age (y)	43.4 ± 9.01	42.8 ± 9.5	0.62
Gender			0.61
Men	3 (2%)	2 (3%)	
Women	176 (98%)	63 (97%)	
Family status			0.20
Divorced	26 (15%)	10 (16%)	
Married	137 (78%)	44 (69%)	
Single	9 (5%)	8 (12%)	
Widow	3 (2%)	2 (3%)	
No. children	2.93 ± 1.1	2.65 ± 1.4	0.11
Births	2.79 ± 1.11	2.51 ± 1.4	0.11
Type of delivery			0.24
CS	79 (45%)	35 (54%)	
BMI	26.2 ± 4.12	26.2 ± 5.3	0.92
Smokers	36 (20%)	15 (23%)	0.59
Bariatric surgery (yes)	20 (11%)	9 (14%)	0.65
Secondary procedure (no)	177 (99%)	63 (98%)	1.00

Table 2. Physical Examination

	Biplanar	Standard Abdominoplasty	P
Diastasis recti (DR)	3.38 ± 0.59	3.48 ± 0.71	0.27
Excess skin	2.58 ± 0.88	2.875 ± 0.97	0.027
Quality of skin	3.70 ± 0.87	3.8 ± 0.92	0.42
Lower bulge	2.89 ± 0.96	3.25 ± 1.09	0.015

DR: 1—severe (considerable bulge of the abdomen), 2—substantial (>10 cm), 3—moderate (1–10 cm), 4—mild (<1 cm), 5—none.

Excess skin: 1—most noticeable, 2—noticeable, 3—moderate, 4—mild to moderate, 5—mild.

Quality of skin: 1—worst, 2—poor, 3—medium, 4—good, 5—excellent.

Lower bulge: 1—very severe, 2—severe, 3—moderate, 4—mild to moderate, 5—mild

Values in boldface are statistically significant at *p* < 0.05.

Table 3. Operative Variables

	Bi-planar	Standard Abdominoplasty	P
Lipo- aspirate volume (ml)	1151.5 ± 467	1096.9 ± 539	0.45
Resection weight (gr)	810.5 [450–1256]	630 [382–1310]	0.29
Use of drains (yes)	91 (51%)	43 (66%)	0.042
Use of mesh (yes)	1 (0.6%)	1 (1.5%)	0.46
Parallel umbilical hernia repair	38 (21%)	11 (16.9%)	0.59
Parallel epigastric hernia or POVH repair	16 (8.9%)	5 (7.7%)	1.00
Length of procedure	2:48 ± 0:44	2:50 ± 0:59	0.69

Values in boldface are statistically significant at *p* < 0.05.

and intended liposuction areas (Fig. 2A, B and Fig. 4A, B). Fourteen hours before surgery, prophylactic subcutaneous Clexane 20mg was injected and continued until full ambulation, normally for 4–5 days. General anesthesia was followed by endotracheal intubation, and perioperative antibiotics were administered (cefazolin 1–2 gm IV or, in the presence of penicillin sensitivity, clindamycin 600–900mg IV). Following sterile scrubbing and draping, a tumescent solution (200mg lidocaine and 1mg of adrenaline in 1000cm³ of lactated ringer solution) was administered to the intended liposuction areas (lateral epigastric areas and flanks). The upper abdominal flap also underwent deep liposuction in the subscarpal plane, mostly in the proximal parts of the flap.⁸ Liposuction

Table 4. Postoperative Variables

	Bi-planar	Standard Abdominoplasty	P
No postoperative follow-ups	5.0 ± 2.8	4.9 ± 2.3	0.70
Follow-up length (mo)	2.7 [1.4–5.1]	2.7 [1.6–5.4]	0.59
Total complications	42 (23.5%)	11 (18.5%)	0.47
Mild dehiscence	10 (5.59%)	0	0.066
Moderate dehiscence	8 (4.47%)	8 (12.3%)	0.039
Mild SSI	2 (1.12%)	1 (1.54%)	1.00
Moderate SSI	2 (1.12%)	0	1.00
Mild seroma	7 (3.91%)	0	0.19
Moderate seroma	2 (1.12%)	1 (1.54%)	1.00
Mild skin necrosis	1 (0.56%)	0	1.00
Moderate skin necrosis	2 (1.12%)	1 (1.54%)	1.00
Severe skin necrosis	0	1 (1.54%)	0.27
Moderate umbilical necrosis	4 (2.23%)	0	0.57
Fat necrosis	1 (0.56%)	0	1.00
Mild hematoma	2 (1.12%)	0	1.00

Values in boldface are statistically significant at *p* < 0.05.

Table 5. Aesthetic Outcomes

	Bi-planar	Standard Abdominoplasty	P
Overall result	4.51 ± 0.66	4.45 ± 0.87	0.51
Lower bulge residue	4.73 ± 0.65	4.65 ± 0.72	0.38
Scar quality	4.39 ± 0.86	4.46 ± 0.87	0.54

Overall result: 1—very bad 2—poor 3—medium 4—good, 5—excellent.

Lower bulge: 1—very noticeable, 2—considerable, 3—moderate, 4—mild to moderate, 5—mild.

Scar quality: 1—very poor, 2—poor, 3—medium, 4—good, 5—excellent.

ensued until achieving the desired contour and defatting of the intended areas. Umbilical circumcission and stalk dissection was performed down to the abdominal wall, leaving a wineglass tissue cuff for vascular augmentation. The lower fusiform skin island was incised through skin and subcutaneous fat down to Scarpa’s fascia laterally and down to the anterior rectus sheath in the mid area, intended to be plicated. The island was excised at a level just underneath Scarpa’s fascia laterally, preserving the SLAS. Undermining the upper flap over the RA fascia was maintained up to the xiphoid. Caudal to the dissected umbilical stalk, the SLAS was elevated as laterally based flaps, extending 2–4 cm lateral to the planned rectus sheath plication (Fig. 3). (See Video 2 [online], which shows a demonstration of the SLAS flaps intraoperatively.) Rectus plication ensued to correct DR using two layers of Vicryl 1 sutures, single pulley sutures, followed by a running interlocking suture.

Subsequently, the previously elevated SLAS flaps were medially advanced and the SLAS midline excess trimmed and sutured to each other, using 2/0 Vicryl sutures to achieve SLAS tightening (Fig. 4). Progressive tension tucking sutures were placed, using Vicryl 0 supra-umbilically along the midline and Vicryl 2/0 dispersed underneath the superior flap all the way down to the abdominoplasty incision line. The umbilicus was exteriorized through a vertical incision through the superior flap drawn along the midline.⁹ The flap was then anchored to the mons pubis, and to the scarpal cuff cephalade with three Vicryl 0 single sutures. Skin was approximated in two layers, Vicryl 2/0 spiral continuous sutures for the superficial fascia and Vicryl 3/0 spiral continuous intra-dermal-sutures, finalized by biological glue, dressed and snugged in an abdominal binder.

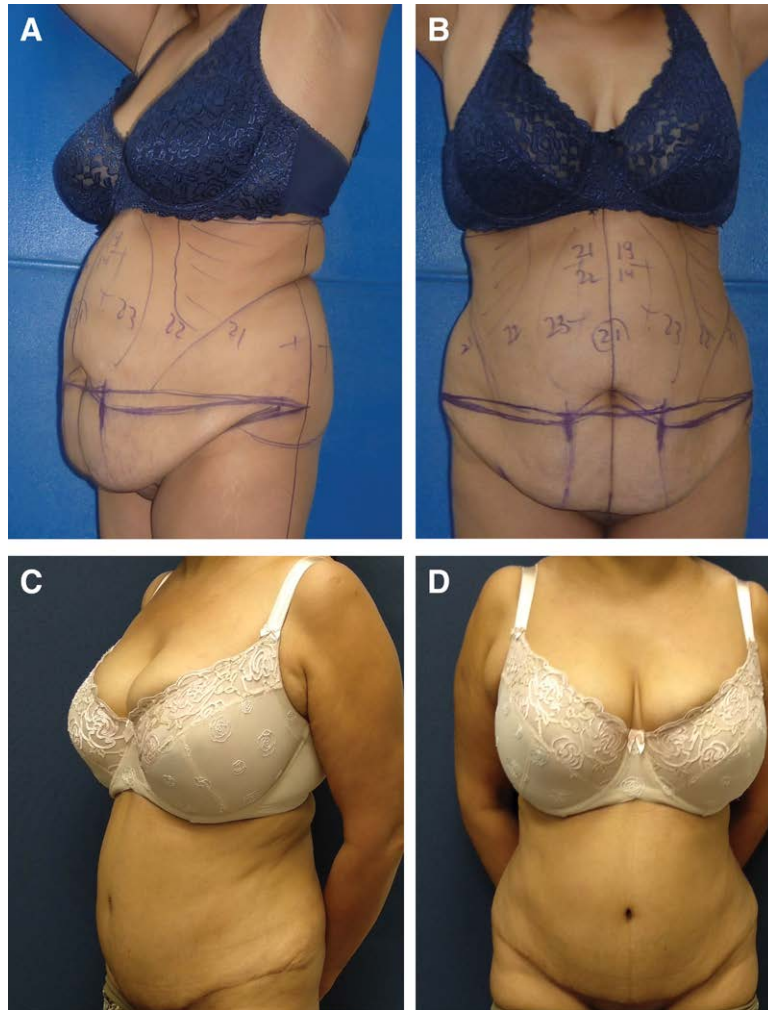


Fig. 2. Preoperative and postoperative images of a 50-year-old patient after biplanar lipoabdominoplasty. Note the tightening of the lateral abdominal wall and hip line area. The scheme of the preoperative planning of the patient is presented. Please note the liposuction units: back rolls, flanks, sub costal, and anterior. The measurements (cm) represent umbilical position and flap size. A, Preoperative; B, 12 months postoperative.

HISTOLOGICAL ANALYSIS

Skin, suprascapular subcutaneous fat, and SLAS tissue specimens were obtained from patients undergoing standard abdominoplasty procedures from the resected abdominal segment, not disrupted by liposuction, after procuring patient consent, and sent for tissue histological fixation, staining, and subsequent examination. Tissue specimens were stained using hematoxylin eosin and Masson trichrom for highlighting collagen fibers and D2-40 (stain for endothelial cells) for identification of blood and lymph vessels.

RESULTS

Histological Analyses of the SLAS

Examination of the histological specimens revealed certain distinct features of the SLAS. Video 3 shows the SLAS in hematoxylin eosin stain, demonstrating less lobular formation and more parallel collagen bundles in a

longitudinal orientation. (See Video 3 [online], which displays a preliminary histological evaluation and characteristics of the SLAS.)

Other specimens stained with Masson trichrome (Video 3) demonstrate the branching of these collagen bundles, while still maintaining their orientation. Also seen are blood vessels that are larger in size and more numerous compared with those in the fat layer overlaying Scarpa's fascia.

Finally, SLAS specimens stained with D2-40 immunostain (Video 3) histological analysis show large blood vessels and relatively developed lymph vessels around them in the SLAS layer.

Results: Retrospective Cohort

Predominately multiparous women (2.79 ± 1.11 children) with mild to severe DR (170/179 cases), average age 43.4 ± 9.01 (range 21–67 years), with average BMI

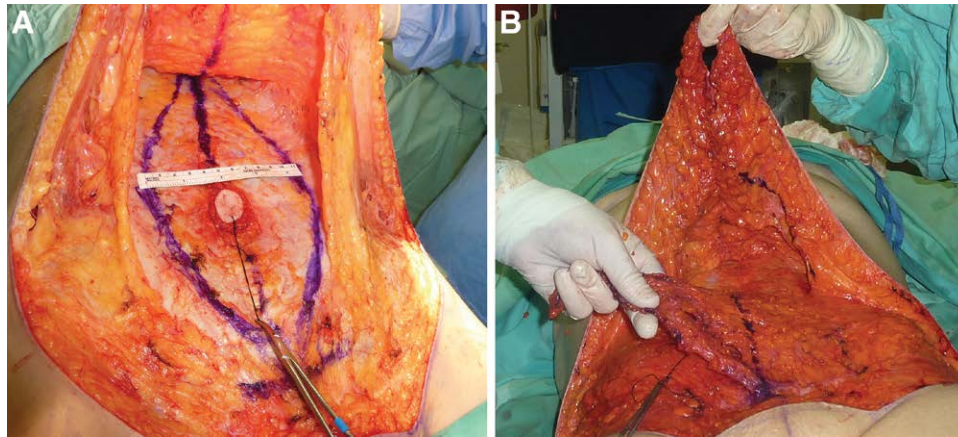


Fig. 3. Intra-operative view of the SLAS. A, The superior abdominal skin flap is elevated while preserving and elevating the SLAS flaps (view before midline placement). B, The Left SLAS flap is pulled to the right over the midline (view after midline placement).

(26.2 ± 4.12), underwent successful biplanar lipoabdominoplasty with SLAS flap tightening. In total, 79 patients (45%) had undergone a cesarean section, and 20 (11%) patients had undergone bariatric procedures on average 4.19 years before the current procedure. Two patients had a previous abdominoplasty procedure performed and 36 (20%) were smokers. The degrees of DR (3.38 ± 0.59), excess skin (2.58 ± 0.88), and lower bulge (2.89 ± 0.96) were assessed by physical examination before performing the procedure, on a five-point Likert scale according to the criteria indicated in the legend of [Table 2](#).

In the biplanar group, the average lipo-aspirate volume was 1151.5 ± 467 ml (range 300–2500 ml) and the average resection weight was 810.5 gr (range 450–1256 gr). An estimated 91 patients (51%) had drainage, and 54 (29.9%) also underwent umbilical, epigastric, or POVH. The average length of the procedure was $02:48 \pm 0:44$ hours ([Table 3](#)).

The control group did not show a statistically significant difference in the above characteristics. However, the

degree of excess skin (2.87 ± 0.97), and of lower bulge (3.25 ± 1.1) were higher in the biplanar group, and drains were more abundantly used in the standard group ([Tables 2, 3](#)).

The postoperative complication rate in the biplanar group was low: mild hematoma in two patients (1.12%), treated by conservative drainage as an office procedure. Seroma formation (mild to moderate) was found in nine patients (5.03%) necessitating percutaneous aspirations; in one case, chronic seroma needed to be surgically resected. Mild to moderate surgical site infection was seen in four patients (2.24%), and required systemic antibiotic treatment. Mild to moderate localized wound dehiscence was observed in 18 patients (10.06%). In three patients (1.68%) localized skin necrosis was seen, and in four patients (2.23%) partial umbilical stalk necrosis was encountered ([Table 4](#)).

No statistical difference was found in the frequency of postoperative complications except for the frequency of moderate dehiscence, which was higher in the standard abdominoplasty group (12.30% versus 4.47%).

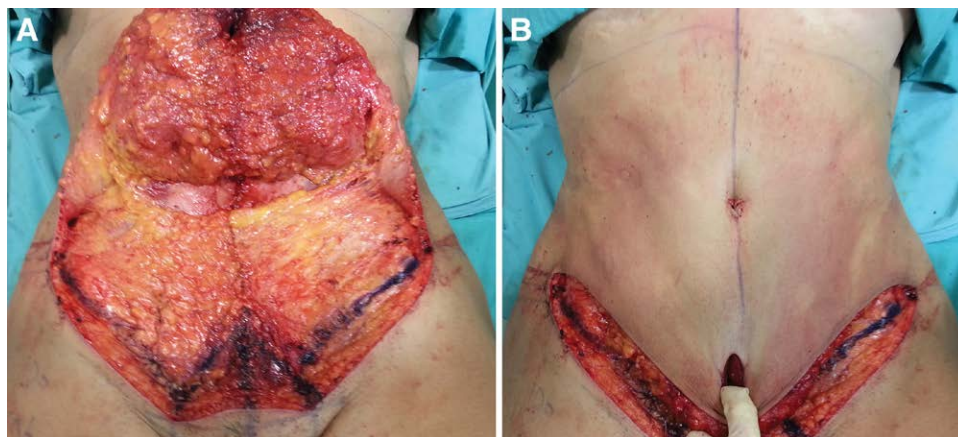

Fig. 4. Lateral SLAS flaps are advanced medially and sutured over the plicated RA fascia, followed by drainless skin closure. A, Intra-operative view of tightened SLAS. B, Intra-operative view of the skin flap re-draped. Note that the actual plication continues routinely inferiorly down to the symphysis pubis.

Aesthetic outcomes were evaluated assessing three indicators on a five-point Likert scale: overall result (4.51 ± 0.66), lower bulge residue (4.73 ± 0.65), and scar quality (4.39 ± 0.86). Criteria for the aesthetic outcome evaluation are indicated in the legend of Table 5. No statistical difference was found in the results between the two methods. However, the starting point, as stated previously, was different, as the skin excess and lower abdominal buldge were significantly greater in the biplanar abdominoplasty group (Table 2).

DISCUSSION

There is a constant rise in the number of abdominoplasty procedures in the annual statistics reports of all plastic surgery societies. There was an increase of 88.5% in the years 2000–2019 in ASPs, and a rise of 21.8% and 2.9% in the years 2015–2019 in ISAPS and ASAPS, respectively. This procedure has been in the top three to six most-common aesthetic surgical procedures in all statistics for many years.¹⁰

The Subscarpal Lipo Aponeurotic System

In the current study, we have used the term “subscarpal lipo aponeurotic system” for the first time. Many plastic surgeons have preserved some of the fatty tissue overlying the musculature fasciae, demonstrating better lymphatic drainage. Nonetheless, the tissue characteristics of this fatty layer have not been described. We verified and preliminarily characterized this distinct layer, the SLAS, using CT imaging and histology analysis. On abdominal CT scan imaging (Fig. 1), the SLAS is presented as a circumferential layer extending all the way to the spinous process adhesion line posteriorly, underlying Scarpa’s fascia, overlying the anterior rectus sheath medially and the external oblique fascia laterally. As demonstrated in histological

findings, the SLAS is a discrete layer which can be differentiated from the supra-scarpal subcutaneous fat. Compared with the supra-scarpal fat layers, the SLAS has more collagen bundles, oriented parallel to the fascia in the SLAS and perpendicular to the fascia in the subcutaneous fat layer (Video 3). In terms of the blood vessels’ size and density, the SLAS has approximately 10%–15% more capillaries, and larger and more numerous blood vessels than in the fat layer overlaying Scarpa’s fascia (Video 3).

Preservation of Scarpa’s fascia has been demonstrated to boost lymphatic drainage and reduce seroma formation.¹¹ Others have preserved only the subscarpal fat, claiming it suffices when combined with drainless closure, thus omitting the need to add progressive tension tucking sutures.¹² Conversely, others disputed the role of Scarpa’s fascia in helping reduce seroma rates.¹³ Previous assessment of the exact lymphatic role of Scarpa’s fascia and the subscarpal fat compartment also proved controversial. A cadaver study found that the long subdermal lymphatic drainers coursing inferiorly just deepen and pierce Scarpa’s fascia at a level only a few centimeters above the inguinal ligament, thus stating that preservation of Scarpa’s fascia is not efficient in boosting postoperative lymphatic drainage.¹⁴ Others found that while most lymphatic channels course in the subdermal plane, about 17% of them course deeper, near the fascial planes and can be preserved while elevating the abdominal flap.¹⁵

In the current study, postoperative seromas were only encountered in nine of 179 patients (5.03%) who underwent biplanar lipoabdominoplasty with SLAS preservation, elevation, and tightening, accompanied with progressive tension tucking sutures: seven mild seromas (3.91%) and two moderate seromas (1.12%) that necessitated percutaneous drainage, one of which was chronic and necessitated a surgical resection. Of those

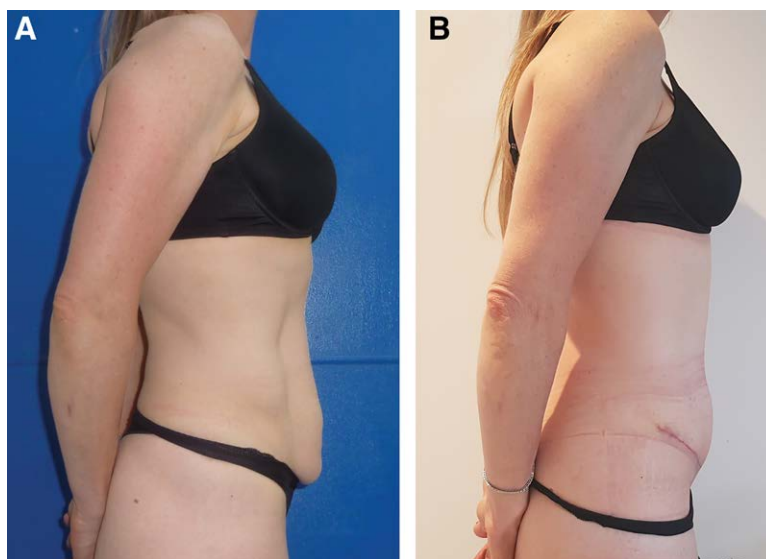


Fig. 5. Preoperative and postoperative images of a 44-year-old patient. In an attempt to demonstrate the limitations of the technique, this figure emphasizes the unfavorable result of added fullness in the inferior abdominal area. A, Preoperative. B, 2 months postoperative.

nine patients, seven were drainless. There was no statistically significant difference in the number of seromas compared with the control group, although in the latter, there was a more statistically significant use of drains.

Our results, accompanied by histological analysis of the tissue, show that the SLAS layer contains more abundant and better developed lymph vessels, and points to possible functions in lymphatic drainage (Video 3). Nonetheless, its efficacy in improving lymphatic drainage is yet to be determined. Additional histology analyses, possibly using different assays, may further elucidate specific characteristics of the SLAS and broaden our understanding of potential future uses in reconstructive and aesthetic surgery of the abdominal wall.

Biplanar Lipoabdominoplasty with SLAS Flap Tightening

In addition to the histological assessment of the SLAS and characterization on CT scans, in this retrospective case series of 179 patients, we also described the surgical technique of preserving the SLAS and elevating it as

a flap, as part of the biplanar lipoabdominoplasty procedure, either with or without the use of postoperative drains. Some examples of postoperative aesthetic results are seen in Figures 2, 5, and 6.

Previous abdominoplasty successes have included preserving the fatty tissue underlying Scarpa's fascia, termed the SLAS, for better lymphatic drainage. The SLAS flap is elevated independently of both Scarpa's fascia and the abdominal musculature fasciae. It covers the RA fascia following its midline suturing and provides further abdominal tightening. The surgical procedure differs slightly from the commonly performed lipoabdominoplasty procedure and can be more time-consuming at the beginning of the learning curve. Preservation of the SLAS necessitates good visualization and recognition of Scarpa's fascia. After its incision, the infra-umbilical abdominal flap is elevated slightly deeper to Scarpa's fascia while preserving the SLAS, adherent to RA fascia and the lateral abdominal wall. The SLAS is then elevated from the RA fascia as two laterally based flaps (Fig. 3, Video 2). Challenges encountered

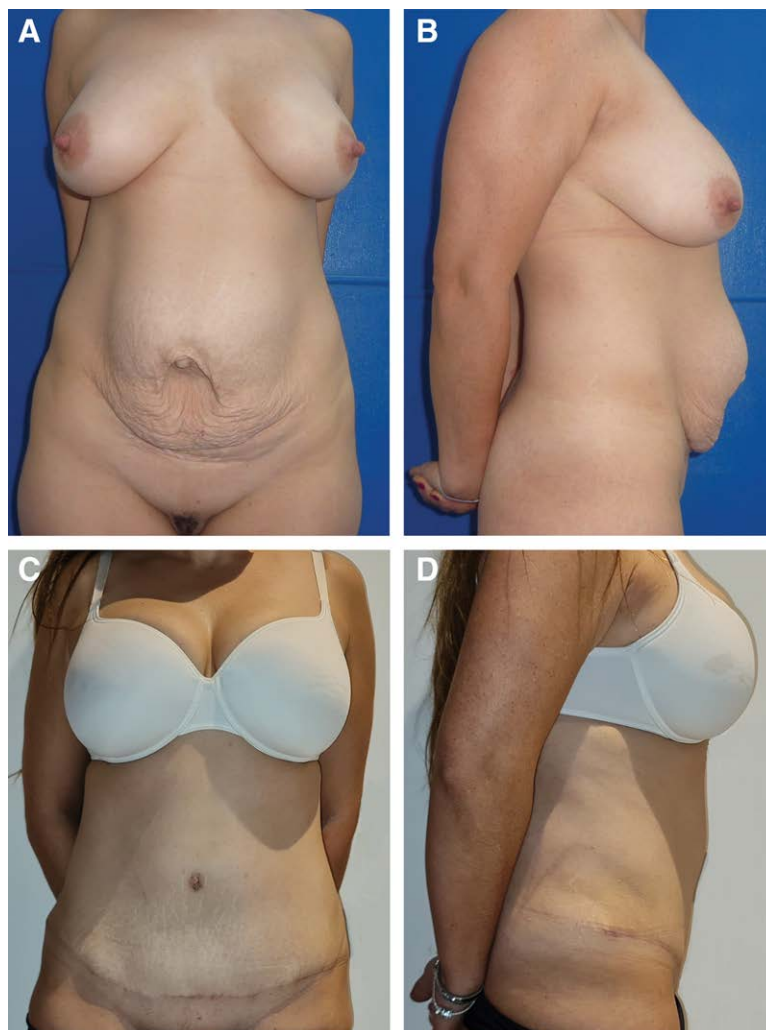

Fig. 6. Preoperative and postoperative images of a 39-year-old patient with concomitant umbilical hernia and significant DR. A, Preoperative. B, 17 months postoperative.

include either an attenuated SLAS in thin individuals or, more commonly encountered, a fibrotic SLAS in patients with a Pfannenstiel incision from a previous cesarean section (45.45% of patients in our case series).

Correction of DR was performed in 170 of the 179 multiparous women. It is usually achieved by plicating the anterior rectus sheath aponeurosis resulting in the reapproximation of adjacent recti muscles toward the midline.^{16–18} A practical plication should provide physiological tension and restoration of the anatomical location of the recti muscle and withstand tension from opposing forces, such as intra-abdominal pressure, muscle contraction, and wound contraction.¹⁶ Several suturing techniques for rectus sheath aponeurosis plication have been previously described.^{19–21} Following RA plication and DR correction, the SLAS flaps are easily advanced and sutured in the midline, after excess trimming. Abdominal tucking sutures also help reduce dead space and help complete the surgical steps in obviating the need for surgical drains.

Nahas has classified abdominal wall deformities into four categories and has suggested different correction techniques for each, including lateral L-shaped plication, to address residual laxity even after approximating the recti muscles.²² Others have also suggested plication techniques that address the need for vertical shortening of the aponeurosis using horizontal plications,²³ suggesting that the reliability of such a plication vector is enhanced due to the subtler direction of the aponeurosis of the external oblique.²⁴ Other techniques that provide vertical and horizontal shortening while better dispersing the tension on sutures include the running horizontal mattress technique²⁵ and the triangular mattress suture.²⁶ Scarpa's lift and externus belt maneuver represent two additional techniques to tighten and reshape the abdominal wall and adjacent areas.^{6,7}

Aesthetic outcomes were evaluated, and no statistical difference was noted in the results between the standard and biplanar surgical approach. However, the starting point was different as the skin excess and lower abdominal buldge were significantly greater in the biplanar abdominoplasty group.

The overall postoperative complication rate was comparable to the previously published information.^{27–30} No major complications were encountered other than one skin necrosis, larger than 5 cm², in a standard lipoabdominoplasty group. The moderate complication rate in the biplanar group was 10.05% compared with 16.92% in the standard group. Moderate complications included SSI with systemic manifestations (fever, chills, or high inflammatory indexes), seroma necessitating surgical resection or large volume drainage, skin dehiscence 1–5 cm in length, and skin and umbilical partial superficial necrosis less than 5 cm². Mild complications were minimal, treated locally and noted for complete and thorough documentation. Mild and moderate complications in the biplanar group summed up to local surgical site infection in four patients (2.24%) requiring oral antibiotics and local treatment, hematoma formation in two patients (1.12%) resolved after office drain insertion, localized wound dehiscence in 18 patients (10.06%), localized skin necrosis in three patients (1.68%) and partial umbilical stalk necrosis in four patients (2.23%), all locally managed.

We attributed the latter to concomitant umbilical hernia repair in three of the four patients. No statistical significance was found in the complication rate between the two methods. To determine a reliable area for this technique, more experience and fine-tuning of the method is needed, as well as continuing evaluation of the learning curve and the nonsmoking policy.

Patient selection is paramount in applying this method. Patients who would not benefit from this procedure are very thin, with an intact and strong abdominal wall (Fig. 5). In some patients, the final aesthetic outcome may be compromised by the added thickness to the inferior abdomen. Supported by the videos, but unfortunately not yet supported by the data, our strong feeling is that the technique is most powerful in the average BMI patient (in our cohort 26.14) with a weakening of the abdominal wall and some fullness of the flanks. This technique is a valuable tool to add reinforcement to the closure and “bring in” the loose tissue around the hip line (Fig. 6). The force by which the SLAS tightening affects the waist line is well demonstrated in Video 4. (**See Video 4 [online]**, which displays an intraoperative medial pull of the SLAS.)

The limitations of this study lie on its retrospective protocol, lacking some long-term follow-up information, thus making it difficult to assess the additive effect to the strength of the lower abdominal wall. Specifically, there is a lack of long-term aesthetic outcomes and of lower abdominal postoperative circumference.

CONCLUSIONS

The SLAS can be individually dissected and used during abdominoplasty. In our study, no statistically significant differences were found in complication rates, length of procedure, or aesthetic outcomes between the cohort that underwent a standard abdominoplasty and the cohort that underwent a biplanar abdominoplasty.

The efficacy of this method should be evaluated in future studies by assessing postoperative edema reduction, lower abdominal wall shape and stability, hip line contour, and ameliorated aesthetic results.

Yoram Wolf, MD

Head of Plastic Surgery

Hillel Yaffe Medical Center

P.O.B 169

Hadera, Israel 38100

E-mail: yoramw@hymc.gov.il

REFERENCES

1. Nahabedian MY. Management strategies for diastasis recti. *Semin Plast Surg.* 2018;32:147–154.
2. Tadiparthi S, Shokrollahi K, Doyle GS, et al. Rectus sheath plication in abdominoplasty: assessment of its longevity and a review of the literature. *J Plast Reconstr Aesthet Surg.* 2012;65:328–332.
3. Mestak O, Kullac R, Mestak J, et al. Evaluation of the long-term stability of sheath plication using absorbable sutures in 51 patients with diastasis of the recti muscles: an ultrasonographic study. *Plast Reconstr Surg.* 2012;130:714e–719e.
4. Nahas FX, Ferreira LM, Ely PB, et al. Rectus diastasis corrected with absorbable suture: a long-term evaluation. *Aesthetic Plast Surg.* 2011;35:43–48.

5. Elkhatib H, Buddhavarapu SR, Henna H, et al. Abdominal musculoaponeurotic system: magnetic resonance imaging evaluation before and after vertical plication of rectus muscle diastasis in conjunction with lipoabdominoplasty. *Plast Reconstr Surg*. 2011;128:733e–740e.
6. Richter DF, Schwaiger N. Abdominoplasty procedures. In: *Plastic Surgery*. 4th ed. vol 2, chapter 23. Amsterdam, Netherlands: Elsevier; 599.
7. Richter DF, Stoff A. The scarpa lift—a novel technique for minimal invasive medial thigh lifts. *Obes Surg*. 2011;21:1975–1980.
8. Saldanha OR, Azevedo SF, Delboni PS, et al. Lipoabdominoplasty: the Saldanha technique. *Clin Plast Surg*. 2010;37:469–481.
9. Rysin R, Wolf Y. Facilitated umbilical positioning in abdominoplasty using the 15/10 rule and the “flap flipping” technique. *Plast Reconstr Surg Glob Open*. 2021;9:e3574.
10. American Society of Plastic Surgeons. The American Society for Aesthetic Plastic Surgery, Cosmetic Surgery National Data Bank Statistics. 2014. Available at <http://www.plasticsurgery.org/Documents/news-resources/statistics/2014-statistics/plastic-surgery-statistics-full-report.pdf>. Accessed August 26, 2021.
11. Costa-Ferreira A, Marco R, Váscónez L, et al. Abdominoplasty with scarpa fascia preservation. *Ann Plast Surg*. 2016;76 (Suppl 4):S264–S274.
12. Quaba AA, Conlin S, Quaba O. The no-drain, no-quilt abdominoplasty: a single-surgeon series of 271 patients. *Plast Reconstr Surg*. 2015;135:751–760.
13. Ribeiro RC, Matos WN Jr, Cruz PFS. Modified lipoabdominoplasty: updating concepts. *Plast Reconstr Surg*. 2016;138:38e–47e.
14. Tourani SS, Taylor GI, Ashton MW. Scarpa fascia preservation in abdominoplasty: does it preserve the lymphatics? *Plast Reconstr Surg*. 2015;136:258–262.
15. Friedman T, Coon D, Kanbour-Shakir A, et al. Defining the lymphatic system of the anterior abdominal wall: an anatomical study. *Plast Reconstr Surg*. 2015;135:1027–1032.
16. Nahas FX, Augusto SM, Ghelfond C. Should diastasis recti be corrected? *Aesthetic Plast Surg*. 1997;21:285–289.
17. Momeni A, Heier M, Bannasch H, et al. The “rising-sun-technique” in abdominoplasty. *Ann Plast Surg*. 2008;60:343–348.
18. Baroudi R, Moraes M. Philosophy, technical principles, selection, and indication in body contouring surgery. *Aesthetic Plast Surg*. 1991;15:1–18.
19. Meeks GR, Nelson KC, Byars RW. Wound strength in abdominal incisions: a comparison of two continuous mass closure techniques in rats. *Am J Obstet Gynecol*. 1995;173:1676–1682.
20. van't Riet M, de Vos van Steenwijk PJ, Kleinrensink GJ, et al. Tensile strength of mesh fixation methods in laparoscopic incisional hernia repair. *Surg Endosc*. 2002;16:1713–1716.
21. Austin BR, Henderson RA. Buried tension sutures: force-tension comparisons of pulley, double butterfly, mattress, and simple interrupted suture patterns. *Vet Surg*. 2006;35:43–48.
22. Nahas FX. An aesthetic classification of the abdomen based on the myoaponeurotic layer. *Plast Reconstr Surg*. 2001;108:1787–1795.
23. Yousif NJ, Lifchez SD, Nguyen HH. Transverse rectus sheath plication in abdominoplasty. *Plast Reconstr Surg*. 2004;114:778–784.
24. Ishida LH, Gemperli R, Longo MV, et al. Analysis of the strength of the abdominal fascia in different sutures used in abdominoplasties. *Aesthetic Plast Surg*. 2011;35:435–438.
25. Weissman O, Zmora N, Rozenblatt SM, et al. Simple continuous suture versus continuous horizontal mattress suture for plication of abdominal fascia: which is better? *Aesthetic Plast Surg*. 2012;36:1015–1018.
26. Verissimo P, Nahas FX, Barbosa MV, et al. Is it possible to repair diastasis recti and shorten the aponeurosis at the same time? *Aesthetic Plast Surg*. 2014;38:379–386.
27. Raghuram AC, Yu RP, Gould DJ. The addition of partial or circumferential liposuction to abdominoplasty is not associated with a higher risk of skin necrosis. *Aesthet Surg J*. 2021;41:NP433–NP444.
28. Restifo RJ. Sub-scarpa’s lipectomy in abdominoplasty: an analysis of risks and rewards in 723 consecutive patients. *Aesthet Surg J*. 2019;39:966–976.
29. Samra S, Sawh-Martinez R, Barry O, et al. Complication rates of lipoabdominoplasty versus traditional abdominoplasty in high-risk patients. *Plast Reconstr Surg*. 2010;125:683–690.
30. Vidal P, Berner JE, Will PA. Managing complications in abdominoplasty: a literature review. *Arch Plast Surg*. 2017;44:457–468.