



Incidence and Risk Factors of Nausea and Vomiting after Exposure to Low-Osmolality Iodinated Contrast Media in Children: A Focus on Preparative Fasting

Ji Young Ha, MD, PhD¹, Young Hun Choi, MD, PhD^{2,3}, Yeon Jin Cho, MD^{2,3}, Seunghyun Lee, MD², Seoul Bi Lee, MD², Gayoung Choi, MD², Jung-Eun Cheon, MD, PhD^{2,3,4}, Woo Sun Kim, MD, PhD^{2,3,4}

¹Department of Radiology, Gyeongsang National University Changwon Hospital, Changwon, Korea; ²Department of Radiology, Seoul National University Hospital, Seoul, Korea; ³Department of Radiology, Seoul National University College of Medicine, Seoul, Korea; ⁴Institute of Radiation Medicine, Seoul National University Medical Research Center, Seoul, Korea

Objective: To evaluate the incidence and risk factors of emetic complications associated with the intravenous administration of low-osmolality iodinated contrast media (ICM) in children undergoing computed tomography (CT).

Materials and Methods: All children who underwent contrast-enhanced CT between April 2017 and July 2019 were included. Pediatric patients were instructed on the preparative dietary protocol at our institution. Experienced nurses in the radiology department monitored the children during the CT scans and recorded any emetic complications in their electronic medical records. These data were used to calculate the incidence of emetic complications. Various patient factors and technical factors, including fasting duration, the type and volume of ICM, and ongoing chemotherapy, were evaluated to identify risk factors for emetic complications using univariate and multivariate logistic regression analyses.

Results: Among the 864 children (mean age, 8.4 ± 5.7 years) evaluated, 18 (2.1%) experienced emetic complications (6 experienced nausea only and 12 experienced nausea and vomiting). None of the children developed aspiration pneumonia. The mean fasting duration of patients with emesis was 7.9 ± 5.7 hours (range, 3–21 hours), whereas that of patients without nausea was 8.7 ± 5.7 hours (range, 0–24 hours). Fasting duration was not associated with the development of nausea and vomiting ($p = 0.634$). Multivariate logistic regression analysis revealed that ongoing chemotherapy (odds ratio [OR] = 4.323; 95% confidence interval [CI] = 1.430–13.064; $p = 0.009$), iomeprol use (OR = 7.219; 95% CI = 1.442–36.146; $p = 0.016$), and iohexol use (OR = 5.241; 95% CI = 1.350–20.346; $p = 0.017$) were independent risk factors for emetic complications.

Conclusion: Only a small proportion (2.1%) of children experienced nausea or vomiting after exposure to low-osmolality ICM. Many children underwent excessive fasting; however, fasting duration was not associated with nausea and vomiting. Moreover, ongoing chemotherapy and the use of iomeprol or iohexol were identified as potential risk factors for emetic complications in children.

Keywords: Contrast media; Computed tomography; Children; Nausea; Fasting

INTRODUCTION

Nausea and vomiting are common acute adverse reactions to iodinated contrast media (ICM). Most

guidelines regarding contrast media safety classify nausea and vomiting as physiologic reactions representing a physiologic response to the contrast material. Although quite rare, nausea and vomiting can lead to aspiration

Received: November 7, 2019 **Revised:** March 26, 2020 **Accepted:** April 1, 2020

This research was supported by a grant of the Korea Health Technology R&D Project through the Korea Health Industry Development Institute (KHIDI), funded by the Ministry of Health & Welfare, Republic of Korea (grant number: HI15C1532).

Corresponding author: Young Hun Choi, MD, PhD, Department of Radiology, Seoul National University Hospital, Seoul National University College of Medicine, 101 Daehak-ro, Jongno-gu, Seoul 03080, Korea.

• E-mail: iater@snu.ac.kr

This is an Open Access article distributed under the terms of the Creative Commons Attribution Non-Commercial License (<https://creativecommons.org/licenses/by-nc/4.0>) which permits unrestricted non-commercial use, distribution, and reproduction in any medium, provided the original work is properly cited.

pneumonia. In the era of high-osmolality ICM, up to 24.5% of adult patients experienced vomiting after intravascular administration of ionic high-osmolality ICM (1, 2). However, with the introduction of nonionic low-osmolality ICM, the reported frequency of vomiting has declined, ranging from less than 1% to 11.7% in adults, according to different studies (3, 4). However, the incidence of nausea and vomiting in children remains unknown.

Before contrast-enhanced computed tomography (CT), patients were traditionally instructed to fast because of concerns about aspiration pneumonia associated with vomiting. This approach seemed sensible given the high rate of emetic complications associated with the use of ionic and high-osmolality contrast media. Nowadays, nearly all radiological clinics in industrialized countries use only low-osmolality nonionic ICM, which is associated with a lower risk of emetic complications (5-7). Therefore, questions remain about the rationale for preparative fasting before CT.

Nevertheless, preparative fasting remains a common request, even though the policy regarding fasting duration and content (solids or fluids) varies considerably across hospitals (4, 8). Furthermore, fasting is required when infants and children require sedation. Ironically, in infants and children, prolonged fasting itself can lead to detrimental metabolic and behavioral effects, increased irritability, and an increased need for sedation in patients who would not otherwise require sedation in a clinical setting. Small children are particularly vulnerable to dehydration and hypoglycemia. Recently, several large-scale clinical studies on adult patients investigated the risk factors for emetic complications after ICM exposure (3, 9). These studies showed that fasting duration was not associated with emetic complications, and the authors did not recommend excessive fasting because of the risks of dehydration and contrast media-induced nephropathy. With regard to children who require sedation, the American Academy of Pediatrics/American Society of Anesthesiologists (ASA) 2019 guidelines and European Society of Anaesthesiology 2011 guidelines recommend a 2-hour fasting interval for clear fluids, a 4-hour fasting interval for breast milk, and a 6-hour fasting interval for solids (6-4-2 regimen) (10-14). For children who do not require sedation, no standard preparative fasting guidelines are available. Therefore, different fasting guidelines are currently being used across pediatric medical centers in different countries (4, 15). At our institution, a preparative

fasting protocol has been established, and a patient monitoring system has been implemented to assess emetic complications in children who undergo CT.

To the best of our knowledge, no study has investigated the incidence and risk factors of nausea and vomiting after exposure to nonionic low-osmolality ICM in children. Thus, the aim of this study was to evaluate the incidence of nausea and vomiting after exposure to nonionic low-osmolality ICM and to identify potential risk factors for emetic complications in children with a focus on preparative fasting.

MATERIALS AND METHODS

Our Institutional Review Board approved this study. The requirement for informed consent was waived because of the retrospective nature of this study.

Preparative Dietary Protocols and Monitoring System at Our Institution

According to our institutional policy, the parents or legal guardians of each child received the following dietary instructions, regardless of the type of CT scan being performed (Table 1).

The dietary instructions given to children who underwent ICM-enhanced CT without sedation were dependent on their age: those younger than 12 months were asked to fast from solid food and non-clear liquids for 2 hours before the scan; those aged 1 to 4 years were asked to fast for 3 hours; and those aged 5 years or older were asked to fast for 4 hours. Clear liquids (i.e., liquids that are transparent and do not contain particulates) such as water and tea without carbohydrates were not restricted.

Table 1. Preparative Dietary Protocols at Our Institution

Age	Fasting Requirement	
No sedation or Oral sedation [†]		
< 12 months	Solid food and non-clear liquids (clear liquids* are not restricted.)	2 h
1-4 years		3 h
≥ 5 years		4 h
Intravenous sedation [†]		
All ages	Clear liquids*	2 h
	Breast milk	4 h
	Solid food [‡]	6 h

*Clear liquids include liquids that are transparent and contain no particulates, e.g., water and tea without carbohydrates, [†]Regardless of usage of contrast agent, [‡]Including other milk products, such as animal (cow's or goat's) milk and formula products. h = hours

When children were sedated using oral sedatives (chloral hydrate; Pocral syrup 10% mL, Hanlim Pharm Co., Ltd.), the aforementioned fasting protocol was applied. When intravenous sedatives (midazolam and/or ketamine) were administered, the following fasting protocols were applied, regardless of the patient's age: clear liquids were restricted for 2 hours before the administration of sedatives; breast milk was restricted for 4 hours; and solid food and other milk products, including animal milk and formula products, were restricted for 6 hours. In case of emergency, the CT scan was performed under the supervision of a doctor, regardless of the child's fasting status.

In the CT preparation room, radiology nurses determined the actual fasting duration and last ingested food for each patient. They also recorded the presence of preexisting sensations of nausea, recent episodes of vomiting, or other gastrointestinal symptoms by taking a comprehensive medical history.

Radiology nurses observed the children during ICM administration and up to 30 minutes afterward. They recorded the occurrence of nausea or nausea with vomiting following ICM injection, the duration of symptoms, and the need for antiemetic drugs. Experienced nurses classified symptom severity using a two-point scale based on their subjective judgment. Emetic complications were considered mild to moderate when the child exhibited slight nausea or minimal vomiting but was capable of tolerating the CT examination; emetic complications was considered severe when the child vomited several times and was unable to tolerate the CT examination. The nurses documented all data related to nausea and vomiting using a standardized form.

Patients

Data from all patients who underwent contrast-enhanced CT examinations at our hospital between April 2017 and July 2019 were retrospectively reviewed. We included patients who were below 20 years of age and underwent ICM-enhanced CT scan during regular working hours on a weekday. We excluded patients who were 20 years old or older or whose medical records did not contain information about the occurrence of nausea and vomiting before and after the CT scan (Fig. 1).

Assessment of Patient Status

In addition to the data recorded by the radiology nurses, we obtained the following information from the electronic

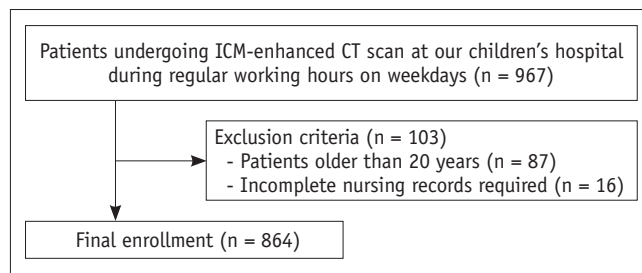


Fig. 1. Flowchart illustrating selection of study population. CT = computed tomography, ICM = iodinated contrast media

medical records of the enrolled patients: age; sex; body mass index (BMI); admission type; type of CT examination; type and volume of ICM injected; previous history of ICM usage and adverse reactions to ICM, including ICM hypersensitivity; use and type of premedication; and the presence of underlying diseases, including cardiac disease, hemato-oncologic malignancies, infection/inflammation, and other diseases. "Other diseases" included heterogeneous diseases such as lymphovascular disease, biliary atresia, pulmonary sequestration, branchial cleft cyst, and duplication cyst. With respect to patients with hemato-oncologic malignancies, we noted if they were undergoing chemotherapy. We defined patients as being "on" chemotherapy if they had been administered chemotherapy agents in the 14 days prior to the CT scan.

Fasting duration was classified according to 30-minute intervals and was categorized into five groups: 4 hours or less, more than 4 hours but less than or equal to 6 hours, more than 6 hours but less than or equal to 12 hours, more than 12 hours but less than 24 hours, and 24 hours or more. To compare each patient's actual fasting duration to the recommended fasting duration based on their age and whether they required intravenous sedation, we classified the patients into four groups. The less fast group comprised patients who fasted for over 30 minutes less than recommended. The appropriate fast group comprised patients who fasted for up to 30 minutes less than recommended and patients who fasted for up to 2 hours more than recommended. The excessive fast group comprised patients who fasted for between 2 and 12 hours more than recommended. The very excessive fast group comprised patients who fasted for over 12 hours more than recommended.

Among the patients who experienced nausea and vomiting, we evaluated the occurrence of aspiration pneumonia after the CT scan by assessing their medical records and analyzing chest radiographs obtained within 3

days of the CT scan, if available.

CT Examination

Various CT protocols involving a 128-slice scanner (SOMATOM Definition Flash, Siemens Healthcare) were used to examine the enrolled patients. All CT scans were performed using one of five types of nonionic low-osmolality ICM: iobitridol 350 (Xenetix®; Guerbet), ioversol 320 (Optiray®; Mallinckrodt Medical), iohexol 350 (Omnipaque®; GE Healthcare), iomeprol 400 (Iomeron®; Bracco), and iopamidol 370 (Pamiray®; Dongkook Pharmaceutical Co., Ltd.). At our institution, each type of ICM was used for a different type of CT examination. The total dose and injection rate of ICM were determined based on the patient's body weight and CT protocol. For multiphasic CT with the arterial phase, a 1.7 mL/kg dose of ICM was administered over 25–30 seconds (minimum injection rate of 0.7 mL/s), followed by a saline chaser of up to 20 mL. For single-venous phase enhanced CT, a 1.7 mL/kg dose of ICM was administered over 50 seconds, followed by a saline chaser of up to 20 mL. For cardiac CT, a 1.5–2 mL/kg dose of ICM was administered at a rate of 1–3 mL/s, followed by a saline chaser injected at the same rate. We classified multiphasic and cardiac CT examinations as rapid injection rate examinations and single-phase CT examinations as routine injection rate examinations.

Statistical Analysis

Demographic and clinical characteristics were compared between patients who experienced nausea or vomiting and those who did not. The chi-square test was used to analyze categorical variables and the Mann-Whitney test was used to analyze continuous variables. The linear-by-linear association test was used to evaluate the frequency of nausea and vomiting according to fasting duration. Univariate logistic regression analysis was performed to evaluate the predictive power of individual variables. Variables with high predictive power ($p < 0.10$, Wald test) were selected and fed into a multivariate logistic regression model to identify the risk factors associated with nausea and vomiting. During the multivariate analysis, the multicollinearity of variables was investigated using collinearity statistics tolerance. All variables analyzed in the multivariate analysis exhibited variance inflation factors less than 5. A p value < 0.05 was considered statistically significant. All statistical analyses were performed using SPSS Statistics, version 22.0 (IBM Corp.).

RESULTS

Patients

The characteristics of the patients are summarized in Table 2. In total, 864 children (492 males and 372 females; mean age: 8.41 ± 5.73 years, range: 1 day–19.58 years) were included in this study. Among them, 18 (2.1%, 9 males and 9 females; mean age: 10.89 ± 3.64 years, range: 4.17–17.92 years) experienced emetic complications. Of these children, 6 (33.3%) experienced nausea only and 12 (66.7%) experienced nausea with vomiting.

Of the 18 pediatric patients who experienced emetic complications, 14 (77.8%) experienced nausea and vomiting during ICM administration and 4 (22.2%) exhibited symptoms after completion of the CT scan. Among these 4 patients, the average time interval between ICM injection and symptom manifestation was 6 minutes 15 seconds (range, 5–10 minutes). The average symptom duration in the 18 patients who experienced emetic complications was 8 minutes 10 seconds (range, 2–20 minutes). Among these 18 patients, 17 (94.4%) had mild to moderate symptoms which persisted for 8.23 ± 5.66 minutes (range, 2–20 minutes). The remaining patient (5.6%) experienced several episodes of vomiting which lasted 7 minutes in total. In all 18 patients, the symptoms subsided spontaneously, and none required antiemetic drugs or developed aspiration pneumonia.

Among the 18 patients who experienced emetic complications, 1 had a history of allergic-like reactions to ICM; however, these reactions did not include gastrointestinal symptoms such as nausea and vomiting, and the patient was premedicated with an antihistamine. Among the 864 patients, 4 (0.46%) experienced urticaria and an itching sensation, and these mild adverse reactions were self-limiting. Among the patients who complained of nausea or vomiting, none had allergic-like reactions to ICM.

In the nausea group, 16 patients (88.9%) had consumed solid food before the CT scan, 1 (5.6%) had consumed a non-clear liquid, and 1 (5.6%) had consumed water. Among the 18 patients in this group, 17 (94.4%) did not receive sedation and 1 (5.6%) received oral sedation.

Age, sex, BMI, admission type, sedation status, type of last ingested food, injection rate, volume of ICM administered, premedication use, and the proportions of patients with underlying diseases or preexisting gastrointestinal symptoms did not significantly differ between the two groups (Table 2). However, the type

Table 2. Patient Characteristics in Nausea and Non-Nausea Groups

	Total (n = 864)	Nausea (n = 18)	Non-Nausea (n = 846)	P
Sex				0.548
Male	492 (56.9)	9 (50.0)	483 (57.1)	
Female	372 (43.1)	9 (50.0)	363 (42.9)	
Age (yr)	8.4 ± 5.7	10.9 ± 3.6	8.3 ± 5.6	0.081
BMI (kg/m ²)	17.91 ± 5.79	18.64 ± 3.48	17.89 ± 5.83	0.165
Admission type				0.333
Inpatient	481 (55.7)	8 (44.4)	473 (55.9)	
Outpatient	383 (44.3)	10 (55.6)	373 (44.1)	
Sedation				0.056
No sedation	640 (74.1)	17 (94.4)	623 (73.6)	
Oral sedation	204 (23.6)	1 (5.6)	203 (24.0)	
IV sedation	16 (1.9)	0 (0)	16 (1.9)	
Oral + IV sedation	4 (0.5)	0 (0)	4 (0.5)	
Types of last ingested food				0.769
Water	34 (3.9)	1 (5.6)	33 (3.9)	
Breast milk	10 (1.2)	0 (0)	10 (1.2)	
Infant formula	76 (8.8)	0 (0)	76 (9.0)	
Semisolid food	42 (4.9)	0 (0)	42 (5.0)	
Other fluids (fruit juice)	84 (9.7)	1 (5.6)	83 (9.8)	
Solid food	586 (67.8)	16 (88.9)	570 (67.4)	
None	32 (3.7)	0 (0)	32 (3.8)	
Underlying disease				0.854
Cardiac disease	205 (23.7)	3 (16.7)	202 (23.9)	
Hemato-oncologic malignancy	400 (46.3)	10 (55.6)	390 (46.1)	
Infection/inflammation	110 (12.7)	2 (11.1)	108 (12.8)	
Others	149 (17.2)	3 (16.7)	146 (17.3)	
Injection rate				0.756
Rapid	269 (31.1)	5 (27.8)	264 (31.2)	
Routine	595 (68.9)	13 (72.2)	582 (68.8)	
Nonionic low-osmolality ICM				0.009
Iobitridol	692 (80.1)	9 (50.0)	683 (80.7)	
Ioversol	60 (6.9)	3 (16.7)	57 (6.7)	
Iomeprol	29 (3.4)	2 (11.1)	27 (3.2)	
Iohexol	48 (5.6)	3 (16.7)	45 (5.3)	
Iopamidol	35 (4.1)	1 (5.6)	34 (4.0)	
Total dose of ICM administration (mL)	51.2 ± 32.0	60.1 ± 24.8	50.6 ± 31.7	0.098
Premedication				0.057
None	855 (99.0)	17 (94.4)	838 (99.1)	
Antihistamine	9 (1.0)	1 (5.6)	8 (0.9)	
Chemotherapy				0.006
None	785 (90.9)	13 (72.2)	772 (91.3)	
On doing	79 (9.1)	5 (27.8)	74 (8.7)	
Gastrointestinal symptoms before CT				0.902
Absent	810 (93.8)	17 (94.4)	793 (93.7)	
Present	54 (6.3)	1 (5.6)	53 (6.3)	

Data are presented as number (%) or mean ± standard deviation. BMI = body mass index, CT = computed tomography, ICM = iodinated contrast media, IV = intravenous

Table 3. Incidence of Nausea according to Fasting Duration

	Total (n = 864)	Group		P
		Nausea (n = 18)	Non-Nausea (n = 846)	
Fasting duration (h)				0.634
≤ 4	276 (31.9)	5 (27.8)	271 (32.0)	
> 4 but ≤ 6	155 (17.9)	6 (33.3)	149 (17.6)	
> 6 but ≤ 12	221 (25.6)	3 (16.7)	218 (25.8)	
> 12 but < 24	173 (20.0)	4 (22.2)	169 (20.0)	
≥ 24	39 (4.5)	0 (0.0)	39 (4.6)	
Adequacy of fasting duration				0.538
Less	25 (2.9)	1 (5.6)	24 (2.8)	
Appropriate	345 (39.9)	9 (50.0)	336 (39.7)	
Excessive	394 (45.6)	5 (27.8)	389 (46.0)	
Very excessive	100 (11.6)	3 (16.7)	97 (11.5)	

Data are presented as number (%).

Table 4. Multivariate Logistic Regression Analysis of Risk Factors for Nausea

	Exp(B) (95% CI)	P
Chemotherapy		
None	1.000 (reference)	
On doing	4.323 (1.430–13.064)	0.009
Nonionic low-osmolality ICM		
Iobitridol	1.000 (reference)	
Ioversol	3.405 (0.876–13.231)	0.077
Iomeprol	7.219 (1.442–36.146)	0.016
Iohexol	5.241 (1.350–20.346)	0.017
Iopamidol	2.112 (0.256–17.421)	0.488

CI = confidence interval

of ICM administered and the proportion of patients undergoing chemotherapy significantly differed between the two groups ($p = 0.009$ and 0.006 , respectively).

Fasting Duration and Nausea

The preparative dietary protocols at our institution were explained to all 864 pediatric patients. The mean fasting duration of patients who experienced emetic complications and those who did not was 7.9 ± 5.7 hours (range, 3–21 hours) and 8.7 ± 5.7 hours (range, 0–24 hours), respectively. The proportions of patients in each of the five fasting duration groups did not significantly differ between the non-nausea and nausea groups ($p = 0.634$). Additionally, there was no significant difference between the nausea and non-nausea groups with respect to the adequacy of fasting duration ($p = 0.538$) (Table 3).

Identification of Risk Factors for Nausea

In the univariate regression analysis, age ($p = 0.081$),

sedation status ($p = 0.056$), type of nonionic low-osmolality ICM ($p = 0.009$), total dose of ICM ($p = 0.098$), premedication use ($p = 0.057$), and ongoing chemotherapy ($p = 0.006$) had p values less than 0.1 (Table 2).

In the multivariate logistic regression analysis (Table 4), iomeprol use (odds ratio [OR] = 7.219; 95% confidence interval [CI] = 1.442–36.146; $p = 0.016$), iohexol use (OR = 5.241; 95% CI = 1.350–20.346; $p = 0.017$), and ongoing chemotherapy (OR = 4.323; 95% CI = 1.430–13.064; $p = 0.009$) were found to be significantly associated with emetic complications.

DISCUSSION

This study demonstrated that emetic complications, including mild nausea, occurred in approximately 2.1% of children after exposure to low-osmolality ICM. However, severe vomiting was extremely rare (0.22%), and none of the children developed aspiration pneumonia.

No previous study has investigated the incidence of emetic complications in pediatric patients; nevertheless, the incidence reported in this study is within the range previously reported in fasting studies on adult patients (nausea and vomiting, 0.07–2.9%) (3, 9, 15, 16). Given the retrospective nature of this study and the challenges inherent to the evaluation of nausea in young children who are sedated or unable to communicate with medical staff, it is possible that we underestimated the incidence of emetic complications.

In the present study, ongoing chemotherapy showed a significant association with emetic complications in the multivariate logistic regression analysis ($p = 0.009$).

Several studies have identified some chemotherapy agents as risk factors for acute adverse reactions to ICM, but these findings remain controversial. Farolfi et al. (17) reported that patients undergoing taxane-based chemotherapy had a twofold higher risk of acute ICM-related adverse reactions than those not receiving treatment. While the exact pathophysiological mechanism underlying this remains unclear, it has been suggested that some chemotherapy agents may induce hypersensitivity reactions, which are clinically similar to a type 1 allergic reaction (17, 18). In addition, there exists a variation of chemotherapy-induced nausea and vomiting called anticipatory nausea and vomiting, which is defined as a conditioned response to an initial emetic experience following chemotherapy infusion (19, 20). This condition was also reported in children who received antineoplastic drugs, and we assume that this psychological factor played a role in our study. In contrast, Barbosa et al. (9) studied the effects of preparative fasting on contrast-enhanced CT at a cancer center and showed that chemotherapy was not associated with adverse symptoms such as nausea, vomiting, and weakness in adult patients with cancer. Nevertheless, further studies are required to elucidate the relationship between chemotherapy and emetic complications.

In our study, the use of iomeprol and iohexol was associated with nausea and vomiting. In a previous study, the use of iobitridol was associated with a reduced incidence of nausea in adults undergoing CT (3). Our findings are consistent with those of previous studies in which iomeprol use was associated with a higher incidence rate of acute adverse reactions. However, previous studies have reported that the use of iohexol is associated with a lower incidence rate of adverse reactions, which is in contrast to our findings (21, 22). Therefore, the association between ICM type and the risk of emetic complications remains inconclusive due to the lack of randomization of ICM type and lack of adjustment for potential confounders in this study. At our institution, iomeprol was administered to those undergoing CT angiography examinations. We think that the high iodine concentration of iomeprol (400 mgI/mL) and high injection rate required for CT angiography may be responsible for the higher incidence of nausea and vomiting seen in patients administered iomeprol in this study (23). Li et al. (23) reported that a high injection rate (≥ 5 mL/s) was a risk factor for adverse drug reactions in adult patients with underlying diseases and risk factors (those with asthma or cardiac insufficiency and elderly patients). However, in our study, injection rate was not significantly

associated with emetic complications ($p = 0.756$). This may be because all of the patients were children, so a lower dose of ICM was administered, meaning that all injection rates were less than 5 mL/s, even for CT angiography. Moreover, in the nausea group, two out of the three children who were administered iohexol had hemato-oncologic malignancies and were undergoing chemotherapy. Therefore, we believe that the occurrence of nausea in these patients was likely due to the effects of chemotherapy itself. However, further studies are warranted to confirm the high rate of nausea associated with the use of iomeprol and iohexol.

Whether preparative fasting prevents vomiting, remains uncertain. The correlation between preparative fasting before contrast-enhanced CT and the occurrence of complications, including aspiration pneumonia, has not yet been investigated on a large scale. Park et al. (24) studied 122 adult patients who visited the emergency room because of acute abdominal pain and reported that the incidences of nausea, vomiting, and aspiration pneumonia did not significantly differ between patients who did not fast and those who had fasted for longer than 6 hours. Kim et al. (3) studied 1175 adult patients who fasted for 6 hours and reported that only 2.9% of patients experienced mild nausea and none experienced vomiting. Furthermore, they found no significant association between fasting duration and nausea. In contrast, some studies suggested that fasting increased the incidence of emetic complications. Wagner et al. (25) conducted a randomized trial involving 1000 patients and found no significant difference in the incidence of emetic complications between patients who fasted for more than 4 hours before ICM administration and those who did not fast ($p = 0.29$). Although not statistically significant, the incidence of emesis was higher in the fasting group than in the non-fasting group (0.4% vs. 0.0%). Oowaki et al. (26) also showed that the incidence of nausea and vomiting after contrast-enhanced CT was higher in the fasting group than in the non-fasting group. In our study, no significant association was observed between fasting duration and emetic complications.

Several studies on pediatric fasting have focused on areas such as surgery or anesthesia, and fasting before radiologic procedures follows the fasting regimen adopted in these fields (11). The practice guidelines for preoperative fasting in pediatric patients developed by the ASA recommend the same fasting regimen for children and adults, except for the guidelines regarding the intake of breast milk and infant formula. This fasting regimen is as follows: 6 hours for

solids, 4 hours for breast milk, and 2 hours for clear fluids (11, 27). However, several studies have shown that hunger and thirst could pose problems for children, particularly for those awaiting elective procedures; hence, some regimens and institutions have reduced the fasting duration for clear fluids (12, 28, 29). Fasting is more difficult for children because prolonged fasting increases irritability; moreover, neonates and infants have to be fed every 2–4 hours. Increased irritability may result in the acquisition of a nondiagnostic CT image and can lead to sedation being required. Furthermore, infants and young children are particularly vulnerable to hypoglycemia and hypovolemia because of their higher metabolic rate and reduced glycogen stores (30). A previous literature review showed that the ingestion of clear inert fluid less than 1 hour before ICM-enhanced CT examinations rarely induced aspiration (4). Unfortunately, in our study, many children (57.2%) fasted for unnecessarily long periods despite having been instructed on our recommended institutional dietary protocol. Under these circumstances, when instructions for preparative fasting are provided, we recommend that children and parents exercise caution to prevent dehydration and hypoglycemia.

Our study had several limitations. First, we analyzed a heterogeneous population of enrolled patients. Second, minor perceptions of nausea may have been missed in infants and young children who could not express themselves. Moreover, we were unable to evaluate nausea in sedated children. Third, we did not enroll patients who underwent emergency CT. Unfortunately, due to staffing limitations, the study was conducted only during regular working hours. However, the study population exhibited fasting durations ranging from 0 to 24 hours. Therefore, we believe that the association between fasting duration and nausea and vomiting was sufficiently assessed. Fourth, we did not collect data on the exact dose of sedatives administered. Among the patients who experienced nausea, one was sedated using oral sedatives and none received intravenous sedation. Therefore, we were unable to determine the association between nausea and the total dose of sedative drugs administered.

In conclusion, 2.1% of children experienced nausea or vomiting after exposure to low-osmolality ICM. However, no significant relationship was observed between emetic complications and patient characteristics such as sex, age, BMI, sedation status, type of last ingested food, underlying disease, injection rate, volume of ICM administered, premedication use, preexisting gastrointestinal symptoms before CT, and fasting duration. Ongoing chemotherapy and

the use of iomeprol or iohexol were identified as potential risk factors for emetic complications in pediatric patients.

Many children fasted for periods that were far longer than those recommended by our institutional dietary protocol. When pediatric patients are instructed to undergo preparative fasting before a contrast-enhanced CT examination, clinicians should stress the importance of following these guidelines to avoid excessive fasting.

Conflicts of Interest

The authors have no potential conflicts of interest to disclose.

Acknowledgments

The authors would like to thank nurses in radiology department at Seoul National University Children Hospital for their support during the data acquisition process.

ORCID iDs

Ji Young Ha

<https://orcid.org/0000-0001-5769-3045>

Young Hun Choi

<https://orcid.org/0000-0002-1842-9062>

Yeon Jin Cho

<https://orcid.org/0000-0001-9820-3030>

Seunghyun Lee

<https://orcid.org/0000-0003-1858-0640>

Seul Bi Lee

<https://orcid.org/0000-0002-5163-3911>

Gayoung Choi

<https://orcid.org/0000-0002-2004-5228>

Jung-Eun Cheon

<https://orcid.org/0000-0003-1479-2064>

Woo Sun Kim

<https://orcid.org/0000-0003-2184-1311>

REFERENCES

1. Katayama H, Yamaguchi K, Kozuka T, Takashima T, Seez P, Matsuura K. Adverse reactions to ionic and nonionic contrast media. A report from the Japanese Committee on the Safety of Contrast Media. *Radiology* 1990;175:621-628
2. Manhire AR, Dawson P, Dennet R. Contrast agent-induced emesis. *Clin Radiol* 1984;35:369-370
3. Kim YS, Yoon SH, Choi YH, Park CM, Lee W, Goo JM. Nausea and vomiting after exposure to non-ionic contrast media: incidence and risk factors focusing on preparatory fasting. *Br J Radiol* 2018;91:20180107

4. Lee BY, Ok JJ, Abdelaziz Elsayed AA, Kim Y, Han DH. Preparative fasting for contrast-enhanced CT: reconsideration. *Radiology* 2012;263:444-450
5. Bush WH, Swanson DP. Acute reactions to intravascular contrast media: types, risk factors, recognition, and specific treatment. *AJR Am J Roentgenol* 1991;157:1153-1161
6. Cochran ST, Bomyea K, Sayre JW. Trends in adverse events after IV administration of contrast media. *AJR Am J Roentgenol* 2001;176:1385-1388
7. Kim YS, Choi YH, Cho YJ, Lee S, Yoon SH, Park CM, et al. Incidence of breakthrough reaction in patients with prior acute allergic-like reactions to iodinated contrast media according to the administration route. *Korean J Radiol* 2018;19:352-357
8. Han S, Yoon SH, Lee W, Choi YH, Kang DY, Kang HR. Management of adverse reactions to iodinated contrast media for computed tomography in Korean referral hospitals: a survey investigation. *Korean J Radiol* 2019;20:148-157
9. Barbosa PNVP, Bitencourt AGV, Tyng CJ, Cunha R, Travesso DJ, Almeida MFA, et al. Preparative fasting for contrast-enhanced CT in a cancer center: a new approach. *AJR Am J Roentgenol* 2018;210:941-947
10. Practice guidelines for moderate procedural sedation and analgesia 2018: a report by the American Society of Anesthesiologists Task Force on Moderate Procedural Sedation and Analgesia, the American Association of Oral and Maxillofacial Surgeons, American College of Radiology, American Dental Association, American Society of Dentist Anesthesiologists, and Society of Interventional Radiology. *Anesthesiology* 2018;128:437-479
11. Coté CJ, Wilson S. Guidelines for monitoring and management of pediatric patients before, during, and after sedation for diagnostic and therapeutic procedures. *Pediatrics* 2019;143:e20191000
12. Frykholm P, Schindler E, Sumpelmann R, Walker R, Weiss M. Preoperative fasting in children: review of existing guidelines and recent developments. *Br J Anaesth* 2018;120:469-474
13. American College of Radiology (ACR), Society of Interventional Radiology (SIR). ACR-SIR practice guideline for sedation/analgesia. Reston: *American College of Radiology*, 2010
14. Smith I, Kranke P, Murat I, Smith A, O'Sullivan G, Soreide E, et al. Perioperative fasting in adults and children: guidelines from the European Society of Anaesthesiology. *Eur J Anaesthesiol* 2011;28:556-569
15. Li X, Liu H, Zhao L, Liu J, Cai L, Zhang L, et al. The effect of preparative solid food status on the occurrence of nausea, vomiting and aspiration symptoms in enhanced CT examination: prospective observational study. *Br J Radiol* 2018;91:20180198
16. Federle MP, Willis LL, Swanson DP. Ionic versus nonionic contrast media: a prospective study of the effect of rapid bolus injection on nausea and anaphylactoid reactions. *J Comput Assist Tomogr* 1998;22:341-345
17. Farolfi A, Della Luna C, Ragazzini A, Carretta E, Gentili N, Casadei C, et al. Taxanes as a risk factor for acute adverse reactions to iodinated contrast media in cancer patients. *Oncologist* 2014;19:823-828
18. Brandi G, Pantaleo MA, Galli C, Falcone A, Antonuzzo A, Mordenti P, et al. Hypersensitivity reactions related to oxaliplatin (OHP). *Br J Cancer* 2003;89:477-481
19. Kamen C, Tejani MA, Chandwani K, Janelsins M, Peoples AR, Roscoe JA, et al. Anticipatory nausea and vomiting due to chemotherapy. *Eur J Pharmacol* 2014;722:172-179
20. Sherani F, Boston C, Mba N. Latest update on prevention of acute chemotherapy-induced nausea and vomiting in pediatric cancer patients. *Curr Oncol Rep* 2019;21:89
21. Gomi T, Nagamoto M, Hasegawa M, Katoh A, Sugiyama M, Murata N, et al. Are there any differences in acute adverse reactions among five low-osmolar non-ionic iodinated contrast media? *Eur Radiol* 2010;20:1631-1635
22. Kim SR, Lee JH, Park KH, Park HJ, Park JW. Varied incidence of immediate adverse reactions to low-osmolar non-ionic iodide radiocontrast media used in computed tomography. *Clin Exp Allergy* 2017;47:106-112
23. Li X, Liu H, Zhao L, Liu J, Cai L, Liu L, et al. Clinical observation of adverse drug reactions to non-ionic iodinated contrast media in population with underlying diseases and risk factors. *Br J Radiol* 2017;90:20160729
24. Park JH, Rhee JE, Kim KS, Shin JH. Is the six-hour fasting before abdominal computed tomography necessary to prevent gastrointestinal adverse events in patients with abdominal pain? *J Korean Soc Emerg Med* 2008;19:333-338
25. Wagner HJ, Evers JP, Hoppe M, Klose KJ. Must the patient fast before intravascular injection of a non-ionic contrast medium? Results of a controlled study. *RoFo* 1997;166:370-375
26. Oowaki K, Saigusa H, Ojiri H, Ariizumi M, Yamagisi J, Fukuda K, et al. [Relationship between oral food intake and nausea caused by intravenous injection of iodinated contrast material]. *Nihon Igaku Hoshasen Gakkai Zasshi* 1994;54:476-479
27. Neubauer V, Griesmaier E, Baumgartner K, Mallouhi A, Keller M, Kiechl-Kohlendorfer U. Feasibility of cerebral MRI in non-sedated preterm-born infants at term-equivalent age: report of a single centre. *Acta Paediatr* 2011;100:1544-1547
28. Engelhardt T, Wilson G, Horne L, Weiss M, Schmitz A. Are you hungry? Are you thirsty?--fasting times in elective outpatient pediatric patients. *Paediatr Anaesth* 2011;21:964-968
29. Fawcett WJ, Thomas M. Pre-operative fasting in adults and children: clinical practice and guidelines. *Anaesthesia* 2019;74:83-88
30. Dennhardt N, Beck C, Huber D, Sander B, Boehne M, Boethig D, et al. Optimized preoperative fasting times decrease ketone body concentration and stabilize mean arterial blood pressure during induction of anesthesia in children younger than 36 months: a prospective observational cohort study. *Paediatr Anaesth* 2016;26:838-843