



# Mechanical and biological complication rates of the modified lateral-screw-retained implant prosthesis in the posterior region: an alternative to the conventional Implant prosthetic system

Jae-Hong Lee<sup>1</sup>, Jong-Bin Lee<sup>2</sup>, Man-Yong Kim<sup>3</sup>, Joon-Ho Yoon<sup>3</sup>, Seong-Ho Choi<sup>1</sup>, Young-Taek Kim<sup>2\*</sup>

<sup>1</sup>Department of Periodontology, Research Institute for Periodontal Regeneration, College of Dentistry, Yonsei University, Seoul, Republic of Korea

<sup>2</sup>Department of Periodontology, National Health Insurance Service Ilsan Hospital, Goyang, Republic of Korea

<sup>3</sup>Department of Prosthodontics, National Health Insurance Service Ilsan Hospital, Goyang, Republic of Korea

**PURPOSE.** The modified lateral-screw-retained implant prosthesis (LSP) is designed to combine the advantages of screw- and cement-retained implant prostheses. This retrospective study evaluated the mechanical and biological complication rates of implant-supported single crowns (ISSCs) inserted with the modified LSP in the posterior region, and determined how these complication rates are affected by clinical factors. **MATERIALS AND METHODS.** Mechanical complications (i.e., lateral screw loosening [LSL], abutment screw loosening, lateral screw fracture, and ceramic fracture) and biological complications (i.e., peri-implant mucositis [PM] and peri-implantitis) were identified from the patients' treatment records, clinical photographs, periapical radiographs, panoramic radiographs, and clinical indices. The correlations between complication rates and the following clinical factors were determined: gender, age, position in the jaw, placement location, functional duration, clinical crown-to-implant length ratio, crown height space, and the use of a submerged or nonsubmerged placement procedure. **RESULTS.** Mechanical and biological complications were present in 25 of 73 ISSCs with the modified LSP. LSL (n=11) and PM (n=11) were the most common complications. The incidence of mechanical complications was significantly related to gender ( $P=.018$ ). The other clinical factors were not significantly associated with mechanical and biological complication rates. **CONCLUSION.** Within the limitations of this study, the incidence of mechanical and biological complications in the posterior region was similar for both modified LSP and conventional implant prosthetic systems. In addition, the modified LSP is amenable to maintenance care, which facilitates the prevention and treatment of mechanical and biological complications. [*J Adv Prosthodont* 2016;8:150-7]

**KEY WORDS:** Dental implant; Dental prosthesis design; Peri-implantitis; Prosthesis failure; Single-tooth implant

Corresponding author:

Young-Taek Kim  
Department of Periodontology, National Health Insurance Service Ilsan Hospital, 100 Ilsan-ro, Ilsan-donggu, Goyang 10444, Republic of Korea  
Tel. 82 319000625; e-mail, youngtaek77@naver.com  
Received November 8, 2015 / Last Revision December 26, 2015 / Accepted January 12, 2016

© 2016 The Korean Academy of Prosthodontics  
This is an Open Access article distributed under the terms of the Creative Commons Attribution Non-Commercial License (<http://creativecommons.org/licenses/by-nc/3.0>) which permits unrestricted non-commercial use, distribution, and reproduction in any medium, provided the original work is properly cited.

This study was supported by the National Health Insurance Service Ilsan Hospital in 2014.

## INTRODUCTION

Dental implant is widely used in the field of reconstructive dentistry as a predictable treatment modality.<sup>1,2</sup> Implant surfaces and design are continuously being improved; the ideal dental implant system should have a contour similar to that of a natural tooth, be esthetic, and demonstrate strength and long-term durability.<sup>3-5</sup> In addition, the maintenance cost should be low, and the patient should agree that the dental implant is a satisfactory replacement of a missing natural tooth.<sup>6</sup>

Despite their widespread use, biological and mechanical failures of implant-supported fixed dental prostheses

(ISFDPs) and implant-supported single crowns (ISSCs) are still frequent.<sup>7,8</sup> The high survival rate of ISSCs is similar to that of ISFDPs, but mechanical, biological, and esthetic complications occur more frequently with ISSCs.<sup>7</sup> Esthetic complications (e.g., soft-tissue recessions, unfavorable color, and visible crown margins) occur frequently in the anterior region, while mechanical complications (e.g., screw loosening, screw fracture, and fractures of the veneer material) are more frequent in the posterior region.<sup>9</sup>

Various dental implant systems have been studied and developed with the aim of improving the mechanical, biological, and esthetic properties and overcoming the above-mentioned disadvantages.<sup>10</sup> The lateral-screw-retained implant prosthesis (LSP) was designed with a lateral screw access hole replacing an occlusal screw access hole. The implementation of physiologically shaped occlusal surfaces increases the esthetic value of the implant prosthesis and essentially removes any possibility of unfavorable occlusion interference.<sup>6</sup> Removal of the occlusal screw holes can also prevent mechanical complications, in particular screw loosening and loss of the access-hole resin and sealing materials.<sup>11-13</sup> Despite these merits, the experimental and clinical studies of the LSP have been insufficient, and the previous treatments have been empirical only.

The modified LSP was designed to improve on the advantages of the LSP by making it easy to separate the implant prosthesis. The purpose of this structural design is to reduce the rates of mechanical and biological complications and to make the prosthesis easier to retrieve. Easy retrievability facilitates maintenance care, which allows mechanical and biological complications to be treated.

The aim of this study was to determine the mechanical and biological complication rates of ISSCs inserted in the posterior region using the modified LSP, with a focus on the cases that could be followed up after an average of 4 years of loading. The effects of the following clinical factors were also considered: gender, age, position in the jaw, placement location, functional duration, clinical crown-to-implant length ratio (C/I ratio), crown height space (CHS), and the use of a submerged or nonsubmerged placement procedure.

## MATERIALS AND METHODS

This retrospective study evaluated the clinical feasibility of using the modified LSP in the posterior region. The study was approved by the Institutional Review Board of National Health Insurance Service (NHIS) Ilsan Hospital (approval no. #2014-074) and was carried out in the Department of Periodontology and Prosthodontics, NHIS Ilsan Hospital.

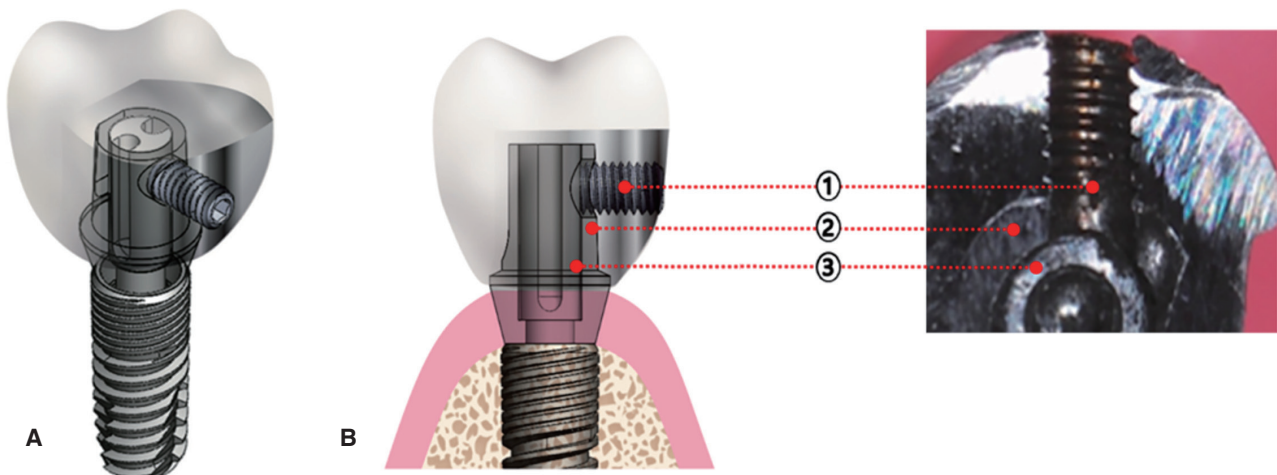
The patients who have been concluded prosthodontic treatments with modified LSPs were reviewed from January 2009 to January 2012. The following inclusion criteria were used: (1) aged 20 to 80 years, (2) good systemic health (including controlled medical or dental diseases), and (3) placement of ISSCs in the posterior region. The following

exclusion criteria were applied: (1) severe systemic disease, (2) advanced or untreated periodontal disease, (3) heavy smoking habit (> 20 cigarettes/day), and (4) severe para-functional activity (heavy clenching or bruxism).

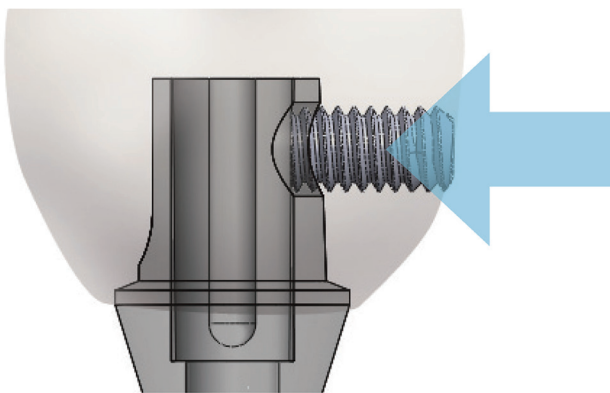
Internal-connection-type implants processed with a resorbable blasting material (RBM) and sandblasted, large-grit, acid-etched surface were placed by a single periodontist. Either one- or two-stage surgery was performed depending on the bone quality and quantity, and all of the procedures, including using a prepared surgical stent, followed the manufacturer's recommended protocol. The final prosthesis (porcelain-fused-to-metal or all-ceramic crown) was attached by a single prosthodontist at least 3 months after the implant fixture had been placed in the ideal prosthesis position. Occlusion was adjusted at the centric relation and eccentric relations to obtain the optimal occlusal contact. After the final setting of the ISSCs with the modified LSP, maintenance care—with a focus on oral hygiene—was provided every 6 months, and an intraoral radiograph was obtained every 12 months using the parallel-cone technique.

The modified LSP (YK Implant Prosthetic System, Dipstek, Seoul, Korea) consists of a lateral screw, an abutment with a lateral hole, an anti-loosening abutment screw, and a crown with a negative screw housing (Fig. 1). The modified LSP has a negative screw housing located within the crown, which provides mechanical locking by pushing against the walls of the abutment. The lateral screw penetrates the abutment and makes direct contact with the abutment screw (Fig. 2). The implant abutment/crown is manually tightened to a torque of 5 - 10 Ncm using a lateral screwdriver with a contra-angle attachment (Fig. 3).

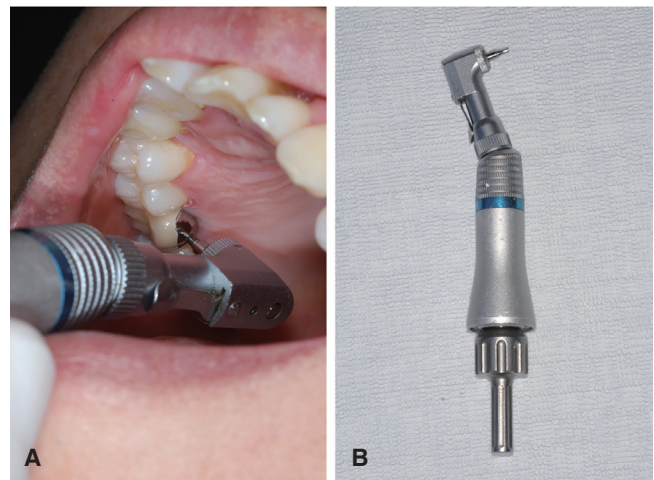
Mechanical complications (i.e., lateral screw loosening [LSL], abutment screw loosening [ASL], lateral screw fracture [LSF], and ceramic fracture [CF]) were identified by examining the patients' treatment records, clinical photographs, and periapical and panoramic radiographs. Biological complications were diagnosed by assessing various clinical and radiographic parameters (probing depth, bleeding on probing, suppuration, mobility, and periapical radiographic bone loss) with the aid of a UNC periodontal probe (Hu-freidy, Chicago, IL, USA). The presence of only reversible inflammatory reactions (e.g., easy bleeding on probing, gingival swelling, or redness) was diagnosed as peri-implant mucositis (PM), while it was diagnosed as peri-implantitis (PI) if these symptoms were accompanied by bone loss (as detected with a periodontal probe and in the periapical radiograph), probing depth > 5 mm, and/or mobility.<sup>14,15</sup> The clinical C/I ratio was measured as the length of the clinical crown (with the fulcrum located at the crestal bone) divided by the length of the implant, while CHS was measured as the length from the crestal bone to the occlusal plane.<sup>16,17</sup> To correct the distortion errors, such as magnification, the clinical C/I ratio, and CHS, were calibrated using the inter-thread distance as a reference on a PACS workstation (Centricity GE Healthcare, Waukesha, WI, USA).



**Fig. 1.** Three-dimensional view (A), cross-sectional view and photograph (B) of the modified lateral-screw-retained implant prosthesis (LSP). The modified LSP consists of a lateral screw, an abutment with a lateral hole, an antiloosening abutment screw, and a crown with a negative screw housing (1, lateral [transverse] screw; 2, abutment; 3, abutment screw).



**Fig. 2.** The modified LSP retains the implant prosthesis by the application of a pushing force onto the abutment (arrow). This system has a negative screw housing located within the crown, which provides mechanical locking by pushing against the walls of the abutment. The lateral screw penetrates the abutment to make direct contact with the abutment screw.



**Fig. 3.** (A) The modified LSP does not involve access-hole resin or sealing materials, and so the occurrence of lateral screw loosening (LSL) can be clinically verified by visually checking the lateral screw access hole. The lateral screw can be tightened if necessary using a lateral screwdriver with a contra-angle attachment. The implant abutment/crown is manually tightened to a torque of 5-10 Ncm. (B) Since the lateral screw is designed for use with a lateral screwdriver and a contra-angle attachment, it is easily managed within the oral cavity.

Statistical analyses were performed with SPSS Statistics software (19 version, SPSS, Chicago, IL, USA), using Student's *t* (two-tailed with independent samples), Fisher's exact, and chi-square tests to identify the relationships

between clinical factors and complication rates. Standard deviation values and 95% confidence intervals were calculated, and the cutoff for statistical significance was set at  $P < .05$ .

## RESULTS

Seventy patients (37 male and 33 female patients) with a mean age of 54.9 years (range: 25 - 77 years) met the inclusion criteria. All of the 73 implants investigated from these patients were the internal-connection type (types: Implantium [n = 60], GS2 [n = 1], GS3 [n = 5], SS2 [n = 7], Dentium and Osstem, Seoul, Korea). Fifty-six implants were placed using a one-stage nonsubmerged procedure without any advanced surgery, while 17 implants were placed using a two-stage submerged procedure.

The implants were distributed in the posterior region as follows: maxillary first premolar, n = 2 (2.7%); second premolar, n = 6 (8.2%); first molar, n = 16 (21.9%); second molar, n = 2 (2.7%); mandibular first premolar, n = 1 (1.4%); first molar, n = 31 (42.5%); and second molar, n = 15 (20.5%).

**Table 1.** Characteristics of the study populations of patients and implants for implant-supported single crowns (ISSCs) with the modified lateral-screw-retained implant prosthesis (LSP)

Patients, n = 70	Value
Gender	
Male	37 (52.9)
Female	33 (47.1)
Age, mean (range)	
20 - 29 years	1 (1.4)
30 - 39 years	6 (8.6)
40 - 49 years	12 (17.1)
50 - 59 years	26 (37.1)
60 - 69 years	20 (28.6)
70 - 79 years	5 (7.1)
Implants, n = 73	
Position	
Maxilla	26 (35.6)
First premolar	2 (2.7)
Second premolar	6 (8.2)
First molar	16 (21.9)
Second molar	2 (2.7)
Mandible	47 (64.4)
First premolar	1 (1.4)
First molar	31 (42.5)
Second molar	15 (20.5)
Duration of functional loading, mean (range)	
Up to 3 years	18 (24.7)
3 - 4 years	30 (41.1)
4 - 5 years	25 (34.2)

Except where stated otherwise, the data are n (%) values.

In total, 26 implants were placed in the maxilla (35.6%) and 47 in the mandible (64.4%). The mean loading period was 43.7 months (range: 31 - 56 months; Table 1).

Mechanical complications were present in 14 (19.8%) of the 73 investigated posterior ISSCs inserted with the modified LSP. LSL was the most common complication (n = 11, 15.1%), followed by ASL (n = 2, 2.7%), LSF (n = 1, 1.4%), and CF (n = 1, 1.4%). LSL and ASL occurred simultaneously in an implant. Biological complications occurred in 11 (15.1%) of the investigated posterior ISSCs. PM (n = 11, 15.1%) and PI (n = 1, 1.4%) were also present, and PM occurred twice in two of the implants (Table 2).

The frequency distributions of the implants according to their positions in the upper and lower jaw are shown in Fig. 4. Complications occurred in 1 (16.7%) of the 6 implants placed in the maxillary second premolar (LSL, n = 1), 8 (50%) of the 16 implants placed in the maxillary first molar (LSL, n = 2; ASL, n = 2; LSF, n = 1; PM, n = 3), 2 (100%) of the 2 implants placed in the maxillary second molar (LSL, n = 1; PM, n = 1), 8 (25.8%) of the 31 implants placed in the mandibular first molar (LSL, n = 4; PM, n = 3; PI, n = 1), and 8 (53.3%) of the 15 implants placed in the mandibular second molar (LSL, n = 3; CF, n = 1; PM, n = 4).

Based on the incidence of mechanical complications relative to the duration of functional loading, 11 (73.3%) of 15 implants exhibited mechanical complications during the first 12 months after undergoing functional loading. The incidence of LSL during the first 12 months was particularly noticeable (n = 9, 60%). ASL occurred after LSL in one case before any repair took place. During the first 12 months, six implants showed PM, with an even distribution of the complications across the duration of functional loading. During the mean follow-up period of 43.7 months, there were no further mechanical complications after 24 months of functional loading (Fig. 5).

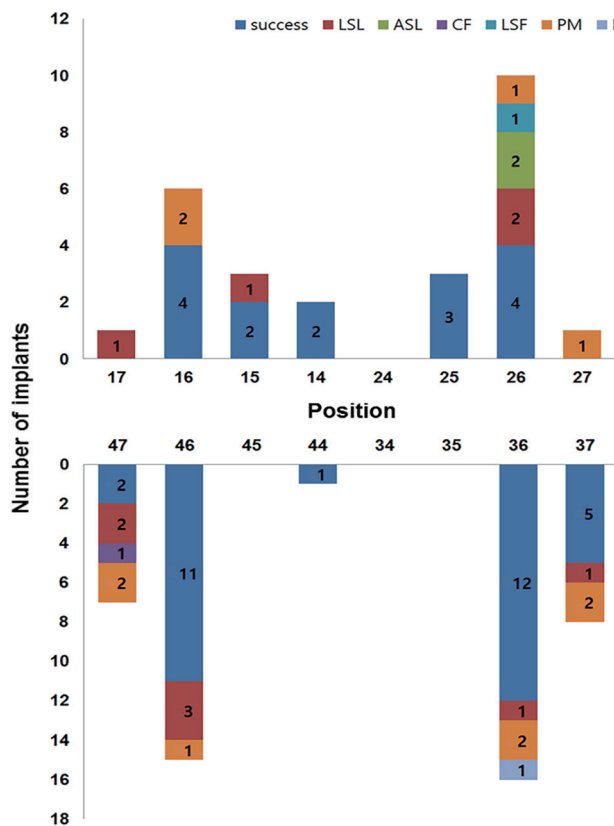
**Table 2.** Mechanical and biological complication rates of the 73 ISSCs with the modified LSP in the posterior region

Complications	n	%
LSL	11*	15.1
ASL	2*	2.7
LSF	1	1.4
CF	1	1.4
PM	11†	15.1
PI	1	1.4

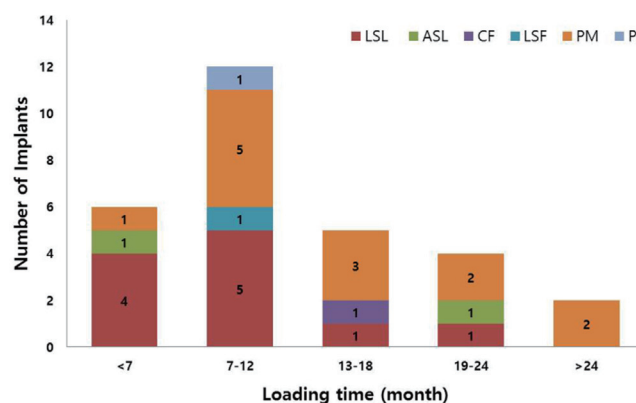
LSL, lateral screw loosening; ASL, abutment screw loosening; LSF, lateral screw fracture; CF, ceramic fracture; PM, peri-implant mucositis; PI, peri-implantitis.

\* LSL and ASL occurred simultaneously in one implant.

† PM occurred twice in each of two of the implants.



**Fig. 4.** Frequency distribution of implants according to their position in the jaw and the complication rates of the implant-supported single crowns (ISSCs) with the modified LSP in the posterior region. ASL, abutment screw loosening; LSF, lateral screw fracture; CF, ceramic fracture; PM, peri-implant mucositis; PI, peri-implantitis.



**Fig. 5.** Incidence of mechanical and biological complications according to the duration of functional loading.

Analyses using the Fisher’s exact, chi-square, and the t-tests indicated that the incidence of mechanical complications was significantly related to gender ( $P = .024$ ). The other clinical factors of age, position in the jaw, placement location (premolars were excluded due to the small size of the sample), functional duration, clinical C/I ratio, CHS, and the use of a submerged or nonsubmerged placement procedure were not significantly associated with the mechanical complication rates. Biological complications showed no statistically significant association with any of the clinical factors (Table 3).

**Table 3.** Mechanical and biological complication rates according to gender, age, position in the jaw, placement location, duration of functional loading, clinical crown-to-implant length ratio (C/I ratio), crown height space (CHS), and use of a submerged (two-stage) placement procedure

Characteristic		Mechanical complication group	Mechanical success group	<i>P</i>	Biological complication group	Biological success group	<i>P</i>
Gender	Male (n)	12	27	.024 <sup>a*</sup>	6	33	.795*
	Female (n)	3	31		6	28	
Age (years)		53.7 ± 9.3	55.2 ± 11.4	.655 <sup>†</sup>	60.1 ± 12.8	53.9 ± 10.4	.075 <sup>†</sup>
Position in the jaw	Maxilla (n)	7	19	.359*	4	22	.857*
	Mandible (n)	8	39		8	39	
Placement location <sup>‡</sup>	First molar (n)	9	38	.495*	7	40	.276*
	Second molar (n)	5	12		5	12	
Functional duration (months)		30.0 ± 8.3	31.6 ± 7.4	.383 <sup>†</sup>	28.2 ± 6.3	32.0 ± 7.6	.076 <sup>†</sup>
Clinical C/I ratio		1.0 ± 0.2	1.0 ± 0.2	.137 <sup>†</sup>	1.0 ± 0.2	1.3 ± 0.2	.385 <sup>†</sup>
CHS (mm)		10.4 ± 1.9	10.5 ± 1.7	.197 <sup>†</sup>	10.2 ± 1.6	10.7 ± 1.7	.375 <sup>†</sup>
Submerged procedure		4	12	.503*	1	16	.180*

Except where stated otherwise, the data are mean ± SD values.

\* Fisher’s exact and chi-square tests, † Student’s t-test (two-tailed with independent samples), ‡ Premolars were excluded due to sample smallness, a Statistically significant difference ( $P < .05$ ).

## DISCUSSION

The present study found that the modified LSP was similar to the conventional implant prosthetic system. A systematic review found that the cumulative 5-year complication rates of CF and screw fracture were 7.8% and 1.3%, respectively.<sup>8</sup> Kreissl *et al.*<sup>18</sup> reported a similar rate of CF (5.7%) over an observation period of 5 years. In the present study, the mean of 4-year cumulative incidence rate was 1.3% for both CF and LSF (CF,  $n = 1$ ; LSF,  $n = 1$ ).

Many studies have indicated that screw loosening is a major mechanical complication of ISSCs.<sup>8,19</sup> The occurrence rates of ASL have been reported to range from 2.4% to 37.7%, and a maximum occurrence rate of 22.2% has been reported for occlusal screw loosening (OSL).<sup>8-11</sup> Among the cases studied in the present study, 11 (15.1%) showed LSL and 2 (2.7%) showed ASL, including a case in which ASL accompanied LSL. The occurrence rate of LSL was similar to or lower than that of OSL, while the occurrence rate of ASL was significantly lower.<sup>19,20</sup> Screw loosening results in non-ideal occlusion and is the main cause of mechanical complications such as screw fracture of ISSCs placed in the posterior region.<sup>21</sup> When mild LSL is detected during routine follow-up, a screwdriver with a contra-angle attachment can be used to tighten the lateral screw, with the occlusal contact also being re-evaluated and adjusted. This intervention results in the modified LSP being effective in reducing the occurrence of serious mechanical complications, such as screw or ceramic fracture. Mechanical complications are most likely to take place within 2 years after functional loading (in contrast to biological complications),<sup>22</sup> and therefore our data are considered to be meaningful although longer, more-detailed prospective and larger controlled studies may be needed.

Structural defects in the implant prosthesis cause clinical problems such as food impaction and cement retention that make it difficult to maintain oral hygiene, and this problem in turn causes biological complications, lowering the survival and success rates of the implants.<sup>23</sup> A recent study found that the presence of excess cement in cement-retained implant prostheses was one of the main causes of peri-implant disease.<sup>24</sup> Wilson reported that excess cement caused peri-implant disease in 81% of cases of a cement-retained implant prosthesis.<sup>25</sup> Among biological complications, PM reportedly occurred in 80% of patients and 50% of implants, while PI occurred in 20 - 56% of patients and 10 - 43% of implants.<sup>26</sup> The present study found that biological complications occurred in 11 implants (15.1%) during recall checks, and no patient complained of discomfort. Nonsurgical mechanical debridement was carried out for the 10 implants (13.7%) with PM,<sup>27</sup> while regenerative surgical therapy was carried out for the PI that occurred in 1 implant (1.4%). After the treatments, the implant prosthesis was regularly separated to allow meticulous scaling and professional care during periodic recall checks.<sup>15,28</sup>

The modified LSP allows easy separation of the prosthesis and provides an environment for easy access when

PM or PI occurs, which facilitates effective peri-implant treatment. When cleaning and caring for the peri-implant mucosa, a wound is formed in the connective tissue while the screw-cement-retained prosthesis is disconnected and subsequently reconnected, causing marginal bone resorption and recession.<sup>29</sup> However, in the modified LSP, recession of the mucosa can be prevented by disconnecting only the crown—and not the abutment—when treating any inflammation present in the marginal gingiva and connective tissue, thereby enhancing gingival health.<sup>30</sup>

An analysis of correlations among observed clinical variables in ISSCs with the modified LSP revealed that gender was the only variable that was significantly related to the occurrence of mechanical complications ( $P = .024$ ); this may be because the biting force and occlusal contact area are greater in male subjects.<sup>31,32</sup> It has been reported that an unfavorable C/I ratio (anatomical and/or clinical C/I ratio of  $\geq 2$ ) does not affect the rate of biomechanical complications associated with implants, while an unfavorable CHS value ( $\geq 15$  mm) does affect the rate of prosthesis complications.<sup>33-36</sup> The present study found that the clinical C/I ratio and CHS were not significantly associated with mechanical and biological complication rates. Since both values fell within the favorable range, they were not considered to affect the incidence of complications. The possibility of mechanical complications increases with the horizontal distance between the most distally positioned ISSCs and the mesially adjacent natural tooth.<sup>37</sup> The present study investigated the 35 most distally positioned ISSCs, and the rate of mechanical complications was found to not vary significantly with horizontal distance ( $P = .099$ ).

The present study found that the incidence of mechanical and biological complications in the posterior region of modified LSP was similar to that of the conventional implant prosthetic system. Despite the considerable differences between the modified LSP and conventional implant system in terms of mechanical and physical aspects, the fact that we did not include a finite element method (FEM) analysis can be considered a limitation of this study. A previous study that performed FEM analysis between cement-retained dental implants and screw-retained dental implants showed that screw-retained implants had low dissipation of overload energy and mechanical stress, which is likely to have resulted in weak-linked components.<sup>38,39</sup> Therefore, an appropriately designed FEM using a modified LSP should be carried out precisely to investigate the dissipation and distribution of mechanical tension and stress among fixture, lateral screw, and prosthetic components.

A long-term study of prosthesis survival and complication rates of ISSCs found that 66% of patients experienced at least one complication.<sup>40</sup> The present study focused on the treatment outcomes of ISSCs inserted with the modified LSP in the posterior region, and in particular the rate of mechanical and biological complications. ISSCs with the modified LSP were found to be clinically acceptable and effective in preventing and treating these complications.

Although the modified LSP structurally compensates for the considerable drawbacks of the conventional prosthetic system, structural constraints associated with using an additional negative screw housing cause overcontouring and restrict the design of the implant prosthesis. In addition, there have been no reports of accumulated long-term success rates, so future studies should perform long-term observations with a larger number of cases, including the anterior region and ISFDPs.

## CONCLUSION

Within the limitations of this study, the mechanical and biological complication rates for ISSCs inserted with the modified LSP were found to be similar to those of conventional implant prosthetic systems. In addition, the modified LSP is amenable to maintenance care, which facilitates the prevention and treatment of mechanical and biological complications.

## ORCID

Jae-Hong Lee <http://orcid.org/0000-0002-2375-0141>

Jong-Bin Lee <http://orcid.org/0000-0002-6800-4337>

Man-Yong Kim <http://orcid.org/0000-0002-8959-935X>

Joon-Ho Yoon <http://orcid.org/0000-0002-4571-7342>

Seong-Ho Choi <http://orcid.org/0000-0001-6704-6124>

Young-Taek Kim <http://orcid.org/0000-0002-5132-5783>

## REFERENCES

- Kotsovilis S, Fourmoussis I, Karoussis IK, Bamia C. A systematic review and meta-analysis on the effect of implant length on the survival of rough-surface dental implants. *J Periodontol* 2009;80:1700-18.
- Moraschini V, Velloso G, Luz D, Barboza EP. Implant survival rates, marginal bone level changes, and complications in full-mouth rehabilitation with flapless computer-guided surgery: a systematic review and meta-analysis. *Int J Oral Maxillofac Surg* 2015;44:892-901.
- Wöhrle PS. Nobel Perfect esthetic scalloped implant: rationale for a new design. *Clin Implant Dent Relat Res* 2003;5:64-73.
- Choquet V, Hermans M, Adriaenssens P, Daelemans P, Tarnow DP, Malevez C. Clinical and radiographic evaluation of the papilla level adjacent to single-tooth dental implants. A retrospective study in the maxillary anterior region. *J Periodontol* 2001;72:1364-71.
- Funato A, Salama MA, Ishikawa T, Garber DA, Salama H. Timing, positioning, and sequential staging in esthetic implant therapy: a four-dimensional perspective. *Int J Periodontics Restorative Dent* 2007;27:313-23.
- Weigl P. New prosthetic restorative features of Ankylos implant system. *J Oral Implantol* 2004;30:178-88.
- Jung RE, Pjetursson BE, Glauser R, Zembic A, Zwahlen M, Lang NP. A systematic review of the 5-year survival and complication rates of implant-supported single crowns. *Clin Oral Implants Res* 2008;19:119-30.
- Jung RE, Zembic A, Pjetursson BE, Zwahlen M, Thoma DS. Systematic review of the survival rate and the incidence of biological, technical, and aesthetic complications of single crowns on implants reported in longitudinal studies with a mean follow-up of 5 years. *Clin Oral Implants Res* 2012;23:2-21.
- Pjetursson BE, Brägger U, Lang NP, Zwahlen M. Comparison of survival and complication rates of tooth-supported fixed dental prostheses (FDPs) and implant-supported FDPs and single crowns (SCs). *Clin Oral Implants Res* 2007;18:97-113.
- Hermanides L. Criteria to manage the technical and biologic success of an implant abutment. *Compend Contin Educ Dent* 2014;35:463-8.
- Pjetursson BE, Tan K, Lang NP, Brägger U, Egger M, Zwahlen M. A systematic review of the survival and complication rates of fixed partial dentures (FPDs) after an observation period of at least 5 years. *Clin Oral Implants Res* 2004;15:667-76.
- Linkevicius T, Vladimirovas E, Grybauskas S, Puisys A, Rutkunas V. Veneer fracture in implant-supported metal-ceramic restorations. Part I: Overall success rate and impact of occlusal guidance. *Stomatologija* 2008;10:133-9.
- Karl M, Graef F, Wichmann MG, Heckmann SM. The effect of load cycling on metal ceramic screw-retained implant restorations with unrestored and restored screw access holes. *J Prosthet Dent* 2008;99:19-24.
- Mombelli A, Lang NP. The diagnosis and treatment of peri-implantitis. *Periodontol* 2000 1998;17:63-76.
- Klinge B, Meyle J. Working Group 2. Peri-implant tissue destruction. The Third EAO Consensus Conference 2012. *Clin Oral Implants Res* 2012;23:108-10.
- Misch CE, Goodacre CJ, Finley JM, Misch CM, Marinbach M, Dabrowsky T, English CE, Kois JC, Cronin RJ Jr. Consensus conference panel report: crown-height space guidelines for implant dentistry-part 1. *Implant Dent* 2005;14:312-8.
- Blanes RJ, Bernard JP, Blanes ZM, Belser UC. A 10-year prospective study of ITI dental implants placed in the posterior region. I: Clinical and radiographic results. *Clin Oral Implants Res* 2007;18:699-706.
- Kreissl ME, Gerds T, Muche R, Heydecke G, Strub JR. Technical complications of implant-supported fixed partial dentures in partially edentulous cases after an average observation period of 5 years. *Clin Oral Implants Res* 2007;18:720-6.
- Theoharidou A, Petridis HP, Tzannas K, Garefis P. Abutment screw loosening in single-implant restorations: a systematic review. *Int J Oral Maxillofac Implants* 2008;23:681-90.
- Cha HS, Kim YS, Jeon JH, Lee JH. Cumulative survival rate and complication rates of single-tooth implant; focused on the coronal fracture of fixture in the internal connection implant. *J Oral Rehabil* 2013;40:595-602.
- Morneburg TR, Pröschel PA. In vivo forces on implants influenced by occlusal scheme and food consistency. *Int J Prosthodont* 2003;16:481-6.

22. Simonis P, Dufour T, Tenenbaum H. Long-term implant survival and success: a 10-16-year follow-up of non-submerged dental implants. *Clin Oral Implants Res* 2010;21:772-7.
23. Bidra AS. Nonsurgical management of inflammatory peri-implant disease caused by food impaction: a clinical report. *J Prosthet Dent* 2014;111:96-100.
24. Korsch M, Robra BP, Walther W. Predictors of excess cement and tissue response to fixed implant-supported dentures after cementation. *Clin Implant Dent Relat Res* 2015; 17:e45-53.
25. Wilson TG Jr. The positive relationship between excess cement and peri-implant disease: a prospective clinical endoscopic study. *J Periodontol* 2009;80:1388-92.
26. Lindhe J, Meyle J. Group D of European Workshop on Periodontology. Peri-implant diseases: Consensus Report of the Sixth European Workshop on Periodontology. *J Clin Periodontol* 2008;35:282-5.
27. Heitz-Mayfield LJ, Salvi GE, Botticelli D, Mombelli A, Faddy M, Lang NP; Implant Complication Research Group. Anti-infective treatment of peri-implant mucositis: a randomised controlled clinical trial. *Clin Oral Implants Res* 2011;22:237-41.
28. Heitz-Mayfield LJ, Salvi GE, Mombelli A, Faddy M, Lang NP. Implant Complication Research Group. Anti-infective surgical therapy of peri-implantitis. A 12-month prospective clinical study. *Clin Oral Implants Res* 2012;23:205-10.
29. Abrahamsson I, Berglundh T, Lindhe J. The mucosal barrier following abutment dis/reconnection. An experimental study in dogs. *J Clin Periodontol* 1997;24:568-72.
30. Biancu S, Ericsson I, Lindhe J. Periodontal ligament tissue reactions to trauma and gingival inflammation. An experimental study in the beagle dog. *J Clin Periodontol* 1995;22:772-9.
31. Miyaura K, Matsuka Y, Morita M, Yamashita A, Watanabe T. Comparison of biting forces in different age and sex groups: a study of biting efficiency with mobile and non-mobile teeth. *J Oral Rehabil* 1999;26:223-7.
32. Ferrario VF, Sforza C, Serrao G, Dellavia C, Tartaglia GM. Single tooth bite forces in healthy young adults. *J Oral Rehabil* 2004;31:18-22.
33. Rangert BR, Sullivan RM, Jemt TM. Load factor control for implants in the posterior partially edentulous segment. *Int J Oral Maxillofac Implants* 1997;12:360-70.
34. Nissan J, Ghelfan O, Gross O, Priel I, Gross M, Chaushu G. The effect of crown/implant ratio and crown height space on stress distribution in unsplinted implant supporting restorations. *J Oral Maxillofac Surg* 2011;69:1934-9.
35. Esposito M, Ekkestubbe A, Gröndahl K. Radiological evaluation of marginal bone loss at tooth surfaces facing single Brånemark implants. *Clin Oral Implants Res* 1993;4:151-7.
36. Tarnow D, Elian N, Fletcher P, Froum S, Magner A, Cho SC, Salama M, Salama H, Garber DA. Vertical distance from the crest of bone to the height of the interproximal papilla between adjacent implants. *J Periodontol* 2003;74:1785-8.
37. Lee JH, Lee JB, Park JI, Choi SH, Kim YT. Mechanical complication rates and optimal horizontal distance of the most distally positioned implant-supported single crowns in the posterior region: a study with a mean follow-up of 3 years. *J Prosthodont* 2015;24:517-24.
38. Ciccù M, Beretta M, Risitano G, Maiorana C. Cemented-retained vs screw-retained implant restorations: an investigation on 1939 dental implants. *Minerva Stomatol* 2008;57:167-79.
39. Ciccù M, Bramanti E, Matakana G, Guglielmino E, Risitano G. FEM evaluation of cemented-retained versus screw-retained dental implant single-tooth crown prosthesis. *Int J Clin Exp Med* 2014;7:817-25.
40. Dierens M, De Bruyn H, Kisch J, Nilner K, Cosyn J, Vandeweghe S. Prosthetic Survival and Complication Rate of Single Implant Treatment in the Periodontally Healthy Patient after 16 to 22 Years of Follow-Up. *Clin Implant Dent Relat Res* 2014 Sep 5.