

Multimodality Radiological Pictorial Review of Testicular Carcinoma: From Initial Staging to Restaging

This article was published in the following Dove Press journal:
Research and Reports in Urology

Jonathan W Revels ¹
Sherry S Wang²
Kiran Gangadhar³
Arafat Ali⁴
Al-Amin Ali⁵
Jean H Lee³

¹Department of Radiology, University of New Mexico, Albuquerque, NM, USA; ²Department of Radiology and Imaging Sciences, University of Utah, Salt Lake, UT, USA; ³Department of Radiology, University of Washington Medical Center, Seattle, WA, USA; ⁴Department of Radiology, University of Cincinnati Medical Center, Cincinnati, OH, USA; ⁵Department of Literature, Science, and Arts, University of Michigan, Ann Arbor, MI, USA

Abstract: With an overall 5-year survival rate >95%, patients with testicular cancer have a great prognosis. Although initial diagnosis is based on clinical examination, imaging does play a significant role in the diagnosis and prognosis of testicular cancer, which are dependent on tumor burden and staging. Successful treatment requires appropriate disease assessment throughout a patient's treatment: evaluating treatment response, restaging, and monitoring for disease recurrence after treatment completion. Ultrasound is usually the initial screening modality for painless testicular masses, and computed tomography (CT) the most commonly used for staging and restaging. However, with regard to seminomas, positron-emission tomography (PET) combined with CT is slowly taking priority. With regard to nonseminomatous germ-cell tumors, PET-CT has not proven to be completely effective, due to a high number of false-negative results. The purpose of this paper is to provide radiologists with a pictorial review of testicular carcinoma from initial staging through posttreatment follow-up.

Keywords: testicular, oncology, computed tomography, positron-emission tomography

Introduction

Testicular cancer is the most common tumor among young adult males, and accounts for 8.2% of all cancer in men aged 15–39 years.^{1,2} In 2017, a National Cancer Institute Physician Data Query cancer-information summary about testicular cancer reported the incidence of new cases to be 8,850, and the lifetime risk of developing testicular cancer is a reported 0.4%.^{3,4} Risk factors for testicular cancer include cryptorchidism (Figure 1), family or personal history of testicular cancer, ethnicity, infertility, testicular dysgenesis, and prenatal exposure.^{5,6} Such factors as marijuana exposure, vasectomy, trauma, mumps, and HIV infection continue to be investigated. With the advent of improved management, survival and life expectancy of patients with testicular cancer is quite good, with reported life expectancy nearly equal to those without a diagnosis of testicular cancer.⁴ Particularly, survival rates for testicular germ-cell tumors (GCTs) are nearly 100% for seminomas and 91% for nonseminomas.^{4,7}

Pathologically, GCTs are broadly divided into seminomas, which resemble primordial GCs, and nonseminomas, which are either undifferentiated or differentiated, exhibiting a degree of embryonic or extraembryonic patterning (including yolk-sac tumors, teratomas, embryonal cell tumors, and choriocarcinoma). Testicular cancer is

Correspondence: Jonathan W Revels
Email revels.do@gmail.com

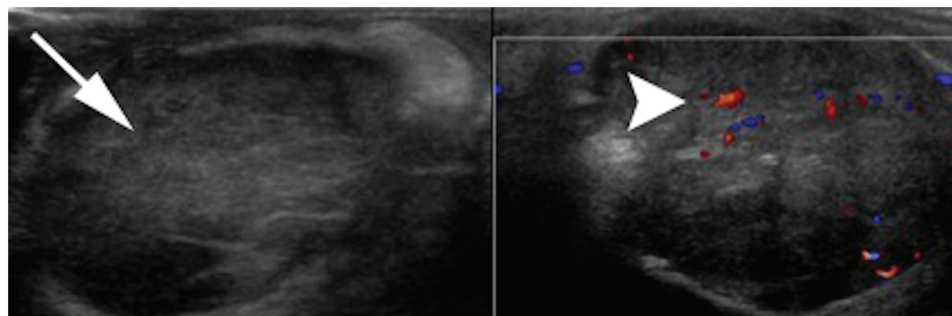


Figure 1 Testicular mass in cryptorchid testis: homogeneous diffuse intratesticular mass lesion with surrounding internal vascularity.

classified as per the 2016 World Health Organization (WHO) guidelines (Table 1).⁸ A complete description of the pathogenesis of testicular tumors is beyond the scope of this radiological review. Rather, the purpose of this manuscript

is to provide an updated overview of the staging of testicular cancer with an emphasis on the radiological perspective.

Diagnosis

Although clinical history and examination of testicular masses remain the cornerstone of diagnosis, imaging using ultrasound (US) examination of the scrotum plays a crucial role in initial diagnosis of tumors. Testicular sonography is also helpful in assessing patients presenting with metastatic disease in whom an occult primary tumor of the testis is suspected or for synchronous tumors in the contralateral testis.^{8,9} Heller et al observed an eightfold-increased prevalence of primary testicular neoplasms in patients with microlithiasis over those without, as well as an increased prevalence of GCTs, particularly pure seminomas (Figure 2).¹⁰ However, US follow-up is of questionable significance, and some studies have clearly expressed doubts that follow-up US screening for patients with testicular microlithiasis would substantially change outcomes.¹¹

Table 1 WHO Histological Classification of Testis Tumors

<p>Germ-cell tumors</p> <ul style="list-style-type: none"> • Intratubular germ-cell neoplasia, unclassified (IGCNU) • Seminoma (including cases with syncytiotrophoblastic cells) • Spermatocytic seminoma (mention if there is sarcomatous component) • Embryonal carcinoma • Yolk-sac tumor • Choriocarcinoma • Teratoma (mature, immature, with malignant component) • Tumors with more than one histological type (specify percentage of individual components)
<p>Sex-cord/gonadal stromal tumors</p> <ul style="list-style-type: none"> • Leydig-cell tumor • Malignant Leydig-cell tumor • Sertoli-cell tumor <ul style="list-style-type: none"> - lipid-rich variant - sclerosing - large-cell calcifying • Malignant Sertoli-cell tumor • Granulosa cell tumor <ul style="list-style-type: none"> - adult type - juvenile type • Thecoma/fibroma group of tumors • Other sex-cord/gonadal stromal tumors <ul style="list-style-type: none"> - incompletely differentiated - mixed • Tumors containing germ-cell and sex cord/gonadal stromal tumors (gonadoblastoma)
<p>Miscellaneous aspecific stromal tumors</p> <ul style="list-style-type: none"> • Ovarian epithelial tumors • Tumors of the collecting ducts and rete testis • Tumors (benign and malignant) of aspecific stroma

Note: Reproduced with permission from Williamson SR, Delahunt B, Magi-Galluzzi C, Algaba F, Egevad L, Ulbright TM, et al. The World Health Organization 2016 classification of testicular germ cell tumours: a review and update from the International Society of Urological Pathology Testis Consultation Panel. *Histopathology*. 2017;70(3):335-46. Copyright 2017, John Wiley and Sons.⁸

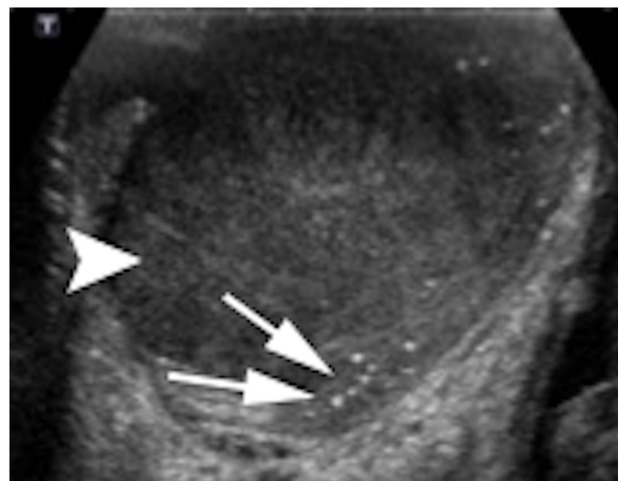


Figure 2 Testicular mass in the background of microlithiasis: homogeneous large oval hypoechoic intratesticular mass lesion with surrounding microlithiasis.

Table 2 Recommended Initial Serological and Radiological Examinations for Staging of Testicular Cancer

Test	Recommendation	Grade
Serum tumor markers	α -fetoprotein β hCG LDH	A
Abdominopelvic CT scan	All patients	A
Chest CT scan	All patients	A
Testis ultrasound (bilateral)	All patients	A
MRI	When abdominal CT is inconclusive	
Bone scan	In case of symptoms	
Brain scan (CT/MRI)	In cases of symptoms and patients with metastasis	
Further investigations Fertility investigations: Total testosterone LH FSH Semen analysis		B
Sperm banking should be offered		A

Note: Reproduced with permission from Albers P, Albrecht W, Algaba F, et al. EAU guidelines on testicularcancer: 2011 update. *Actas Urol Esp.* 2012;36:127–145. Copyright 2012, Elsevier.⁵⁸

Magnetic resonance imaging (MRI) may be a valuable problem-solving modality for the morphological evaluation and characterization of scrotal masses in patients with inconclusive and inconsistent sonographic features, and may improve differentiation between intratesticular and extratesticular masses.¹² Dynamic contrast-enhanced subtraction MRI may be used to differentiate benign from malignant intratesticular mass lesions by analyzing contrast enhancement.¹³ At present, the role of positron-emission tomography (PET) is limited in the initial evaluation of testicular tumors. Current testicular cancer–staging algorithms rely primarily on anatomic features of primary and metastatic disease (eg, enlarged lymph nodes, pulmonary nodules, bone lesions), as opposed to the functional information provided by PET. A few studies have demonstrated a potential benefit of PET to alter a patient’s initial testicular cancer staging — upstage or downstage — which could mean that one day this modality will have a more active role in initial staging.¹⁴

Initial Tumor–Node–Metastasis Staging and Serology

The diagnosis of testicular cancer is commonly based on histopathology after radical orchiectomy. Use of noninvasive

imaging allows for clinical staging of testicular cancer before orchiectomy (Table 2). Staging is crucial, as the treatment approach is based on the staging/clinical classification of the malignancy.¹⁵ Serum tumor markers can assist in appropriate diagnosis, most notably a histopathologically reported pure seminoma in the presence of elevated serum AFP: as AFP should not be elevated in a pure seminoma, the diagnosis is more likely a nonseminomatous GCT with at least some component of yolk-sac tumor. In addition to tumor markers, staging also involves assessment of metastatic disease: nodal and distant metastatic sites, including the chest, abdomen, and pelvis. With normal tumor markers and no evidence of metastases on imaging, patients are classified as having clinical stage I disease. Bone and brain metastatic evaluation are considered if related symptoms are present.¹⁶ TNM international classification criteria are used for staging of the tumor.^{17,18} Using TNM classification (Tables 3 and 4), patients can be staged based on the AJCC classification (Tables 5 and 6).¹⁹ AJCC classification is often used to determine prognosis and patient survival, which is also provided by the International Germ Cell Cancer Collaborative Group classification (Table 7).²⁰

Tumor Staging (T Stage)

In sum, 70%–80% will present with disease confined to the testis (stage I). The primary imaging modality is US scanning of the scrotum, which has sensitivity approaching 100% in experienced hands. Recently, use of US elastography in providing additional information to differentiate between malignant and benign lesions has been evaluated by many studies.²¹ However, this technique can only be complementary to conventional US, but not an imaging modality of choice, because of overlapping imaging findings in lesions <10 mm in size. The majority (>95%) of intratesticular lesions are malignant, typically present as a painless mass, and usually result in orchiectomy.²²

On US, seminomas are typically round, homogeneous, hypoechoic tumors with increased vascularity compared to background testicular parenchyma (Figure 3). In certain cases, seminoma can replace testicular parenchyma, which can make it difficult to differentiate from other infiltrative masses of the testis, such as leukemia and lymphoma. This appearance is in contrast to the heterogeneity of nonseminomatous GCTs (NSGCTs) related to hemorrhage and necrosis with cystic degeneration and calcifications (Figure 4).^{23,24} Two factors associated with poor prognosis include rete-testis invasion and tumors ≥ 4 cm.²⁵ Color Doppler US may be helpful in prepubertal boys when the

Table 3 TNM classification (AJCC eighth edition, 2017)

Clinical T (cT)	
cT category	cT Criteria
cTX	Primary tumor cannot be assessed
cT0	No evidence of primary tumor
cTis	Germ-cell neoplasia in situ
cT4	Tumor invades scrotum with or without vascular/lymphatic invasion
Pathological T (pT)	
pT category	pT Criteria
pTX	Primary tumor cannot be assessed
pT0	No evidence of primary tumor
pTis	Germ-cell neoplasia in situ
pT1	Tumor limited to testis (including rete testis invasion) without lymphovascular invasion
pT1a (subclassification applies only to pure seminoma)	Tumor <3 cm
pT1b (subclassification applies only to pure seminoma)	Tumor 3 cm or larger
pT2	Tumor limited to testis (including rete testis invasion) with lymphovascular invasion OR Tumor invading hilar soft tissue, epididymis, or penetrating visceral mesothelial layer covering the external surface of tunica albuginea with or without lymphovascular invasion
pT3	Tumor directly invades spermatic cord soft tissue with or without lymphovascular invasion
pT4	Tumor invades scrotum with or without lymphovascular invasion
Regional lymph nodes —clinical N (cN)	
cNX	Regional lymph nodes cannot be assessed
cN0	No regional lymph-node metastasis
cN1	Metastasis with a lymph node mass 2 cm or smaller in greatest dimension OR Multiple lymph nodes, none >2 cm in greatest dimension
cN2	Metastasis with lymph-node mass >2 cm but not >5 cm in greatest dimension OR Multiple lymph nodes, any >2 cm but not >5 cm in greatest dimension
cN3	Metastasis with a lymph node >5 cm in greatest dimension

(Continued)

Table 3 (Continued).

Pathological N (pN)	
pNX	Regional lymph nodes cannot be assessed
pN0	No regional lymph-node metastasis
pN1	Metastasis with a lymph node 2 cm or less in greatest dimension and five or fewer positive nodes, none >2 cm in greatest dimension
pN2	Metastasis with a lymph node >2 cm but not >5 cm in greatest dimension OR More than five nodes positive, none >5 cm OR Evidence of extranodal extension of tumor
pN3	Metastasis with a lymph node >5 cm in greatest dimension
Distant metastasis	
MX	Distant metastasis cannot be assessed
M0	No distant metastasis
M1	Distant metastasis
M1a	Nonregional lymph node(s) or lung
M1b	Other sites

Note: Used with permission of the American College of Surgeons, Chicago, Illinois. The original source for this information is the AJCC Cancer Staging Manual, Eighth Edition (2017) published by Springer International Publishing.¹⁹

gray-scale findings of the mass are subtle, and may help identify an isoechoic mass.²⁶ US elastography typically demonstrates increased parenchymal “stiffness”; however, the role of US elastography is still questionable in characterization of testicular lesions.²⁷ Difficulties may arise in differentiating orchitis from tumors and in establishing definitive diagnoses for small lesions on regular US. Usually, surgical exploration through the groin and open biopsy of the testis using the Chevassu technique along with intraoperative US localization is necessary to diagnose and stage the tumor appropriately.

Table 4 TNM Classification for Testicular Cancer Per Serum Testicular Tumor–Marker Level

S stage	LDH (U/l)	hCG (mIU/mL)	AFP (ng/mL)
Sx	Not available	Not available	Not available
S0	Normal	Normal	Normal
S1	S1 <1.5 × normal	<5,000	<1,000
S2	1.5–10 × normal	5,000–50,000	1,000–10,000
S3	>10 × normal	>50,000	>10,000

Note: Used with permission of the American College of Surgeons, Chicago, Illinois. The original source for this information is the AJCC Cancer Staging Manual, Eighth Edition (2017) published by Springer International Publishing.¹⁹

Table 5 Stage Groupings of Testicular Germ-Cell Tumors

	TNM classification
Stage I	pT1–4, N0, M0, SX
Stage II	Any pT/Tx, N1–3, M0, SX
IIA	Any pT/Tx, N1, M0, S0
IIB	Any pT/Tx, N1, M0, S1
IIC	Any pT/Tx, N2, M0, S0 Any pT/Tx, N2, M0, S1 Any pT/Tx, N3, M0, S0 Any pT/Tx, N3, M0, S1
Stage III	Any pT/Tx, any N, M1, SX
IIIA	Any pT/Tx, any N, M1a, S0
IIIB	Any pT/Tx, any N, M1a, S1
IIIC	Any pT/Tx, N1–3, M0, S2 Any pT/Tx, any N, M1a, S2 Any pT/Tx, N1–3, M0, S3 Any pT/Tx, any N, M1a, S3 Any pT/Tx, any N, M1b, any S

Note: Used with permission of the American College of Surgeons, Chicago, Illinois. The original source for this information is the AJCC Cancer Staging Manual, Eighth Edition (2017) published by Springer International Publishing.¹⁹

Table 6 AJCC Staging classification

Stage I	Tumor limited to the testis (normal CT and markers)
Stage I serological	Tumor limited to the testis with persistence of elevated markers
Stage II	Regional lymph-node spread, but not to distant lymph nodes or distant organs
Stage IIA	Regional lymph node measures <2 cm; if surgical lymph-node dissection has been performed, no more than five lymph nodes are positive for cancer
Stage IIB	Regional lymph node measures 2–5 cm; if surgical lymph-node dissection has been performed, no more than five lymph nodes are positive for cancer
Stage IIC	Regional lymph node measures >5 cm
Stage III	Supradiaphragmatic lymph-node, pulmonary, or other visceral involvement

Note: Used with permission of the American College of Surgeons, Chicago, Illinois. The original source for this information is the AJCC Cancer Staging Manual, Eighth Edition (2017) published by Springer International Publishing.¹⁹

MRI is an efficient diagnostic tool for the evaluation of testicular masses. It is accurate in the preoperative differentiation of benign and malignant intratesticular masses. MRI of the testes seems to be more efficient than US for detecting local extent of the tumor: involvement of the tunica albuginea, epididymis, and spermatic cord.²⁸ MRI may also be helpful in differentiating seminomas from NSGCTs, showing

Table 7 Prognostic-Based Staging System for Metastatic Germ-Cell Cancer

Good-Prognosis Group
Nonseminomas (56% of cases): all the following criteria 5-year PFS 89%, testis/retroperitoneal primary 5-year survival 92%, no nonpulmonary visceral metastases AFP <1,000 ng/mL hCG <5,000 IU/l (1,000 ng/mL) LDH <1.5 ULN
Seminomas (90% of cases): all the following criteria 5-year PFS 82%, any primary site 5-year survival 86%, no nonpulmonary visceral metastases Normal AFP Any hCG Any LDH
Intermediate-prognosis group
Nonseminomas (28% of cases): all the following criteria 5-year PFS 75%, testis/retroperitoneal primary 5-year survival 80%, no nonpulmonary visceral metastases AFP 1,000–10,000 ng/mL, or hCG 5,000–50,000 IU/l, or LDH 1.5–10 ULN
Seminomas (10% of cases): any of the following criteria 5-year PFS 67%, any primary site 5-year survival 72%, nonpulmonary visceral metastases Normal AFP Any hCG Any LDH
Poor-prognosis group
Nonseminomas (16% of cases): any of the following criteria: 5-year PFS 41%, mediastinal primary 5-year survival 48%, nonpulmonary visceral metastases AFP >10,000 ng/mL, or hCG >50,000 IU/l (10,000 ng/mL), or LDH >10 ULN
Seminomas No patients classified with poor prognosis

Note: Reprinted with permission. © 1997 American Society of Clinical Oncology. All rights reserved. International Germ Cell Cancer Collaborative Group. International germ cell consensus classification: a prognostic factor-based staging system for metastatic germ cell cancers. J Clin Oncol. 1997;15:594–603.²⁰

Abbreviations: PFS, progression-free survival; AFP, α -fetoprotein; hCG, human chorionic gonadotrophin; LDH, lactate dehydrogenase; ULN, upper limit of normal.

better characterization of NSGCTs demonstrating heterogeneous signal and enhancement characteristics caused by necrosis and hemorrhage. However, there may be overlap in the imaging characteristics of seminomas and NSGCTs.²⁹

Lymph-Node Metastases (N Stage)

About 15%–20% will present with disease that has metastasized to abdominal lymph nodes, constituting stage II disease. CT scans of the chest, abdomen, and pelvis are the

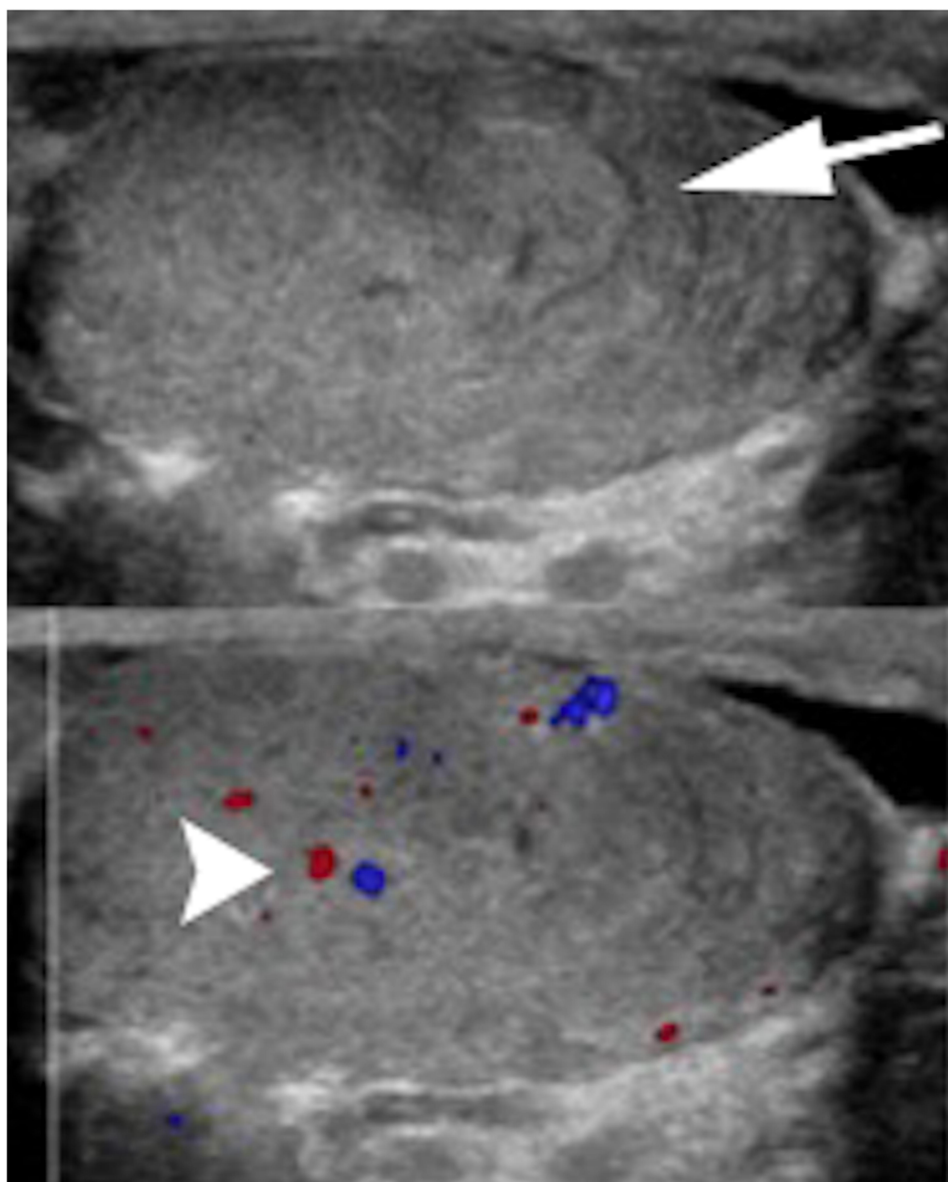


Figure 3 Seminoma: homogeneous large oval intratesticular mass lesion with internal hypervascularity.

recommended method for staging for infradiaphragmatic lymph nodes (Figure 5). Lymphatics are a major route of cancer spread for testicular malignancies, because the tunica albuginea forms a barrier against local extension. Retroperitoneal spread is felt to be the result of embryological migration of the testis through the retroperitoneum, where it acquires drainage from the lymphatics adjacent to the aorta and inferior vena cava.³⁰ As per the literature, about 15%–20% of patients with stage I seminoma can have subclinical metastatic disease, usually in the retroperitoneum, and relapse after orchiectomy alone.³¹

While CT is the standard of care for locating the presence of lymphadenopathy or retroperitoneal masses,

its false-negative rates have been reported to be as high as 30%–59%.^{32,33} A pitfall of CT is that inflammatory reactive lymph nodes cannot be differentiated from those that are enlarged secondarily to malignant disease.³⁴ Lymph-node involvement is usually limited to the site of the primary tumor, and contralateral nodal involvement is usually present only in the presence of advanced disease.³⁵ Lymph nodes >1 cm are suspicious for metastasis, especially if they are located in the renal hilar regions or the aortocaval areas. Various studies have established the accuracy of CT in detecting metastatic retroperitoneal lymph nodes, with sensitivity of 65%–96% and specificity of 81%–100%.^{36,37} On CT,

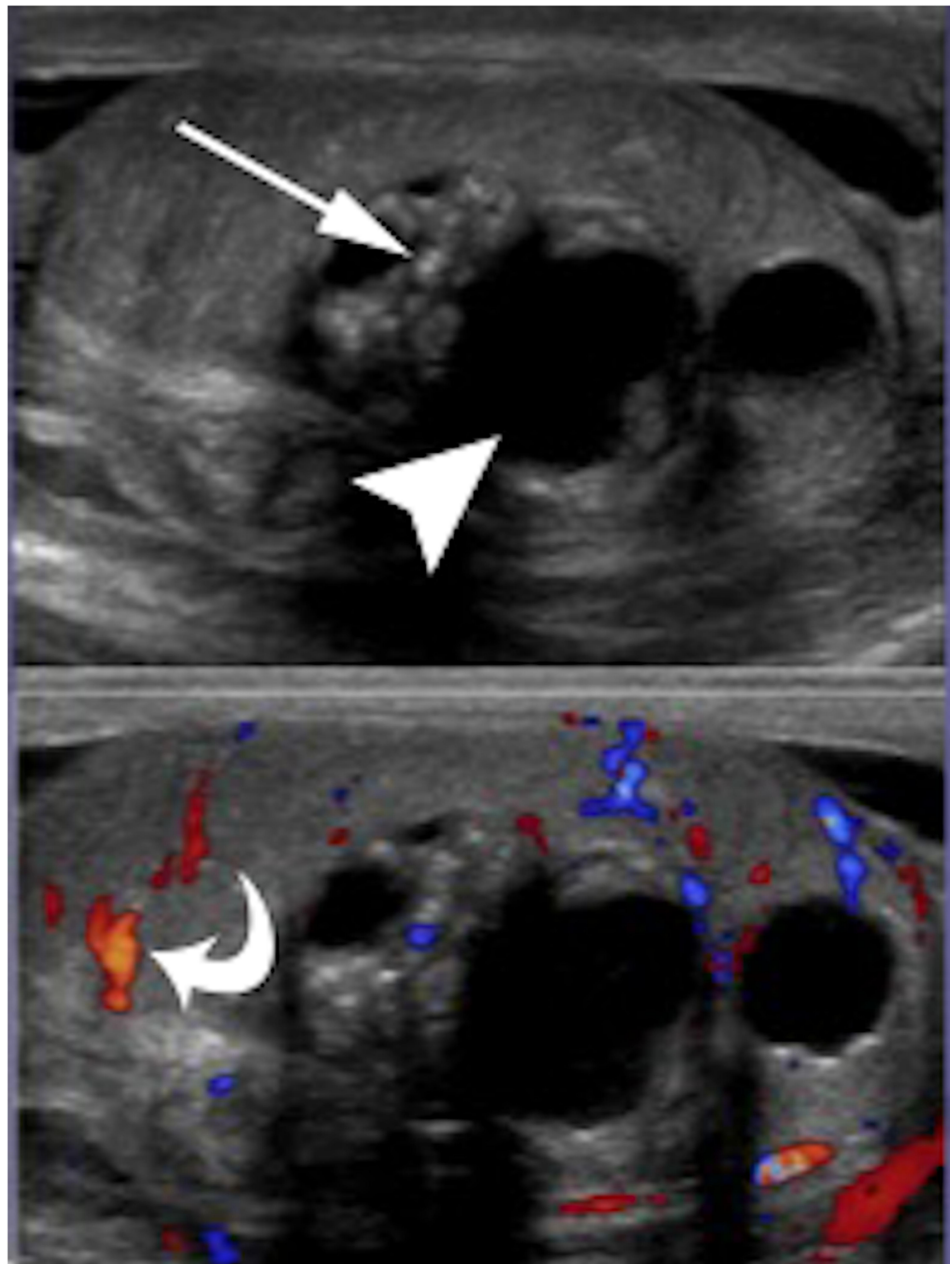


Figure 4 Nonseminomatous GCT: heterogeneous large oval intratesticular mass lesion with internal cystic and calcific changes. The mass also show internal hypervascularity.

retroperitoneal spread will present as enlarged lymph nodes, which could be homogeneous or heterogeneous, depending on cystic or necrotic degeneration. These lymph nodes can be bulky and lobulated, showing conglomeration, and can be encasing the retroperitoneal vasculature.

A recent meta-analysis study by Zhao et al concluded that PET-CT may be an accurate noninvasive and useful diagnostic tool for patients with testicular cancer (Figure 6).³⁸ A negative PET-CT result eliminates viability in large lesions

and helps to avoid unnecessary surgery. In addition, PET-CT demonstrates good specificity, being a potentially useful tool if combined with other imaging methods. Another study by the National Cancer Research Institute Testis Cancer Clinical Studies Group evaluated the performance of PET-CT in nodal staging of testicular cancers with good prognosis, chemotherapy being offered to PET-CT-positive patients, and monitoring of PET-CT-negative patients.³⁹ The sensitivity of PET-CT does not at present seem to be sufficient to detect lymph-node micrometastases or single out patients

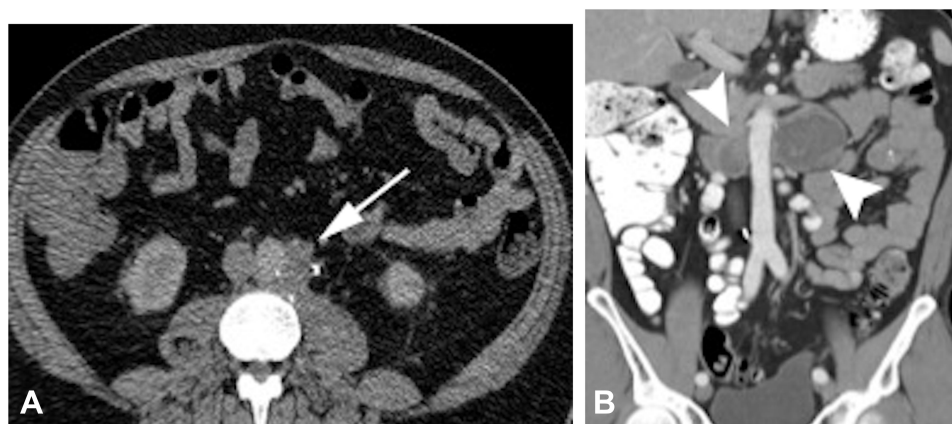


Figure 5 Retroperitoneal metastasis. (A) Left para-aortic lymph node on a patient with left-sided testicular mass. (B) Bilateral large heterogeneous retroperitoneal lymph nodes.

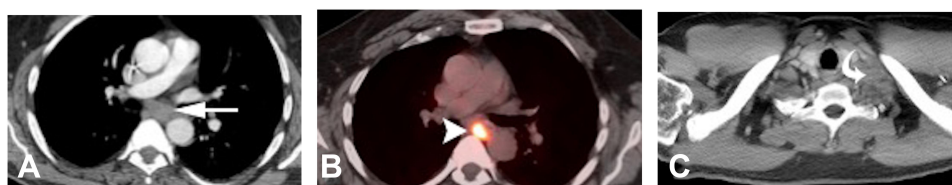


Figure 6 Distant lymph-node metastases. (A) Chest CT soft-tissue window showing subcarinal mediastinal lymphadenopathy with corresponding PET-CT. (B) Increased FDG avidity. (C) Left supraclavicular lymphadenopathy in axial CT with soft-tissue window settings.

with a low risk of recurrence, and additional evidence is needed in order to support its use in initial staging of testicular cancer.⁴⁰ However, PET-CT may still play a role in deciding between chemotherapy or surgery for the initial management of retroperitoneal masses by using metabolic activity as one additional criterion.⁴¹

Distant Metastases (M Stage)

The M1 stage consists of visceral metastatic and supra-diaphragmatic lymph-node involvement. In testicular malignancies, nodal involvement of the inguinal, external iliac, and pelvic nodes is usually considered distant spread. Hematogeneous metastasis usually includes pulmonary metastases (can show a “cannonball” appearance as well), and can also metastasize to the liver, brain, or bone to a lesser extent. Other rare sites of metastasis include the peritoneum, kidneys, and spleen, and are more frequently observed at the time of relapse. CT of the chest, abdomen, and pelvis is currently the most precise and rapid imaging method for exploring the entire trunk, looking for metastases in the lungs and other target organs.⁴² CT of the thorax is most often preferred over chest X-rays.⁴³ It is uncommon to observe metastases in

the lung and posterior mediastinum without concomitant retroperitoneal disease (Figures 8 and 9).⁴⁴

Brain MRI may be advocated in addition to the chest/abdomen/pelvis CT scan if the patient has pertinent clinical symptoms or for testicular tumors with a poor prognosis (Figure 10). Brain metastases are most common with choriocarcinoma, which is also the most common cause of hemorrhagic pulmonary metastases.⁴⁵ GCT metastases may have histological characteristics that are different from those of the primary testicular tumor, indicating the totipotential nature of the GCs.⁴⁶ Spinal MRI may also be proposed when vertebral metastasis has been shown on the CT scan. Bone scintigraphy using technetium-99m-labelled phosphate derivatives can be recommended in patients when bone metastasis is suspected.¹⁸ Evaluation by PET-CT is again not currently indicated in any initial staging of testicular cancer.⁴⁰

MRI has also been recommended in the staging of testicular tumors in special circumstances: patients with iodinated contrast is contraindicated or in cases where radiation exposure should be limited. In these instances, MRI sensitivity and specificity results have been shown to be similar to CT.⁴⁷ The disadvantages of MRI are longer examination times, high cost, artifacts, and low availability

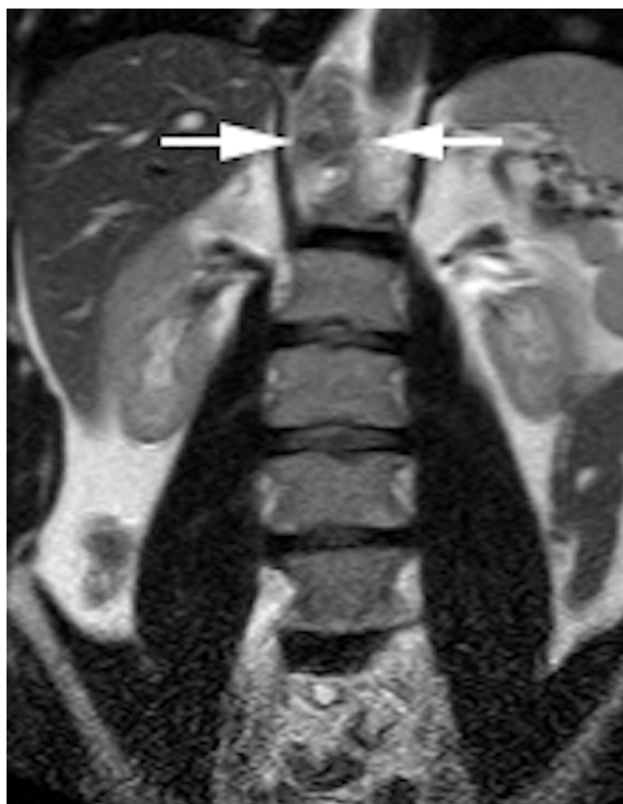


Figure 7 Use of MRI for retroperitoneal spread. Retrocrural heterogeneous T_2 intermediate signal intensity LN on right side.

(Figure 7). MRI with lymphotropic nanoparticles has been shown to be an effective method for evaluating lymph nodes in different cancers.⁴⁸ The role of MRI with lymphotropic nanoparticles still needs larger study designs to be able to be accommodated in regular clinical practice.

Serological Tumor Markers

In testicular GCTs, serum concentrations of α -fetoprotein (AFP), human chorionic gonadotrophin (hCG), and lactate dehydrogenase (LDH) are imperative in screening, diagnosis, staging, treatment monitoring, and surveillance. However, different types of GCT have different tumor-marker profiles, as well as pure form or mixed type. Patients with testicular GCT will have elevated tumor markers in 51% of cases: increased levels of AFP are associated with yolk-sac tumors, and elevated β -hCG is found in cases of choriocarcinoma. LDH is reportedly a less informative tumor marker.^{49,51} Tumor markers also offer a means of patient follow-up and continue to yield information regarding response and ongoing prognosis.⁵²

In cases of seminomatous testicular tumors, LDH may be elevated in 80% of patients, but this tumor marker can

also be elevated in up to 60% of NSGCTs.⁵³ Elevated LDH may be seen, and correlates with tumor burden, growth rate, cellular proliferation, and advanced disease. Placental alkaline phosphatase is another tumor marker that may be elevated in seminomas, but may also be falsely elevated in smokers.²⁵ Elevated β -hCG can be seen in up to 20% of cases of advanced seminomatous disease.⁵⁴ Testicular choriocarcinoma very often has elevated serum β -hCG levels that are produced by tumor syncytiotrophoblasts. Therefore, β -hCG is important in monitoring treatment response and recurrence.⁵⁴ Yolk-sac tumors have elevated AFP levels in 90% of cases, which usually decrease 5 days after orchiectomy.⁵⁴ If AFP levels do not decrease, this raises concern for possible residual primary disease or metastases that were not detected on the initial staging evaluation.⁵⁴

Testicular embryonal-cell tumors demonstrate elevated AFP and β -

hCG; however, in pure embryonal cell tumors these tumor markers are elevated to a lesser extent. Levels of these tumor markers are proportional to tumor burden, and elevation is a sign of poor prognosis.⁵⁴ Pure testicular teratomas do not have AFP elevation; however, elevated AFP can be seen in tumors with mucinous or hepatoid differentiation. The lack of tumor-marker elevation at initial staging can pose a challenge in treatment monitoring/surveillance, as confidence in a disease-free state becomes exclusively reliant on radiological changes: new or growing soft tissue at the site of resection, lymphadenopathy, or new distant lesions suggestive of metastases.

Restaging and Surveillance

Of all seminomas, 75% are confined to the testicle at the time of clinical presentation, and a complete cure is thus achieved with a thorough radical orchiectomy. In patients with non-metastatic stage I seminoma, the risk of subsequent para-aortic lymph-node relapse is 15%–20%, but adjuvant use of either chemotherapy or radiotherapy reduces the risk of recurrence to <1%.⁵⁵ Patients declining primary chemotherapy may be offered primary nerve-sparing retroperitoneal lymph-node dissection with adjuvant chemotherapy. Primary chemotherapy and primary retroperitoneal lymph-node dissection have comparable outcomes and a cure rate of almost 90% for stage II disease.⁵⁶ Chemotherapy with radiotherapy appears to reduce the relapse rate in stage II seminoma with minimal additional toxicity.⁵⁷

Imaging and tumor markers are the two important aspects of restaging and surveillance of testicular tumors.

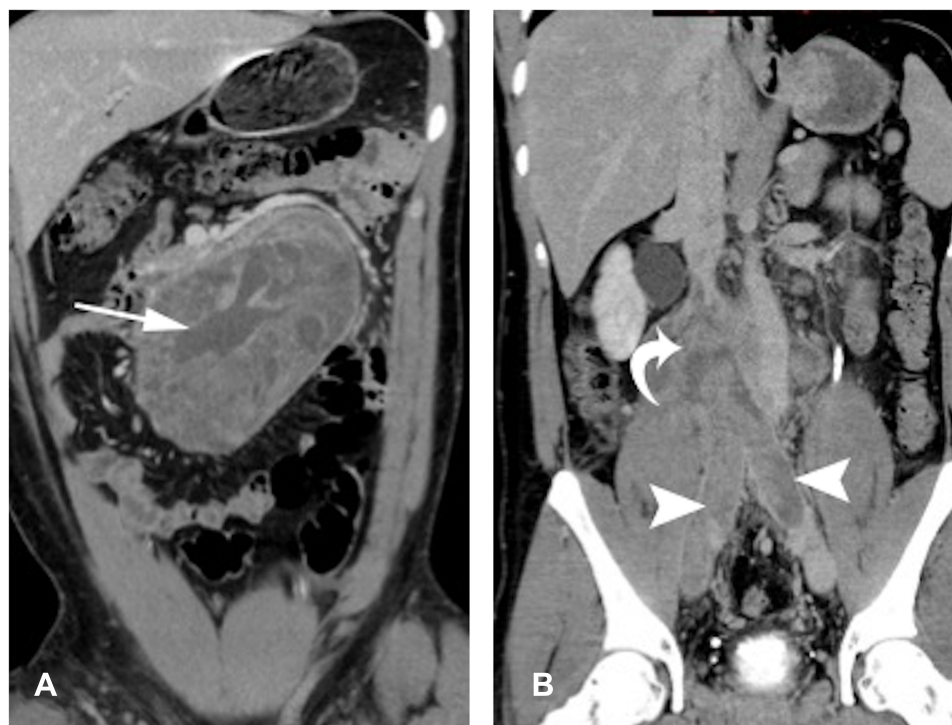


Figure 8 Retroperitoneal metastasis teratoma. **(A)** Large heterogeneous retroperitoneal mass lesion with internal necrotic and cystic contents. **(B)** Retroperitoneal spread with vascular invasion involving iliac veins and IVC.

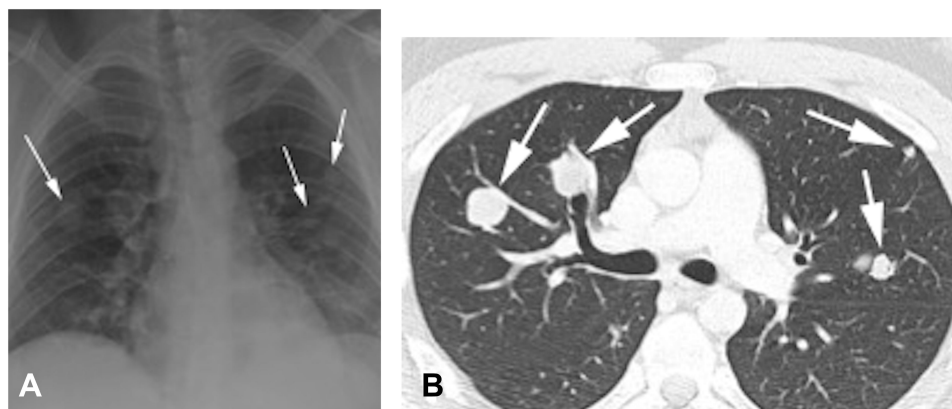


Figure 9 Pulmonary metastases. Same patient as [Figure 8](#). **(A)** Chest radiograph showing multiple pulmonary masses and nodules predominantly in bilateral mid-zones. **(B)** Chest CT lung window settings showing multiple lung nodules in right-middle and left-upper lobes.

Depending on the stage of the tumor, follow-up guidelines vary based on the 2011 European Association of Urology guidelines ([Tables 8–, 10](#)).⁵⁸ The European Consensus Conference on Diagnosis and Treatment of GC Cancer guidelines state that radiological restaging must be performed after completion of first-line chemotherapy; however, in patients with slow tumor-marker decline or clinical evidence of progression, restaging should be performed earlier, because immediate modification of the first-line treatment strategy may be required.⁵⁹

CT of chest/abdomen/pelvis is the usual method for assessing response of disease to treatment. Size reduction of metastases is the primary criterion for assessing tumor response to therapy, though institutional preferences may vary based on clinical trial guidelines. In addition to size change, CT can help assess residual postchemotherapy tissue characteristics, eg, development of cystic and fatty features at sites of previous metastases have been associated with mature differentiated teratomas and may indicate the need for surgical removal.^{60,62} Seminoma primary

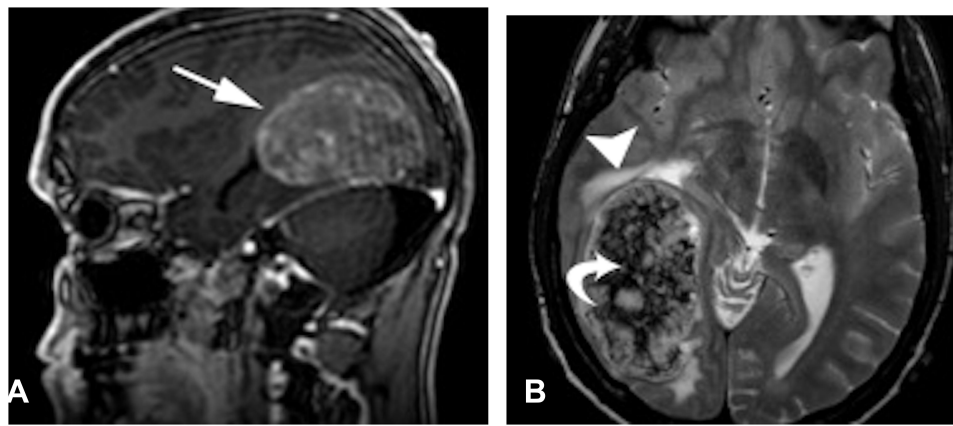


Figure 10 Brain metastases of NSGCT with a patient presenting with headaches. **(A)** Sagittal T_1 -weighted postcontrast images showing intra-axial heterogeneous enhancing mass lesion in right occipital region. **(B)** Axial T_2 WI Large intra-axial heterogeneous mass lesion with surrounding mass effect and edema, also showing internal dark T_2 foci, which could represent hemorrhagic components.

and metastatic sites may demonstrate necrosis, fibrosis, and/or calcifications.⁶³ Treated lung metastases may demonstrate cavitation that may initially appear ominous,

then subsequently progress to more benign-appearing fibrosis.⁶⁴ Patients with large-volume post-neoadjuvant therapy disease may benefit from the use of CT and MRI for planning an operative approach.⁶⁵

Table 8 Stage I Nonseminoma Testicular Cancer: Minimum Follow-up Schedules for Surveillance and Following Retroperitoneal Lymph-Node Dissection or Adjuvant Chemotherapy

Minimum follow-up schedules for surveillance				
Procedure	Year 1	Year 2	Years 3–5	Years 6–10
Chest X-ray	Twice	Twice	—	—
Abdominopelvic CT	Twice (at 3 months and 12 months)	—	—	—
Following retroperitoneal lymph-node dissection or adjuvant chemotherapy				
Procedure	Year 1	Year 2	Year 3–5	Year 6–10
Chest X-ray	Twice	Twice	—	—
Abdominopelvic CT	Once	Once	—	—

Note:Reproduced with permission from Albers P, Albrecht W, Algaba F, et al. EAU guidelines on testicularcancer: 2011 update. *Actas Urol Esp.* 2012;36:127–145. Copyright 2012, Elsevier.⁵⁸

Table 9 Stage I Seminoma Testicular Cancer: Minimum Follow-up Schedule for Postorchietomy Surveillance, Radiotherapy, or Chemotherapy

Procedure	Year 1	Year 2	Year 3	Years 4–5
Chest X-ray	Twice	Twice	—	—
Abdominopelvic CT	Twice	Twice	Annually	Annually

Note:Reproduced with permission from Albers P, Albrecht W, Algaba F, et al. EAU guidelines on testicularcancer: 2011 update. *Actas Urol Esp.* 2012;36:127–145. Copyright 2012, Elsevier.⁵⁸

Follow-up of metastatic lymphadenopathy with CT demonstrates similar features to response and recurrence at primary and other metastatic sites, eg, treatment response of decreased size and necrosis/fibrosis, and progression or recurrence of lymphadenopathy growth. Studies have emphasized the usefulness of PET-CT in the follow-up evaluation of metastatic lymphadenopathy based on maximum systemic uptake values.⁴¹ In patients with pure seminomas and postchemotherapy residual disease >3 cm, PET-CT can be considered (Figures 11 and 12), and PET-positive masses should be considered for biopsy, selective surgical resection, or close

Table 10 Advanced (Metastatic) Testicular Cancer: Minimum Follow-up Schedule

Procedure	Year 1	Year 2	Year 3–5	Thereafter
Chest X-ray	Four times	Four times	Twice per year	Annually
Abdominopelvic CT	Twice	Twice	As indicated	As indicated
Chest CT	As indicated	As indicated	As indicated	As indicated
Brain CT	As indicated	As indicated	As indicated	As indicated

Note:Reproduced with permission from Albers P, Albrecht W, Algaba F, et al. EAU guidelines on testicularcancer: 2011 update. *Actas Urol Esp.* 2012;36:127–145. Copyright 2012, Elsevier.⁵⁸

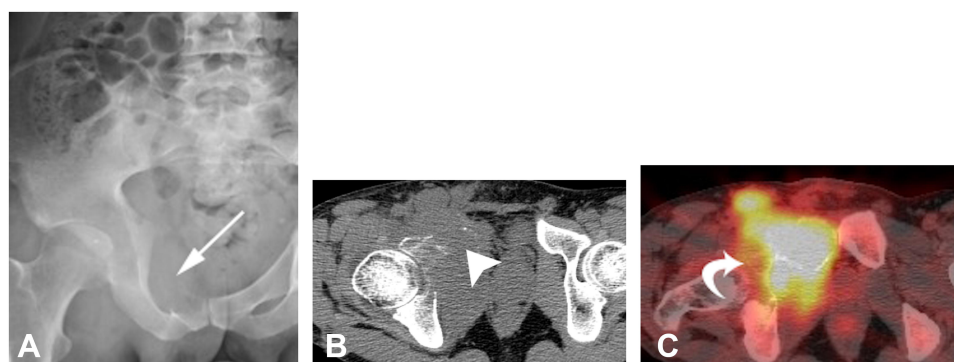


Figure 11 Bone metastases of NSGCT in a patient presenting with seminoma and PET-avid osseous metastasis. **(A)** Pelvic radiography showing geographic lytic lesion involving right superior pubic ramus. **(B and C)** Axial CT of pelvis showing geographic mass lesion with soft-tissue component involving superior pubic ramus with corresponding increased FDG avidity.

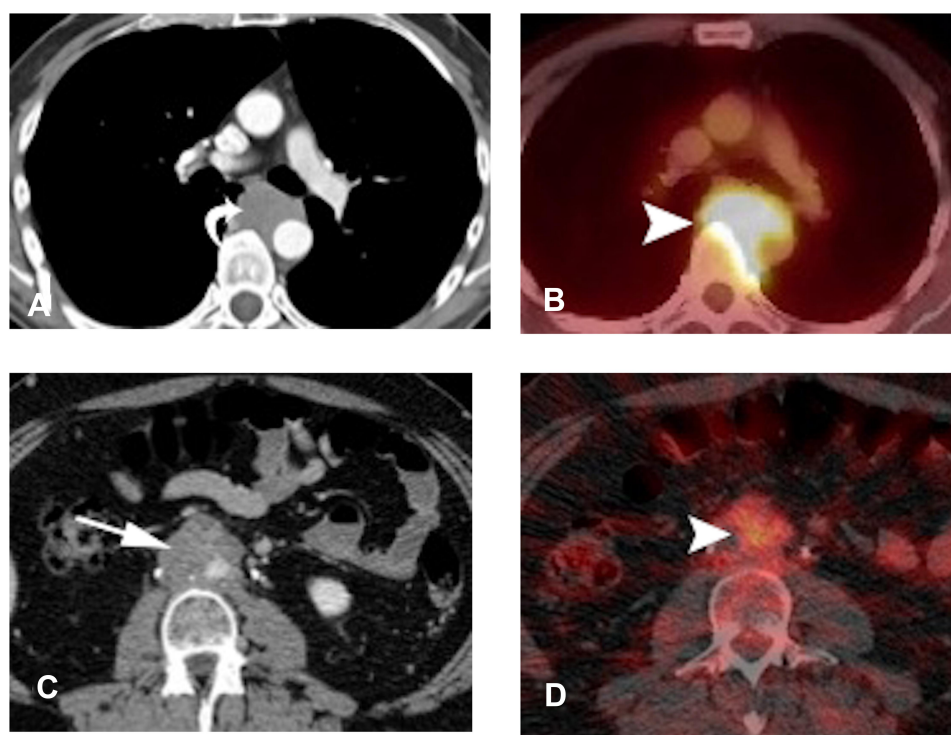


Figure 12 Use of FDG-PETCT in restaging. **(A and B)** Patient with seminoma showing mediastinal lymphadenopathy with increased FDG avidity. **(C and D)** Patient with NSGCT showing mildly hypermetabolic retroperitoneal lymph nodes. In both cases, FDG-PET/CT was used for treatment-response monitoring.

surveillance.⁶⁶ It should be noted that FDG-PET is sub-optimal at distinguishing fibrosis from teratomas, as both have low uptake values; however, Sugawara et al suggested the utility of PET kinetic-rate constants to differentiate mature teratomas from fibrosis and necrosis.⁶⁷ PET-CT may also demonstrate false-positive (nonmalignant) hypermetabolic activity as a result of posttreatment inflammation.^{38,68} For this reason, it might be prudent to perform PET-CT before chemotherapy or have an interval of no sooner than 4 weeks after chemotherapy.⁶⁹

Treatment and Treatment Complications

Standard-of-care medical therapy for patients with low-risk GCTs includes three cycles of bleomycin, etoposide, and cisplatin (BEP) or four cycles of EP.⁷⁰ Patients with advanced disease typically receive four cycles of BEP or etoposide, ifosfamide, and cisplatin.^{71,72} Toxicities associated with these chemotherapeutic agents have been well described in the literature.^{70,73,76} Bleomycin is associated with immunomediated pulmonary toxicity, eventually leading to fibrosis. With dose as the sole risk factor, bleomycin-induced

pulmonary toxicity has an incidence of 8.5%.⁷³ Poor renal function and high cumulative dose are the best-established risk factors, and their presence increases the probability of developing pulmonary toxicity. In fact, incidence of fatal pulmonary fibrosis has been reported as high as 10% for patients receiving high cumulative doses.^{70,73} High-resolution CT findings of bleomycin-induced pulmonary toxicity vary by histological patterns of lung injury. Injury patterns vary from aspecific interstitial pneumonia, cryptogenic organizing pneumonia, and diffuse alveolar damage patterns. Cisplatin-induced venous thromboembolism and cardiovascular disease is another common chemotherapy-induced toxicity encountered in the treatment of testicular cancer.^{70,76} Endothelial injury and increased circulating prothrombotic factors can lead to thrombosis.⁷⁶ On cardiovascular or abdominopelvic imaging, the presence of new or increasing calcified or uncalcified atherosclerotic plaques can suggest the presence of cisplatin-induced vascular toxicity.

Conclusion

Testicular cancer is considered almost curable in low tumor-burden stages. In addition to tumormarkers, multimodality-imaging evaluation plays a pivotal role in patient management. While US and CT are mainly used as imaging modalities for initial staging, PET-CT and MRI can be used in restaging in special circumstances. Imaging is necessary for tumor response to treatment, restaging, and surveillance. It is essential that the clinical team has thorough knowledge of imaging modalities to be used in each stage of the disease, and radiologists should also guide clinicians to order a study depending on the circumstances of the patient.

Disclosure

The authors report no conflicts of interest for this work.

References

- Bray F, Richiardi L, Ekbom A, Pukkala E, Cuninkova M, Moller H. Trends in testicular cancer incidence and mortality in 22 European countries: continuing increases in incidence and declines in mortality. *Int J Cancer*. 2006;118:3099–3111. doi:10.1002/ijc.21747
- Keegan TH, Ries LA, Barr RD, et al. Comparison of cancer survival trends in the United States of adolescents and young adults with those in children and older adults. *Cancer*. 2016;122:1009–1016. doi:10.1002/cncr.29869
- Board PDQATE. Testicular cancer treatment (PDQ(R)): health Professional version. In: *PDQ Cancer Information Summaries*. Bethesda (MD): National Cancer Institute (US); 2002.
- Ehrlich Y, Margel D, Lubin MA, Baniel J. Advances in the treatment of testicular cancer. *Transl Androl Urol*. 2015;4:381–390. doi:10.3978/j.issn.2223-4683.2015.06.02
- Richiardi L, Pettersson A, Akre O. Genetic and environmental risk factors for testicular cancer. *Int J Androl*. 2007;30:230–240; discussion 240–231. doi:10.1111/j.1365-2605.2007.00760.x
- Cook MB, Akre O, Forman D, Madigan MP, Richiardi L, McGlynn KA. A systematic review and meta-analysis of perinatal variables in relation to the risk of testicular cancer—experiences of the mother. *Int J Epidemiol*. 2009;38:1532–1542. doi:10.1093/ije/dyp287
- Chien FL, Schwartz SM, Johnson RH. Increase in testicular germ cell tumor incidence among Hispanic adolescents and young adults in the United States. *Cancer*. 2014;120:2728–2734. doi:10.1002/cncr.28684
- Williamson SR, Delahunt B, Magi-Galluzzi C, et al. The World Health Organization 2016 classification of testicular germ cell tumors: a review and update from the International Society of Urological Pathology Testis Consultation Panel. *Histopathology*. 2017;70:335–346. doi:10.1111/his.13102
- Sohaib SA, Koh DM, Husband JE. The role of imaging in the diagnosis, staging, and management of testicular cancer. *AJR Am J Roentgenol*. 2008;191:387–395. doi:10.2214/AJR.07.2758
- Heller HT, Oliff MC, Doubilet PM, O’Leary MP, Benson CB. Testicular microlithiasis: prevalence and association with primary testicular neoplasm. *J Clin Ultrasound*. 2014;42:423–426. doi:10.1002/jcu.22144
- Cast JE, Nelson WM, Early AS, et al. Testicular microlithiasis: prevalence and tumor risk in a population referred for scrotal sonography. *AJR Am J Roentgenol*. 2000;175:1703–1706. doi:10.2214/ajr.175.6.1751703
- Muglia V, Tucci S, Elias J, Trad CS, Bilbey J, Cooperberg PL. Magnetic resonance imaging of scrotal diseases: when it makes the difference. *Urology*. 2002;59:419–423. doi:10.1016/S0090-4295(01)01579-5
- Tsili AC, Argyropoulou MI, Astrakas LG, et al. Dynamic contrast-enhanced subtraction MRI for characterizing intratesticular mass lesions. *AJR Am J Roentgenol*. 2013;200:578–585. doi:10.2214/AJR.12.9064
- Thomas KL, Jeong D, Montilla-Soler J, Feuerlein S. The role of diagnostic imaging in the primary testicular cancer: initial staging, response assessment and surveillance. *Transl Androl Urol*. 2020;9:S3–S13. doi:10.21037/tau.2019.07.01
- Moul JW. Timely diagnosis of testicular cancer. *Urol Clin North Am*. 2007;34:109–117. doi:10.1016/j.ucl.2007.02.003
- Albers P, Albrecht W, Algaba F, et al. Guidelines on testicular cancer. *Eur Urol*. 2005;48:885–894. doi:10.1016/j.eururo.2005.06.019
- Schmoll HJ, Souchon R, Krege S, et al. European consensus on diagnosis and treatment of germ cell cancer: a report of the European Germ Cell Cancer Consensus Group (EGCCCG). *Ann Oncol*. 2004;15:1377–1399. doi:10.1093/annonc/mdh301
- Krege S, Beyer J, Souchon R, et al. European consensus conference on diagnosis and treatment of germ cell cancer: a report of the second meeting of the European Germ Cell Cancer Consensus group (EGCCCG): part I. *Eur Urol*. 2008;53:478–496. doi:10.1016/j.eururo.2007.12.024
- Amin M, Edge S, Greene F, et al. *AJCC Cancer Staging Manual*. 8th ed. Springer International Publishing: American Joint Commission on Cancer;2017.
- International Germ Cell Cancer Collaborative Group. International germ cell consensus classification: a prognostic factor-based staging system for metastatic germ cell cancers. *J Clin Oncol*. 1997;15:594–603. doi:10.1200/JCO.1997.15.2.594
- Aigner F, De Zordo T, Pallwein-Prettner L, et al. Real-time sonoelastography for the evaluation of testicular lesions. *Radiology*. 2012;263:584–589. doi:10.1148/radiol.12111732
- Sung EK, Setty BN, Castro-Aragon I. Sonography of the pediatric scrotum: emphasis on the Ts—torsion, trauma, and tumors. *AJR Am J Roentgenol*. 2012;198:996–1003. doi:10.2214/AJR.11.8034
- Woodward PJ, Sohaey R, O’Donoghue MJ, Green DE. From the archives of the AFIP: tumors and tumorlike lesions of the testis: radiologic-pathologic correlation. *Radiographics*. 2002;22:189–216. doi:10.1148/radiographics.22.1.g02ja14189

24. Schwerk WB, Schwerk WN, Rodeck G. Testicular tumors: prospective analysis of real-time US patterns and abdominal staging. *Radiology*. 1987;164:369–374. doi:10.1148/radiology.164.2.3299487
25. Vasdev N, Moon A, Thorpe AC. Classification, epidemiology and therapies for testicular germ cell tumors. *Int J Dev Biol*. 2013;57:133–139. doi:10.1387/ijdb.130031nv
26. Luker GD, Siegel MJ. Pediatric testicular tumors: evaluation with gray-scale and color Doppler US. *Radiology*. 1994;191:561–564. doi:10.1148/radiology.191.2.8153341
27. Cosgrove D, Piscaglia F, Bamber J, et al. EFSUMB guidelines and recommendations on the clinical use of ultrasound elastography. Part 2: clinical applications. *Ultraschall Med*. 2013;34:238–253. doi:10.1055/s-0033-1335375
28. Tsili AC, Argyropoulou MI, Giannakis D, Sofikitis N, Tsampoulas K. MRI in the characterization and local staging of testicular neoplasms. *AJR Am J Roentgenol*. 2010;194:682–689. doi:10.2214/AJR.09.3256
29. Aganovic L, Cassidy F. Imaging of the scrotum. *Radiol Clin North Am*. 2012;50:1145–1165. doi:10.1016/j.rcl.2012.08.003
30. Sheinfeld J, McKiernan J, GJ Bosl. *Surgery for Testicular Tumors*. 2002:2920–2944.
31. Sternberg CN. The management of stage I testis cancer. *Urol Clin North Am*. 1998;25:435–449. doi:10.1016/S0094-0143(05)70033-1
32. Fernandez EB, Moul JW, Foley JP, Colon E, McLeod DG. Retroperitoneal imaging with third and fourth generation computed axial tomography in clinical stage I nonseminomatous germ cell tumors. *Urology*. 1994;44:548–552. doi:10.1016/S0090-4295(94)80056-1
33. McLeod DG, Weiss RB, Stablein DM, et al. Staging relationships and outcome in early stage testicular cancer: a report from the Testicular Cancer Intergroup Study. *J Urol*. 1991;145:1178–1183; discussion 1182–1173. doi:10.1016/S0022-5347(17)38567-1
34. McMahon CJ, Rofsky NM, Pedrosa I. Lymphatic metastases from pelvic tumors: anatomic classification, characterization, and staging. *Radiology*. 2010;254:31–46. doi:10.1148/radiol.2541090361
35. Dunnick NR, Javadpour N. Value of CT and lymphography: distinguishing retroperitoneal metastases from nonseminomatous testicular tumors. *AJR Am J Roentgenol*. 1981;136:1093–1099. doi:10.2214/ajr.136.6.1093
36. Hilton S, Herr HW, Teicher JB, Begg CB, Castellino RA. CT detection of retroperitoneal lymph node metastases in patients with clinical stage I testicular nonseminomatous germ cell cancer: assessment of size and distribution criteria. *AJR Am J Roentgenol*. 1997;169:521–525. doi:10.2214/ajr.169.2.9242768
37. Husband JE, Barrett A, Peckham MJ. Evaluation of computed tomography in the management of testicular teratoma. *Br J Urol*. 1981;53:179–183. doi:10.1111/j.1464-410X.1981.tb03162.x
38. Zhao JY, Ma XL, Li YY, et al. Diagnostic accuracy of 18F-FDG-PET in patients with testicular cancer: a meta-analysis. *Asian Pac J Cancer Prev*. 2014;15:3525–3531. doi:10.7314/APJCP.2014.15.8.3525
39. Huddart RA, O'Doherty MJ, Padhani A, et al. 18fluorodeoxyglucose positron emission tomography in the prediction of relapse in patients with high-risk, clinical stage I nonseminomatous germ cell tumors: preliminary report of MRC Trial TE22—the NCRI Testis Tumor Clinical Study Group. *J Clin Oncol*. 2007;25:3090–3095. doi:10.1200/JCO.2006.09.3831
40. Becherer A. PET in testicular cancer. *Methods Mol Biol*. 2011;727:225–241.
41. Sterbis JR, Rice KR, Javitt MC, Schenkman NS, Brassell SA. Fusion imaging: a novel staging modality in testis cancer. *J Cancer*. 2010;1:223–229. doi:10.7150/jca.1.223
42. Brunereau L, Bruyere F, Linassier C, Baulieu JL. The role of imaging in staging and monitoring testicular cancer. *Diagn Interv Imaging*. 2012;93:310–318. doi:10.1016/j.diii.2012.01.014
43. White PM, Adamson DJ, Howard GC, Wright AR. Imaging of the thorax in the management of germ cell testicular tumors. *Clin Radiol*. 1999;54:207–211. doi:10.1016/S0009-9260(99)91152-2
44. Stephenson AJ, Sheinfeld J. The role of retroperitoneal lymph node dissection in the management of testicular cancer. *Urol Oncol*. 2004;22:225–233; discussion 234–225. doi:10.1016/j.urolonc.2004.04.029
45. Seo JB, Im JG, Goo JM, Chung MJ, Kim MY. Atypical pulmonary metastases: spectrum of radiologic findings. *Radiographics*. 2001;21:403–417. doi:10.1148/radiographics.21.2.g01mr17403
46. Ulbright TM, Hattab EM, Zhang S, et al. Primitive neuroectodermal tumors in patients with testicular germ cell tumors usually resemble pediatric-type central nervous system embryonal neoplasms and lack chromosome 22 rearrangements. *Mod Pathol*. 2010;23:972–980. doi:10.1038/modpathol.2010.70
47. Hansen J, Jurik AG. Diagnostic value of multislice computed tomography and magnetic resonance imaging in the diagnosis of retroperitoneal spread of testicular cancer: a literature review. *Acta Radiol*. 2009;50:1064–1070. doi:10.3109/02841850903220371
48. Rockall AG, Sohaib SA, Harisinghani MG, et al. Diagnostic performance of nanoparticle-enhanced magnetic resonance imaging in the diagnosis of lymph node metastases in patients with endometrial and cervical cancer. *J Clin Oncol*. 2005;23:2813–2821. doi:10.1200/JCO.2005.07.166
49. Wanderas EH, Fossa SD, Tretli S. Risk of a second germ cell cancer after treatment of a primary germ cell cancer in 2201 Norwegian male patients. *Eur J Cancer*. 1997;33:244–252. doi:10.1016/S0959-8049(96)00459-5
50. Sturgeon CM, Duffy MJ, Stenman UH, et al. National Academy of Clinical Biochemistry laboratory medicine practice guidelines for use of tumor markers in testicular, prostate, colorectal, breast, and ovarian cancers. *Clin Chem*. 2008;54:e11–e79.
51. von Eyben FE, Liu FJ, Amato RJ, Fritsche HA. Lactate dehydrogenase isoenzyme 1 is the most important LD isoenzyme in patients with testicular germ cell tumor. *Acta Oncol*. 2000;39:509–517. doi:10.1080/028418600750013438
52. Looijenga LH, Stoop H, Biermann K. Testicular cancer: biology and biomarkers. *Virchows Arch*. 2014;464:301–313. doi:10.1007/s00428-013-1522-1
53. Leman ES, Gonzalgo ML. Prognostic features and markers for testicular cancer management. *Indian J Urol*. 2010;26:76–81. doi:10.4103/0970-1591.60450
54. Marshall C, Enzerra M, Rahnemai-Azar AA, Ramaiya NH. Serum tumor markers and testicular germ cell tumors: a primer for radiologists. *Abdom Radiol*. 2019;44:1083–1090. doi:10.1007/s00261-018-1846-z
55. Chung P, Parker C, Panzarella T, et al. Surveillance in stage I testicular seminoma - risk of late relapse. *Can J Urol*. 2002;9:1637–1640.
56. Williams SD, Stablein DM, Einhorn LH, et al. Immediate adjuvant chemotherapy versus observation with treatment at relapse in pathological stage II testicular cancer. *N Engl J Med*. 1987;317:1433–1438. doi:10.1056/NEJM198712033172303
57. Patterson H, Norman AR, Mitra SS, et al. Combination carboplatin and radiotherapy in the management of stage II testicular seminoma: comparison with radiotherapy treatment alone. *Radiother Oncol*. 2001;59:5–11. doi:10.1016/S0167-8140(00)00240-1
58. Albers P, Albrecht W, Algaba F, et al. EAU guidelines on testicular cancer: 2011 update. *Actas Urol Esp*. 2012;36:127–145. doi:10.1016/j.acuro.2011.06.017
59. Krege S, Beyer J, Souchon R, et al. European consensus conference on diagnosis and treatment of germ cell cancer: a report of the second meeting of the European Germ Cell Cancer Consensus Group (EGCCCG): part II. *Eur Urol*. 2008;53(3):497–513. doi:10.1016/j.eururo.2007.12.025
60. Lentini JF, Love MB, Ritchie WG, Sedlacek TV. Computed tomography in retroconversion of hepatic metastases from immature ovarian teratoma. *J Comput Assist Tomogr*. 1986;10:1060–1062. doi:10.1097/00004728-198611000-00037
61. Moskovic E, Jobling T, Fisher C, Wiltshaw E, Parsons C. Retroconversion of immature teratoma of the ovary: CT appearances. *Clin Radiol*. 1991;43:402–408. doi:10.1016/S0009-9260(05)80570-7

62. Connor S, Guest P. Conversion of multiple solid testicular teratoma metastases to fatty and cystic liver masses following chemotherapy: CT evidence of “maturation”. *Br J Radiol.* 1999;72:1114–1116. doi:10.1259/bjr.72.863.10700831
63. Williams MP, Naik G, Heron CW, Husband JE. Computed tomography of the abdomen in advanced seminoma: response to treatment. *Clin Radiol.* 1987;38:629–633. doi:10.1016/S0009-9260(87)80345-8
64. Charig MJ, Williams MP. Pulmonary lacunae: sequelae of metastases following chemotherapy. *Clin Radiol.* 1990;42:93–96. doi:10.1016/S0009-9260(05)82075-6
65. Dalal PU, Sohaib SA, Huddart R. Imaging of testicular germ cell tumors. *Cancer Imaging.* 2006;6:124–134. doi:10.1102/1470-7330.2006.0020
66. Aparicio J. Spanish Germ Cell Cancer G. Positron emission tomography (PET) is not indicated in the postchemotherapy evaluation of advanced non-seminomatous testicular germ cell tumors. *Clin Transl Oncol.* 2014;16:509–510. doi:10.1007/s12094-014-1161-2
67. Sugawara Y, Zasadny KR, Grossman HB, Francis IR, Clarke MF, Wahl RL. Germ cell tumor: differentiation of viable tumor, mature teratoma, and necrotic tissue with FDG PET and kinetic modeling. *Radiology.* 1999;211:249–256. doi:10.1148/radiology.211.1.r99ap16249
68. Lewis DA, Tann M, Kesler K, McCool A, Foster RS, Einhorn LH. Positron emission tomography scans in postchemotherapy seminoma patients with residual masses: a retrospective review from Indiana University Hospital. *J Clin Oncol.* 2006;24:e54–55. doi:10.1200/JCO.2006.08.1737
69. De Santis M, Becherer A, Bokemeyer C, et al. 2-18fluoro-deoxy-D-glucose positron emission tomography is a reliable predictor for viable tumor in postchemotherapy seminoma: an update of the prospective multicentric SEMPET trial. *J Clin Oncol.* 2004;22:1034–1039. doi:10.1200/JCO.2004.07.188
70. Feldman DR, Bosl GJ, Sheinfeld J, Motzer RJ. Medical treatment of advanced testicular cancer. *JAMA.* 2008;299:672–684. doi:10.1001/jama.299.6.672
71. Hinton S, Catalano PJ, Einhorn LH, et al. Cisplatin, etoposide and either bleomycin or ifosfamide in the treatment of disseminated germ cell tumors: final analysis of an intergroup trial. *Cancer.* 2003;97:1869–1875. doi:10.1002/cncr.11271
72. Wood MJ, Thomas R, Howard SA, Braschi-Amirfarzan M. Imaging of metastatic germ cell tumors in male patients from initial diagnosis to treatment-related toxicities: a primer for radiologists. *AJR Am J Roentgenol.* 2020;214:24–33. doi:10.2214/AJR.19.21623
73. O’Sullivan JM, Huddart RA, Norman AR, Nicholls J, Dearnaley DP, Horwich A. Predicting the risk of bleomycin lung toxicity in patients with germ-cell tumors. *Ann Oncol.* 2003;14:91–96. doi:10.1093/annonc/mdg020
74. Silva CI, Müller NL. Drug-induced lung diseases: most common reaction patterns and corresponding high-resolution CT manifestations. In: *Seminars in Ultrasound, CT and MRI.* Vol. 27. WB Saunders; 2006:111–116.
75. Torrisi JM, Schwartz LH, Gollub MJ, Ginsberg MS, Bosl GJ, Hricak H. CT findings of chemotherapy-induced toxicity: what radiologists need to know about the clinical and radiologic manifestations of chemotherapy toxicity. *Radiology.* 2011;258:41–56. doi:10.1148/radiol.10092129
76. Seng S, Liu Z, Chiu SK, et al. Risk of venous thromboembolism in patients with cancer treated with Cisplatin: a systematic review and meta-analysis. *J Clin Oncol.* 2012;30:4416–4426. doi:10.1200/JCO.2012.42.4358

Research and Reports in Urology

Dovepress

Publish your work in this journal

Research and Reports in Urology is an international, peer-reviewed, open access journal publishing original research, reports, editorials, reviews and commentaries on all aspects of adult and pediatric urology in the clinic and laboratory including the following topics: Pathology, pathophysiology of urological disease; Investigation and

treatment of urological disease; Pharmacology of drugs used for the treatment of urological disease. The manuscript management system is completely online and includes a very quick and fair peer-review system, which is all easy to use. Visit <http://www.dovepress.com/testimonials.php> to read real quotes from published authors.

Submit your manuscript here: <https://www.dovepress.com/research-and-reports-in-urology-journal>