


A Case of “Cryptammonia”: Disseminated Cryptococcal Infection Generating Profound Hyperammonemia in a Liver Transplant Recipient

Journal of Investigative Medicine High
Impact Case Reports
Volume 10: 1–4
© 2022 American Federation for
Medical Research
DOI: 10.1177/23247096221129467
journals.sagepub.com/home/hic


Steven M. Phillips, DO¹, Stephanie M. Pouch, MD¹, Denise J. Lo, MD¹,
Sheetal Kandiah, MD¹, Koba A. Lomashvili, MD¹,
Ram A. Subramanian, MD¹, Peter Moran, PharmD¹,
Alley Killian, PharmD¹, and Prem A. Kandiah, MD¹ 

Abstract

Mycoplasma and *Ureaplasma* infections have been described as a cause of hyperammonemia syndrome leading to devastating neurological injury in the post-transplant period, most commonly in lung transplant recipients. The occurrence of significant hyperammonemia caused by other urease-producing organisms remains unclear. We describe a case of disseminated cryptococcosis presenting with profound hyperammonemia in a 55-year-old orthotopic liver transplant recipient. Through a process of elimination, other potential causes for hyperammonemia were excluded revealing a probable association between hyperammonemia and disseminated cryptococcosis.

Keywords

hyperammonemia, liver transplant, cryptococcus, immunocompromised

Introduction

Ammonia is a waste product of nitrogen metabolism that is recycled at physiologic levels for amino acid production and acid-base homeostasis. At elevated plasma levels, ammonia is a neurotoxic compound that is predominantly detoxified by a functioning liver along with the assistance of kidneys and skeletal muscle. While liver cirrhosis is the most common presentation of hyperammonemia, there are a number of uncommon presentations of profound hyperammonemia, that if overlooked results in deadly neurological consequences. After liver transplantation with a functioning graft, it is commonly perceived that there is no utility for checking plasma ammonia levels. This case illustrates an important exception attributable to a disseminated fungal infection.

Case Presentation

A 55-year-old man with history of nonalcoholic steatohepatitis and alpha 1 antitrypsin deficiency underwent orthotopic liver transplant. His postoperative course was complicated by an incarcerated inguinal hernia that was repaired uneventfully and cytomegalovirus (CMV) viremia that was treated with valganciclovir. He was discharged on maintenance immunosuppression of mycophenolate mofetil, tacrolimus,

and prednisone. He then presented 5 weeks post-transplant with 2 days of encephalopathy and increasing home oxygen requirements. On arrival, he required 4L nasal cannula to maintain oxygen saturation >92% and encephalopathy characterized by sparse speech and disorientation with a nonfocal neurologic examination. Other vital signs and physical examination were within normal limits. His white blood cell count was $9.3 \times 10^9/L$, creatinine 2.12 mg/dL (baseline <1.0 mg/dL) and blood urea nitrogen of 53 mg/dL (baseline <20 mg/dL). His synthetic liver function international normalized ratio, alanine aminotransferase, aspartate aminotransferase, and bilirubin were within normal limits. His arterial ammonia was unusually elevated at 204 $\mu\text{mol/L}$ in the emergency department precipitating an intensive care unit (ICU)

¹Emory University, Atlanta, GA, USA

Received June 12, 2022. Revised September 3, 2022. Accepted September 12, 2022.

*Steven M. Phillips is now affiliated to University of Nebraska Medical Center, Omaha, NE, USA

Corresponding Author:

Steven M. Phillips, DO, University of Nebraska Medical Center, 988440 Nebraska Medical Center, Omaha, NE 68198-8440, USA.
Email: sphillips@unmc.edu



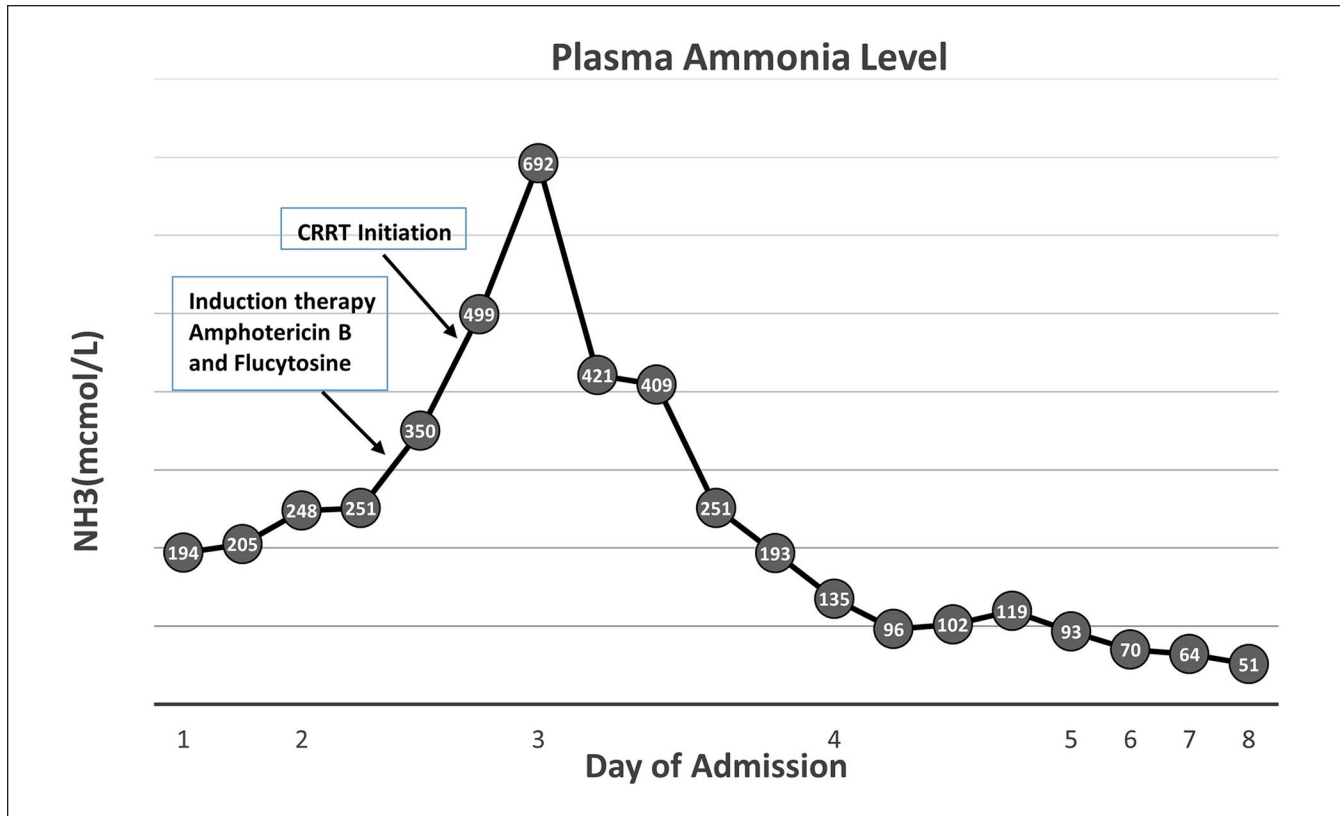


Figure 1. Trends in serial plasma ammonia levels measured 6-hourly in relation to initiation of therapeutic antifungal agents and continuous renal replacement therapy (CRRT).

admission. Induction dosing of intravenous ganciclovir was started for elevated CMV titers. He was started on empiric antibiotic coverage with vancomycin, meropenem, micafungin after blood cultures were drawn. Intravenous micronutrient supplementation for B1, B6, and levocarnitine was initiated on admission to the ICU. Lumbar puncture on admission revealed an opening pressure of 8 cmH₂O, but Gram stain revealed encapsulated yeast suspicious for *Cryptococcus*. He was started on liposomal amphotericin B and flucytosine. For his hyperammonemia, he was started on continuous renal replacement therapy (CRRT) and rifaximin, zinc, and lactulose. Ammonia proceeded to unexpectedly climb to 692 µmol/L over the ensuing 12 to 24 hours with concomitant neurological deterioration necessitating mechanical ventilation. Empiric intravenous doxycycline was started after a urine and bronchial aspirate was obtained for *Mycoplasma* and *Ureaplasma* polymerase chain reaction (PCR). Forty-eight hours after antifungal induction and CRRT, ammonia levels had fallen to <100 µmol/L (see Figure 1). Cryptococcal serum and cerebrospinal fluid (CSF) antigen titers both returned positive at >1:2560. Cultures from bronchoalveolar lavage, CSF, and blood all revealed cryptococcal growth consistent with disseminated disease.

Repeat lumbar punctures revealed opening pressures greater than 45 cmH₂O requiring large volume drainage

every 48 hours. Unfortunately, permanent CSF diversion was not possible given persistent thrombocytopenia that developed 48 hours into his hospitalization reaching a nadir of $16 \times 10^3/\mu\text{L}$. His mental status transiently improved, but he was unable to wean from mechanical ventilation and ultimately require tracheostomy. Even after culture clearance, he continued to display complications of cryptococcal infection related to sludging and obstruction of microvascular structures, resulting in persistent hydrocephalus, oliguric renal failure, and progressive splenic infarcts with necrosis requiring splenectomy.^{1,2} Magnetic resonance imaging of the brain did not reveal cytotoxic edema which was likely prevented by the rapid correction of ammonia levels. His hospital course was further complicated by sepsis, duodenal leak, persisting renal failure, and failure to thrive. Given poor quality of life with multiple unresolved end-organ problems, the family decided to move to comfort care in hospice. Urea cycle disorder screening studies eventually returned revealing a low urine orotic level and a normal serum citrulline and arginine level making this diagnosis unlikely.

Discussion

Severe hyperammonemia is a life-threatening toxidrome that causes cytotoxic brain edema and can lead to irreversible

neurological injury, refractory seizures, and brain herniation. Hyperammonemia following liver transplantation is very rare, occurring in less than 1% of patients with data available mostly through case reports. There are multiple potential causes of hyperammonemia in post-liver transplant patients. These include primary graft failure, transplant rejection, an acquired inborn error of metabolism from the donor liver,³ persistent portosystemic shunting, medications, hyperalimentation, postgastric bypass macronutritional and micronutritional deficiencies, and infection. Our comprehensive workup of hyperammonemia included synthetic liver function tests, serum and urine amino acids, urine orotic acid, blood and urine cultures, imaging for portosystemic shunts, *Ureaplasma* PCR tested in urine and bronchoalveolar lavage, all which were negative. In the absence of another cause, we hypothesize the profound hyperammonemia in this case was the result of disseminated cryptococcal infection.

Our proposed mechanism of hyperammonemia involves the production of urease by *Cryptococcus neoformans*. Urease is a nickel-dependent metalloenzyme present in numerous bacteria, fungi, and plants. It catalyzes urea into ammonia and carbamate. The latter compound spontaneously hydrolyzes to form carbonic acid and another molecule of ammonia.⁴ Urease is produced by multiple organisms including *Proteus*, *Klebsiella*, *Mycoplasma*, *Ureaplasma*, *Helicobacter pylori*, *C neoformans*, and *Cryptococcus gattii*, among others.⁵⁻⁷ Urease is thought to enhance the ability of *Cryptococcus* to cross the blood-brain barrier and facilitate survival in phagocytes while they undergo transcytosis resembling a Trojan horse mechanism. There is also evidence that ammonia directly induces damage of astrocyte tight junctions which increases permeability.⁸ Urease serves as a potential therapeutic target for cryptococcal infections. Acetohydroxamic acid, a US Food and Drug Administration (FDA)-approved irreversible enzyme inhibitor of urease for the management of struvite stones, is a potential candidate. Its activity against *Cryptococcus* has only been demonstrated in vitro thus far.⁹ Acetohydroxamic acid may also serve as a potential adjunctive treatment to control hyperammonemia caused by urease-producing organisms and requires further study for this indication. Acetohydroxamic acid was not available at our institution and only arrived after we had established control of the plasma ammonia levels and therefore was not used in our patient.

There are several other confounding causes of hyperammonemia with normal liver function. Nutritional deficiencies are a known etiology of hyperammonemia; however, this scenario is more frequently reported in the context of prior bowel shortening surgeries, such as Roux-en-Y and Whipple procedures. Severe malnutrition triggering a catabolic state can cause protein degradation and deamination of amino acids. Roux-en-Y procedures can cause alterations of the gut microbiome with bacterial overgrowth favoring urease-producing organisms, leading to cases of significant hyperammonemia.

Micronutrient deficiencies such as carnitine, biotin, and zinc have only been implicated as a cause of hyperammonemia in a few case reports and animal studies.^{10,11} While our patient had a 15 lb weight loss since his transplant, there was no history of significant dietary deficiency, short gut, or bariatric surgery to invoke micronutrient deficiency or severe malnutrition as a primary cause.

Liver donors may also be asymptomatic carriers of inborn errors of metabolism. Ornithine transcarbamylase deficiency (OTC) is the most common syndrome. It is an X-linked recessive defect that has more than 244 genes and 13 polymorphisms, and incomplete penetrance is common.¹² Frequently patients present with hyperammonemia during times of stress as the affected urea cycle is unable to tolerate increased demand. Enzymatic deficiencies can potentially be transmitted via liver transplantation; however, this is a very unlikely scenario given that both receiving a liver transplant and OTC deficiency are uncommon events. Urine orotic acid is expected to be elevated in OTC and is used as a screening test. Our patient had a low level of urine orotic acid making this diagnosis exceedingly unlikely. Toxidromes targeting the urea cycle such as a valproic acid overdose or eating unripe ackee fruit have been reported to cause isolated hyperammonemia. Review of home medications and absence of intake herbal or over the counter supplements eliminate this possibility in our patient.

Ureaplasma has recently been identified as a cause for hyperammonemia in lung transplant patients, especially in the immediate post lung transplant period.¹³ In a defining study, *Ureaplasma* was detected in all 6 patients with hyperammonemia with 20 control subjects testing negative.¹⁴ The impact of hyperammonemia in this patient population was devastating due to the high mortality from progression to cerebral edema and brain herniation. The impact of hyperammonemia in disseminated cryptococcal infections remains unknown. While urease production in *C neoformans* is well recognized, to our knowledge, the association of hyperammonemia in the setting of clinical cryptococcal infection had not been recognized until 2021 when it was described in 2 case reports (see Table 1).¹⁵⁻¹⁷ Our case adds to this growing body of knowledge with the addition of excluding the possibility of *Ureaplasma* as a confounding cause. It is interesting to note, patients in both reports presented with altered mental status implying a possible contribution from hyperammonemia. Without checking plasma ammonia levels, altered mentation can easily be attributable to central nervous system cryptococcosis, overlooking a secondary insult from hyperammonemia. It is reassuring to note plasma ammonia levels in 3 patients including ours, responded to a combination antifungal therapy and CRRT. Early consultation with nephrology and initiation of CRRT may be a critical intervention.

In summary, we describe a case of profound hyperammonemia caused by disseminated *C neoformans* infection in

Table 1. Summary of Pertinent Clinical Findings Case Reports of *Cryptococcus* Associated Hyperammonemia.

Case report	Immunosuppressed/ Reason	Cirrhosis	Impaired renal function	Altered mental status	Urea cycle workup	CNS crypto vs Disseminated crypto	Mycoplasma/ Ureaplasma PCR	CRRT for NH3 control	Peak NH3 level	Neurological outcome
Phillips et al	Immunosuppressed/Liver transplantation	No	Yes	Yes	Negative	Disseminated blood antigen titer: >2560 CSF Antigen titer: >2560	Negative PCR	Yes	692 µmol/L	Transient improvement Normal brain MRI
Hannah et al ¹⁷ and Masroujeh et al ¹⁵	Immunosuppressed/Focal segmental glomerular sclerosis	No	Yes	Yes	Negative ^a	Disseminated Blood antigen titer: 1:262, 154	Not reported	Yes	676 µmol/L	Slow neurological improvement
Stewart et al ¹⁶	Immunosuppressed/Renal transplantation	No	Yes	Yes	Not reported	Disseminated CSF antigen Titer I: 256	Not reported	Yes	240 µmol/L	Complete recovery

Abbreviations: NH3, plasma ammonia; CNS, central nervous system; CRRT, continuous renal replacement therapy; MRI, magnetic resonance imaging.

^aGenetic analysis performed.

a liver transplant patient with preserved liver synthetic function. Early monitoring and control of plasma ammonia elevation may prove to be paramount in managing patients with disseminated cryptococcosis and should be further explored.

Declaration of Conflicting Interests

The author(s) declared no potential conflicts of interest with respect to the research, authorship, and/or publication of this article.

Funding

The author(s) received no financial support for the research, authorship, and/or publication of this article.

Ethics Approval

Our institution does not require ethical approval for reporting individual cases or case series.

Informed Consent

Written informed consent was obtained from a legally authorized representative(s) for anonymized patient information to be published in this article.

ORCID iD

Prem A. Kandiah  <https://orcid.org/0000-0002-7964-0793>

References

- Fries BC, Lee SC, Kennan R, Zhao W, Casadevall A, Goldman DL. Phenotypic switching of *Cryptococcus neoformans* can produce variants that elicit increased intracranial pressure in a rat model of cryptococcal meningoencephalitis. *Infect Immun*. 2005;73(3):1779-1787.
- Bollee G, Touzot M, Mechai F, et al. Plasma exchange for disseminated cryptococcosis. *Am J Kidney Dis*. 2009;53(4):673-676.
- Ghabril M, Nguyen J, Kramer D, Genco T, Mai M, Rosser BG. Presentation of an acquired urea cycle disorder post liver transplantation. *Liver Transpl*. 2007;13(12):1714-1716.
- Andrews RK, Blakeley RL, Zerner B. Urea and urease. *Adv Inorg Biochem*. 1984;6:245-283.
- Torres-Rodriguez JM, Alvarado-Ramirez E, Gutierrez-Gallego R. [Urease activity in *Cryptococcus neoformans* and *Cryptococcus gattii*]. *Rev Iberoam Micol*. 2008;25(1):27-31.
- Feder V, Kmetzsch L, Staats CC, et al. *Cryptococcus gattii* urease as a virulence factor and the relevance of enzymatic activity in cryptococcosis pathogenesis. *FEBS J*. 2015;282(8):1406-1418.
- Cox GM, Mukherjee J, Cole GT, Casadevall A, Perfect JR. Urease as a virulence factor in experimental cryptococcosis. *Infect Immun*. 2000;68(2):443-448.
- De Oliveira HC. Fungal infections of the central nervous system. In: Zaragoza O, Casadevall A, eds. *Encyclopedia of Mycology*. Amsterdam, the Netherlands: Elsevier; 2021:736-748.
- Fu MS, Coelho C, De Leon-Rodriguez CM, et al. *Cryptococcus neoformans* urease affects the outcome of intracellular pathogenesis by modulating phagolysosomal pH. *PLoS Pathog*. 2018;14(6):e1007144.
- Maeda Y, Kawata S, Inui Y, Fukuda K, Igura T, Matsuzawa Y. Biotin deficiency decreases ornithine transcarbamylase activity and mRNA in rat liver. *J Nutr*. 1996;126(1):61-66.
- Nagamine T, Saito S, Kaneko M, et al. Effect of biotin on ammonia intoxication in rats and mice. *J Gastroenterol*. 1995;30(3):351-355.
- Tuchman M, Jaleel N, Morizono H, et al. Mutations and polymorphisms in the human ornithine transcarbamylase gene. *Hum Mutat*. 2002;19(2):93-107.
- Roberts SC, Bharat A, Kurihara C, et al. Impact of screening and treatment of ureaplasma species on hyperammonemia syndrome in lung transplant recipients: a single center experience. *Clin Infect Dis*. 2021;73(9):e2531-e2537.
- Bharat A, Cunningham SA, Scott Budinger GR, et al. Disseminated ureaplasma infection as a cause of fatal hyperammonemia in humans. *Sci Transl Med*. 2015;7(284):284re3.
- Masroujeh R, Teba CV. Severe hyperammonemia caused by *Cryptococcal meningitis*. *Am J Resp Crit Care Med*. 2018;197:A3355.
- Stewart AG, Sinclair H, Chapman P, Baboolal K, Barber BE, Townsend S. *Cryptococcus neoformans* infection as a cause of severe hyperammonemia and encephalopathy. *Intern Med J*. 2021;51(10):1750-1751.
- Hannah WB, Nizialek G, Dempsey KJ, et al. A novel cause of emergent hyperammonemia: *Cryptococcal fungemia* and meningitis. *Mol Genet Metab Rep*. 2021;29:100825.