

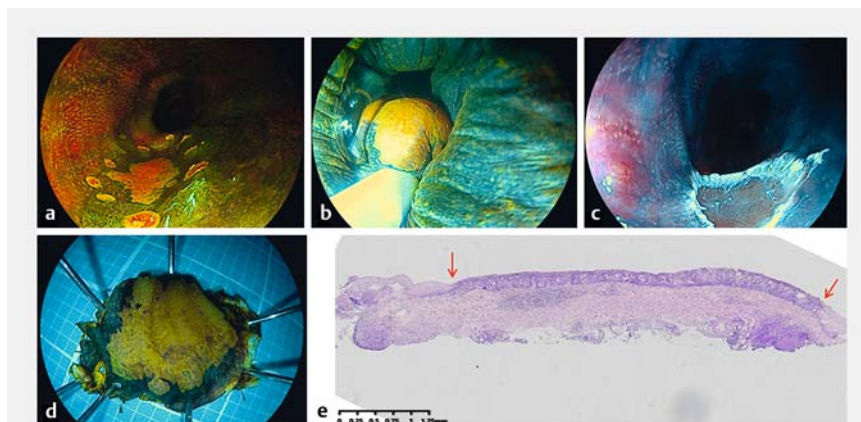
Spasmodic contraction induced by high concentration iodine staining to facilitate underwater endoscopic mucosal resection of early esophageal cancer

OPEN
ACCESS

A 61-year-old man was diagnosed with early esophageal cancer by endoscopy and pathological biopsy. The lesion of about 1 cm in diameter met the indications for endoscopic resection after pre-operative evaluation. The markers around the lateral margin of cancer were made by the snare tip with soft coagulation (Effect 5, 80 W) (► **Fig. 1 a**).

Conventional underwater endoscopic mucosal resection (UEMR) was attempted first and failed owing to the inability to fully snare the lesion. Therefore we stimulated the esophageal wall with a high concentration of 3% Lugol solution causing spasmodic contraction. UEMR was performed during spasmodic contraction, completely snaring the target lesion to obtain en bloc resection with an ENDO CUT Q (Effect 3, Cut duration 2, Cut interval 4) (Erbe Elektromedizin GmbH, Tübingen, German) (► **Fig. 1 b**). The wound was clean without bleeding or perforation (► **Fig. 1 c**). The fresh specimen was stretched and fixed on a foam plate, with R0 resection proved by the second iodine staining with a low concentration of 1% Lugol solution (► **Fig. 1 d**). Finally, the vitamin C solution was sprayed for deiodination. The post-resection histological findings revealed pathological lamina propria invasion (pT1a-LPM) and negative vertical and horizontal margins (► **Fig. 1 e**). The patient was discharged on the second day after the operation (► **Video 1**).

UEMR is becoming more and more popular for complete resection of gastrointestinal tumors but rarely reported for endoscopic resection of early esophageal cancer, which may be related to the difficulty to fully snare the lesion [1]. We propose that the spasmodic contraction-assisted UEMR technique may successfully and inexpensively be applied to deal with early esophageal cancer 1–2 cm in size.



► **Fig. 1** The process of spasmodic contraction induced by high concentration iodine staining to facilitate underwater endoscopic mucosal resection of early esophageal cancer. **a** The markers around the lateral margin of cancer were made by the snare tip with soft coagulation. **b** Underwater endoscopic mucosal resection was performed during spasmodic contraction caused by a high concentration of 3% Lugol solution to obtain en bloc resection. **c** The wound was clean without bleeding or perforation. **d** The fresh specimen was stretched and fixed. **e** The histological appearance of the resected specimen showed pathological lamina propria invasion (pT1a-LPM) and negative vertical and horizontal margins.

Endoscopy_UCTN_Code_TTT_1AO_2AG

Competing interests

The authors declare that they have no conflict of interest.

The authors

Chao Deng^{1*}, Suhua Wu^{1*}, Feng Xu¹, Li Zhong¹, Ying Huang², Zhechuan Mei¹, Song He¹

- 1 Department of Gastroenterology, The Second Affiliated Hospital of Chongqing Medical University, Chongqing, China
- 2 Department of Pathology, The Second Affiliated Hospital of Chongqing Medical University, Chongqing, China

* Contributed equally

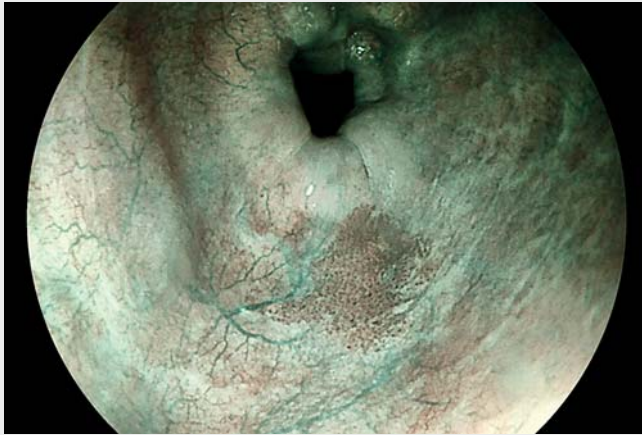
Corresponding author

Song He, MD

Department of Gastroenterology, The Second Affiliated Hospital of Chongqing Medical University, No. 76 Linjiang Road, Yuzhong District, Chongqing 400000, P.R. China
hedoctor65@cqmu.edu.cn

Reference

- [1] Maida M, Sferrazza S, Murino A et al. Effectiveness and safety of underwater techniques in gastrointestinal endoscopy: a comprehensive review of the literature. *Surg Endosc* 2021; 35: 37–51



Video 1 Spasmodic contraction-assisted underwater endoscopic mucosal resection of early esophageal cancer.

Bibliography

Endoscopy 2022; 54: E952–E953

DOI 10.1055/a-1883-9819

ISSN 0013-726X

published online 21.7.2022

© 2022. The Author(s).

This is an open access article published by Thieme under the terms of the Creative Commons Attribution-NonDerivative-NonCommercial License, permitting copying and reproduction so long as the original work is given appropriate credit. Contents may not be used for commercial purposes, or adapted, remixed, transformed or built upon. (<https://creativecommons.org/licenses/by-nc-nd/4.0/>)

Georg Thieme Verlag KG, Rüdigerstraße 14,
70469 Stuttgart, Germany



ENDOSCOPY E-VIDEOS

<https://eref.thieme.de/e-videos>



Endoscopy E-Videos is an open access online section, reporting on interesting cases and new techniques in gastroenterological endoscopy. All papers include a high quality video and all contributions are freely accessible online. Processing charges apply (currently EUR 375), discounts and wavers acc. to HINARI are available.

This section has its own submission website at
<https://mc.manuscriptcentral.com/e-videos>