

Phyllodes Tumors of the Breast

Osama Turki Abusaleem¹, Anwar Al-Masri²

Department of general Surgery, RMS, Irbid, Jordan¹

Department of Histopathology, RMS, Irbid, Jordan²

ORIGINAL PAPER

SUMMARY

Objective: To study all patients with phyllodes tumors of the breast which were diagnosed at King Hussien Medical Center and Prince Rashid Military Hospital between the 1st of may 2002 till January 2009. **Methods:** A total of 26 patients diagnosed to have phylloedes tumors were retrieved from the hospital records. All cases were analyzed and assessed in two main categories: demographical characteristics and histopathological parameters. The demographical characteristics included: sex and age of the patients, and tumor size while the histopathological aspects were divided into three subgroups: Benign, Borderline and Malignant tumors with its stromal components characteristics. All the histopathological reports for specimens sent by surgeons were reviewed by 2 senior pathologists. Statistical analysis was done by using Chi square and P-Value. **Results:** All our patients were females; their age range between 17-67 years, the mean patient age at presentation was 39 years. Out of the 26 patients diagnosed to have phyllodes tumor, 6 had breast-conserving therapy and 20 women had mastectomy. The types of Phyllodes tumors include: A-Benign phyllodes tumors (15 cases), B-Borderline phyllodes (7cases) and C-malignant phyllodes (4 cases). With significant values of benign tumors occurrence ($p < 0.01$), while borderline and malignant ones were not significant (NS) in comparison to the benign type. There were two cases below the age of 20 and one above the age of 65, with right breast involvement in eleven out of twenty six cases (42%), fifteen out of twenty six cases have involvement of the left breast (58%) and no cases found of bilateral phyllodes tumors of the breast. The greatest dimension of the tumors ranged from 1 to 15 cm, with a mean of 5 cm. Approximately 73.1% of tumors were less or equal to 5 cm in the greatest dimension and 26.9% >5 cm. The duration of symptoms varied from one month to ten years. Six patients had painful swellings, whereas in twenty patients the pain was absent. Four patients had recurrent tumors; the distinctive features of those with recurrent tumors were the histological findings of stromal over growth and the presence of positive resection margin. In our series, we found that three patients of those with recurrence discovered to have stromal over growth. While one only had a previous positive resection margin without stromal overgrowth. **Conclusion:** Rapid growth of phyllodes tumor does not necessarily imply malignancy. In our series, clinical tumor's size was not the significant factor for recurrence. Local recurrence occur in patients who were treated with breast-conserving surgery, and it is highly significant when there is stromal over growth (P value <0.01 and Chi square of 8.21) in comparison with the resection margin without stromal overgrowth (P value <0.1 and Chi square of 3.23) which gives a clue for further studies about the stromal factor role in recurrence of the tumor.

Key words: Breast, Cancer, Phyllodes tumor.

1. INTRODUCTION

The phyllodes tumor (PT), a lesion limited to mammary tissue, was first described by Muller in 1838. It is a rare condition, and its cause remains unclear (1). They make up 0.3 to 0.5% of female breast tumors and have an incidence of about 2.1 per one million women (2), the tumor is rarely found in adolescents and the elderly (3). The phyllodes tumor, like the fibroadenoma, arises from the intra-lobular stroma of the breast. Overall, they are rare tumors and represents 3% of fibroepithelial breast tumors and all are considered breast cancer, as even the benign form is regarded as having a malignant tendency or potential for metastasis (4). Management of the phyllodes tumor presents the surgeon with unique challenges.

Thus, these tumors are divided into benign, border line and malignant. They are variable in size and sometimes encompassing the entire breast. Grossly, there is lobulation of the tumor as the stroma proliferates resembling a leaf (phyllodes means leaf-like in Greek).

Tumors that do metastasize often do so to the lungs. Un-

like carcinomas of the breast, these tumors spread by blood vessel invasion bypassing the lymph nodes.

2. METHODS

We reviewed the pathological reports of 26 patients with Phyllodes tumor treated at King Hussien Medical Center (KHMC) as well as in Prince Rashid Military Hospital between the 1st of January 2002 till 1st of January 2009. those hospitals provide medical services for military personnel as well as civilians.

Diagnosis of this rare tumor was reviewed by two senior histopathologists at the laboratory of pathology and cytology division of Princess Iman Research laboratory sciences at KHMC.

All cases were analyzed and assessed in two main categories: demographical characteristics and histological parameters.

Demographical characteristics according to their age and sex of the patients and tumor size while histopathological aspect was splitted into three subgroups: benign,

borderline and malignant tumors including stromal components' characteristics.

3. RESULTS

Age of patients is showed on Table 1. All our patients were females; Patients' age ranged between 17 and 67-year-old, the mean age being 39-year-old . Two patients was 17 and 18-year-old (under 20 years) and had a benign tumor and two patients were 67-year-old, one having a benign tumor and the other a borderline phyllodes tumor (PT) (Figure 1).

Results show that 15 patients had benign tumors. The

Age groups (years)	Benign PT (15)	Borderline PT (7)	Malignant PT (4)	Total (26)
17-67 Years				
10-19	2	0	0	2
20-29	2	1	1	4
30-39	3	1	1	5
40-49	4	3	1	8
50-59	3	1	1	5
60-69	1	1	0	2
The lowest age	17	25	23	
The highest age	50	67	50	
The mean age(years)	37	42	41	39
Std. dev.	1.048809	0.983192	0.516398	2.250926

Table 1. Age distribution of Phyllodes Tumors Legend: PT - phyllodes tumor; Std. dev. - standard deviation.

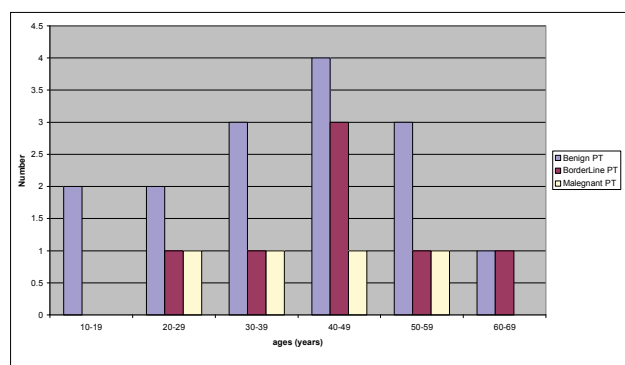


Figure 1.-Age distribution of Phyllodes Tumors

lowest age increased from benign PT-group progressively to malignant PT-group to borderline PT-group (17 to 23 and to 25-year old respectively). The highest age for patients with borderline PT was 67-year-old. The mean age of patients increased also from benign PT-group (37-year-old) to malignant PT-group (41-year-old), borderline PT-group having a mean age of (42-year-old).

Tumor site is presented on Table 2. Phyllodes tumors were more frequently situated in left breast than in the right side (58% vs. 42% respectively), and no cases found of bilateral phyllodes tumors of the breast.

Site	Benign	Borderline	Malignant	Total
Right	6	4	1	11
Left	9	3	3	15

Table 2. Phyllodes Tumor site

Cytopathological study

The cytopathological examination (Table 3) revealed in most of cases (15/26) aspects suggesting a benign fibroepithelial lesion. High cellularity fields were found in only four cases with definite malignant cellular features, suggesting a sarcomatous lesion.

Factor	Number of patients N = 26	% of patients
Surgical stump:		
Negative	25	96
positive	1	4
Stromal overgrowth:		
Absent	22	84.6
present	4	15.4
Histology:		
benign	15	57.7
borderline	7	26.9
malignant	4	15.4
Stromal cellular atypia:		
Mild	22	84.6
marked	4	15.4
Mitotic activity		
low (< 4 per 10 hpf)	15	57.7
Moderate (4-9 per hpf)	7	26.9
high (10 per 10 hpf)	4	15.4
Tumor size		
< 5cm	19	73.1
5cm	7	26.9

Table 3. Clinical and histological aspects of phyllodes tumor patients

Histopathological examination revealed that 11 out of the 17 cases with preoperative cytopathological examination were benign phyllodes tumors, 7 were borderline and 4 malignant.

Cytopathological study of the benign phyllodes tumors biopsy (Figure 2) shows cellular atypia was mild in most of patients , usually 1] but occasionally 2]stromal atypia, with

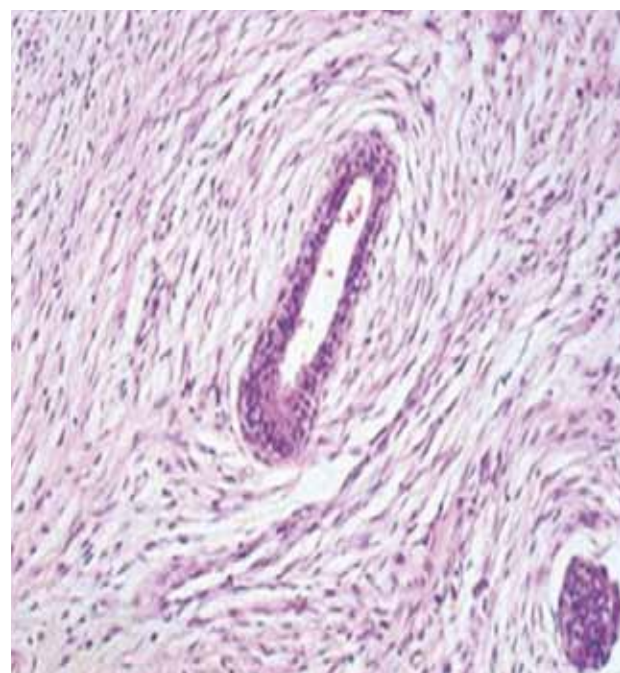


Figure 2 .Phyllodes tumor, benign. Note the contrasting stromal cellularity, and an epithelial-lined cleft in the tumor.

benign Fibro epithelial lesion in 13 out of the 15 benign phyllodes tumors specimens and high in only one case; while in one case presented with a scant cellularity. Stromal fragments were present at least one in every microscopic field. Semi-quantitative assessment revealed that the whole cases (fifteen cases) are characterized by few if any mitoses, moderate to marked cellular overgrowth, and slight to moderate cellular pleomorphism.

The cytopathological study of borderline phyllodes is presented on Figure 3.

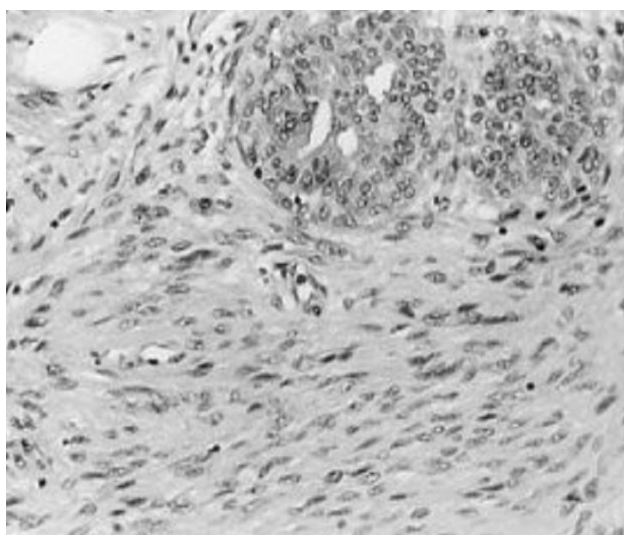


Figure 3. Low-grade malignant phyllodes tumor shows invasive borders.

An average of two to five mitoses per 10 high-power field, and moderate stromal cellularity that is heterogeneously distributed in hypocellular areas. The presence in variable proportions of sheets with epithelial cells with round edges and honeycomb features and also the presence of naked round monomorphic nuclei.

The cytopathological study of malignant phyllodes tumors is presented on Figure 4.

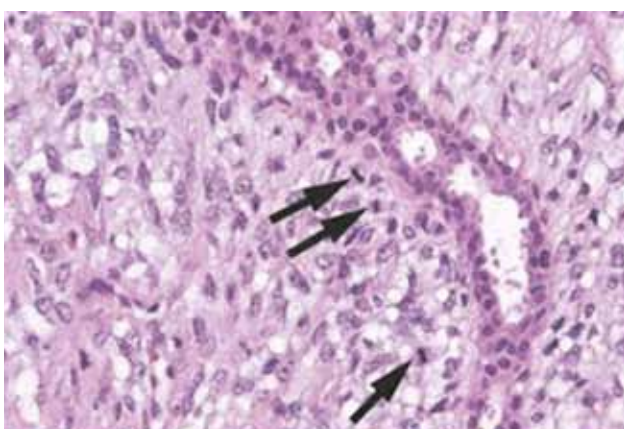


Figure 4. High-grade malignant phyllodes tumor.

Malignant phyllodes tumors show a marked degree of hypercellular stromal overgrowth, with more than 10 mitoses per high-power field, with sarcomatous component and have an invasive border; Stromal fragments were of variable dimensions, usually 3|stromal atypia (6) (Figure 5).

We noticed no epithelial elements on the smears. About 25% of phyllodes tumors metastasize (7). Although it is unanimously recognized that the cytology has an informative value, in our study the diagnostic accuracy was of 88.5%. There are authors who emphasized the importance of cytology in preoperative diagnosis of PT, reporting in their studies a 92.8% diagnostic accuracy (8).

Treatment

Of the 26 patients, 6 had breast-conserving therapy (Wide local excision with a safety margin) and 20 women had mastectomy (Table 4). The duration of symptoms varied from one month to ten year. Six patients had painful swellings whereas in twenty patients pain was absent.

Variable	NO.	%
Age (yr)		
Mean	39	////
Range	18-67	100%
< 40 years	11	42.3%
40 years	15	57.7%
Presenting symptom		
Lump	22	85%
Lump and pain	4	15%
Symptom duration		
<6mo	15	58%
6 mo-2 yr	5	19%
> 2 yr	4	15%
Unknown	2	8%
Clinical tumor size (mm)		
< 20	4	15%
20-50	15	58%
51-100	5	19%
> 100	2	8%
Palpable lymph nodes		
Yes	0	0%
No	26	100%
Metastasis at diagnosis	0	0%
Surgery		
Local excision	6	23%
Mastectomy (simple or radical)	20	77%
Adjuvant treatment		
None	25	96%
Radiation therapy	1	4%
Chemotherapy	0	0

Table 4. Clinical Descriptive Characteristics

Four patients had undergone resection of breast lumps previously. The diameter of the tumor mass: The greatest dimension of the tumors ranged from 1 to 15 cm, with a mean of 5 cm. Approximately (19 patients) 73% of tumors were 5 cm in the greatest dimension and (7 patients) 27%

	Stromal overgrowth	Resection margin	Total
Recurrence rate	3	1	4
P-VALUE	<0.01	<0.1	---
X2(Chi square)	8.21	3.23	---

Table 5. Recurrence Rate (P value is very significant if it is <0.05).

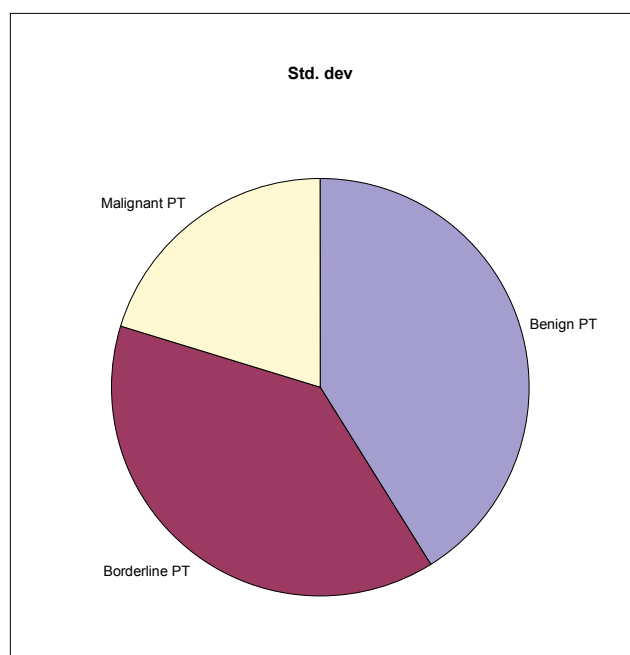


Figure 5. Benign, Borderline and Malignant Phyllodes tumors.

>5 cm (Table 4). Rapid growth of phyllodes tumor does not necessarily imply malignancy. In our series, clinical tumor size was not of a significant factor for recurrence. Local recurrence occurred in four patients (Table 5). It was controlled by additional surgery, in which the initial therapy had been a local excision. The recurrences occurred within 3 years after initial excision. Local recurrence was among patients who treated with breast-conserving surgery, three patients (75%) of those with tumor recurrence discovered to have stromal over growth (P value <0.01 and Chi square of 8.21) which is significant while one only had a previous positive resection margin without stromal overgrowth (P value <0.1 and Chi square of 3.23) which gives a clue for further studies about the stromal factor role in recurrence of the tumor.

We found that PT had a predilection for the left breast. There is little data in the literature concerning the tumor site. In some studies, the frequency of phyllodes tumors was higher in the left breast (left side 15-right side 11), (Figure 6) without any explanation of this fact or any correlation between the tumor type and site as in our series (12).

4. DISCUSSION

Pathologists and surgeons should have a healthy respect for phyllodes tumors. There is still confusion in the minds of surgeons and pathologists with respect to usefulness and accuracy of histologic assessment of malignancy. Phyllodes tumors (PTs) are rare fibro epithelial neoplasms with epithelial and cellular stromal components, the latter of which represents the neoplastic process. The presence of an epithelial component differentiates the phyllodes tumor from other stromal sarcomas, all tumors are more or less locally aggressive and some of them have the ability to metastasize.

Benign PT-group because this group had the highest number of cases, this is correlated with the world wide studies (5), In contrast, malignant PT-group had the small-

est standard deviation because this group had the narrowest range of ages as it has a reduced number of cases. The borderline group had a standard deviation between the other groups because it had a wide range of ages, this is in controversy for the world wide studies as malignant PT has the eldest age (5), while in our study it is in the borderline group (Table 1). Malignant and borderline phyllodes tumors can metastasize more frequently, but metastases of benign phyllodes tumors were also reported (9). In our series, PTs happened exclusively in females.

Phyllodes tumors mimic fibroadenomas and are often excised with close margins. Hyper cellular stromal fragments occur not only in Phyllodes tumor, but also in fibroadenoma, and hence they cannot be used as the sole criterion for making a diagnosis of Phyllodes tumor on FNA. It is important to remember that core biopsy specimens reported as fibroadenoma with subsequent excision showing phyllodes tumor represent < 1% (10).

No patient had associated axillary lymph nodes enlargement. Lymph node metastases are unusual and occur secondary to necrotic tumor. Our patients presented with

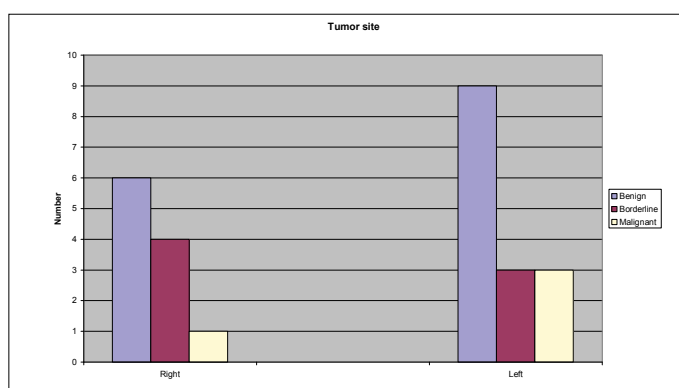


Figure 6. Phyllodes Tumor site distribution

a firm, mobile, well-defined, macrolobulated, and painless mass. There were no path gnomonic mammographic or ultrasound features. For this reason, early diagnosis of the phyllodes tumor is crucial so that the correct management of the tumor can be pursued as early as possible. This may also prevent the growth of phyllodes tumors into giant ones. The incidence of cystosarcoma phyllodes of the breast is apparently high (19 patients) in our series; One logical explanation for this phenomenon would be the increasing and effective use of screening methods for breast cancer in Jordan.

In one study it is shown that a pre-operative diagnosis of phyllodes tumors was definite in only 10 to 20% of patients, positive family history of breast carcinoma has been reported in nearly 50% of patients, with about 25% having a maternal first-degree relative affected (11). The average diameter of a benign tumor is 4 cm and that of malignant one is 6 cm (Table 4). Two patients in our series complained of sudden increase in size of pre-existing longstanding growth, yet both had benign disease. Thus, rapid growth does not necessarily imply malignancy. There is no relation between tumor size and histology was observed in our series.

We found that PT had a predilection for the left breast. There is little data in the literature concerning the tumor site. In some studies, the frequency of phyllodes tumors was higher in the left breast (15 vs. 11), (Figure 5) without any explanation of this fact or any correlation between the tumor type and site as in our series (12). Benign PT-group because this group had the highest number of cases, this is correlated with the world wide studies (5). In contrast, malignant PT-group had the smallest standard deviation because this group had the narrowest range of ages and also a reduced number of cases. The borderline group had a standard deviation between the other groups because it had a wide range of ages, this is in controversy for the world wide studies as malignant PT has the eldest age (5), while in our study it was the most in the border line group.

In our series, the mean age was 39 years, which is younger from the average worldwide age (45 years) (13).

One of The features related to local recurrence (Table 5) is the presence of tumor at surgical margins ($p < 0.1$) as is similarly reported by Neto (4). In our series, we found that three patients of those with recurrence (75%) (P value < 0.01) discovered to have stromal over growth. While one only (25%) (P value < 0.1) had a previous positive resection margin without stromal overgrowth, which gives a clue for further study about the stromal overgrowth role in recurrence of the tumor. Overall, the recurrence rate in our series was 15% (4 out of 26 cases). Histologic appearance (Table 6) may not, however, correlate with clinical behavior; some suggest genetic–molecular nature that causes the local relapse or distant metastasis (14). Our findings are similar to the histopathologic parameters of Oberman and Hart et al.” They used multiple criteria for malignancy including stromal overgrowth (which was considered the most important parameter), mitotic activity, infiltrative borders, stromal cellularity, and atypia (15).

Other authors suggested that several combinations of individual parameters could explain recurrence (16). Approximately 20%–50% of phyllodes tumors are reported to be malignant, some authors said that the usage of Magnatic Resonance Imaging (MRI) findings can be helpful in determining the histologic grade of phyllodes breast tumors preoperatively (17).

Because of the danger of an incomplete or inadequate excision, the surgeon is often faced with the need for mastectomy for phyllodes tumors that are huge sized tumors, 20 patients (77%) underwent mastectomy while 6 patients (23%) had a wide local excision.

Chest wall invasion appears to be an uncommon as no case in our series found to have chest wall invasion at the time of surgery. At a rate of 50% the malignant phyllodes tumors give metastasis to the bones and viscera, mainly hematogenously (18). Radical mastectomy is no longer applied, and because the tumor is hematogenously disseminated, resection of axillary lymph nodes is not justified (18). Also, the role of adjuvant radiotherapy remains uncertain and none of the patients who received chemotherapy developed distant disease (12). Tumor size has generally been considered to be of prognostic significance (18), but

the optimal cut-off value to distinguish between high-risk and low-risk tumors has remained controversial.” In our series, clinical tumor size was not a prognostic factor.

Excision of phyllodes tumors it is important to achieve a negative surgical margin for good local control. A phyllodes tumor with a positive surgical margin diagnosed based on excisional biopsy is likely to have a high local recurrence rate, particularly in cases with stromal overgrowth and a malignant tumor. Thus, in such cases we recommend ensuring inclusion of the tumor margin by re-excision.

Two patients in our series complained of sudden increase in size of pre-existing longstanding growth, yet both had benign disease. Thus, rapid growth does not necessarily imply malignancy. Routine axillary lymph node dissection does not appear to be indicated. While rare instances of axillary lymph node metastases have been reported (19), no lymph node metastases were identified in our patient population.

Today, recent studies upon estrogen and progesterone receptors in these tumors seem to provide hopeful results, useful for the hormonal management of phyllodes tumor (20).

In excision of phyllodes tumors it is important to achieve a good local control, in such cases of phyllodes tumor with stromal overgrowth and a malignant tumor is likely to have a high local recurrence, Thus, in such cases we recommend ensuring inclusion of the tumor margin by re-excision.

5. CONCLUSION

Phyllodes tumor is a subject of considerable interest because of its not uncommon occurrence and varied histological pattern.

This study for the 1st time reports the pathological features of phyllodes tumor in Jordan. Rapid growth of phyllodes tumor does not necessarily imply malignancy. In our series, clinical tumor size was not of a significant factor for recurrence.

Local recurrence occur in patients who treated with breast-conserving surgery, and is highly significant when there is stromal over growth (P value < 0.01 and Chi square of 8.21) in comparison with the resection margin without stromal overgrowth (P value < 0.1 and Chi square of 3.23) which gives a clue for further studies about the stromal factor role in recurrence of the tumor.

Acknowledgment:

Special thanks to the department of Breast Unite at KHMC and to Dr. Ali Elbose for the valuable help in this research.

REFERENCES

1. Mangi AA, Smith BL, Gadd MA, Tanabe KK, Ott M J, Souba WW, Surgical Management of Phyllodes Tumors . Arch Surg. 1999; 134: 487-473.
2. Bernsfein L, Deapen DPH, Ross RK, The Descriptive Epidemiology of Malignant Cystosarcoma Phyllodes Tumors of the Breast. Cancer. 1993; 71: 302-304.
3. Liang MI, Ramaswamy B, Patterson CC, McKelvey MT, Gordillo G, Nuovo GJ, et al. Giant breast tumors: Surgical management of phyllodes tumors, potential for reconstructive surgery and a review of literature. World Journal of Surgical Oncology. 2008, 6: 117..

4. Neto JJDA, Terra RM, Fernandez A, Rawet V, et al. Case Reports. Full-Thickness Chest Wall Resection for Recurrent Breast Phyllodes Tumor. *Ann Thorac Surg.* 2007; 83: 2196-2197.
5. Patrascu A, Popescu CF, Plesea IE, Badulescu A, Tanase F, Mateescu G, Clinical and cytopathological aspects in phyllodes tumors of the breast. *Romanian Journal of Morphology and Embryology.* 2009, 50(4): 605–611.
6. Chen WH, Cheng SP, Tzen CY, et al. Surgical Treatment of Phyllodes Tumors of the Breast: Retrospective Review of 172 Cases. *Journal of Surgical Oncology.* 2005; 91: 185–194.
7. Goel NB, Knight TE, Pandey S, et al. Fibrous Lesions of the Breast: Imaging-Pathologic Correlation. *RadioGraphics.* 2005; 25: 1547-1559.
8. Jayaram G, Sthaneshwar P. Fine-needle aspiration cytology of phyllodes tumors, *Diagn Cytopathol.* 2002; 26(4): 222–227.
9. Rowell MD, Perry RR, Hsiu JG, Barranco SC. Phyllodes tumors. *Am J Surg.* 1993, 165(3): 376–379.
10. Lee AHS, Hodi Z, Ellis IO, Elston CW. Histological features useful in the distinction of phyllodes tumour and fibroadenoma on needle core biopsy of the breast. *Histopathology* 2007, 51: 336-344.
11. Rosen Peter P. Unusual Clinical Presentations of Carcinoma. *Rosen's Breast Pathology*, 3rd Edition, Chapter 33, Lippincott Williams & Wilkins, 2009.
12. Chaney AW, Pollack A, Mcneese MD, Zagars GK, Pisters PWT, et al. Primary Treatment of Cystosarcoma Phyllodes of the Breast. June 15, 2000. *Cancer.* 2000; 89: 1502–11.
13. Parker SJ, Harries SA. Phyllodes tumours. *Reviews. Postgrad Med J.* 2001; 77: 428–435.
14. Roa JC, Tapia O, Carrasco P, et al. Prognostic factors of phyllodes tumor of the breast. *Pathology International.* 2006; 56: 309–314.
15. Cohn-Cedermark G, Rutqvist LE, Rosendahl I, Silfversward C, Prognostic Factors in Cystosarcoma Phyllodes A Clinico-pathologic Study of 77 Patients, *Cancer.* 1991; 68: 2017-2022.
16. Abdalla HM, Saker MA. Predictive Factors of Local Recurrence and Survival Following Primary Surgical Treatment of Phyllodes Tumors of the Breast, *Journal of the Egyptian Nat. Cancer Inst.* 2006; 18(2): 125-133.
17. Yabuuchi H, Soeda H, Matsuo Y, Okafuji T, et al. Phyllodes Tumor of the Breast: Correlation between MR Findings and Histologic Grade. *Radiology.* 2006; 241: 702-709.
18. Stamatakos M, Tsaknakil S, Kontzoglou K, Gogas J, Kostakis A, Safioleas M. Phylloides tumor of the breast: a rare neoplasm, though not that Innocent. *BioMed Central.* Page 1 of 4. *International Seminars in Surgical Oncology. International Seminars in Surgical Oncology 2009, 20 February 2009.*
19. Noms HJ, Taylor HB. Relationship of histologic features to behavior of cystosarcoma phyllodes: Analysis of ninety-four cases. *Cancer.* 1967; 20: 2090-2099.

Corresponding author: Osama Abu Salem, MD. Department of general surgery, RMS, Irbid, Jordan. P.O.Box:620033. Tel. + 0777905757. E-mail:osamaabu-salem@hotmail.com
