

Critical heart rate and left bundle-branch block resolution in anesthesia

Madam,

Left bundle-branch block (LBBB) occurs when there is a block in the conduction pathway of the left bundle branches. LBBB can be described as transient, intermittent, or permanent. Transient BBB can be caused by a phase 3 block, a phase 4 block, or a concealed conduction.^[1] Disease processes associated with LBBB include hypertension, coronary heart disease, hyperkalemia, idiopathic degeneration of conduction tissue, cardiomyopathy, valvular abnormalities, myocarditis, infective endocarditis, and trauma or cardiac surgery.^[1,2] Of these, LBBB is most often a result of coronary heart disease and hypertension.^[3] This case report describes a scenario in which an LBBB transiently converts to normal sinus rhythm with the induction of general anesthesia and reverts back to LBBB upon emergence from anesthesia.

A 50-year-old female with chronic back pain presented for a minimally invasive L4/L5 transforaminal lumbar interbody

fusion. An electrocardiogram (ECG) from 5 months prior to her preoperative evaluation was interpreted as normal sinus rhythm (NSR) with heart rate (HR) 75 beats per minute (bpm) [Figure 1]. A subsequent ECG a week prior to surgery demonstrated LBBB at HR of 76 bpm [Figure 2]. A preoperative stress test with myocardial perfusion imaging was negative for inducible ischemia. All preoperative laboratories including electrolytes and blood counts were within normal limits.

Prior to induction of anesthesia, the LBBB was appreciated at HR of 84 bpm. Upon induction, LBBB was no longer appreciated on telemetry [Figure 3] until extubation and arrival at post anesthesia care unit (PACU) [Figure 4]. Standard American Society of Anesthesiologists (ASA) monitors were used intraoperatively. Minimum blood pressure in the surgery was 86/60 mmHg with a HR of 55 bpm. Maximum blood pressure was 137/71 mmHg with a HR of 78 bpm. There were no intraoperative complications, hemodynamic instability, or ventilatory difficulties. Blood loss estimated to be 25 ml, urine 100 ml, and crystalloids 900 ml.

The patient was transported to PACU, where the initial vital signs demonstrated a HR of 102 bpm, BP 139/91 mmHg,

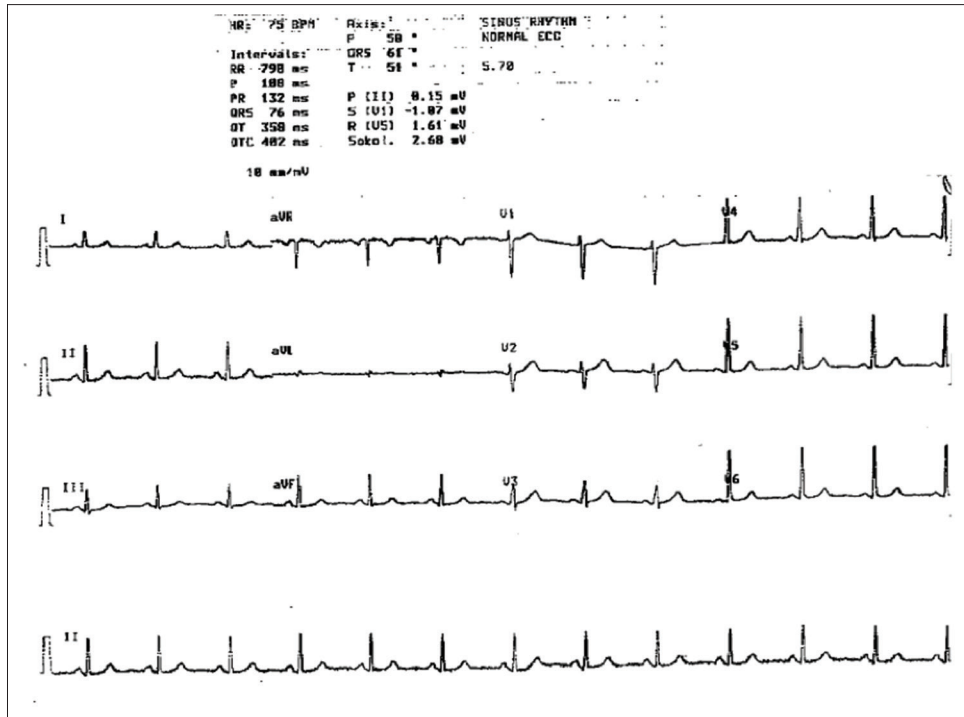


Figure 1: EKG 01/18/16

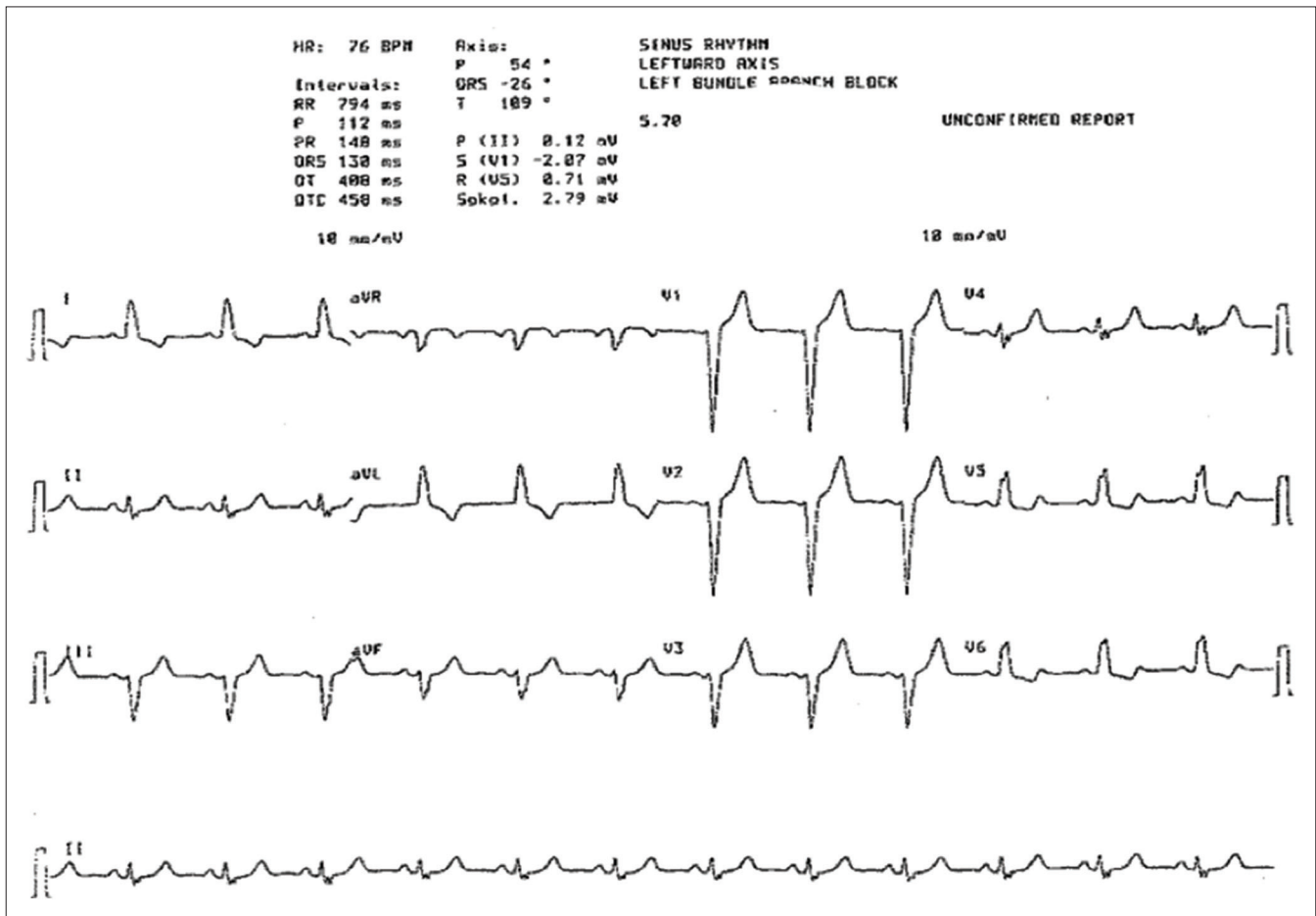


Figure 2: EKG: 06/15/16 (preoperative)

and O₂ sat 100%. PACU telemetry demonstrated a reversion back to the initial LBBB.

The following day, postoperative ECG showed NSR with a HR of 86 bpm and an LBBB [Figure 5].

LBBB most often presents secondary to myocardial ischemia. This is unlikely the cause of LBBB in our patient given she had a negative cardiac workup and was asymptomatic from a cardiac standpoint. The likely cause for the transient disappearance of the LBBB during anesthesia in our case

appears to have been aberrant conduction of supraventricular signals (phase 3 block). Constantini described a “critical heart rate,” defined as the HR at which an LBBB is produced. He noted that a change in HR of plus or minus 1 bpm could cause an appearance or disappearance of a BBB.^[4] LBBB was not evident when the patient’s HR was less than 76 bpm. Consequently, a HR of 76 may be the “critical heart rate” at which point, an LBBB is induced.

Opioids were used throughout the surgical procedure and were the likely agents that maintained this patient’s HR below 76 bpm. Opioids are vagotonic and cause bradycardia through depression of sinoatrial node function. These properties of opioids in anesthesia may have produced results similar to those seen in Herrmann and Ashman’s case series in which vagal maneuvers caused conversion of an LBBB to a normal sinus rhythm.^[5] Further electrophysiological evaluation of the patient’s heart would be necessary to determine whether this hypothesis is true. However, this datum is not available. In the future, further investigations should be considered to see whether or not an element of general anesthesia may activate these aberrant pathways.

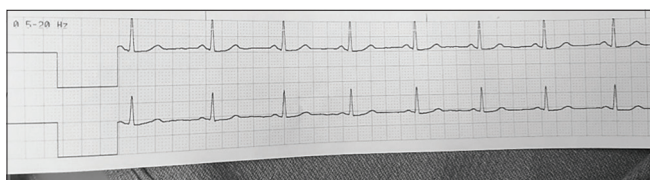


Figure 3: Lead 2, V5 rhythm strip after induction 06/21/16

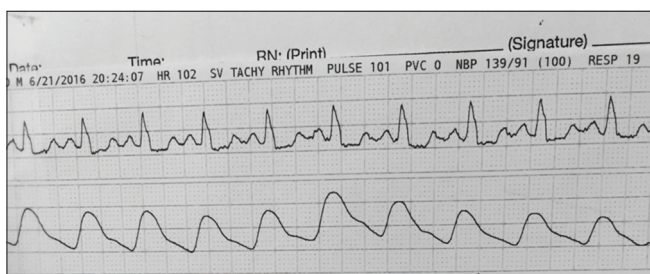


Figure 4: Recovery room rhythm strip on 06/21/16

Declaration of patient consent

The authors certify that they have obtained all appropriate patient consent forms. In the form the patient has given her consent for her images and other clinical information to be reported in the journal. The patient understands that her name and initials will not be published and due efforts will be made to conceal her identity, but anonymity cannot be guaranteed.

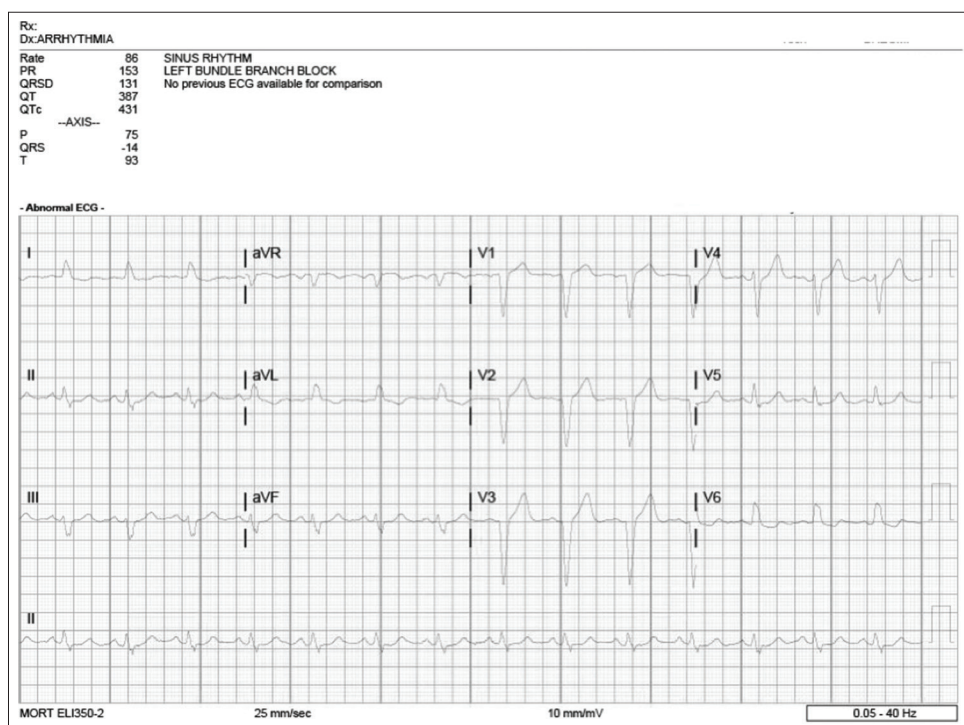


Figure 5: EKG 06/22/16 (postoperative)

Financial support and sponsorship

Nil.

Conflicts of interest

There are no conflicts of interest.

Jeremy Laney, Thang Tran, Arash Motamed

Department of Anesthesiology, Keck School of Medicine, University of Southern California, San Pablo Street, Suite, Los Angeles, CA, USA

Address for correspondence: Dr. Jeremy Laney,
Department of Anesthesiology, Keck School of Medicine, University
of Southern California, 1450 San Pablo Street, Suite, Los Angeles,
CA - 90033, USA.

E-mail: jeremy.laney@med.usc.edu

References

1. Bazoukis G, Tsimos K, Korantzopoulos P. Episodic left bundle branch block-a comprehensive review of the literature. *Ann Noninvasive Electrocardiol* 2016;21:117-25.
2. Garcia EJ, Kumar CM, Lawler PG, Newnam PT. Spontaneous remission of left bundle branch block during anaesthesia. *Anaesthesia* 1997;52:684-7.
3. Ting PC, Lin TS, Yang MW, Ho AC. Spontaneous remission of left bundle branch block immediately after denitrogenation with inhalation of 100% oxygen prior to anesthetic induction. *Acta Anaesthesiol Taiwan* 2010;48:140-4.
4. Costantini M. Intermittent bundle branch block: a clinical model for the study of electrophysiological phenomena. *G ItalCardiol (Rome)* 2014;15:25-36.
5. Herrmann G, Ashman R. Partial bundle-branch block: A theoretical consideration of transient normal intraventricular conduction in the presence of apparently complete bundlebranch block. *Am Heart J* 1931;6:375-403.

This is an open access journal, and articles are distributed under the terms of the Creative Commons Attribution-NonCommercial-ShareAlike 4.0 License, which allows others to remix, tweak, and build upon the work non-commercially, as long as appropriate credit is given and the new creations are licensed under the identical terms.

Access this article online	
Quick Response Code:	Website: www.joacp.org
	DOI: 10.4103/joacp.JOACP_197_18

How to cite this article: Laney J, Tran T, Motamed A. Critical heart rate and left bundle-branch block resolution in Anaesthesiol. *J J Anaesthesiol Clin Pharmacol* 2020;36:282-5.

Submitted : 19-Jun-2018 **Revised:** 27-Mar-2019 **Accepted:** 11-Jul-2019
Published: 15-Jun-2020

© 2020 Journal of Anaesthesiology Clinical Pharmacology | Published by Wolters Kluwer - Medknow