



Active septic arthritis of the hip in adults: what's new in the treatment? A systematic review

Fabio D'Angelo¹

Luca Monestier²

Luigi Zagra³

- Treatment of bacterial septic arthritis in the native adult hip joint can be challenging. Prompt diagnosis and treatment decisions can reduce the associated morbidity and mortality.
- For this systematic review of the literature, we asked: (1) What are the treatment options? (2) What are the success rates and the outcomes after treatment? (3) Which antibiotic and duration of therapy are optimal?
- We searched the electronic databases PubMed, Scopus, and Embase using the search terms “hip” or “native hip” and “septic arthritis” or “coxitis”. Studies were included if they reported on: (1) bacterial infection of the hip, (2) treatment, (3) success rate/outcomes, (4) follow-up. The final review included 19 studies. The quality of study reporting was evaluated with the Methodological Index for Non-randomized Studies (MINORS) questionnaire.
- Three treatment options are: arthroscopy, single open surgery, and two-stage total hip arthroplasty (THA). A high success rate in infection eradication was reported for all three. Intravenous antibiotic therapy should be promptly initiated to eradicate septic arthritis and minimize potential sequelae and complications.
- Arthroscopy, single open or two-stage THA were reported to be effective in treating bacterial septic arthritis of the native hip. The key to optimal outcome is early diagnosis and timely treatment.

Keywords: hip arthritis; septic arthritis; treatment

Cite this article: *EFORT Open Rev* 2021;6:164-172.

DOI: 10.1302/2058-5241.6.200082

Background

Treatment of bacterial septic arthritis in the native adult hip poses distinct challenges. The yearly incidence is

estimated at about 4–10 per 100,000 patients worldwide; however, its real incidence is difficult to quantify.^{1–3} The estimated mortality rate due to complications of bacterial arthritis is about 11%. Since bacterial sepsis can rapidly destroy the hip joint, prompt diagnosis and treatment are pivotal in management of the infection:¹ hospital admission for assessment, intravenous antibiotic therapy, and surgical treatment as deemed necessary.

Most studies concern septic arthritis in the adult native knee joint. But, as occurs in other joints (shoulder, sternoclavicular or wrist), bacterial arthritis of the hip differs in pathogenesis and diagnosis. The literature includes mainly case reports on hip arthritis while a few case series/retrospective cohort studies have been published in the last 20 years. Since the presentation and outcomes in adults differ from those in children, combining both groups can confound the study data. While the immunocompromised (diabetes, HIV, drug and alcohol abuse) are at greater risk for septic arthritis, occasionally healthy young adults can also be affected.⁴ Prompt diagnosis can be challenging. Delayed diagnosis beyond three weeks, besides host type and polymicrobial infection, are strong predictors of sacrificing the joint.⁵ Reinfection rates are high and make repeat surgery necessary.⁶ Advanced age, high preoperative C-reactive protein level, and resistant organism profile are other predictors for failure.⁷ Differential diagnosis of septic arthritis with other arthropathies (e.g. aggressive inflammatory arthritis, avascular femoral head necrosis or osteoarthritis) is difficult; nonetheless, timely diagnosis is crucial as these joint diseases can lead to sepsis and result in unsuccessful outcome.

In 1928, Girdlestone first described resection arthroplasty for the treatment of tuberculous and pyogenic arthritis of the hip by complete removal of the proximal part of the femur and debridement of the surrounding tissues.⁸ While hip resection arthroplasty may eradicate the infection, the sequelae include limp, length discrepancy, and partial pain relief. Although modified over the years, Girdlestone's procedure remains a viable option

Table 1. Search terms for septic arthritis in the hip joint

Search terms	PubMed	Embase	Scopus
"Hip/" OR "Hip native/" AND "septic arthritis/" OR "coxitis/"	N = 1204	N = 200	N = 2522

for treating septic arthritis of the adult hip in selected patients. Recent advances in treatment include antibiotic-loaded cement spacers, total hip arthroplasty (THA), and arthrotomic or arthroscopic toilette.

With this systematic review of the literature we wanted to address three questions about the treatment of bacterial arthritis in the native hip of adult patients: (1) What are the treatment options? (2) What are the success rates and the outcomes after treatment? (3) Which antibiotic and duration of therapy are optimal?

Methods

Search strategy and criteria

For this systematic review we searched the electronic databases PubMed, Scopus, and Embase using the search terms: "hip" or "native hip" and "septic arthritis" or "coxitis" (Table 1). The search was limited to articles published in the past 20 years because few case reports were published before 2000 and most case series or cohort studies have appeared since then. Articles were reviewed according to the Preferred Reported Items for Systematic Reviews and Meta-Analyses Statement for Individual Patient Data (PRISMA-IPD).⁹

The research questions, inclusion and exclusion criteria were decided a priori. The inclusion criteria included human studies published in English and studies on the treatment of bacterial septic arthritis of the native hip. Exclusion criteria were: septic arthritis in children; infection after hip arthroplasty; avascular necrosis of the femoral head; tubercular or fungal infection; rheumatic disease; septic arthritis involving other joints (knee, shoulder, sternoclavicular, wrist, pubic symphysis); tumours; hip osteoarthritis or impingement; hip dysplasia; not a systematic review; studies on animals/cadavers; epidemiologic studies; aseptic disease.

Study screening

After excluding the duplicates, two reviewers (FD, LM) screened the title, abstract, and full text of each study. Disagreements were solved by discussion after full-text evaluation. The reference lists of the studies were manually searched for other publications that may have eluded the initial search.

Search results

A total of 3926 articles were retrieved for preliminary evaluation (Fig. 1). After the duplicates were eliminated, 3081

original articles remained. Two authors (FD, LM) reviewed the titles: 2939 studies were excluded because they did not meet the inclusion criteria and 19 because they were published in a language other than English. After the abstracts were reviewed, 102 studies were excluded because they did not meet the inclusion criteria. Of the remaining 21 articles, ten were excluded after evaluation of the full text. Eight articles were added to 11 eligible studies from their references, for an end total of, 19 studies in the final analysis and quality assessment. All 19 studies reported data on treatment of bacterial septic arthritis in the adult native hip (first research question); on success rates and outcomes after surgery (second research question); 17 reported data on antibiotic regimen and its duration (third research question).

Assessment of study quality

Two reviewers (FD, LM) independently evaluated each study for quality. For this systematic review, the Methodological Index for Non-randomized Studies (MINORS) questionnaire was used.¹⁰ The final analysis included retrospective case-control studies ($n = 3$), retrospective case series ($n = 14$), a systematic review and a prospective study ($n = 1$ each) (Table 2). The mean MINORS score for retrospective case series was 11/16 (range, 7–13); the MINORS score for the case-control studies was 17/24 (range, 15–21). The inclusion of only one prospective study was the main study quality deficiency.

Data collection

Data from each study included number of patients, sex, age, follow-up, pathogen, treatment, success rate, outcomes, and complications (Table 3). The studies were grouped and compared by treatment: arthroscopy, two-stage open treatment, one-stage open treatment (Tables 4, 5 and 6). Complications associated with treatment were assessed; the range is reported.

Results

Treatment options

Treatment options for bacterial arthritis of the native hip can be grouped into three categories:

1. Arthroscopic treatment (Table 4): hip arthroscopy is performed in standard supine position with a three-portal (anterior, anterolateral, posterolateral) procedure.^{13,15,18,19,25} Yamamoto et al describe the use of three different arthroscopes, each from a single portal.¹⁹ After gentle distraction, a 70° arthroscope and then a 30° arthroscope is inserted.^{13,15,18} Lee et al suggest mixing 1 mL 0.1% epinephrine solution to the saline fluid to obtain a more precise

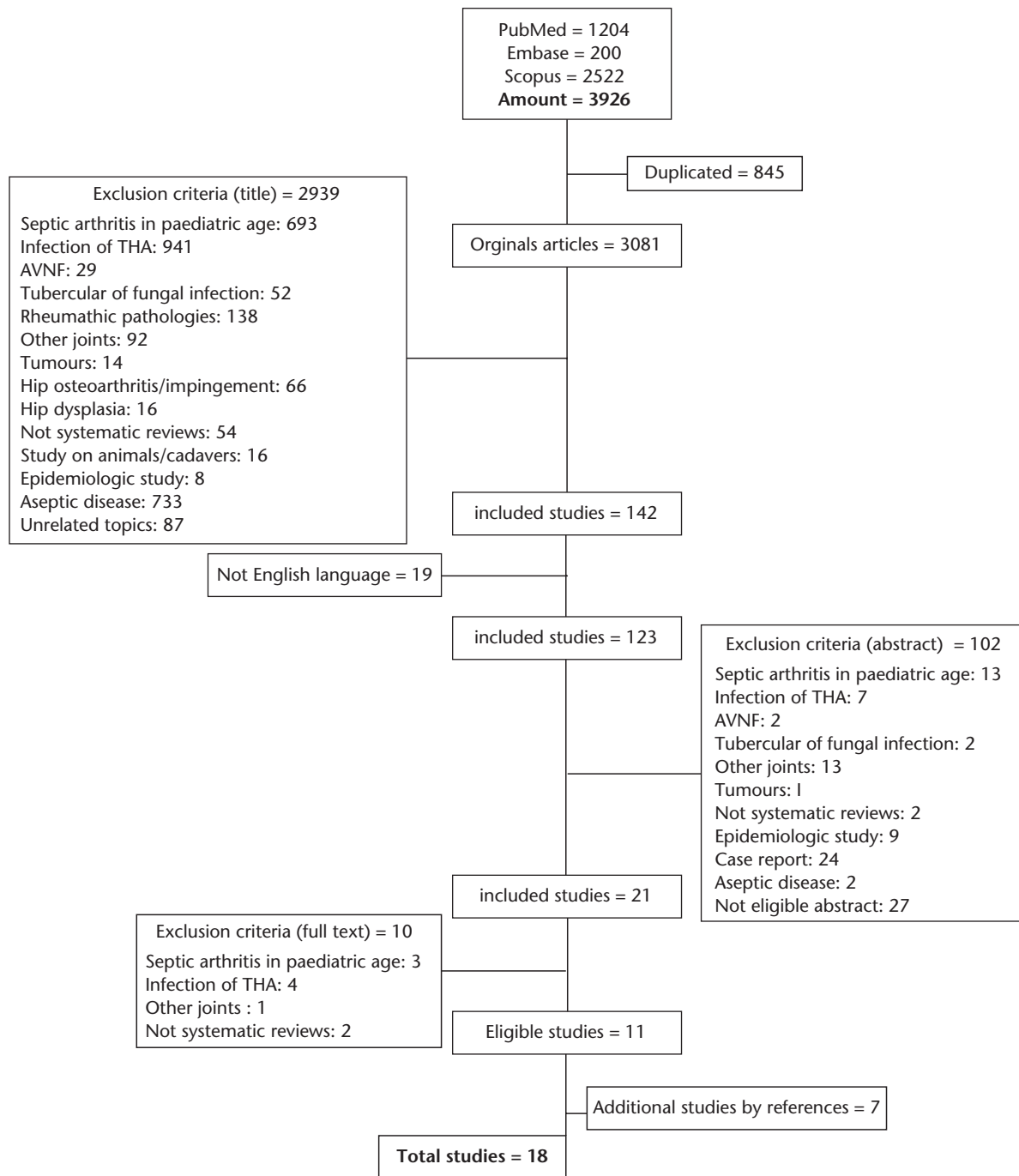


Fig. 1 Study flowchart.

Note. THA, total hip arthroplasty; AVNF, AVascular Necrosis of Femoral head

view.¹⁵ There is no a defined regimen for irrigation volume: Nusem et al¹⁸ use 6–8 L of saline solution, while other authors reported using more than 20 L.^{13,19,25} One or two suction drainages are usually positioned and then removed 2–3 days later.^{15,18,25} Kim et al describe drain removal after 5–14 days.¹³ Tolerable weight-bearing with crutches and

unrestricted range of motion exercise are allowed immediately.^{13,15,18,25} Yamamoto et al permit weight-bearing after three weeks.¹⁹

- Two-stage treatment (Table 5): the first stage entails debridement of the infected tissues, resection arthroplasty of the proximal femur followed by implantation of an antibiotic-loaded cement spacer

Table 2. Authors, journal, publication year, type of study, and MINORS score

First author	Journal	Year of publication	Study design	Control group	MINORS score
Khazi ZM ¹¹	<i>Arthroscopy</i>	2020	Retrospective case control	Arthrotomy	15/24
Kao FC ¹²	<i>Medicine (Baltimore)</i>	2019	Retrospective case serie	NO	13/16
Kim CH ¹³	<i>HIP International</i>	2018	Retrospective case serie	NO	11/16
Ohtsuru T ¹⁴	<i>HIP International</i>	2016	Retrospective case control	Arthroscopy/ debridement/ resection/spacer	15/24
Anagnostakos K ⁶	<i>Archives of Orthopaedic and Trauma Surgery</i>	2016	Retrospective case serie	NO	7/16
Lee YK ¹⁵	<i>Knee Surgery, Sports Traumatology, Arthroscopy</i>	2014	Retrospective case serie	NO	13/16
Fleck EE ¹⁶	<i>Clinical Orthopaedics and Related Research</i>	2011	Retrospective case serie	NO	10/16
Kelm J ¹⁷	<i>International Journal of Medical Sciences</i>	2009	Retrospective case serie	NO	12/16
Nusem I ¹⁸	<i>Arthroscopy</i>	2006	Retrospective case serie	NO	8/16
Yamamoto Y ¹⁹	<i>Arthroscopy</i>	2001	Retrospective case serie	NO	8/16
de Sa D ²⁰	<i>Arthroscopy</i>	2015	Systematic review	NO	
Chen CE ²¹	<i>International Orthopaedics</i>	2008	Retrospective case serie	NO	13/16
Shen H ²²	<i>Orthopedics</i>	2013	Retrospective case serie	NO	12/16
Cho YJ ²³	<i>Journal of Arthroplasty</i>	2018	Retrospective case serie	NO	10/16
Huang TW ²⁴	<i>Journal of Trauma</i>	2010	Retrospective case serie	NO	10/16
Schröder JH ²⁵	<i>Advances in Orthopedics</i>	2016	Retrospective case serie	NO	13/16
Romanò CL ⁴	<i>BMC Infectious Disorders</i>	2011	Prospective cohort	NO	12/16
Kelm J ²⁶	<i>International Journal of Medical Science</i>	2009	Retrospective case serie	NO	10/16
Papanna MC ²⁷	<i>HIP International</i>	2018	Retrospective case control	THA without spacer	21/24

Note. MINORS, Methodological Index for Non-randomized Studies; THA, total hip arthroplasty.

Table 3. Clinical data

First author	No. patients	Age (yrs)	Sex	Follow-up (mths)	Pathogen	Treatment	Antibiotic	Antibiotic duration
Khazi ZM ¹¹	421	n.a.	M 222, F 199	Not reported	MSSA	387 arthrotomy, 34 arthroscopy	Not reported	Not reported
Kao FC ¹²	51	58.7	M 32, F 19	48.8	MSSA 3.9%, other 13.8%, multiple organisms 3.9%, not identified 78.4%	Debridement only 12, hip disarticulation 1, resection arthroplasty 38, cement spacer 28, THA 14	Empiric antibiotic therapy, depending on sensitivity	85 dys
Kim CH ¹³	7	50.9	M 4, F 3	16.0	MSSA 42.9%, <i>S. agalactiae</i> 14.2%, not identified 42.9%	Arthroscopy	Empiric antibiotic therapy, depending on sensitivity	4–6 wks
Ohtsuru T ¹⁴	15	55.9	M 9, F 6	Not reported	MRSA 33.3%, MSSA 20.0%, other 40.0%, not identified 6.66%	Group A: arthroscopy, debridement, resection arthroplasty, spacer 10; musculocutaneous flap transposition 5	Vancomycin	4 wks intravenous + 2 wks oral
Anagnostakos K ⁶	22	59.7	M 11, F 11	44.8	MSSA 72.7%, not identified 27.3%	Two stage: moduled spacer + THA	Empiric antibiotic therapy, depending on sensitivity	6 wks
Lee Y ¹⁵	9	45.0	M 4, F 5	18.0	MSSA 44.4%, not identified 55.6%	Arthroscopy	Empiric antibiotic therapy, depending on sensitivity	4–6 wks
Fleck EE ¹⁶	14	60.8	M 7, F 7	50.0	MSSA 35.7%, MRSA 21.4%, other 21.4%, not identified 21.4%	Prostalac spacer	Empiric antibiotic therapy, depending on sensitivity	6 wks
Kelm J ¹⁷	28	71.0	M 11, F 17	36.0	MSSA 10.7%, MRSA 10.7%, <i>S. epidermidis</i> 25.0%, other 32.2%, not identified 21.4%	VAC therapy	Empiric antibiotic therapy, depending on sensitivity	2 wks intravenous + 2 wks oral
Nusem I ¹⁸	6	24.0	M 3, F 3	22.0	MSSA 66.6%, other 16.7%, not identified 16.7%	Arthroscopy	Empiric antibiotic therapy, depending on sensitivity	3 wks intravenous + 3 wks oral
Yamamoto Y ¹⁹	4	59.0	M 1, F 3	32.0	MSSA 50.0%, other 50.0%	Arthroscopy	Cefazolin + Cefdinir	1 wk Cefazolin oral + 1 wk Cefdinir 300 mg oral
de Sa D ²⁰ Chen CE ²¹	28	53.0	M 22, F 6	77.0	MSSA 21.4%, MRSA 28.6%, other 50.0%	Resection arthroplasty + THA 14; resection arthroplasty + gentamycin spacer + THA 14	Empiric antibiotic therapy, depending on sensitivity	4 wks
Shen H ²²	5			39.6	Not reported	Spacer + THA	Not reported	6 wks

(Continued)

Table 3. (Continued)

First author	No. patients	Age (yrs)	Sex	Follow-up (mths)	Pathogen	Treatment	Antibiotic	Antibiotic duration
Cho YJ ²³	9 (10 hips)	44.6	M 5, F 4	44.9	MSSA 40.0%, other 20.0%, not identified 40.0%	Spacer + THA	Vancomycin 1 g + Cefazedone 1 g	Twice for 3 wks intravenous + 3 wks oral
Huang TW ²⁴	14 (15 hips)	54.3	M 9, F 5	42.5	MSSA 28.6%, MRSA 28.6%, other 21.4%, not identified 21.4%	Spacer	Empiric antibiotic therapy, depending on sensitivity	1 wk intravenous
Schröder JH ²⁵	7	44.0	M 4, F 3	27.0	MSSA 28.2%, other 43.8%, not identified 28.2%	Arthroscopy	Empiric antibiotic therapy, depending on sensitivity	4 wks intravenous
Romanò CL ⁴	19 (20 hips)	55.7	M 9, F 10	56.6	MSSA 35.0%, MRSA 20.0%, other 25.0%, not identified 20.0%	Spacer G	Empiric antibiotic therapy, depending on sensitivity	4–6 wks
Kelm J ²⁶	10	66.0	M 5, F 5	57.6	MSSA 13.9%, 1 MRSA, 1 streptococcus, 3 not identified	Spacer + THA	Empiric antibiotic therapy, depending on sensitivity	6 wks
Papanna MC ²⁷	36	58.0	M 21, F 15	70.0	MSSA 33.3%, MRSA 2.78%, other 2.78%, not identified 61.1%	Group A: resection arthroplasty, spacer + THA; Group B: THA	Empiric antibiotic therapy, depending on sensitivity	3 dys to 4 mths, oral or intravenous

Note. n.a., not available; MSSA, methicillin-susceptible *Staphylococcus aureus*; MRSA, methicillin-resistant *Staphylococcus aureus*; THA, total hip arthroplasty; VAC, vacuum-assisted closure.

Table 4. Arthroscopic treatment

First author	No. patients	Follow-up (mths)	Antibiotic duration	Success rate	Complications
Khazi ZM ¹¹	421	Not reported	Not reported	100%	Total adverse events arthroscopy 75.71%, arthroscopy 52.94%; return-to-room arthroscopy 45.9%, arthroscopy 38.2%
Kim CH ¹³	7	16	4–6 wks	100%	Hip osteoarthritis 14.2%, heterotopic ossification 14.2%
Lee YK ¹⁵	9	18	4–6 wks	88.8% after first arthroscopy, 100% after second arthroscopy	None
Nusem I ¹⁸	6	22	3 wks intravenous + 3 wks oral	100%	Not reported
Yamamoto Y ¹⁹	4	32	1 wk Cefazolin oral + 1 wk Cefdinir 300 mg oral	100%	Cartilage damage and detachment 100.0%
Schröder JH ²⁵	7	27	4 wks intravenous	100%	

or cement beads. The second stage involves implantation of a total hip replacement.^{4,6,12,16,21–24,27} Anagnostakos and Kelm suggest high-pressure pulsatile lavage with 20 L of antiseptic solution (chlorhexidine) and Ringer solution.^{6,26} The femoral neck should be cut as proximal as possible to preserve femoral bone.^{23,26}

The use of antibiotic-loaded hip spacers obtains a high local concentration of antibiotic, while maintaining leg length and function in the interim period, thus making subsequent hip replacement easier and more functional.^{12,16,21–23} Antibiotics in spacers or beads should be based on culture result; the most commonly used are gentamicin and vancomycin.^{4,6,16,21–24,26,27} Use of a spacer cup is reported in the case of affected acetabulum.⁶ Cement spacers should be positioned without further opening the femoral canal, thus preventing the spread of infection, and fixed with antibiotic-loaded cement, according to ‘glove’ or ‘press-fit’ methods.^{4,22,26} Cho et al describe an innovative technique in which four

cancellous screws or Steinmann pins are inserted into the remaining proximal femoral neck parallel to the long axis of the femur. Antibiotic-loaded cement is then fixed to the screws and moulded to create the shape of the femoral head.²³

After first-stage surgery, patients can walk with crutches and toe-touch weight.^{6,26} The range of motion of the hip is permitted up to 60° of flexion.^{6,26} The second stage is performed only when satisfactory infection control has been achieved: wound healing and normal erythrocyte sedimentation rate/C-reactive protein level measured at three consecutive follow-up visits indicate eradication of infection.^{4,6,12,16,21,24} Additional aspiration for cell count and culture can be performed to confirm the absence of septic arthritis.^{4,16,21,24,27} Anagnostakos et al compare negative findings of intraoperative frozen tissue sections before THA can be performed.⁶

- Open surgical procedures (Table 6): surgical debridement aims to improve patient survival and prevention of radical excisional tissue removal; the

Table 5. Two-stage treatment

First author	No. of patients	Follow-up (mths)	Treatment	Antibiotic duration	Success rate	Complications
Kao FC ¹²	51	48.8	Debridement only 12, hip disarticulation 1, resection arthroplasty 38, cement spacer 28, THA 14	85 dys	73.4% resection arthroplasty, 73% after spacer, 92.9% revision THA	Death 13.7%, recurrent infection 9.8%
Anagnostakos K ⁶	22	44.8	Moduled spacer + THA	6 wks	87% after one spacer, 100% after two spacers	After spacer 23% Without spacer 50%
Fleck EE ¹⁶	14	50.0	Prostalac spacer + THA	6 wks	92.8% after one spacer, 100% after two spacers	None
Chen CE ²¹	28	77.0	Resection arthroplasty + THA 14; resection arthroplasty + gentamycin spacer + THA 14	4 wks	79% excellent, 14.3% fair, 7.1% poor	Reinfection 10.7%, periprosthetic fracture 10.7%, aseptic loosening 7.1%, dislocation 7.1%, stem broken 3.5%, cerebellar haemorrhage 3.5%
Shen H ²²	5	39.6	Spacer + THA	6 wks	100%	None
Cho YJ ²³	9 (10 hips)	44.9	Spacer + THA	Twice for 3 wks intravenous + 3 wks oral	100%	None
Huang TW ²⁴	14 (15 hips)	42.5	Spacer + THA	1 wk intravenous	93% at first attempt, 100% at second attempt	2 intraoperative fractures
Romanò CL ⁴	19 (20 hips)	56.6	Spacer G + THA	4–6 wks	95%	1 septic failure of revision stem
Kelm J ²⁶	10	57.6	Spacer + THA	6 wks	80%	1 spacer dislocation
Papanna MC ²⁷	36	70.0	Group A resection arthroplasty, spacer + THA; group B THA	3 days to 4 mths, oral or intravenous	100%	Group A: heterotopic ossification 2 (12%), dislocation 1 (6%); Group B: heterotopic ossification 3 (17%), periprosthetic infection 1 (6%)

Note. THA = total hip arthroplasty.

surgical approaches varied on surgeon's preferences by paying particular attention to the vascular supply of the femoral head. Routine open debridement includes removal of all accessible synovial tissue, capsulectomy, and drain placement. New approaches are described by Ohtsuru et al and Kelm et al.^{14,17} Ohtsuru et al describe placement of a pedicled vastus lateralis muscle flap after infection eradication.¹⁴ An anterolateral thigh skin paddle flap is created and a pedicled vastus lateralis muscle flap is detached. The flap is rotated 180° and placed into the incision of the approach below the subcutaneous fat. The muscle flap is placed to fill the dead space in the hip and a suction tube is inserted. Hip motion is permitted two weeks after surgery and full weight-bearing after three months.

Kelm et al report the use of vacuum-assisted closure (VAC) therapy with polyvinyl alcohol sponges.¹⁷ Polyvinyl is preferred because it provokes less pain and can be left in situ for longer than polyurethane. Postoperatively, a continuous subatmospheric pressure of 200 mm Hg is applied via a vacuum therapy system. Sponges are removed after infection eradication, defined as clinical healing, normalization of laboratory parameters, and inspection of the drained fluid.

Outcomes and success rate

Successful treatment of bacterial arthritis is usually defined as eradication of the infection without reinfections or infective complications, and with the restoration of hip joint function. Outcomes and success rates depend on treatment choice:

1. Arthroscopic treatment (Table 4): all the studies report a 100% success rate.^{13,15,18,19,25} Only Lee et al report a success rate of 88.8% after the first arthroscopy and complete success after second-look arthroscopy.¹⁵ Most studies report no arthroscopy-related complications.^{13,15,18,20,25} Kim describes a case of hip osteoarthritis and heterotopic ossification in one patient.¹³ Yamamoto et al describe damage and detachment of cartilaginous fragments in all the cases treated.¹⁹ Finally, Kim et al mention a potential risk of abdominal compartment syndrome due to arthroscopy fluid extravasation.¹³
2. Two-stage treatment (Table 5): the two-stage technique is associated with positive outcomes and very low failure rates, reinfection or persistent infection. Most studies define therapeutic success as no infection recurrence and infection eradication.^{4,6,12,16,21–24,27} The success rate is reported

Table 6. Open surgery

First author	No. of patients	Follow-up	Treatment	Antibiotic duration	Success rate	Complications
Ohtsuru T ¹⁴	15	Not reported	Group A: arthroscopy, debridement, resection arthroplasty, spacer 10; musculocutaneous flap transposition 5	4 wks intravenous + 2 wks oral	100%	Intramuscular abscess 6.66%
Kelm J ¹⁷	28	36 mths	VAC therapy	2 wks intravenous + 2 wks oral	100%	Postoperative haemorrhage 3.6%, reinfection 7.2%

Note. VAC, vacuum-assisted closure.

from 73.7% to 92.8% after spacer implantation and from 80.0% to 100.0% after THA replacement.^{4,6,12,21–24,26,27} Harris Hip Score improves from 11.5–58.8 before to 61.6–71.0 after surgery with spacers, and to 93.3–93.6 after THA.^{16,22,23}

The most common local complications are recurrent infection (range, 9.8–10.7%), drainage sinus following THA implantation (44% in one study), periprosthetic fracture (10.7% in one study), aseptic loosening (7.1% in one study), broken stem (3.5% in one study), heterotopic ossification (12–17%).^{4,6,12,16,21,27} Spacer-specific complications are rare: Anagnostakos et al report moulded spacer fractures in three patients and moulded spacer dislocation in two. Papanna et al report spacer dislocation in one case. When recurrent dislocations occur, the authors suggest a Girdlestone resection arthroplasty.^{6,27}

Reported general complications are cerebellar haemorrhage (3.5%).²¹ Kao et al report a 13.5% mortality rate in patients with septic hip arthritis.¹² The rate rises to 18% after the first stage. The authors report that patients who undergo repeat surgical debridement have favourable clinical results.

- Open surgical procedures (Table 6): the two studies report a 100% success rate.^{14,17} No complications are observed during VAC removal, while one case of intramuscular abscess of a muscle flap is described.^{14,17} Ohtsuru et al report no need for additional surgery and no recurrence in patients who received musculocutaneous flap transposition; the hip range of motion is 0–90° and the Harris Hip Score 77.¹⁴ VAC therapy is reported as successful for the eradication of septic hip arthritis, without recurrence.¹⁷

Antibiotic therapy

Antibiotic treatment is mandatory to eradicate hip infection in association with surgical treatment. All the studies describe antibiotic therapy initiated according to culture results and bacterial sensitivity: pending the culture results, empirical antibiotic therapy is recommended.^{5,13,15–19,23–27} If cultures are negative, vancomycin, teicoplanin, levofloxacin, clindamycin, gentamicin

or first-generation cephalosporine can be administered intravenously.^{4,17,23,24,26} In most studies the duration of antibiotic therapy is from three to six weeks and is generally successful in infection eradication.^{13,15–18,21–25,26,27} Intravenous antibiotics are immediately initiated after surgery and oral antibiotics are introduced after the first 3–4 weeks, then continued for further 2–3 weeks.^{16,18,23,25–27} Discontinuation of intravenous administration depends on clinical or laboratory evidence of resolution of ongoing infection.^{16,22,26} Oral antibiotics are given until C-reactive protein levels return to normal.^{24,26} Nussem et al report the use of an elastomeric continuous infusion device for intravenous antibiotic therapy after discharge from the hospital.¹⁸ Yamamoto describes a restricted antibiotic protocol, with daily oral administration of cefazolin or cefdinir for one week: no reinfection is reported.¹⁹

Discussion

Treatment of septic arthritis of the native adult hip poses distinct challenges for orthopaedic surgeons: early diagnosis and definitive surgery are pivotal for treating septic arthritis successfully, because failure to adequately treat the septic joint will have serious sequelae.^{4,12,15,18–20,26,27} Conventionally, septic hip arthritis was treated with resection arthroplasty, as described by GR Girdlestone:⁸ however, functional outcomes were often unsatisfactory. In the last decades, new therapeutic approaches have been developed: arthroscopic treatment, open surgical debridement, and two-stage strategies (first stage, resection arthroplasty and implant on an antibiotic spacer; second stage, THA implant). We thought it timely to perform a systematic review of the literature. We found that all three therapeutic procedures (arthroscopy, open debridement, two-stage) can be effective for treating septic arthritis of the hip joint.

Arthroscopy was reported to be safe and successful.^{15,18,19,25} This less invasive procedure is useful to debride necrotic synovial tissue, remove purulent material, and inspect cartilage directly with minimal operative morbidity.^{15,19,25} None of the studies found arthroscopy to be superior to open arthrotomy in the treatment of septic hip arthritis.^{15,18,19,25} While the long-term clinical results may not be different, hospitalization for hip arthroscopy

is significantly shorter and requires less irrigation or debridement.²⁰

Irrigation with huge volumes of fluid (25–30 L) is mandatory, as suggested by Nusem et al and Yamamoto et al.^{18,19} Moreover, drainage placement is fundamental to reduce intraarticular pressure and lysozyme activity and to minimize joint cartilage destruction.^{18–20,25} Complications of hip arthroscopy vary across different studies: Khazi et al reported complications in about 53% of cases, whereas Yamamoto et al described cartilaginous damage or heterotopic ossification in almost all cases.^{11,19} Other studies reported no arthroscopy-related complications.^{15,18,20}

Open procedures allow for adequate drainage of septic arthritis of the hip and can improve functional outcomes with minimal adverse effects.^{14,17,27} Nonetheless, they are associated with potential complications, such as osteonecrosis of the femoral head, dislocation, and unacceptable cosmesis.^{15,18}

Two-stage total hip arthroplasty is a safe and effective choice for the treatment of primary infectious arthritis of the hip.^{4,16,21,22,26} The two-stage procedure improves pain and function in hip joint infection;^{4,16,21–23,26} cement-loaded spacers are effective in eradicating infection and restoring good hip movement. Nonetheless, since hip function is re-established with the second-stage THA implant, the surgeon must be certain that eradication is complete before proceeding with a THA implant. The authors highlighted the importance of the absence of infective symptoms, normal erythrocyte sedimentation rate (ESR)/C-reactive protein (CRP) levels at three consecutive follow-up visits, and a negative culture.^{4,6,12,16,21,24} However, we are doubtful about the need for ESR/CRP normal levels at three consecutive follow-ups: various studies reported false negative CRP values in patients with septic arthritis of the hip as they stated that the absence of raised ESR and CPR does not exclude the diagnosis of a septic joint.^{28–31} For this reason, it is recommended not to use only ESR or CPR alone to exclude septic hip arthritis but to consider negative clinical signs and symptoms, negative radiological findings, normal white blood cell (WBC) count and a negative joint fluid culture.

Also, for open procedures, a huge volume of fluid (20 L) is needed to manage septic arthritis.⁶ Complications are drainage sinus following THA implantation, periprosthetic fracture, aseptic loosening, broken stem, and heterotopic ossification. Spacer-specific complications are rare and are related to the type of spacer. The absence of an endoskeleton is a risk factor for mechanical failure, while dislocation is related to the type used.

Institution of intravenous/oral antibiotic therapy combined with an antibiotic spacer implant has produced encouraging results. Antibiotics should be continued until normalization of clinical and laboratory parameters (normally within four to six weeks). As aforementioned, CRP or

ESR alone should not be used as criteria to stop antibiotic therapy, as negative values have been reported in patients with septic hip arthritis.^{28–31}

Success in the treatment of bacterial arthritis is defined as eradication of the infection, without reinfection or infective complications, and restoration of joint function. All three treatment options have a high success rate, with a significant improvement in clinical scores. In two-stage THA implant, the success rate is often more than 90% after the first stage and reaches 100% after the second-stage implant.^{6,16,24}

Mortality associated with septic arthritis varies across studies but seems to hover around 11%, though Kao et al reported a 13.5% mortality rate.^{1,12} Attention should be paid to debilitated patients (immunodeficiency, diabetes, corticosteroid therapy).

The present study has several limitations. First, the level of evidence of the studies is generally low, and only one prospective study could be included. This can be justified by the type of pathology, which is infrequent and too problematic to be included in prospective or randomized studies. Moreover, the studies are difficult to compare due to the heterogeneity of joint damage, host, and pathogen. While eradication of infection as an endpoint can be comparable, functional outcomes after diverse techniques (arthroscopic vs. open vs. joint replacement) are difficult to match. Lastly, we intentionally restricted our search to studies published in the last two decades: innovative procedures have been introduced only since 2000, before which date mainly case reports were published.

In conclusion, this review provides evidence that arthroscopic, single open debridement or two-stage THA procedures can be effective in treating bacterial septic arthritis of the native hip. Intravenous antibiotic therapy is necessary to eradicate septic arthritis and to minimize the risk of potential sequelae and complications. Although healthy adults may be affected, the immunocompromised (diabetes, HIV, drug and alcohol abuse) merit particular attention because of the higher risk for septic arthritis. Early diagnosis and timely treatment are key to good outcome. Prospective or randomized studies comparing the clinical outcomes after different techniques at various stages of disease are desirable to establish a shared protocol of treatment options.

AUTHOR INFORMATION

¹Division of Orthopaedics and Traumatology, ASST Sette Laghi, Department of Biotechnologies and Life Sciences (DBSV), Università degli Studi dell'Insubria, Varese, Italy.

²Division of Orthopaedics and Traumatology, ASST Sette Laghi, Varese, Italy.

³IRCCS Istituto Ortopedico Galeazzi, Hip Department, Milan, Italy.

Correspondence should be sent to: Fabio D'Angelo, Division of Orthopaedics and Traumatology, ASST Sette Laghi, Department of Biotechnologies and Life Sciences (DBSV), Università degli Studi dell'Insubria, viale L.Borri 57, Varese, Italy.
Email: fabio.dangelo@uninsubria.it

ICMJE CONFLICT OF INTEREST STATEMENT

LZ is an Associate Editor of *EFORT Open Reviews*, not related to the submitted work. The authors declare no conflict of interest relevant to this work.

FUNDING STATEMENT

No benefits in any form have been received or will be received from a commercial party related directly or indirectly to the subject of this article.

OPEN ACCESS

© 2021 The author(s)

This article is distributed under the terms of the Creative Commons Attribution-Non Commercial 4.0 International (CC BY-NC 4.0) licence (<https://creativecommons.org/licenses/by-nc/4.0/>) which permits non-commercial use, reproduction and distribution of the work without further permission provided the original work is attributed.

REFERENCES

1. Mathews CJ, Weston VC, Jones A, Field M, Coakley G. Bacterial septic arthritis in adults. *Lancet* 2010;375:846–855.
2. Morgan DS, Fisher D, Merianos A, Currie BJ. An 18 year clinical review of septic arthritis from tropical Australia. *Epidemiol Infect* 1996;117:423–428.
3. Kaandorp CJ, Dinant HJ, van de Laar MA, Moens HJ, Prins AP, Dijkmans BA. Incidence and sources of native and prosthetic joint infection: a community based prospective survey. *Ann Rheum Dis* 1997;56:470–475.
4. Romanò CL, Romanò D, Meani E, Logoluso N, Drago L. Two-stage revision surgery with preformed spacers and cementless implants for septic hip arthritis: a prospective, non-randomized cohort study. *BMC Infect Dis* 2011;11:129.
5. Matthews PC, Dean BJ, Medagoda K, et al. Native hip joint septic arthritis in 20 adults: delayed presentation beyond three weeks predicts need for excision arthroplasty. *J Infect* 2008;57:185–190.
6. Anagnostakos K, Duchow L, Koch K. Two-stage protocol and spacer implantation in the treatment of destructive septic arthritis of the hip joint. *Arch Orthop Trauma Surg* 2016;136:899–906.
7. Xu C, Kuo FC, Kheir M, Li X, Chai W, Chen JY. Outcomes and predictors of treatment failure following two-stage total joint arthroplasty with articulating spacers for evolutive septic arthritis. *BMC Musculoskelet Disord* 2019;20:272.
8. Girdlestone GR. Acute pyogenic arthritis of the hip: an operation giving free access and effective drainage, 1943. *Clin Orthop Relat Res* 2008;466:258–263.
9. Moher D, Liberati A, Tetzlaff J, Altman DG; PRISMA Group. Preferred reporting items for systematic reviews and meta-analyses: the PRISMA statement. *PLoS Med* 2009;6:e1000097.
10. Slim K, Nini E, Forestier D, Kwiatkowski F, Panis Y, Chipponi J. Methodological index for non-randomized studies (MINORS): development and validation of a new instrument. *ANZ J Surg* 2003;73:712–716.
11. Khazi ZM, Cates WT, An Q, Duchman KR, Wolf BR, Westermann RW. Arthroscopy versus open arthrotomy for treatment of native hip septic arthritis: an analysis of 30-day complications. *Arthroscopy* 2020;36:1048–1052.
12. Kao FC, Hsu YC, Liu PH, Tu YK, Jou IM. High 2-year mortality and recurrent infection rates after surgical treatment for primary septic arthritis of the hip in adult patients: an observational study. *Medicine (Baltimore)* 2019;98:e16765.
13. Kim CH, Aditya K, Lee SJ, et al. Arthroscopic treatment of psoas abscess concurrent with septic arthritis of the hip joint. *Hip Int* 2018;28:336–340.
14. Ohtsuru T, Murata Y, Morita Y, Sakurai H, Kato Y. Risk assessment and usefulness of musculocutaneous flap transposition for recurrent septic arthritis of the hip in adults. *Hip Int* 2016;26:503–507.
15. Lee YK, Park KS, Ha YC, Koo KH. Arthroscopic treatment for acute septic arthritis of the hip joint in adults. *Knee Surg Sports Traumatol Arthrosc* 2014;22:942–945.
16. Fleck EE, Spangehl MJ, Rapuri VR, Beauchamp CP. An articulating antibiotic spacer controls infection and improves pain and function in a degenerative septic hip. *Clin Orthop Relat Res* 2011;469:3055–3064.
17. Kelm J, Schmitt E, Anagnostakos K. Vacuum-assisted closure in the treatment of early hip joint infections. *Int J Med Sci* 2009;6:241–246.
18. Nusem I, Jabur MK, Playford EG. Arthroscopic treatment of septic arthritis of the hip. *Arthroscopy* 2006;22:902.e1–902.e3.
19. Yamamoto Y, Ide T, Hachisuka N, Maekawa S, Akamatsu N. Arthroscopic surgery for septic arthritis of the hip joint in 4 adults. *Arthroscopy* 2001;17:290–297.
20. de Sa D, Cargnelli S, Catapano M, et al. Efficacy of hip arthroscopy for the management of septic arthritis: a systematic review. *Arthroscopy* 2015;31:1358–1370.
21. Chen CE, Wang JW, Juhn RJ. Total hip arthroplasty for primary septic arthritis of the hip in adults. *Int Orthop* 2008;32:573–580.
22. Shen H, Wang QJ, Zhang XL, Jiang Y. Novel articulating medullary-sparing spacer for the treatment of infectious hip arthritis. *Orthopedics* 2013;36:e404–e408.
23. Cho YJ, Patel D, Chun YS, Shin WJ, Rhyu KH. Novel antibiotic-loaded cement femoral head spacer for the treatment of advanced pyogenic arthritis in adult hip. *J Arthroplasty* 2018;33:1899–1903.
24. Huang TW, Huang KC, Lee PC, Tai CL, Hsieh PH. Encouraging outcomes of staged, uncemented arthroplasty with short-term antibiotic therapy for treatment of recalcitrant septic arthritis of the native hip. *J Trauma* 2010;68:965–969.
25. Schröder JH, Krüger D, Perka C, Hufeland M. Arthroscopic treatment for primary septic arthritis of the hip in adults. *Adv Orthop* 2016;2016:8713037.
26. Kelm J, Bohrer P, Schmitt E, Anagnostakos K. Treatment of proximal femur infections with antibiotic-loaded cement spacers. *Int J Med Sci* 2009;6:258–264.
27. Papanna MC, Chebbout R, Buckley S, Stockley I, Hamer A. Infection and failure rates following total hip arthroplasty for septic arthritis: a case-controlled study. *Hip Int* 2018;28:63–67.
28. Ernst AA, Weiss SJ, Tracy LA, Weiss NR. Usefulness of CRP and ESR in predicting septic joints. *South Med J* 2010;103:522–526.
29. Couderc M, Pereira B, Mathieu S, et al. Predictive value of the usual clinical signs and laboratory tests in the diagnosis of septic arthritis. *CJEM* 2015;17:403–410.
30. Hariharan P, Kabrhel C. Sensitivity of erythrocyte sedimentation rate and C-reactive protein for the exclusion of septic arthritis in emergency department patients. *J Emerg Med* 2011;40:428–431.
31. Madruga Dias J, Costa MM, Pereira da Silva JA, Viana de Queiroz M. Septic arthritis: patients with or without isolated infectious agents have similar characteristics. *Infection* 2014;42:385–391.