

Microcystic Meningioma with Late-phase Accumulation on Thallium-201 Single-photon Emission Computed Tomography: Case Report

Fumihiro MATANO,¹ Koji ADACHI,¹ Yasuo MURAI,¹ Takayuki KITAMURA,¹
Ryuji OHASHI,² Akira TERAMOTO,¹ and Akio MORITA¹

¹Department of Neurosurgery, Nippon Medical School, Tokyo;

²Division of Diagnostic Pathology, Nippon Medical School Hospital, Tokyo

Abstract

Microcystic meningiomas are rare but benign brain tumors. Previous reports have shown that Thallium-201 single-photon emission computed tomography (²⁰¹Tl SPECT) demonstrated a higher late-phase accumulation of ²⁰¹Tl in malignant or recurrent meningiomas than in nonaggressive meningiomas. No study has reported ²⁰¹Tl SPECT findings in microcystic meningiomas. We here describe a case of a microcystic meningioma with a high ²⁰¹Tl SPECT retention rate in a 62-year-old woman who complained of headache. Computed tomography revealed an intracranial tumor in the right frontal lobe. Moreover, ²⁰¹Tl SPECT revealed a high uptake of ²⁰¹Tl in the tumor, which was particularly prominent in the delayed phase. The uptake index on an early image was 1.46 and that on a delayed image was 1.35. Therefore, the retention index was 0.92. After 2 years of tumor growth, we performed successful radical resection, and histological examination revealed the presence of a microcystic meningioma. Therefore, we concluded that ²⁰¹Tl SPECT may be useful for the preoperative diagnosis of microcystic meningiomas and that late-phase accumulation of ²⁰¹Tl is not a specific finding of malignant brain tumors. Therefore, we need to be careful in the evaluation and judgment of high retention in a delayed image of ²⁰¹Tl SPECT.

Key words: microcystic meningioma, thallium-201, single-photon emission computed tomography

Introduction

Thallium-201 single-photon emission computed tomography (²⁰¹Tl SPECT) exhibits early and relatively high accumulation in all types of meningiomas, but its retention rate varies according to the histological type.^{1,2)} ²⁰¹Tl SPECT has demonstrated higher late-phase accumulation of ²⁰¹Tl in malignant or recurrent meningiomas than in nonaggressive meningiomas.^{3–6)} To our knowledge, no study has reported ²⁰¹Tl SPECT findings in microcystic meningiomas. We here describe a case of microcystic meningioma with a high ²⁰¹Tl SPECT retention rate and review of the literature.

Case Report

A 62-year-old woman presented with headache. Computed tomography (CT) revealed an intracranial tumor in the

right frontal lobe. The tumor had been growing for 2 years, and the patient was referred to our hospital for a detailed examination. Neurological examination results were normal. CT revealed a low-density lesion with edema (Fig. 1A), whereas angiography did not demonstrate any tumor staining (data not shown). The tumor appeared as a low-density lesion on T₁-weighted magnetic resonance imaging (MRI) (Fig. 1B) and as a high-density lesion on T₂-weighted MRI (Fig. 1C). On enhanced T₁-weighted MRI, the tumor appeared to have an enhanced wall (Fig. 1D). Early phase ²⁰¹Tl SPECT images showed high tumor uptake (Fig. 1E), which was particularly prominent in the delayed phase (Fig. 1F). The uptake index on an early image was 1.46 and that on a delayed image was 1.35. Therefore, the retention index was 0.92.

Surgical treatment (radical resection) was successfully carried out. The tumor, with a soft and moist consistency similar to that of a jellyfish, was easily separated from the brain surface and underwent Simpson Grade 1 resection. Following radical resection, duraplasty was performed

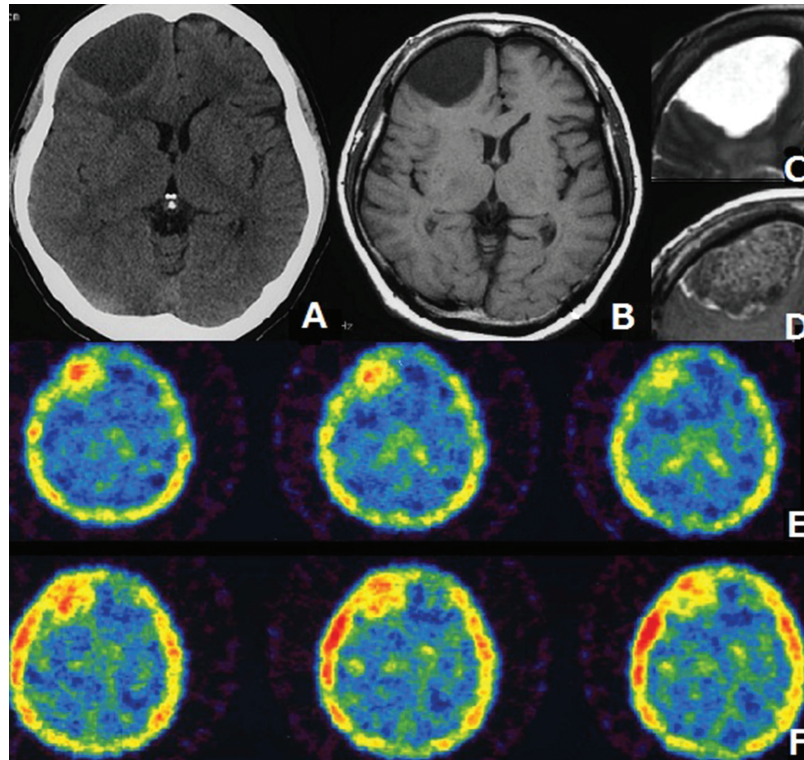


Fig. 1 A: CT scan revealing a low-density lesion. B: T₁-weighted MRI showing a low-density lesion. C: T₂-weighted MRI showing a high-density lesion. D: Tumor showing an enhanced wall on enhanced T₁-weighted MRI. E: Early ²⁰¹Tl SPECT image showing high tumor uptake. F: Delayed ²⁰¹Tl SPECT image showing high tumor uptake. CT: computed tomography, MRI: magnetic resonance imaging, ²⁰¹Tl SPECT: Thallium-201 single-photon emission computed tomography.

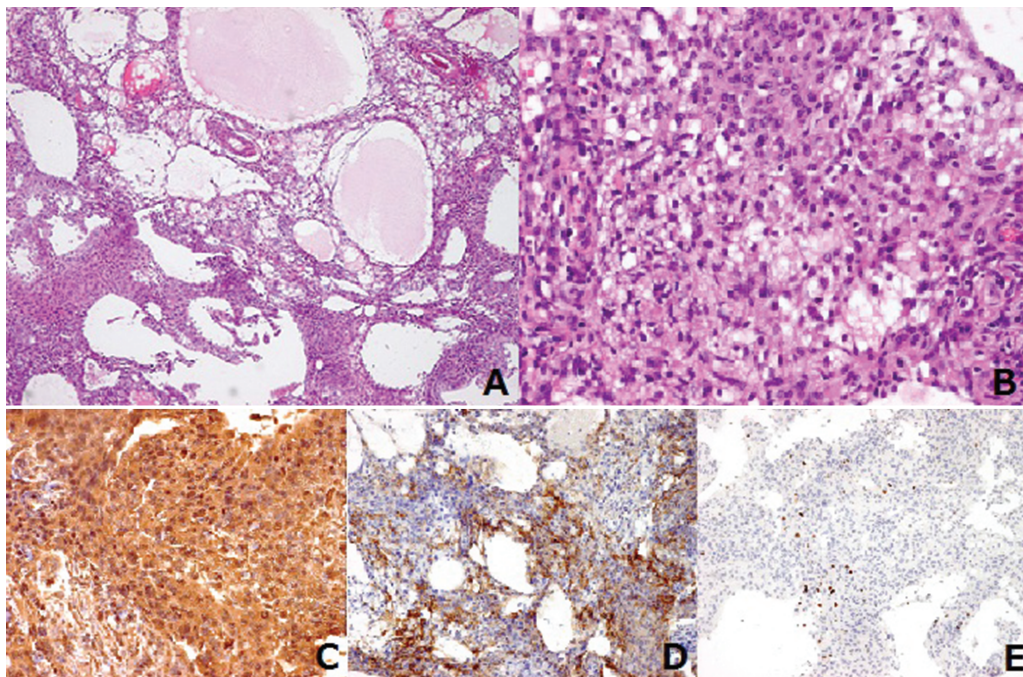


Fig. 2 A, B: Histological examination, indicative of a microcystic meningioma, showing variable-sized tumor cells with vacuolated cytoplasm and elongated cell processes forming microcystic spaces (hematoxylin and eosin stain) (A $\times 40$, B $\times 200$). C: Vimentin positivity on immunostaining ($\times 200$), D: Epithelial membrane antigen positivity on immunostaining ($\times 100$). E: MIB-1 index ranged from 3% to 5% ($\times 100$). MIB-1: mindbomb homolog 1.

using artificial dura. Histological examination revealed a tumor characterized by vacuolated cells with abundant cytoplasmic processes forming variable-sized microcysts (Fig. 2A, B). Immunohistochemically, the tumor cells were diffusely positive for vimentin (Fig. 2C) and focally positive for epithelial membrane antigen (Fig. 2D). The mindbomb homolog 1 (MIB-1) index, detected by Ki67 staining, ranged from 3% to 5% (Fig. 2E). These histological and immunohistochemical findings were diagnostic of a microcystic meningioma.

The patient's postoperative recovery was favorable, and she was discharged with no signs of neurological deficit.

Discussion

We reported that late-phase accumulation of ^{201}Tl may occur in microcystic meningiomas. We speculated that ^{201}Tl SPECT may be useful for the preoperative diagnosis of microcystic meningiomas and that late-phase accumulation of ^{201}Tl is not a specific finding of malignant brain tumors.

Microcystic meningiomas are rare but benign brain tumors, accounts for only 1.6% of all intracranial meningiomas.⁷⁾ In 1993, the World Health Organization classified this variant as a distinct subgroup of meningiomas.^{8,9)} On CT and MRI, microcystic meningiomas present characteristics different from other meningiomas.^{10–12)} In our case, the tumor appeared as a low-density lesion on CT and T_1 -weighted MRI and as a high-density lesion on T_2 -weighted MRI. On gadolinium diethylenetriaminepentaacetate (Gd-DTPA)-enhanced T_1 -weighted imaging, the tumor did not show intense enhancement. Peritumoral cerebral edema is a common MRI finding of microcystic meningiomas.^{13–16)}

In the present case, the CT and MRI results were typical of microcystic meningiomas, but ^{201}Tl SPECT has not been reported previously and was found to be relatively atypical for a benign meningioma. ^{201}Tl SPECT has been reported to be useful for detecting tumor viability in cases of malignant tumors^{3,4,6,17,18)} and exhibits early and relatively high accumulation in all types of meningiomas. However, the retention rates differ according to histological types. Jinnouchi et al.¹⁾ reported that early and delayed ^{201}Tl SPECT studies of meningiomas revealed meningotheial, transitional, fibroblastic, and malignant tumors. They concluded that retention was lower for meningotheial meningiomas than for malignant meningiomas, and the transitional and fibroblastic meningiomas showed relatively high retention in the delayed image of ^{201}Tl SPECT. Based on the case of our microcystic meningiomas and previous reports, high retention in a delayed image of ^{201}Tl SPECT always does not imply the detection of a malignant brain tumor. Therefore, we need to be careful in our evaluation and judgment of high retention in a delayed image of ^{201}Tl SPECT.

There have been no previous reports focusing on ^{201}Tl

SPECT findings in microcystic meningiomas. Therefore, it would be helpful to study more patients presenting with microcystic meningiomas in relation to ^{201}Tl SPECT results to obtain further evidence.

Conflicts of Interest Disclosure

The authors have no conflicts of interest. All authors who are members of the Japan Neurosurgical Society (JNS) have registered by filling Self-reported COI Disclosure Statement forms available online through the website for JNS members.

References

- 1) Jinnouchi S, Hoshi H, Ohnishi T, Futami S, Nagamachi S, Watanabe K, Ueda T, Wakisaka S: Thallium-201 SPECT for predicting histological types of meningiomas. *J Nucl Med* 34: 2091–2094, 1993
- 2) Valotassiou V, Leondi A, Angelidis G, Psimadas D, Georgoulas P: SPECT and PET imaging of meningiomas. *Scientific World Journal* 2012: 412580, 2012
- 3) Black KL, Hawkins RA, Kim KT, Becker DP, Lerner C, Marciano D: Use of thallium-201 SPECT to quantitate malignancy grade of gliomas. *J Neurosurg* 71: 342–346, 1989
- 4) Ishibashi M, Taguchi A, Sugita Y, Morita S, Kawamura S, Umezaki N, Shigemori M, Hayabuchi N: Thallium-201 in brain tumors: relationship between tumor cell activity in astrocytic tumor and proliferating cell nuclear antigen. *J Nucl Med* 36: 2201–2206, 1995
- 5) Takeda T, Nakano T, Asano K, Shimamura N, Ohkuma H: Usefulness of thallium-201 SPECT in the evaluation of tumor natures in intracranial meningiomas. *Neuroradiology* 53: 867–873, 2011
- 6) Tedeschi E, Soricelli A, Brunetti A, Romano M, Bucciero A, Iaconetta G, Alfieri A, Postiglione A, Salvatore M: Different thallium-201 single-photon emission tomographic patterns in benign and aggressive meningiomas. *Eur J Nucl Med* 23: 1478–1484, 1996
- 7) Kuchna I, Matyja E, Wierzba-Bobrowicz T, Mazurowski W: Microcystic meningioma—a rarely occurring morphological variant of meningioma. *Folia Neuropathol* 32: 259–263, 1994
- 8) Kleihues P, Burger PC, Scheithauer BW: The new WHO classification of brain tumours. *Brain Pathol* 3: 255–268, 1993
- 9) Louis DN, Ohgaki H, Wiestler OD, Cavenee WK, Burger PC, Jouvet A, Scheithauer BW, Kleihues P: The 2007 WHO classification of tumours of the central nervous system. *Acta Neuropathol* 114: 97–109, 2007
- 10) Bromley PJ, Grymaloski MR, Zetler PJ: CT appearance of microcystic meningioma. *J Comput Assist Tomogr* 20: 570–572, 1996
- 11) Nishio S, Takeshita I, Morioka T, Fukui M: Microcystic meningioma: clinicopathological features of 6 cases. *Neurol Res* 16: 251–256, 1994
- 12) Shimoji K, Yasuma Y, Mori K, Eguchi M, Maeda M: Unique radiological appearance of a microcystic meningioma. *Acta Neurochir (Wien)* 141: 1119–1121, 1999

- 13) Kubota Y, Ueda T, Kagawa Y, Sakai N, Hara A: Microcystic meningioma without enhancement on neuroimaging—case report. *Neurol Med Chir (Tokyo)* 37: 407–410, 1997
- 14) Paek SH, Kim CY, Kim YY, Park IA, Kim MS, Kim DG, Jung HW: Correlation of clinical and biological parameters with peritumoral edema in meningioma. *J Neurooncol* 60: 235–245, 2002
- 15) Paek SH, Kim SH, Chang KH, Park CK, Kim JE, Kim DG, Park SH, Jung HW: Microcystic meningiomas: radiological characteristics of 16 cases. *Acta Neurochir (Wien)* 147: 965–972; discussion 972, 2005
- 16) Yoshioka H, Hama S, Taniguchi E, Sugiyama K, Arita K, Kurisu K: Peritumoral brain edema associated with meningioma: influence of vascular endothelial growth factor expression and vascular blood supply. *Cancer* 85: 936–944, 1999
- 17) Kinuya K, Ohashi M, Itoh S, Sakai S, Yamamoto K, Kakuda K, Nobata K, Terahata S, Taki S, Kinuya S: Thallium-201 brain SPECT to diagnose aggressiveness of meningiomas. *Ann Nucl Med* 17: 463–467, 2003
- 18) Rubinstein R, Karger H, Pietrzyk U, Siegal T, Gomori JM, Chisin R: Use of ²⁰¹Thallium brain SPECT, image registration, and semi-quantitative analysis in the follow-up of brain tumors. *Eur J Radiol* 21: 188–195, 1996

Address reprint requests to: Fumihiko Matano, MD, Department of Neurosurgery, Nippon Medical School, 1-1-5 Sendagi, Bunkyo-ku, Tokyo 113-8603, Japan.
e-mail: s00-078@nms.ac.jp