



## CASE REPORT

# Case Report: Lupoid cutaneous leishmaniasis mimicking verruca plana [version 1; referees: 4 approved]

Emin Ozlu <sup>1</sup>, Aysegul Baykan<sup>2</sup>, Ozan Yaman<sup>3</sup>, Ragıp Ertas<sup>4</sup>, Mustafa Atasoy<sup>4</sup>, Kemal Ozyurt<sup>4</sup>, Abdullah Turasan<sup>4</sup>, Nazan Taslıdere<sup>4</sup>

<sup>1</sup>Department of Dermatology, School of Medicine, Duzce University, Duzce, Turkey

<sup>2</sup>Department of Dermatology, Kayseri Tekden Hospital, Kayseri, Turkey

<sup>3</sup>Department of Microbiology, Kayseri Training and Research Hospital, Kayseri, Turkey

<sup>4</sup>Department of Dermatology, Kayseri Training and Research Hospital, Kayseri, Turkey

**v1** First published: 20 Jun 2017, 6:947 (doi: [10.12688/f1000research.11591.1](https://doi.org/10.12688/f1000research.11591.1))  
Latest published: 20 Jun 2017, 6:947 (doi: [10.12688/f1000research.11591.1](https://doi.org/10.12688/f1000research.11591.1))

## Abstract

Cutaneous leishmaniasis (CL) is an infectious disease caused by various species of leishmania protozoan parasites. Lupoid CL is a rare form of CL that has a stunning similarity to other granulomatous cutaneous conditions of infectious or inflammatory origin. Verruca plana, also known as a “flat wart”, is a benign proliferation of the skin resulting from infection with human papilloma virus (HPV). Herein, we presented a case of lupoid CL mimicking verruca plana on the face.

## Open Peer Review

Referee Status:

	Invited Referees			
	1	2	3	4
<b>version 1</b>				
published 20 Jun 2017	report	report	report	report

1 **Gulhan Gurel**, Bozok University, Turkey

2 **Altay Atalay**, Erciyes University, Turkey

3 **Mehmet Akif Dundar**, Kayseri Training and Research Hospital, Turkey

4 **Roderick J Hay**, International Foundation for Dermatology, UK

## Discuss this article

Comments (0)

**Corresponding author:** Emin Ozlu ([dermatologg@gmail.com](mailto:dermatologg@gmail.com))

**Competing interests:** No competing interests were disclosed.

**How to cite this article:** Ozlu E, Baykan A, Yaman O *et al.* **Case Report: Lupoid cutaneous leishmaniasis mimicking verruca plana [version 1; referees: 4 approved]** *F1000Research* 2017, 6:947 (doi: [10.12688/f1000research.11591.1](https://doi.org/10.12688/f1000research.11591.1))

**Copyright:** © 2017 Ozlu E *et al.* This is an open access article distributed under the terms of the [Creative Commons Attribution Licence](https://creativecommons.org/licenses/by/4.0/), which permits unrestricted use, distribution, and reproduction in any medium, provided the original work is properly cited.

**Grant information:** The author(s) declared that no grants were involved in supporting this work.

**First published:** 20 Jun 2017, 6:947 (doi: [10.12688/f1000research.11591.1](https://doi.org/10.12688/f1000research.11591.1))

## Introduction

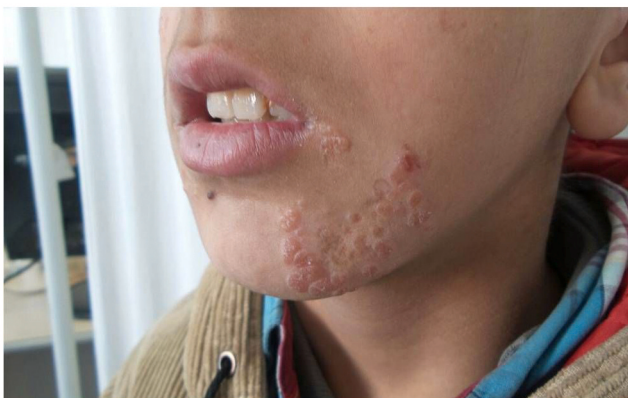Leishmaniasis encompasses a group of diseases caused by the protozoan parasites of the *Leishmania* genus<sup>1</sup>. Classical lesions of cutaneous leishmaniasis (CL) advance in the forms of papules, nodules and ulcerated lesions, and they heal with an atrophic scar over months and years<sup>2</sup>. Nevertheless, CL has been seen in atypical form, including erysipeloid, lupoid, sporotrichoid, hyperkeratotic, eczematous, verrucous and impetiginized form<sup>3</sup>.

Lupoid CL is one of the more rarely seen forms of CL<sup>4</sup>. The incidence of lupoid CL has been reported to be 0.5 to 6.2%<sup>5</sup>. This clinical presentation with a chronic course develops after acute CL infection. In this clinical form, papulonodular lesions of granulomatous and lupoid character are seen 1–2 years after the acute lesion is healed<sup>4</sup>. Although there is an immune response against parasites in lupoid CL, the immune system is unable to remove the parasites altogether and thus the chronic granulomatous response continues for a long time<sup>6</sup>. Many clinical presentations of lupoid CL have been reported; however, no lupoid CL mimicking *verruca plana* has, to our knowledge, previously been reported in the literature.

## Case report

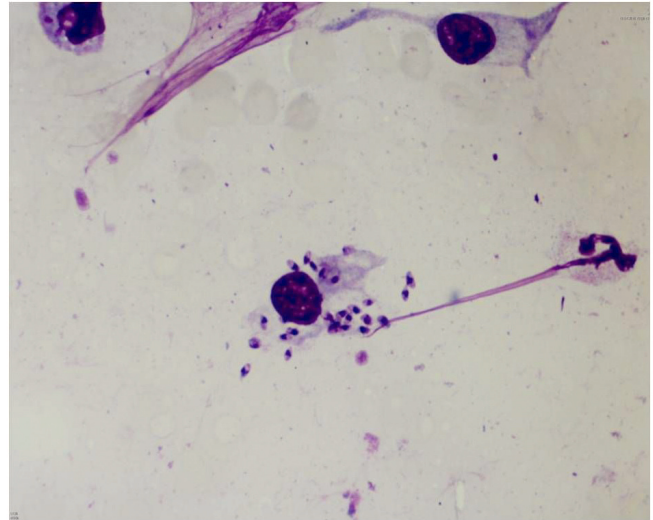
A 9-year-old male patient presented at our clinic with multiple papular lesions located in the left cheek. He had had these lesion for three months, and they had gradually enlarged. The medical history revealed that the patient had a follow-up after diagnosis of CL located in the nose two years ago, and presented with complete regression after he was started on intralesional meglumine antimonate.

Dermatological examination revealed multiple, coalescing, rough, slightly elevated, yellowish-brown papular lesions 3–6 mm in diameter located in the left cheek (Figure 1). In addition, he had large atrophic scar on the nose. Nothing of interest was noted in his family history or his laboratory tests. After staining with Giemsa, a parasitological smear showed numerous leishmania parasites in their amastigote form (Figure 2).

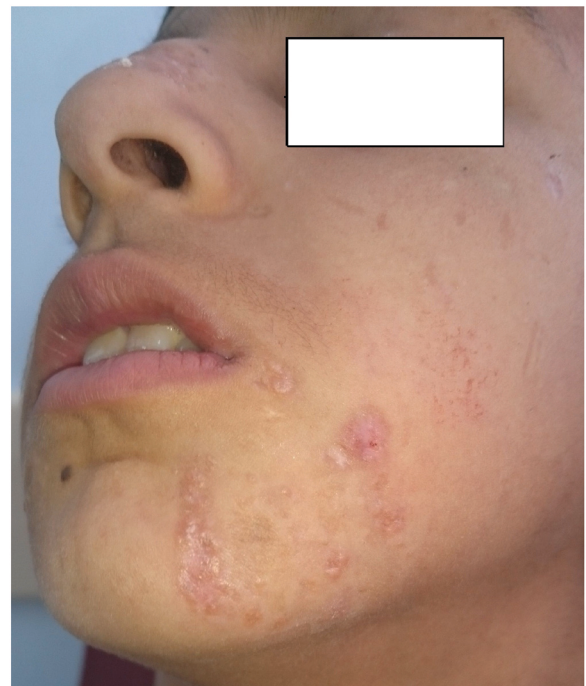

**Figure 1.** Multiple yellowish-brown coalescing papular lesions located in the patient's left cheek.

The patient was diagnosed with lupoid CL based on his medical history, and his clinical and microscopy findings. He was started on intralesional meglumine antimonate injection per week. After the 4 sessions of treatment, significant improvement was observed in the patient's lesions (Figure 3).



**Figure 2.** *Leishmania* spp. amastigotes (Giemsa staining x1000).



**Figure 3.** Yellowish-brown, slightly elevated papular lesions located in the left cheek after treatment.

## Discussion

CL is a parasitic disease caused by leishmania protozoa, transmitted to humans during blood sucking by infected phlebotomine sandflies<sup>3</sup>. Clinical signs of CL vary from a self-limited asymptomatic presentation to life-threatening diffuse destructive lesions, depending on the type of the leishmania and the immunological state of the host. Initial lesions are frequently erythematous papules or nodular lesions<sup>7</sup>.

Lupoid CL is a rare, chronic form of CL that develops following acute CL. In this clinical form, papulonodular lesions are developed at the edges of the scar months and even years after the acute lesion is healed. Papular lesions in brownish red or brownish yellow with a tendency to merge with each other, and nodules in apple-jelly consistency compose the characteristic lupoid image in lupoid CL. The lesions are sometimes squamous, crusted, and psoriasiform and may mimic lupus vulgaris. The clinical course of lupoid CL is considered to be associated with changes in the cell-mediated immunity. A possible underlying pathogenetic mechanism involves changes in Th1 and Th2 cell responses and interleukin 4 (IL-4) production<sup>8</sup>. The altered host immune response then contributes to the high sensitivity to parasitic infections and extraordinary clinical presentations<sup>8</sup>.

Lupoid CL has been defined as having atypical clinical properties and a chronic recurrent course. Clinically, lupoid CL may particularly resemble lupus erythematosus and lupus vulgaris<sup>8</sup>. It may also resemble other granulomatous diseases of infectious or inflammatory origin and may mimic them; however, microscopic and histopathological findings are important in differentiating them from other dermatoses<sup>9</sup>.

Ul Bari *et al.*<sup>8</sup> evaluated 16 patients with lupoid CL and reported 4 different morphological patterns, including psoriasiform lesions, ulcerated/crusted lesions and discoid lupus erythematosus. Douba *et al.*<sup>9</sup> analyzed 1880 patients with chronic CL. In that study, 1.4 % of 1880 patients were reported to have lesions with verrucous character<sup>9</sup>. In this case report, the patient had a progressively increasing amount of groups of papular lesions that were yellowish brown in colour, in the left cheek and chin region. Clinically, the lesions suggested verruca plana; however, the

microscopic evaluation of the sample obtained from the lesion revealed amastigotes and a diagnosis of lupoid CL was made. To the best of our knowledge, there is no case of lupoid CL mimicking verruca plana in the literature. In this case, it is striking that no lesion was seen around the CL scar.

Amastigotes are seen rarely in the parasitological smear in lupoid CL<sup>10</sup>. In our present case, amastigotes may have been observed due to the lesions having appeared in the last three months.

There is no current protocol for efficient and accurate treatment of lupoid CL. First-line treatment involves administration of pentavalent antimony compounds<sup>10</sup>. In the present case, following treatment with intralesional meglumine antimonate for 4 sessions, a significant regression in the lesions of the patient was observed; and treatment was discontinued.

## Conclusion

Lupoid CL is a rare and chronic form of CL. Lupoid CL manifest with atypical clinical and histopathological properties. It should be considered that lupoid CL may be seen as lesions similar to verruca plana.

## Consent

We obtained written informed consent from patient's parents for the publication of the manuscript.

## Author contributions

EO wrote the manuscript; AB prepared the manuscript; OY is the patient's consultant from the Department of Microbiology; RE, MA and KO, AT and NT helped manage the patient's diagnosis and therapy.

## Competing interests

No competing interests were disclosed.

## Grant information

The author(s) declared that no grants were involved in supporting this work.

## References

- Inci R, Ozturk P, Mulayim MK, *et al.*: **Effect of the Syrian Civil War on Prevalence of Cutaneous Leishmaniasis in Southeastern Anatolia, Turkey.** *Med Sci Monit.* 2015; **21**: 2100–2104.  
[PubMed Abstract](#) | [Publisher Full Text](#) | [Free Full Text](#)
- Pace D: **Leishmaniasis.** *J Infect.* 2014; **69**(Suppl 1): S10–18.  
[PubMed Abstract](#) | [Publisher Full Text](#)
- Saab J, Fedda F, Khattab R, *et al.*: **Cutaneous leishmaniasis mimicking inflammatory and neoplastic processes: a clinical, histopathological and molecular study of 57 cases.** *J Cutan Pathol.* 2012; **39**(2): 251–262.  
[PubMed Abstract](#) | [Publisher Full Text](#)
- Bowling JC, Vega-Lopez F: **Case 2. Lupoid leishmaniasis.** *Clin and Exp Derm.* 2003; **28**(6): 683–684.  
[PubMed Abstract](#) | [Publisher Full Text](#)
- Nilforoushadeh MA, Jaffray F, Reiszadeh MR, *et al.*: **The therapeutic effect of combined cryotherapy, paramomycin, and intralesional meglumine**

- antimoniate in treating lupoid leishmaniasis and chronic leishmaniasis.**  
*Int J Dermatol.* 2006; **45**(8): 989–991.  
[PubMed Abstract](#) | [Publisher Full Text](#)
6. Stefanidou MP, Antoniou M, Koutsopoulos AV, *et al.*: **A rare case of leishmaniasis recidiva cutis evolving for 31 years caused by *Leishmania tropica*.**  
*Int J Dermatol.* 2008; **47**(6): 588–589.  
[PubMed Abstract](#) | [Publisher Full Text](#)
  7. David CV, Craft N: **Cutaneous and mucocutaneous leishmaniasis.** *Dermatol Ther.* 2009; **22**(6): 491–502.  
[PubMed Abstract](#) | [Publisher Full Text](#)
  8. Ul Bari A, Raza N: **Lupoid cutaneous leishmaniasis: a report of 16 cases.** *Indian J Dermatol Venereol Leprol.* 2010; **76**(1): 85.  
[PubMed Abstract](#) | [Publisher Full Text](#)
  9. Douba MD, Abbas O, Wali A, *et al.*: **Chronic cutaneous leishmaniasis, a great mimicker with various clinical presentations: 12 years experience from Aleppo.** *J Eur Acad Dermatol Venereol.* 2012; **26**(10): 1224–1229.  
[PubMed Abstract](#) | [Publisher Full Text](#)
  10. Khaled A, Goucha S, Trabelsi S, *et al.*: **Lupoid cutaneous leishmaniasis: a case report.** *Dermatol Ther (Heidelb).* 2011; **1**(2): 36–41.  
[PubMed Abstract](#) | [Publisher Full Text](#) | [Free Full Text](#)

# Open Peer Review

Current Referee Status:    

---

## Version 1

Referee Report 24 July 2017

doi:[10.5256/f1000research.12521.r24237](https://doi.org/10.5256/f1000research.12521.r24237)



**Roderick J Hay**

International Foundation for Dermatology, London, W1P 5HQ, UK

This is an interesting case report of an unusual variant of cutaneous leishmaniasis. It is infrequently reported and therefore worth recording. I'm not sure that these lesions resemble plane warts - they are certainly flattish but the lateral borders appear slightly curved. I would call them large flat topped papules instead.

**Is the background of the case's history and progression described in sufficient detail?**

Yes

**Are enough details provided of any physical examination and diagnostic tests, treatment given and outcomes?**

Yes

**Is sufficient discussion included of the importance of the findings and their relevance to future understanding of disease processes, diagnosis or treatment?**

Yes

**Is the case presented with sufficient detail to be useful for other practitioners?**

Yes

**Competing Interests:** No competing interests were disclosed.

**I have read this submission. I believe that I have an appropriate level of expertise to confirm that it is of an acceptable scientific standard.**

Referee Report 03 July 2017

doi:[10.5256/f1000research.12521.r23660](https://doi.org/10.5256/f1000research.12521.r23660)



**Mehmet Akif Dundar**

Department of Pediatric, Kayseri Training and Research Hospital, Kayseri, Turkey

I read the case report. The differential diagnosis of lupoid cutaneous leishmaniasis is difficult and may depend on the detection of a few Leishmania amastigotes in the histologic sections. The case provided

will most likely be highly favorable for management of this disease in Turkey. I think this case report is appropriate for publication and will contribute to the literature.

**Is the background of the case's history and progression described in sufficient detail?**

Yes

**Are enough details provided of any physical examination and diagnostic tests, treatment given and outcomes?**

Yes

**Is sufficient discussion included of the importance of the findings and their relevance to future understanding of disease processes, diagnosis or treatment?**

Yes

**Is the case presented with sufficient detail to be useful for other practitioners?**

Yes

**Competing Interests:** No competing interests were disclosed.

**I have read this submission. I believe that I have an appropriate level of expertise to confirm that it is of an acceptable scientific standard.**

Referee Report 23 June 2017

doi:10.5256/f1000research.12521.r23760



**Altay Atalay**

Department of Medical Microbiology, Faculty of Medicine, Erciyes University, Kayseri, Turkey

The paper titled "Case Report: Lupoid cutaneous leishmaniasis mimicking verruca plana" makes a significant contribution to the field because of its rarity. The topic is important. According to my opinion the background of the case's history and progression described in sufficient detail and details provided of any physical examination and diagnostic tests, treatment given and outcomes are enough. In addition the case is presented with sufficient detail to be useful for other practitioners. Figures are useful.

In conclusion, the paper is novel and the work delivers what it promises. My overall evaluation of the paper is positive.

**Is the background of the case's history and progression described in sufficient detail?**

Yes

**Are enough details provided of any physical examination and diagnostic tests, treatment given and outcomes?**

Yes

**Is sufficient discussion included of the importance of the findings and their relevance to future understanding of disease processes, diagnosis or treatment?**

Yes

**Is the case presented with sufficient detail to be useful for other practitioners?**

Yes

**Competing Interests:** No competing interests were disclosed.

**Referee Expertise:** Mycology

**I have read this submission. I believe that I have an appropriate level of expertise to confirm that it is of an acceptable scientific standard.**

Referee Report 23 June 2017

doi:10.5256/f1000research.12521.r23759



**Gulhan Gurel**

Department of Dermatology, School of Medicine, Bozok University, Yozgat, Turkey

I evaluated the case report entitled 'Lupoid cutaneous leishmaniasis mimicking verruca plana'.

Leishmania is currently endemic in 102 countries, areas or territories worldwide and 2 million new cases are recorded annually<sup>1</sup>. This sentence can be added at the introduction of the article.

Cutaneous leishmaniasis is still considered an important health issue in many parts of the world. Lupoid CL is a very rare form of CL. The lupoid CL mimicking the verruca plana may lead to delay in the diagnosis. It is thought that the very rare case will contribute to the literature. This case report is appropriate for publication.

#### References

1. Özbilgin A, Harman M, Karakuş M, Bart A, Töz S, Kurt Ö, Çavuş İ, Polat E, Gündüz C, Van Gool T, Özbel Y: Leishmaniasis in Turkey: Visceral and cutaneous leishmaniasis caused by *Leishmania donovani* in Turkey. *Acta Trop.* 2017; **173**: 90-96 [PubMed Abstract](#) | [Publisher Full Text](#)

**Is the background of the case's history and progression described in sufficient detail?**

Yes

**Are enough details provided of any physical examination and diagnostic tests, treatment given and outcomes?**

Yes

**Is sufficient discussion included of the importance of the findings and their relevance to future understanding of disease processes, diagnosis or treatment?**

Yes

**Is the case presented with sufficient detail to be useful for other practitioners?**

Yes

**Competing Interests:** No competing interests were disclosed.

**I have read this submission. I believe that I have an appropriate level of expertise to confirm that it is of an acceptable scientific standard.**

---