

Concurrent Coronary, Left Ventricle, and Cerebral Thrombosis – A Trilogy

Abstract

Left ventricular (LV) thrombus is a known complication of acute myocardial infarction (AMI), especially anterior wall MI and leads to systemic thromboembolism. However, increase in the rates of coronary perfusion either by thrombolysis or percutaneous interventions have reduced its incidence. Concurrent stroke and MI are seen in 0.009% of cases. The occurrence of AMI with LV thrombus with or without stroke mandates the combination of antiplatelet and antithrombotic therapy. Hitherto, there are no randomized studies in the setting of AMI with LV thrombus comparing dual (single antiplatelet plus oral anticoagulant [OAC]) and triple therapy (dual antiplatelet therapy with OAC). There are no large randomized trials as well to delineate the optimal therapy for simultaneous cardiac and cerebral infarction. We hereby, report an unusual case of a young patient who presented with triple combo of acute anterior wall MI, LV thrombus, and ischemic stroke and discuss the challenges in management in this scenario.

Keywords: Anticoagulation, cardio-cerebral infarction, dual therapy, intracerebral hemorrhage, thrombolysis

Introduction

Left ventricular (LV) thrombus usually occurs when there is a severe reduction of LV ejection fraction like in dilated cardiomyopathy or LV aneurysm following a large myocardial infarction (MI).^[1,2] The incidence of LV thrombus following MI in the percutaneous coronary intervention (PCI) era varies from 5% to 15% depending on the method employed such as echocardiography, magnetic resonance imaging, left ventriculography, etc.^[1] Although there has been a reduction in the incidence of LV thrombus post MI, the risk of systemic embolism remains high. The concomitant occurrence of acute MI (AMI) and ischemic stroke is also rare and is estimated to be around 0.009%.^[3] Such an unfortunate scenario was termed as “cardio-cerebral infarction” by Omar *et al.* 2010.^[3] There are some explanations for coexistence of ischemic stroke in AMI. One of the possible explanations is the formation of LV thrombus. The other mechanism could be the reduction of cerebral blood flow to watershed areas of the brain and subsequent infarction resulting from the sudden hemodynamic compromise. This is more relevant for patients presenting

with AMI with a long-standing history of hypertension, especially if there is a failure of blood pressure autoregulatory mechanisms. On the other hand, there may be myocardial stunning and intracardiac thrombus due to acute adrenergic surge from acute ischemic stroke.^[3] The American College of Cardiology/American Heart Association guidelines for the management of AMI recommends addition of oral anticoagulants (OACs) in addition to dual antiplatelet (DAPT) agents for the treatment and prevention of LV thrombus in AMI.^[3] The use of triple antithrombotic (DAPT+OAC) increases the incidence of bleeding events substantially.^[4] Some studies advocate the use of a single antiplatelet agent (SAPT) with OAC as bleeding events are reduced with comparable efficacy in certain conditions with AMI requiring OAC. However, the optimal management strategy in AMI with LV thrombus is not clear.^[5,6] In addition, there are uncertainties regarding the use of novel OACs (NOACs). Further, there are no consensus guidelines for the management in case of simultaneous occurrence of AMI and acute ischemic stroke as in our case.

Case Report

A 38-year-old male presented to us with a sudden-onset chest pain of 17 h

**Monika Bhandari,
Akshyaya Kumar
Pradhan,
Pravesh
Vishwakarma,
Rishi Sethi**

*Departments of Cardiology,
King George's Medical
University, Lucknow,
Uttar Pradesh, India*

Submitted: 30-Jan-2021
Revised: 07-Dec-2021
Accepted: 14-Dec-2021
Published: 10-May-2022

Address for correspondence:
Dr. Akshyaya Kumar Pradhan,
Additional Professor,
Department of Cardiology,
King George's Medical
University, Lucknow, Uttar
Pradesh-226003, India.
E-mail: akshyaya33@gmail.com

Access this article online

Website:
www.ijabmr.org

DOI:
10.4103/ijabmr.ijabmr_95_21

Quick Response Code:



How to cite this article: Bhandari M, Pradhan AK, Vishwakarma P, Sethi R. Concurrent coronary, left ventricle, and cerebral thrombosis – A trilogy. *Int J App Basic Med Res* 2022;12:130-3.

This is an open access journal, and articles are distributed under the terms of the Creative Commons Attribution-NonCommercial-ShareAlike 4.0 License, which allows others to remix, tweak, and build upon the work non-commercially, as long as appropriate credit is given and the new creations are licensed under the identical terms.

For reprints contact: WKHLRPMedknow_reprints@wolterskluwer.com

and right-sided hemiplegia for 4 h before presentation. On examination, his vitals were stable and his cardiac examination was within normal limits. The patient was in altered sensorium with the Glasgow Coma Scale of 11/15. He was immediately shifted to the intensive cardiac care unit. A 12-lead electrocardiogram showed acute anterior wall MI with right bundle branch block and sinus rhythm [Figure 1]. Two-dimensional transthoracic echocardiography showed akinetic apex, apico-septal, apico-lateral, and mid and anterior septal wall with an LV ejection fraction of 34%. There was a large mobile thrombus at LV apex measuring 1.8 cm × 2.2 cm in apical four-chamber view and 1.9 cm × 2.3 cm in parasternal short-axis view at the level of papillary muscles [Figure 2a and b]. Since the patient also had hemiplegia, noncontrast computed tomography (NCCT) scan of head was ordered which revealed a large infarct in the middle cerebral artery territory occupying more than half of the left brain area with compression of the ventricle [Figure 3]. Neurology and neurosurgery opinion was taken. As the infarct was too large, patient could not be thrombolized, and the facility for endovascular intervention for stroke was not available, so the patient was managed conservatively. Unfortunately, patient's condition deteriorated and he succumbed to his illness after 48 h.

Discussion

LV thrombus following MI is associated with dreaded complications due to systemic embolization and portends a poor prognosis.^[7] There has been a significant reduction in the occurrence of LV thrombus post MI as compared to pre-PCI era. Several factors are responsible for the decline in the incidence of LV thrombus which includes widespread use of primary PCI which reduces infarct size, greater use of drugs that reduce LV remodeling, and use of better antithrombotic agents. However, rates of systemic embolism remain high in case a LV thrombus occurs. According to a meta-analysis, the rate of systemic embolism is around 9% and with use of anticoagulants there is a 33% absolute reduction in its incidence.^[8] According to a recent study, the rate of systemic embolism in post MI patients with LV thrombus was 16% over 5 years with a significant reduction with use of warfarin.^[2] In another study done by Leow *et al.*, acute ischemic stroke occurred in 11.8% of patients of AMI with LV thrombus. Although majority (76.5%) of these strokes were cardioembolic in nature, a significant proportion was due to small vessel disease (14.7%) or large vessel atherosclerosis (8.8%). The presence of protruding thrombus (hazard ratio [HR]-3.04, 95% confidence interval [CI] 1.25–7.41, $p=0.01$), failure of thrombus resolution (HR-3.03, 95% CI 1.23–7.45, $P=0.02$), and thrombus recurrence (HR-4.20, 95% CI 1.46–12.11, $P<0.01$) were found to be significant independent predictors for stroke in these patients.^[9]

The incidence of stroke following AMI was 1.7% to 2.4% in the pre thrombolytic era, with a mortality rate of

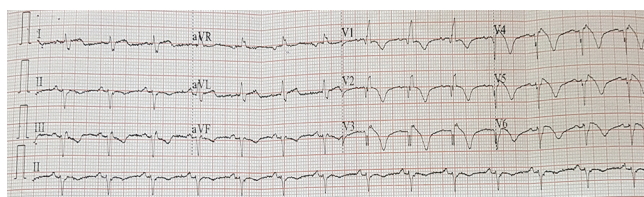


Figure 1: Twelve-lead electrocardiogram showed NSR, QRBBB pattern with ST-elevation V2-V6, I, a VL suggestive of acute anterior wall myocardial infarction

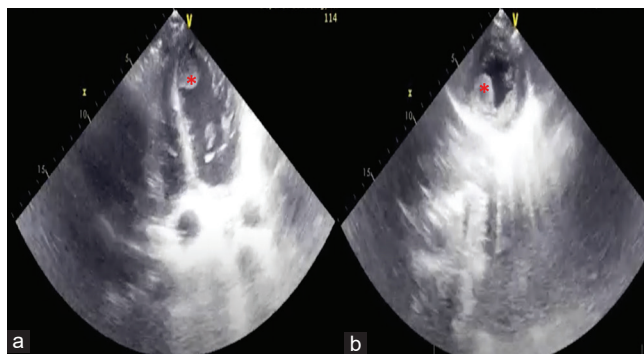


Figure 2: (a) Two-dimensional echocardiography four-chamber view showing large apical left ventricle clot measuring 1.8 cm × 2.2 cm (*). (b) Parasternal short-axis view at the level of papillary muscles showing large apical left ventricle clot measuring 1.9 cm × 2.3 cm (*)

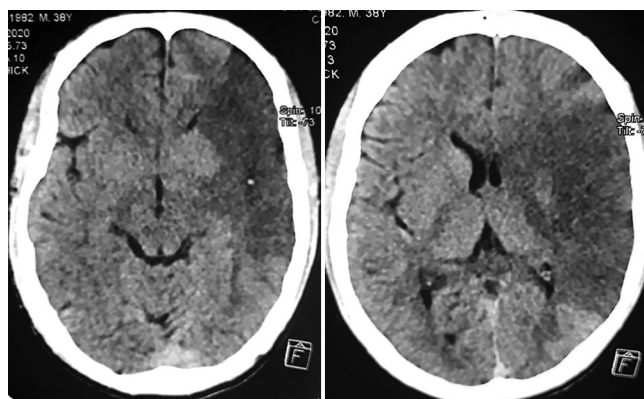


Figure 3: Cross-section images on NCCT scan showing large infarct (*) in the middle cerebral artery territory occupying more than half of the left brain area hence compressing ventricle

as high as 50% to 60%. According to the recent studies, the incidence of ranges between 0.7 and 2.2%.^[10] While the rate of concomitant occurrence is only 0.009%.- The short-term and 1-year mortalities ranges between 30.1 and 36.5% when AMI is complicated by ischemic stroke.^[10]

It is extremely rare to find a case with simultaneous involvement of coronary and cerebral circulation along with LV thrombus. We would like to term this unfortunate trilogy as “cardio-ventriculo-cerebral” infarction or ventricular variant of “cardiocerebral” infarction. The management is highly difficult as on the one hand, the presence of AMI, especially with LV thrombus requires

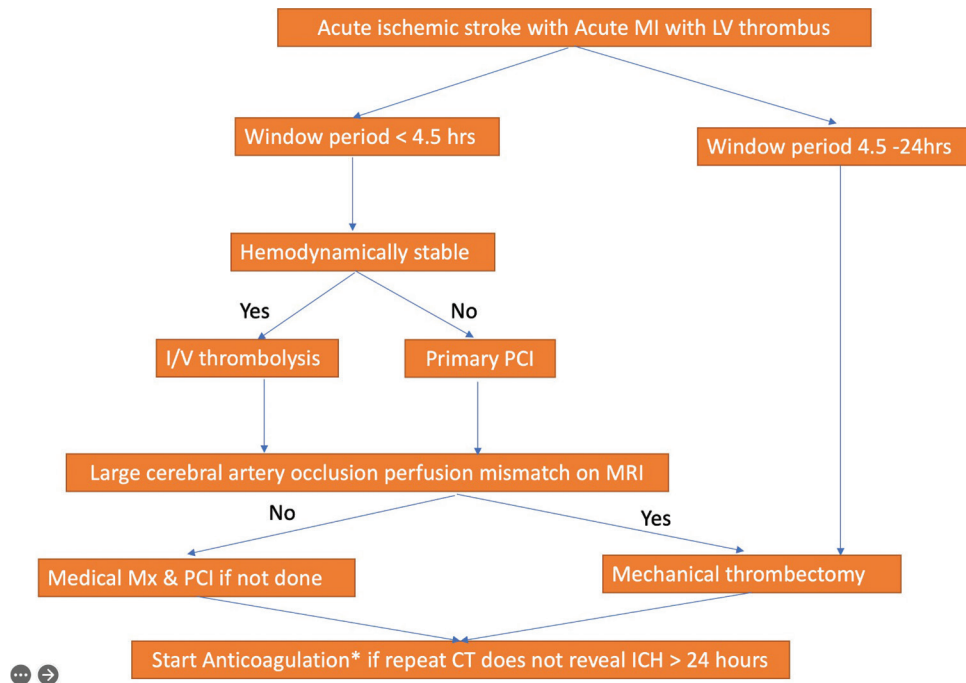


Figure 4: Algorithm for the management of the patient with simultaneous acute myocardial infarction with LV thrombus with acute ischemic stroke. *-The choice of anticoagulant OAC/NOAC will depend on bleeding risk with HAS-BLED score with NOAC's being preferred in patients with score > 3. A dual therapy should be preferred instead of triple therapy to reduce bleeding risk. (CT: Computed tomography; MRI: Magnetic resonance imaging; PCI: Percutaneous coronary intervention; STEMI: ST-elevation myocardial infarction)

both antiplatelet and anticoagulant agents, and on the other hand, their use may lead to hemorrhagic transformation of cerebral infarct, especially if it is large. In fact, most of the guidelines do not address this condition because of a lack of any direct evidence.^[11] According to a study done by Sandercock *et al.*, the pooled risk of hemorrhagic transformation in patients undergoing anticoagulation 1 to 2 weeks after ischemic stroke is 1.4%.^[12] There are no evidence-based guidelines and neither any randomized studies have been done in patients presenting with AMI and acute ischemic stroke. Depending on the clinical condition, decision to deal with one vascular bed over the other in priority can be made which obviously could adversely affect the other affected area. If a patient comes within a window period for acute stroke, best would be mechanical thrombectomy for the stroke (can be done up to 6 h of last seen normal neurologically and up to 24 h if stroke involves anterior circulation) along with primary PCI for AMI. However, if facilities for primary PCI or mechanical thrombectomy or are not available, thrombolysis can be done for a window period of up to 4.5 h.^[10] However, if there is a large cerebral artery occlusion or if the National Institute of Health Stroke Scale (NIHSS) is high, the patient should undergo mechanical thrombectomy as there are high chances of secondary intracranial hemorrhage in such situations. After this intervention, the patient can be put on intravenous heparin and antiplatelets can be started if repeat NCCT does not demonstrate any secondary intracranial hemorrhage. The patient can be taken for PCI later if not done priori or can be managed medically

depending on patient's clinical and hemodynamic status. If there is evidence of LV thrombus also (as in our case patient), he will need additional OAC therapy at discharge, although there is no data for optimal antithrombotic management in this situation [Figure 4].

To date, no randomized study has been done in the setting of AMI with LV thrombus to formulate optimal antithrombotic regimen in them. The American guidelines recommend DAPT with OAC for 3 months in such situation, whereas the European guidelines recommend the same for 6 months.^[13,14] However, triple therapy increases the bleeding risk substantially.^[13] Several randomized studies have shown that dual therapy (SAPT with OAC) is comparable to triple therapy (DAPT with OAC) in efficacy with less bleeding risk.^[5,6,15] In case the patient is not able to achieve therapeutic INR with warfarin, NOACs can be used safely. Although there are only small supporting data on the use of DOAC for LV thrombus, but the increased safety and efficacy of these agents in other settings, especially where the thromboembolic risk is around 3% or more their use in these high-risk patients a valid consideration.^[16] In a small retrospective study of Hasan Iqbal, there was no difference in terms of safety and efficacy between Vitamin K antagonists and NOACs.^[16] Similarly, in another retrospective analysis of 98 patients with LV thrombus, 36% of which were treated with NOACs, there were no differences in rates of stroke or systemic embolization.^[17] A meta-analysis of four NOAC trials comparing dual versus triple therapy for atrial fibrillation patients undergoing PCI

found a significant reduction in bleeding.^[18] Extrapolating the encouraging results, anticoagulation regimen for MI with LV thrombus may be simplified by the use of novel dual therapy (NOAC plus SAPT), although these patients were not specifically in these NOAC trials. The use of a bleeding score like HAS-BLED may help to stratify patients at high bleeding risk who can benefit from preferential use of dual therapy (either OAC or NOAC) in such a scenario. A HAS-BLED score >3 would justify the use of NOAC in such a scenario.

Conclusions

The simultaneous occurrence of cardiac and cerebral infarct with LV thrombus in addition is extremely rare. Further, it is very unusual to find such a combination, especially within 24 h of AMI. A presence of hereditary thrombophilia might be a possibility; however, the patient could not be investigated for the same. The management of this complex combination is highly challenging and demands immediate attention. The management should be made on case to case basis and to be guided by the patient's hemodynamic status which can direct the physician which infarct should be dealt first. Large clinical trials and studies are needed to delineate the optimal anticoagulation strategies for such uncommon scenarios.

Declaration of patient consent

The authors certify that they have obtained all appropriate patient consent forms. In the form, the patient(s) has/have given his/her/their consent for his/her/their images and other clinical information to be reported in the journal. The patients understand that their names and initials will not be published and due efforts will be made to conceal their identity, but anonymity cannot be guaranteed.

Financial support and sponsorship

Nil.

Conflicts of interest

There are no conflicts of interest.

References

- Solheim S, Seljeflot I, Lunde K, Bjornerheim R, Aakhus S, Forfang K, *et al.* Frequency of left ventricular thrombus in patients with anterior wall acute myocardial infarction treated with percutaneous coronary intervention and dual antiplatelet therap. *Am J Cardiol* 2010;106:1197-200.
- Maniwa N, Fujino M, Nakai M, Nishimura K, Miyamoto Y, Kataoka Y, *et al.* Anticoagulation combined with antiplatelet therapy in patients with left ventricular thrombus after first acute myocardial infarction. *Eur Heart J* 2018;39:201-8.
- Obaid O, Smith HR, Brancheau D. Simultaneous acute anterior ST-elevation myocardial infarction and acute ischemic stroke of left middle cerebral artery: A case report. *Am J Case Rep* 2019;20:776-9.
- Nikolsky E, Mehran R, Dangas GD, Yu J, Parise H, Xu K, *et al.* Outcomes of patients treated with triple antithrombotic therapy after primary percutaneous coronary intervention for ST-elevation myocardial infarction (from the Harmonizing Outcomes with Revascularization and Stents in Acute Myocardial Infarction [HORIZONS-AMI] trial). *Am J Cardiol* 2012;109:831-8.
- Cannon CP, Bhatt DL, Oldgren J, Lip GY, Ellis SG, Kimura T, *et al.* Dual antithrombotic therapy with dabigatran after PCI in atrial fibrillation. *N Engl J Med* 2017;377:1513-24.
- Dewilde WJ, Oirbans T, Verheugt FW, Kelder JC, De Smet BJ, Herrman JP, *et al.* Use of clopidogrel with or without aspirin in patients taking oral anticoagulant therapy and undergoing percutaneous coronary intervention: An open-label, randomised, controlled trial. *Lancet* 2013;381:1107-15.
- McCarthy CP, Verma S, Bhatt DL. The management of antiplatelet and antithrombotic regimens in patients with mechanical valves undergoing percutaneous coronary intervention: A forgotten cohort? *JAMA Cardiol* 2017;2:713-4.
- Vaitkus PT, Barnathan ES. Embolic potential, prevention and management of mural thrombus complicating anterior myocardial infarction: A meta-analysis. *J Am Coll Cardiol* 1993;22:1004-9.
- Leow AS, Sia CH, Tan BY, Kaur R, Yeo TC, Chan MY, *et al.* Characterisation of acute ischemic stroke in patients with left ventricular thrombi after myocardial infarction. *J Thromb Thrombolysis* 2019;48:158-66.
- Bhandari M, Vishwakarma P, Sethi R, Pradhan A. Stroke complicating acute ST elevation myocardial infarction-current concepts. *Int J Angiol* 2019;28:226-30.
- Lansberg MG, O'Donnell MJ, Khatri P, Lang ES, Nguyen-Huynh MN, Schwartz NE, *et al.* Antithrombotic and thrombolytic therapy for ischemic stroke: Antithrombotic therapy and prevention of thrombosis, 9th ed: American College of Chest Physicians Evidence-Based Clinical Practice Guidelines. *Chest* 2012;141 Suppl 2:e601S-36S.
- Sandercock PA, Counsell C, Kane EJ. Anticoagulants for acute ischaemic stroke. *Cochrane Database Syst Rev* 2015;2015:CD000024.
- O'Gara PT, Kushner FG, Ascheim DD, Casey DE Jr., Chung MK, de Lemos JA, *et al.* 2013 ACCF/AHA guideline for the management of ST-elevation myocardial infarction: A report of the American College of Cardiology Foundation/American Heart Association task force on practice guidelines. *Circulation* 2013;127:362-425.
- Ibanez B, James S, Agewall S, Antunes MJ, Bucciarelli-Ducci C, Bueno H, *et al.* 2017 ESC Guidelines for the management of acute myocardial infarction in patients presenting with ST-segment elevation: The Task Force for the management of acute myocardial infarction in patients presenting with ST-segment elevation of the European Society of Cardiology (ESC). *Eur Heart J* 2018;39:119-77.
- Fiedler KA, Maeng M, Mehilli J, Schulz-Schüpke S, Byrne RA, Sibbing D, *et al.* Duration of triple therapy in patients requiring oral anticoagulation after drug-eluting stent implantation: The ISAR-TRIPLE trial. *J Am Coll Cardiol* 2015;65:1619-29.
- Iqbal H, Straw S, Craven TP, Stirling K, Wheatcroft SB, Witte KK. Direct oral anticoagulants compared to vitamin K antagonist for the management of left ventricular thrombus. *ESC Heart Fail* 2020;7:2032-41.
- Robinson A, Ruth B, Dent J. Direct oral anticoagulants compared to warfarin for left ventricular thrombi: A single center experience. *J Am Coll Cardiol* 2018;71:A981.
- Lopes RD, Hong H, Harskamp RE, Bhatt DL, Mehran R, Cannon CP, *et al.* Safety and efficacy of antithrombotic strategies in patients with atrial fibrillation undergoing percutaneous coronary intervention: A network meta-analysis of randomized controlled trials. *JAMA Cardiol* 2019;4:747-55.