



# COVID-19 Associated Vertebral Osteomyelitis Caused by *Aspergillus* Species—A Case Series

Parikshit S. Prayag<sup>1</sup> · Bharat D. Purandare<sup>1</sup> · Sampada A. Patwardhan<sup>2</sup> · Pradyumna P. Pairaiturkar<sup>3</sup> · Amol J. Rege<sup>3</sup> · Arvind V. Bhav<sup>3</sup> · Ramya S<sup>1</sup> · Shweta P. Panchakshari<sup>1</sup> · Poorana T. Raja<sup>3</sup> · Advait S. Melinkeri<sup>4</sup> · Amrita P. Prayag<sup>5</sup>

Received: 18 November 2021 / Accepted: 24 March 2022 / Published online: 15 April 2022  
© Indian Orthopaedics Association 2022

## Abstract

Coronavirus Disease (COVID-19) associated fungal infections including pulmonary aspergillosis, mucormycosis and other invasive fungal infections have been increasingly described in the current pandemic. *Aspergillus* osteomyelitis is a rare clinical form of aspergillosis. Most cases of *Aspergillus* osteomyelitis are reported in immunocompromised patients. We describe four cases of vertebral osteomyelitis caused by *Aspergillus* species in the post COVID-19 setting. To the best of our knowledge, *Aspergillus* vertebral osteomyelitis has not been described in the post COVID-19 setting. None of the four patients described in this series were immunocompromised and all of them had received steroids during their hospitalization for COVID-19 pneumonitis. Vertebral osteomyelitis caused by *Aspergillus* species is a rare clinical manifestation of Aspergillosis. It requires a high index of suspicion and prompt efforts to establish a diagnosis. For a clinician involved in assessing a patient with Spondylodiscitis, the work up must not be limited to testing for Tuberculosis. Every attempt must be made to establish the microbiological diagnosis. Combined medical and surgical management is generally needed for *Aspergillus* osteomyelitis.

**Keywords** Aspergillus vertebral osteomyelitis · Post COVID

## Introduction

COVID-19 associated fungal infections including pulmonary aspergillosis, mucormycosis and other invasive fungal infections have been increasingly described in the current pandemic [1, 2]. *Aspergillus* osteomyelitis is a rare clinical form of aspergillosis. Most cases of *Aspergillus* osteomyelitis are reported in immunocompromised patients. It

is difficult to diagnose and requires a high index of suspicion. *Aspergillus* vertebral osteomyelitis can closely mimic tubercular vertebral involvement, and hence, requires further microbiological and histopathological work-up to establish the diagnosis. Therapy is often prolonged and outcomes can be grave. In a review of 310 cases of *Aspergillus* osteomyelitis published in 2014, the crude mortality was found to be 25% [3]. We describe four cases of vertebral osteomyelitis caused by *Aspergillus* species in the post COVID-19 setting. This is a case series of 4 patients who developed *Aspergillus* osteomyelitis after Covid19 illness. There is history of receipt of steroid in all the 4 patients. Based on this limited knowledge, it is difficult to attribute fungal Discitis to solely either Covid19 illness vs use of steroids. None of the patients were vaccinated against Covid19. The Covid19 status of all 4 patients was checked during the time of spinal infection and was negative. To the best of our knowledge, this is the first case series of COVID-19 associated vertebral osteomyelitis caused by *Aspergillus* species (Figs 1, 2, 3, 4, 5, 6, 7, 8, 9, 10, 11 and 12).

✉ Parikshit S. Prayag  
pprayag100@gmail.com

<sup>1</sup> Department of Infectious Diseases, Deenanath Mangeshkar Hospital, Pune, India

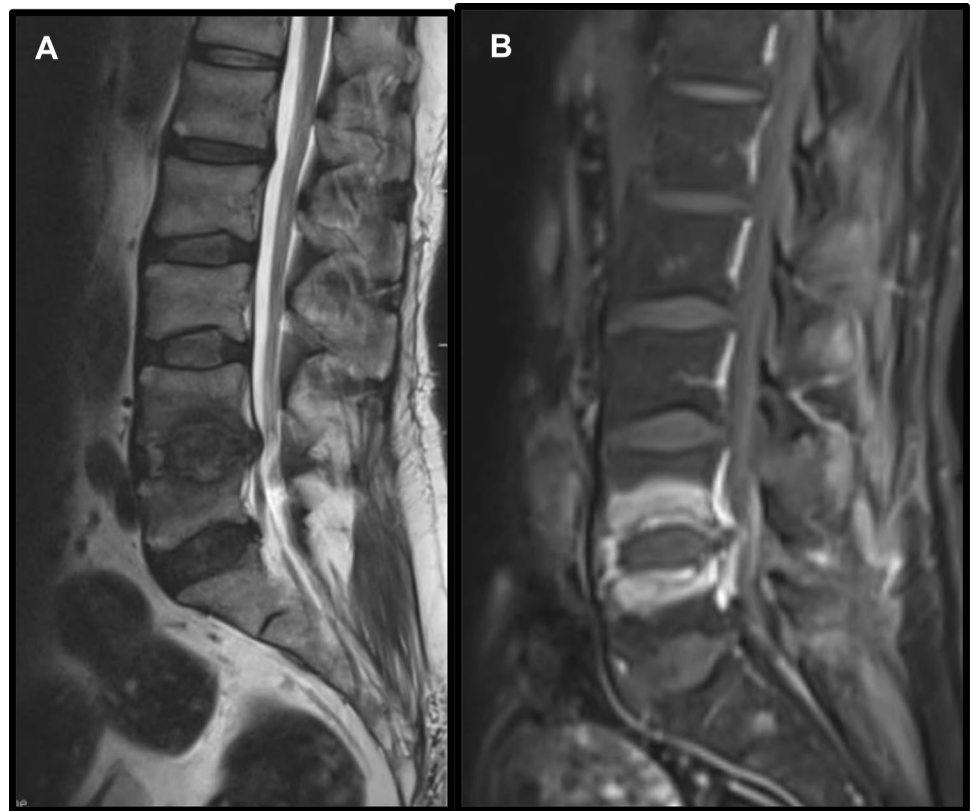
<sup>2</sup> Department of Microbiology, Deenanath Mangeshkar Hospital, Pune, India

<sup>3</sup> Department of Orthopedics, Deenanath Mangeshkar Hospital, Pune, India

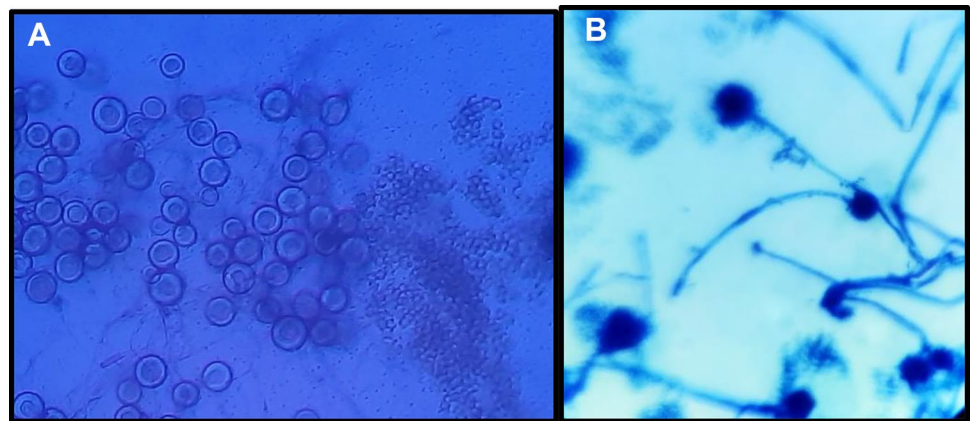
<sup>4</sup> Bharati Vidyapeeth Deemed University College of Medicine, Pune, India

<sup>5</sup> Department of In-House Research, Deenanath Mangeshkar Hospital, Pune, India

**Fig. 1** **A:** Sagittal view Magnetic Resonance imaging (MRI) of the lumbosacral spine showing T2/STIR (Short Tau Inversion Recovery) hypointense signal within the L4-L5 intervertebral disc and the adjacent L4 and L5 vertebral endplates along with prevertebral soft tissue collection. **B:** Sagittal view post contrast T1 view suggestive of post contrast uniform enhancement of L4-L5 endplate with non enhancement of intervertebral disc. Also shows Epidural extension with spinal cord indentation. Small peripherally enhancing partially liquefied prevertebral collections at the L4-L5 disc level are seen, suggestive of abscess



**Fig. 2** **A:** Lactophenol cotton blue (LPCB) stain showing Hulle cells of *Aspergillus nidulans*. **B:** LPCB stain showing mature conidiophores of *Aspergillus nidulans*, bearing chains of conidia

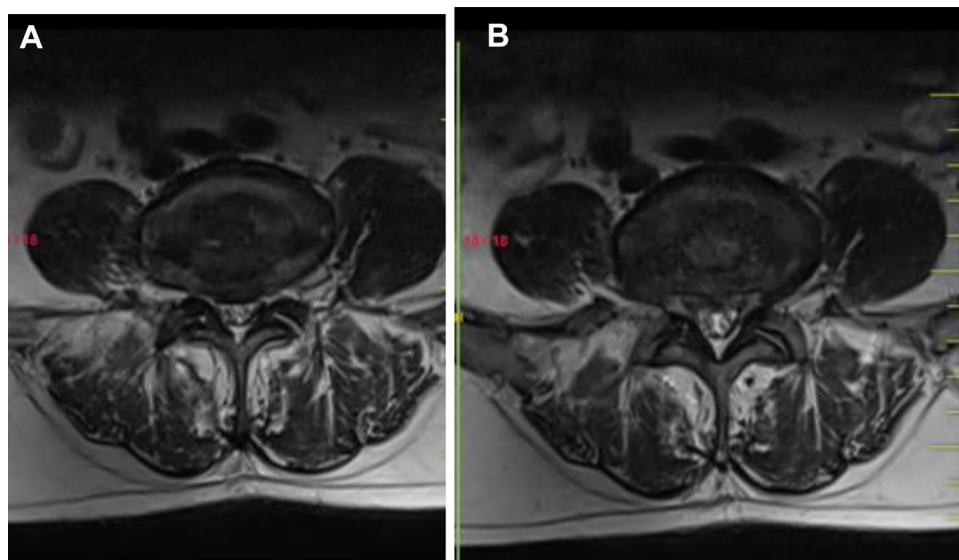


## Case 1

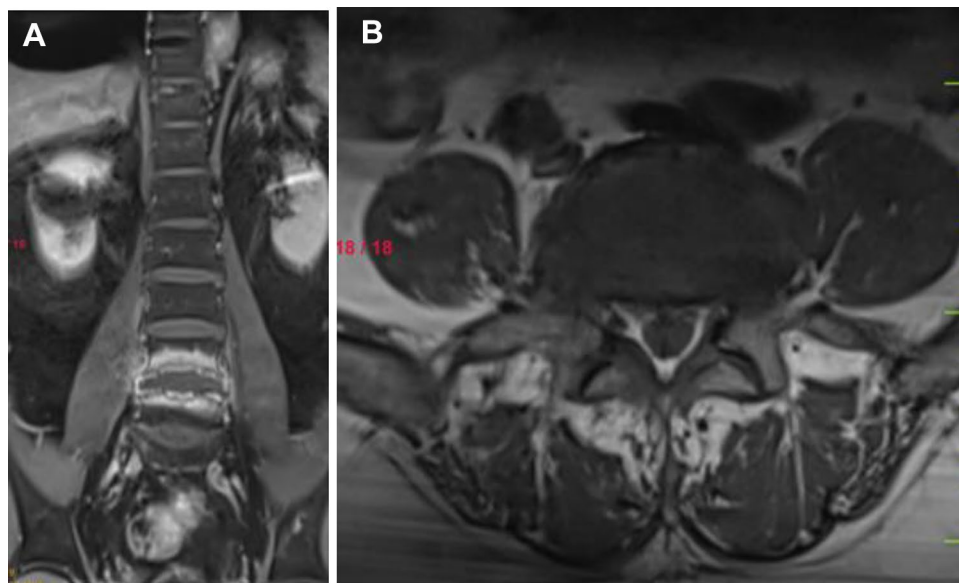
A 70-year-old male with a past medical history of diabetes mellitus and hypertension was admitted with severe COVID-19 pneumonitis. He was administered remdesivir for 5 days, and required dexamethasone for 10 days (4 mg twice a day). He was not administered any other immunomodulators. He was discharged in a stable condition. Three weeks later, he presented with low grade fever and lower back pain. He underwent a magnetic resonance imaging (MRI) of the thoracolumbar spine which showed

a T1 hypointense, STIR (Short Tau Inversion Recovery) hyperintense signal within the L4-L5 intervertebral disc and the adjacent L4 and L5 vertebral endplates along with bilateral partially liquefied paravertebral abscesses at the L4-L5 disc level. He underwent a transpedicular vertebral biopsy which was inconclusive, and hence, was taken up for decompression. He then underwent an antero-lateral L4-5 debridement, discectomy, decompression and iliac crest bone grafting. The bone tissue on Calcofluor and KOH staining showed acute branching, narrow hyphae, suggestive of *Aspergillus*. Work up for Tuberculosis, including the Xpert MTB/RIF assay (Cepheid, Sunnyvale,

**Fig. 3** **A** and **B**: T2 axial images showing discitis with very minimal para-vertebral Component



**Fig. 4** **A** and **B**: MRI Coronal (A) and T1 axial (B) images

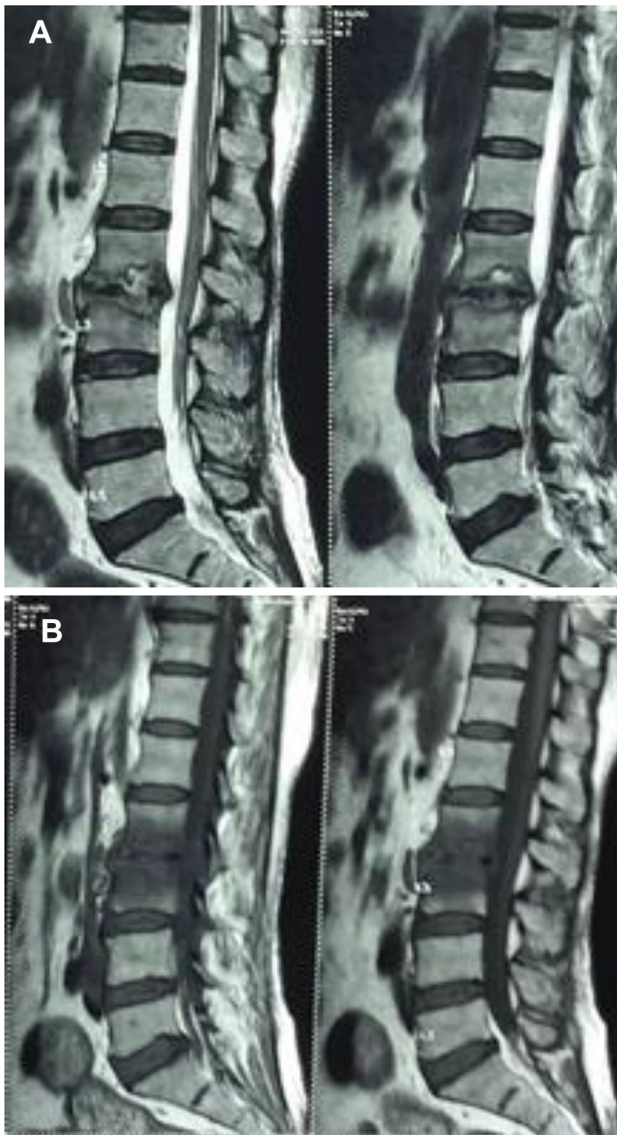

CA, USA) as well as acid fast staining, was negative. The bone tissue culture showed fungal growth of *Aspergillus* species suggestive of *Aspergillus nidulans* based on typical morphological features such as short conidiophores, biserial phialides covering the upper half of the vesicle, and presence of Hülle cells. He was initiated on voriconazole and has completed three weeks of therapy so far, with partial resolution of the back pain, and complete resolution of the fever.

## Case 2

A 66-year-old male with no comorbidities was admitted for COVID-19 pneumonitis. He was treated with remdesivir, supplemental oxygen and 7 days of oral dexamethasone (4 mg twice a day). He was discharged home, but presented after one month with low grade fevers and severe low back pain. His X-ray showed L2-L3 disc space





**Fig. 5** **A** and **B**: T2 Sagittal (**A**) and T1 Sagittal (**B**) MRI images showing discitis with L2 Vertebral abscess

erosion with adjoining vertebral body involvement. An MRI of the spine revealed an L2-L3 spondylodiscitis with a small paravertebral collection without any epidural collection. Even though patient did not have epidural collection or neurological involvement—severe instability back pain warranted one-time treatment for the patient with biopsy and stabilization with iliac crest bone graft. The procedure opted for him was antero-lateral retroperitoneal debridement with iliac crest bone grafting as a structural support.

No instrumentation or implants used. He underwent antero-lateral L2-L3 debridement, discectomy, decompression and iliac crest bone grafting. Was taken for decompression in view of severe right lower limb radiculopathy and weakness.

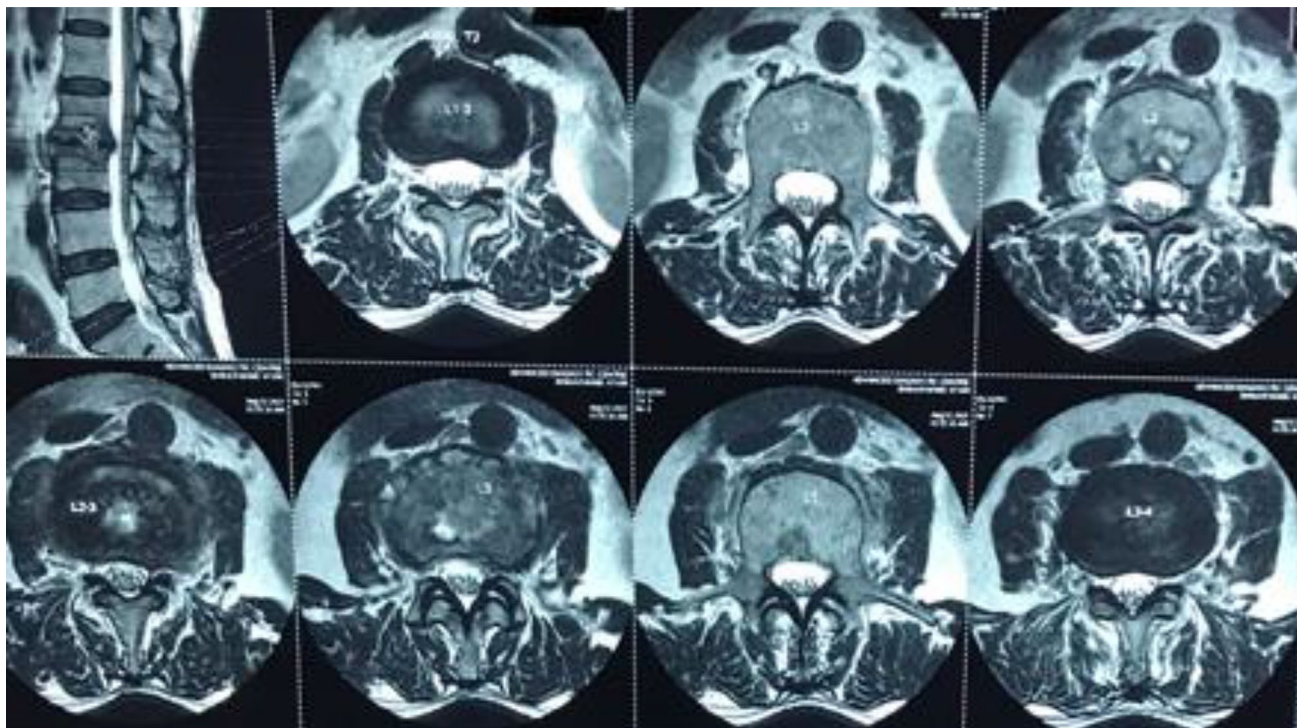
The debrided tissue showed degenerated fibrocartilaginous disc material along with focal areas of necrosis mixed with acute on chronic inflammatory exudate mainly composed of neutrophils, few hemosiderin laden macrophages, plasma cells and lymphocytes. Serum galactomannan level was 5.854. Fungal culture of debrided tissue showed growth of *Aspergillus fumigatus*. He was started on voriconazole and has completed two weeks of therapy with resolution of fever.

### Case 3

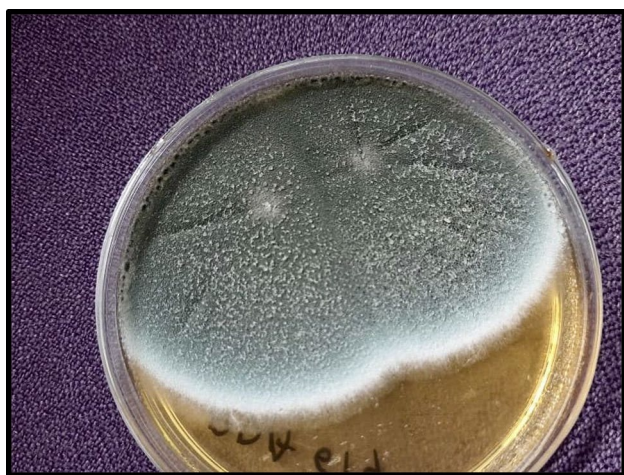A 67-year-old male with a past history of pulmonary tuberculosis was admitted with severe COVID-19 pneumonitis. He required supplemental oxygen for 15 days, and also received remdesivir for five days and dexamethasone for 14 days (4 mg twice a day). He was discharged and approximately two months later developed low back pain with some difficulty in walking. He underwent biopsy from the vertebral collection and was empirically started on anti-tubercular therapy. However, he had progressive difficulty in walking over the next two weeks and was referred to our center. A repeat MRI Spine showed D9-D10/D12-L1 spondylodiscitis. The lesion at D9-D10 has increased in size in comparison to the previous scan, and also showed cord compression at that level. He then underwent decompression and posterior pedicle fixation. The histopathology of the tissue showed degenerated disc material with many foci of infarcted disc tissue and mixed inflammatory infiltrates composed of neutrophils, eosinophils, lymphocytes and plasma cells. Fungal culture of the bone tissue demonstrated a growth of *Aspergillus fumigatus* and he was started on oral voriconazole therapy, and is currently in the third week of therapy.

### Case 4

A 42-year-old male with no known comorbidities was admitted with COVID-19 pneumonitis and needed supplemental oxygen. He was treated with remdesivir and dexamethasone for 10 days (4 mg twice a day) following which he was discharged. 10 weeks following the onset of COVID-19, he developed lower back pain. MRI of the spine showed abnormal signal intensity at the end plates of L2-L3 which was T2/STIR hyperintense and T1 hypointense. No evidence of prevertebral or epidural collection was found. Patient had severe back pain with severely restricted lumbar range of movements for 3 weeks. His X-ray showed endplate erosion and adjoining body destruction at the involved level. This was the main indication to perform stabilization and decompression to start early ambulation. He underwent debridement and decompression with pedicle screw fixation at L2-L3 level. Fungal culture from the debrided tissue grew



**Fig. 6** Axial T2 weighted images with vertebral and disc abscess with para-vertebral Soft tissue component



**Fig. 7** Potato Dextrose Agar showing grey-green velvety colonies with a narrow white border suggestive of *Aspergillus fumigatus*

*Aspergillus fumigatus*. His serum galactomannan was 1.73, and beta D glucan level was 72 pg/ml. He has been started on voriconazole and awaits clinical recovery (Table 1).

## Discussion

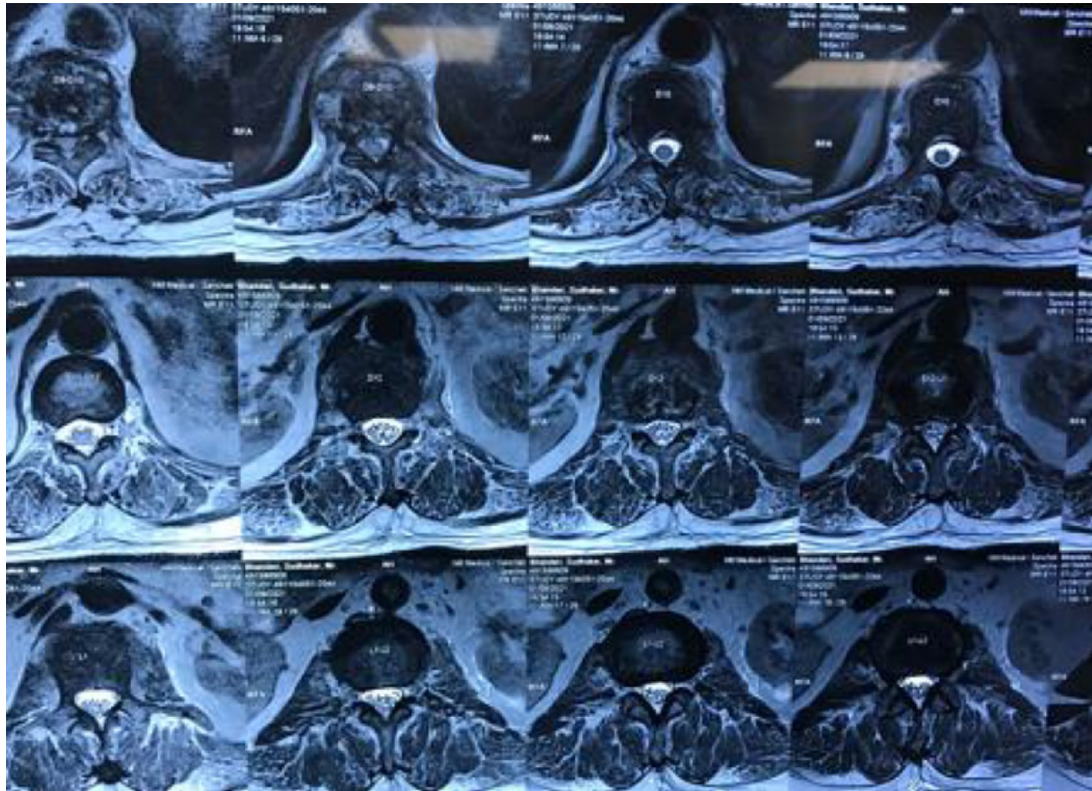
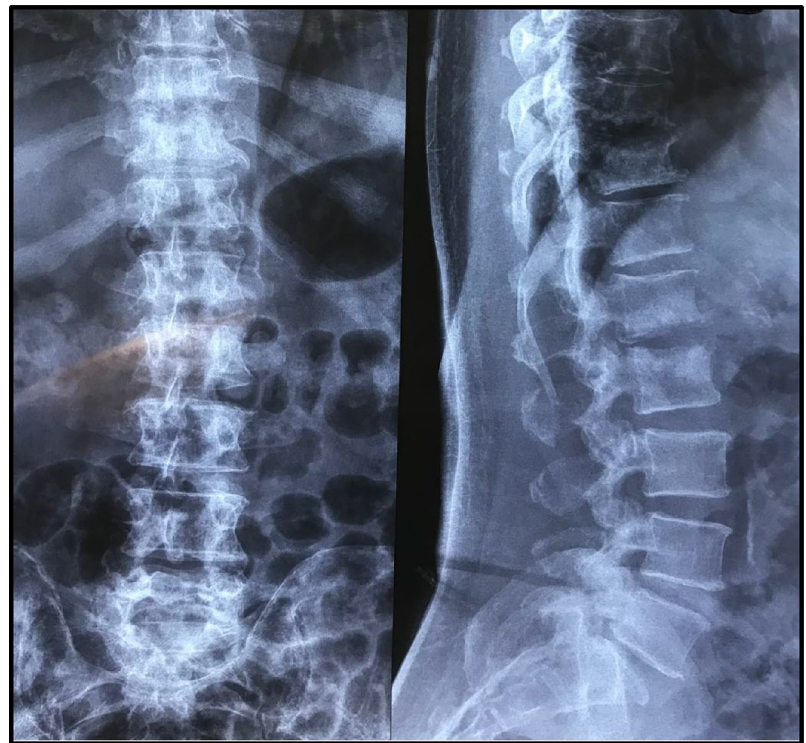
Aspergillosis is an opportunistic fungal infection predominantly involving the respiratory tract. The involvement of the musculoskeletal system is rare and of those, approximately half involve the spine [4–6]. The pathogenesis of *Aspergillus* vertebral osteomyelitis involves contiguous spread from the adjacent lung foci, hematogenous seeding of bone tissue by bloodborne route or direct inoculation during trauma or surgery [4].

To our knowledge, *Aspergillus* vertebral osteomyelitis has not been described in the post COVID-19 setting. None of the four patients described in this series were immunocompromised and all of them had received steroids during their hospitalization for COVID-19 pneumonitis. One patient had a history of diabetes mellitus which was controlled at the time of onset of osteomyelitis. None of these patients received steroids for more than two weeks, and all of them received dexamethasone. They did not receive any other immunomodulator during their course of illness. The timeline of developing symptoms of vertebral osteomyelitis was variable (5 weeks to 11 weeks). Of note, none of them showed pulmonary involvement with *Aspergillus*.

Patients with *Aspergillus* vertebral osteomyelitis may not have any clinical tell-tale signs. The most common symptom is lower back pain, with or without fever [4]. A high index of suspicion is required, as these patients in the Indian

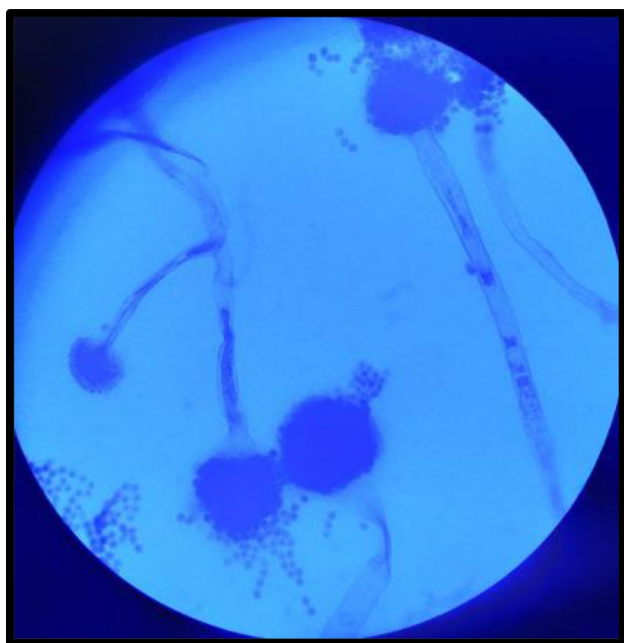
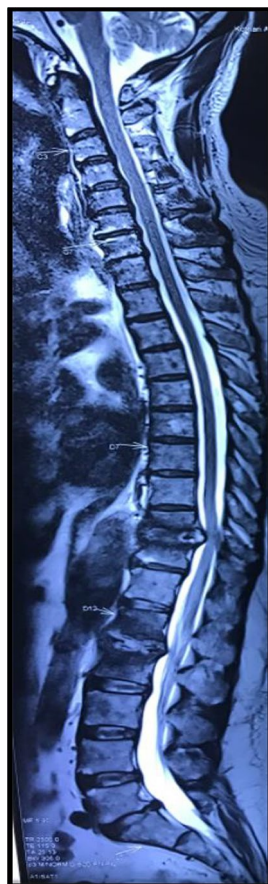

**Fig. 8** Plain X ray of the patient showing marked endplate irregularity and destruction at D9-D10 and D12-L1 levels



**Fig. 9** Sagittal and axial MRI images showing two level involvement with D9-D10 Conus compression

**Fig. 10** MRI Spine of the same patient—T2 weighted whole spine mid-sagittal cut showing skip lesions at D9-D10 and D12-L1 levels. Epidural cord compression at the level of D9-D10



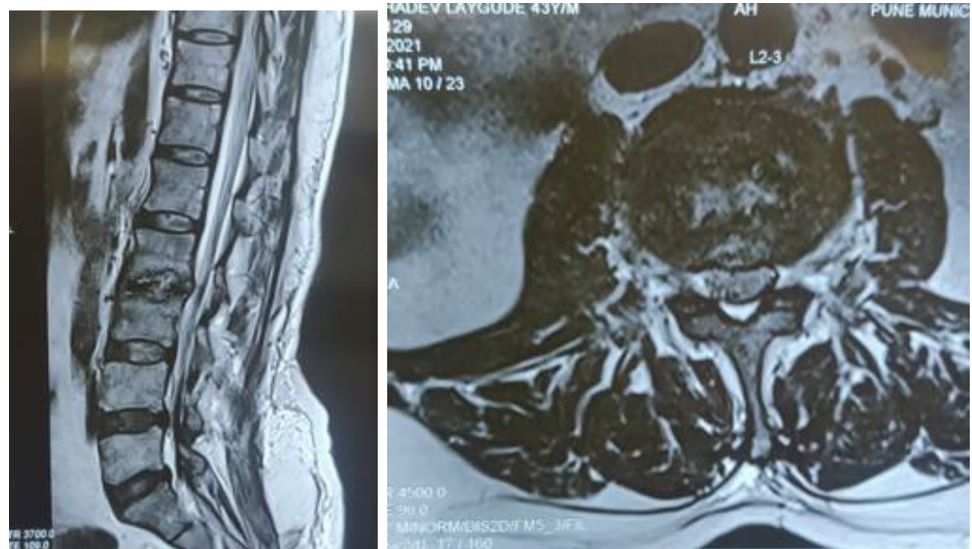
**Fig. 11** LPCB stain from the growth obtained on fungal culture demonstrating narrow septate conidiophores with phialides covering the upper two-third surface of the vesicle suggestive of *Aspergillus fumigatus*

setting often receive empiric therapy for Tuberculosis. In a review of 180 cases of *Aspergillus* osteomyelitis, the commonest MRI findings included decreased signal intensity on T1-weighted images and increased signal intensity on T2-weighted images as well as increased gadolinium contrast enhancement of T1-weighted images [4]. Establishing a diagnosis of proven *Aspergillus* osteomyelitis involves demonstrating growth of *Aspergillus* in bone cultures or histopathological evidence of *Aspergillus* in the bone tissue, in the proper clinical and radiographic settings [4]. All the four patients described in this series had compatible clinical and radiographic findings and the bone cultures grew *Aspergillus* species. The commonest species described in this setting has been *Aspergillus fumigatus*. In three out of the four cases, the bone culture grew *Aspergillus fumigatus* while bone culture in one case grew *Aspergillus nidulans*. The sensitivity of serum galactomannan has not been well established in this setting. Of the four patients described here, galactomannan was available only for two patients and was positive in both these cases. While a positive galactomannan would support the diagnosis, it would be difficult to rule out *Aspergillus* osteomyelitis based on a negative galactomannan. A CT-guided puncture biopsy should be performed as soon as possible to establish the diagnosis in such cases and guide antimicrobial therapy. CT-guided biopsy can be less invasive than an intraoperative biopsy, however adequate samples may not be obtained [7].

The management of *Aspergillus* osteomyelitis is challenging and involves a combination of medical and surgical therapies [5]. Spinal instability, spinal nerve compression, or presence of epidural abscess may be indications for surgical intervention [7]. Various factors have to be kept in mind while choosing the antifungal therapy and include the species of *Aspergillus* involved, the minimum inhibitory concentrations (MICs), bone penetration of antifungal drugs, toxicities, interactions and cost of therapy. Voriconazole remains the drug of choice. Ensuring adequate levels of voriconazole, checking for interactions, and recognizing the toxicities associated with voriconazole are important aspects of management. Posaconazole and Isavuconazole are emerging options, while amphotericin is used in patients with azole resistant Aspergillosis.

These patients often require a long duration of antifungal therapy. In a review of 180 cases of *Aspergillus* osteomyelitis, the median duration of therapy was 90 days (10–772 days). Also, in this review, there were fewer relapses in the group treated with combined medical and surgical therapy [4]. All the four patients in this case series have undergone surgical therapy and are currently on voriconazole therapy with adequate drug levels. In a patient who does not respond clinically, ensuring adequate levels of the azole drug, ruling out drug resistance, ensuring compliance and re-evaluating the need for surgical therapy should be



**Fig. 12** Sagittal and axial images at L2-L3 level**Table 1** Summary of the 4 cases of COVID-19 associated *Aspergillus* vertebral osteomyelitis

Characteristic	Patient 1	Patient 2	Patient 3	Patient 4
Age (years)	70	66	67	42
Gender	Male	Male	Male	Male
Comorbidities	Diabetes mellitus Hypertension	None	Pulmonary tuberculosis	None
Species grown on fungal culture	<i>Aspergillus nidulans</i>	<i>Aspergillus fumigatus</i>	<i>Aspergillus fumigatus</i>	<i>Aspergillus fumigatus</i>
Location of lesion	L4-L5	L2-L3	D9-D10/ D12-L1	L2-L3
Serum galactomannan	Not done	5.854	Not done	1.73
Beta-D Glucan assay (pg/ml)	Not done	> 500	Not done	72
GeneXpert from the debrided tissue for MTB	Negative for MTB	Negative for MTB	Negative for MTB	Not done
Time interval between the onset of COVID-19 and onset of osteomyelitis (in weeks)	5	6	11	10
Duration of Steroids used in COVID19 treatment	10 days	7 days	14 days	10 days

done. Despite optimum management the mortality can be as high as 25% [4]. Control of risk factors including reduction of immunosuppressive therapy whenever applicable and feasible and tight glycemic control form vital components of the management of such patients.

In conclusion, vertebral osteomyelitis caused by *Aspergillus* species is a rare clinical manifestation of Aspergillosis. It requires a high index of suspicion and prompt efforts to establish a diagnosis. For a clinician involved in assessing a patient with Spondylodiscitis, the work up must not be limited to testing for Tuberculosis. Every attempt must be made to establish the microbiological diagnosis. Combined medical and surgical management is generally needed for *Aspergillus* osteomyelitis. Duration of medical therapy is often long, and requires managing

the associated toxicities, interactions and cost of therapy. To our knowledge this is the first case series of COVID-19 associated vertebral osteomyelitis caused by *Aspergillus* species reported in literature.

## Declarations

**Conflict of Interest** The authors declare that they have no conflict of interest.

**Ethical Approval** This article does not contain any studies with human or animal subjects performed by the any of the authors.

**Informed Consent** For this type of study informed consent is not required.



## References

1. Patel, A., Agarwal, R., Rudramurthy, S. M., et al. (2021). Multicenter epidemiologic study of coronavirus disease-associated mucormycosis. *India. Emerging Infectious Diseases.*, 27(9), 2349–2359. <https://doi.org/10.3201/eid2709.210934>
2. Dimopoulos, G., Almyroudi, M. P., et al. (2021). COVID-19-Associated Pulmonary Aspergillosis (CAPA). *Journal of Intensive Medicine.* <https://doi.org/10.1016/j.jointm.2021.07.001>
3. Gabrielli, E., Fothergill, A. W., Brescini, L., Sutton, D. A., Marchionni, E., Orsetti, E., Staffolani, S., Castelli, P., Gesuita, R., & Barchiesi, F. (2014). Osteomyelitis caused by *Aspergillus* species: a review of 310 reported cases. *Clinical Microbiology and Infection*, 20(6), 559–565. <https://doi.org/10.1111/1469-0691.12389>
4. Gamaletsou, M. N., Rammaert, B., Bueno, M. A., et al. (2014). *Aspergillus* osteomyelitis: Epidemiology, clinical manifestations, management, and outcome. *Journal of Information Security*, 68(5), 478–493.
5. Gabrielli, E., Fothergill, A. W., Brescini, L., et al. (2014). Osteomyelitis caused by *Aspergillus* species: A review of 310 reported cases. *Clinical Microbiology & Infection*, 20(6), 559–565.
6. Koehler, P., Tacke, D., & Cornely, O. A. (2014). Aspergillosis of bones and joints—a review from 2002 until today. *Mycoses*, 57(6), 323–335.
7. Dai, G., Wang, T., Yin, C., et al. (2020). *Aspergillus* spondylitis: Case series and literature review. *BMC Musculoskeletal Disorders*, 21(1), 572. <https://doi.org/10.1186/s12891-020-03582-x>

**Publisher's Note** Springer Nature remains neutral with regard to jurisdictional claims in published maps and institutional affiliations.