


Contents lists available at [ScienceDirect](#)

## Acta Orthopaedica et Traumatologica Turcica

journal homepage: <https://www.elsevier.com/locate/aott>

## Primary total knee arthroplasty for elderly complex tibial plateau fractures



Jie-Feng Huang <sup>a</sup>, Jian-Jian Shen <sup>b,\*</sup>, Jun-Jie Chen <sup>a</sup>, Pei-Jian Tong <sup>a</sup>

<sup>a</sup> Department of Orthopedics, The First Affiliated Hospital of Zhejiang Chinese Medical University, Hangzhou, China

<sup>b</sup> Department of Orthopedics, Wenzhou Medical College-Affiliated Cixi Hospital Cixi, Zhejiang, China

### ARTICLE INFO

#### Article history:

Received 21 November 2014

Accepted 28 March 2015

Available online 23 November 2016

#### Keywords:

Tibial plateau  
Fracture  
Arthroplasty  
Knee

### ABSTRACT

**Objective:** The aim of this study is to evaluate the clinical and radiologic results of primary Total Knee Arthroplasty (TKA) for elderly complex tibial plateau fractures.

**Materials and methods:** Between November 2010 and February 2012, six cases of elderly complex tibial plateau fractures were treated with primary TKA using the standard medial parapatellar approach. All six patients were available at follow up with mean duration of 32.3 months (range 25–41 months). There were 3 women and 3 men with an average age of 69.5 years (58–78 years) at the time of the arthroplasty.

**Results:** The mean Hospital for Special Surgery (HSS) knee score was 89.8 (range 85–94): 6/6 excellent. The mean knee flexion was 119.2° (105–130°). No significant postoperative complications were noted. None of these patients had significant postoperative knee pain required revision surgery, or had radiographic loosening of the components at the latest follow-up.

**Conclusions:** TKA is a suitable solution for the treatment of elderly patients with complex tibial plateau fractures.

**Level of Evidence:** Level IV, Therapeutic study

© 2016 Turkish Association of Orthopaedics and Traumatology. Publishing services by Elsevier B.V. This is an open access article under the CC BY-NC-ND license (<http://creativecommons.org/licenses/by-nc-nd/4.0/>).

### Introduction

Traditionally, complex displaced intra-articular fractures of the proximal tibia were treated by open reduction and internal fixation (ORIF),<sup>1,2</sup> external fixation,<sup>3</sup> and eventually secondary total knee arthroplasty (TKA)<sup>4,5</sup> in case of failure or complications.

Complex fractures of the tibial plateau present a surgical treatment challenge. Such injuries are usually the result of high-energy trauma, and the management of such fractures is associated with an increased incidence of soft-tissue damage, infection, loss of motion, development of posttraumatic arthritis, and knee instability.<sup>6–8</sup> High-grade injuries in elderly patients are more likely to lead to more severe arthritis. Marco Frattini et al only obtained satisfactory results (52.6% clinical outcomes and 31.6% radiographic outcomes, respectively) in elderly patients treated with ORIF of complex tibial plateau fractures.<sup>9</sup> Two recent literatures reported the incidence of posttraumatic arthritis following tibia plateau comminuted fracture of 39.1% and 58%, respectively.<sup>1,10</sup> Pre-existing

osteoarthritis and osteoporosis, cartilage damage during trauma, suboptimal reduction and fixation due to poor bone stock and/or secondary displacement frequently lead to poor outcome in elderly patients.

Despite the operation works, patients are also unable to have early full-weight bearing. Usually, a revision surgery, which is more difficult, is needed because of limb malalignment, anatomical deformity, posttraumatic arthritis, posttraumatic knee stiffness, pain and poor range of movement.<sup>4,5,11</sup> On the basis of the available data in the literature, one can deduce that the outcomes of TKA in patients with a prior fracture are inferior to those of primary TKA.<sup>11–13</sup> In addition, a multiple incisions operation before often leads to poor soft-tissue envelope and the infection also plays an important role.<sup>4,14–16</sup>

For the reasons above, we investigated the possibility to perform a TKA as a primary treatment in elderly patients with complex tibial plateau fractures. Although primary TKA for these fractures is not well-accepted treatment option as primary hip arthroplasty for femoral neck fractures.<sup>17</sup> However, primary TKA has the potential to bypass many of the above-mentioned difficulties and provide a stable knee for early full-weight bearing. The purpose of this study

\* Corresponding author.

E-mail address: [cryorthopaedic@163.com](mailto:cryorthopaedic@163.com) (J.-J. Shen).

was to evaluate the clinical and radiologic results of primary TKA with a minimum of 2-years follow-up in elderly patients with a complex tibial plateau fractures.

### Patients and methods

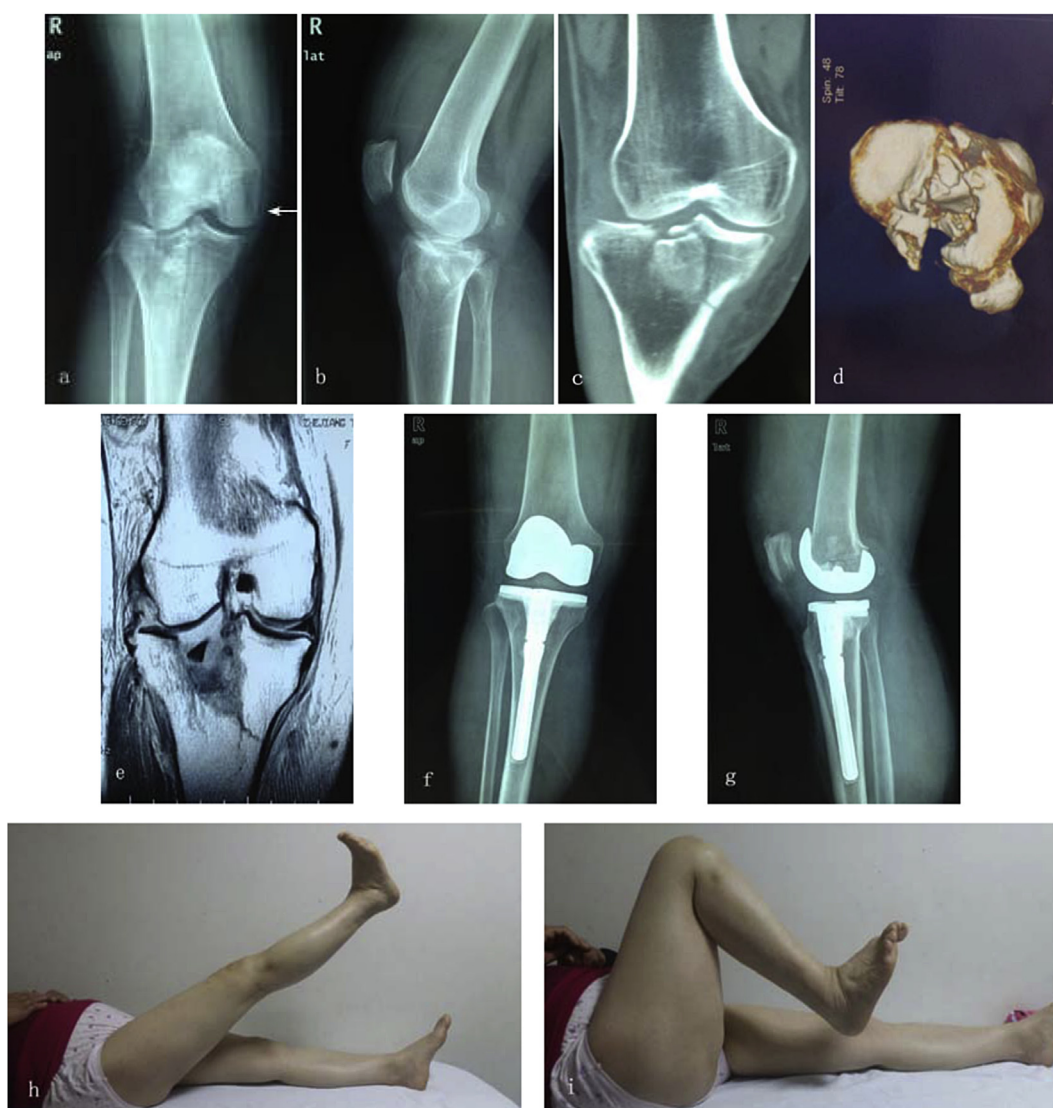Between November 2010 and February 2012, six patients with a closed complex tibial plateau fracture underwent primary TKAs and were included in this retrospective study. All six patients had unilateral plateau fractures. Leading causes of the fractures were high-energy traffic accidents and fallen from height. The Hospital Ethics committee approved the study protocol, and all patients gave their informed consent. They were at least 58 years old with poor bone quality and presenting with a complex tibial plateau fracture that would be difficult to treat with ORIF.

There were 3 women and 3 men, with an average age at the time of index operation of 69.5 years (range: 58–78). All were closed fractures. One case combined with a compromised knee subluxation and medial collateral ligament (MCL) injury (Fig. 1 a–e), three

with meniscus injuries, and one with anterior cruciate ligament (ACL) injury. Fractures were classified according to Schatzker Classification<sup>18</sup>: 4 of type-V and 2 of type-VI. The duration of clinical follow-up averaged 32.3 months (range: 25–41 months). Clinical evaluation was performed according to the Hospital for Special Surgery (HSS) knee score and radiographs of the knees. Information about type of Schatzker Classification, associated injuries, prosthesis, bone defect after resection, complications, immediate weight bearing, duration of hospitalization, knee motion and HSS was collected (Table 1).

### Surgical technique

All the procedures were performed by the Senior Author (Pei-Jian Tong). Using a pneumatic tourniquet applied about the upper thigh, the standard medial parapatellar approach was adopted. A medial parapatellar arthrotomy was performed in all the cases to evert the patella. Pay attention to prevent patellar tendon rupture while the surgeons attempt to obtain adequate exposure.



**Fig. 1.** Preoperative radiographs of a 58-year-old woman with Schatzker type-V complex tibial plateau fracture with a compromised knee subluxation and MCL injury (←) (a, b). Preoperative three-dimensional computed tomography (CT) and Magnetic Resonance Imaging (MRI), (c, d, e). Postoperative radiographs of the knee after performance of TKA for 2 years with NexGen LPS femoral component and NexGen LCCK tibial component, (f, g). Photographs of Knee ROM 2 years after surgery, (h, i). This patient had an excellent result for HSS knee score 92.

**Table 1**  
Summary of the patients treated with a TKA for a complex tibial plateau fracture.

Gender	Age	Fracture type (Schatzker)	Associated injuries	Type TKA	Bone defect after resection (mm)	Complications	Immediate weight bearing	Pain	Length of hospitalization (days)	ROM (°)	HSS final
Male	78	VI	Medial meniscus	NexGen LPS + LCCK	NC 2	None	FWB	None	20	0/0/120	88
Female	58	V	MCL and a knee subluxation	NexGen LPS + LCCK	C 6	None	FWB	None	19	0/0/120	92
Male	65	VI	None	NexGen LPS + LCCK	C 5	None	FWB	None	20	0/0/115	90
Male	69	V	ACL	NexGen LPS + LCCK	C 3	None	FWB	None	19	0/0/130	90
Female	74	V	Lateral meniscus	NexGen LPS + LCCK	0	None	PWB	Mild	21	0/0/105	85
Female	73	V	Medial meniscus	NexGen LPS + LCCK	NC 3	None	FWB	occasional None	18	0/0/125	94

Abbreviations: C: Contained; NC: Noncontained; FWB: Full-weight bearing; PWB: Partial-weight bearing.

Kirschner wires and/or dot reset forceps were used to the temporary fixation of tibial fracture blocks and help reset. Ligament suture by 2# Ethicon was required if the damage existed (1 knee MCL reconstruction). Bone defect was dealt with after resection of the tibial plateau. The bone defect at the proximal tibia was augmented in 5 knees (3 contained and 2 noncontained (mean 3.2 mm)) and filled with polymethyl methacrylate (PMMA) or autologous bone. We balance flexion and extension gaps after resection and bone graft. Implant selection congruously: Zimmer NexGen LPS for femur and Zimmer NexGen LCCK for tibia. All of the tibial and femoral components used in this series were placed with cement fixation. Cemented long-stem tibial components (NexGen LCCK) were used to improve fixation or to bypass stress risers from fractures and/or bone defect. All had a patellar trimming. Knee stability and motion were checked after prosthesis inserted. Hemostatic steps and the ice-pack treatment were performed to reduce bleeding. Drainage tube was removed routinely at 48 h after surgery with fluid drainage less than 50 ml. Patients commenced active and passive exercises on the first postoperative day. Under the guidance of physical therapist, patients were required to practice early full-weight bearing with walking aids if condition permissible.

## Results

In this study, a total number of six patients (3 women, 3 men) underwent primary TKAs with a mean 19.5 days of length of hospitalization. All fractures were complicated bicondylar tibial plateau fractures belong to type-Vor type-VI of Schatzker Classification.

There was no preoperative compartment syndrome. All patients were admitted immediately after trauma. General conditions and soft-tissue conditions allowed the procedure. The mean time interval between admission and surgery was 4 days (range: 2–6).

The mean duration of surgery was 100 min (range: 90–120). In all cases we used a combination of NexGen LPS femoral component and NexGen LCCK tibial component. Cemented long-stem tibial component was used to bypass stress risers from fractures and/or bone defect.

Bone defect happened after resection of tibial plateau (5/6): (3 contained and 2 noncontained (mean 3.2 mm)). Contained bone defect was filled with autologous bone (2 knees) or PMMA (1 knee). Noncontained bone defect was filled with PMMA (2 knees). Our principles on bone defect include: for deficits <5 mm, PMMA fill; for deficits 5–10 mm, autogenous bone fill; for deficits >10 mm, bone graft, metal wedges or spacer with screws. Bone defect is another reason for using cemented long-stem tibial component. No metal wedges or spacer with screws were used in this series.

All incisions and fractures healed well. Full weight bearing was permitted as soon as tolerated in all patients. Partial-weight bearing was permitted in one painful knee. All patients were

required to reach full extension and a flexion of 95° 2 weeks after surgery. Then, they were discharged from the hospital with the mean stay of 19.5 days (range: 18–21 days). All patients received antithrombotic prevention with low-molecular weight heparin (LMWH) for 2 weeks. No conspicuous complications were noted during hospital stay and later follow-up.

No patients had a revision and were lost to follow-up. HSS knee score and radiological results were recorded to evaluate at the latest available follow-up time. At last follow-up, the mean HSS score was 89.8 (range, 85–94) (Fig. 1 h, i). The mean knee flexion was 119.2° (105–130°). None of these patients had significant postoperative knee pain required revision surgery, or had radiographic loosening of the components at the latest follow-up (Fig. 1 f, g). There was no evidence of bone loss or post-operative deformity during the follow-up.

## Discussion

A paucity of information exists about the outcome of primary TKA for elderly complex tibial plateau fractures. Kini SG et al<sup>19</sup> reported 6 cases of acute tibial plateau fractures treated by navigated primary knee arthroplasty and recommended TKA should be considered a treatment option for acute upper tibial fractures in the elderly with coexistent knee arthritis and poor bone stock. Jan Vermeire et al<sup>20</sup> reviewed 12 patients and suggested TKA is a suitable solution for the treatment of elderly complex tibial plateau fractures and yielded encouraging results.

The routine midline incision was performed the same as traditional TKAs in degenerative knees. All incisions were healed well. Such plateau fractures usually need multiple incisions for ORIF. Multiple incisions can compromise the soft-tissue envelope around the knee, which may in turn predispose to wound complications and infection.<sup>16</sup> An infected tibial plateau fracture would cause a higher rate of complications of subsequent TKA.<sup>15</sup> Wound problems may result in calamitous failure of the TKA or even amputation.<sup>14</sup> We suspect that the low infection rate is the result of the combination of primary surgery with good soft-tissue, careful operative procedures and a limited number of patients.

There is a high rate of posttraumatic arthritis following tibia plateau comminuted fracture of ORIF<sup>1,10</sup> and posttraumatic arthritis often leads to poor outcome. Hendrik Jansen et al found 39.1% patients with posttraumatic arthritis from radiographs after ORIF of complex intra-articular fractures of the tibial plateau in a medium-term results.<sup>1</sup> David Wasserstein et al reported that the two, five, and ten-year rates of TKA in the plateau fracture and control cohorts were 0.32% versus 0.29%, 5.3% versus 0.82%, and 7.3% versus 1.8%, respectively (p < 0.0001). Higher rates of TKA were also associated with increasing age (>48), bicondylar fracture, and greater comorbidity. They concluded elderly patients and those with more severe fractures were also more likely to need TKA after

repair of a tibial plateau fracture.<sup>21</sup> Obviously, it is not unusual to find groups of patients with posttraumatic arthritis in large series of primary TKAs.<sup>22</sup>

Most types of fracture fixation do not allow immediate full-weight bearing, which interferes with early rehabilitation and reintegration. ORIF allows early motion but full-weight bearing usually begins after 8–12 weeks of fracture healing.<sup>23</sup> Early full-weight bearing may lead to collapse and fracture redisplacement in ORIF. Early full-weight bearing not only boost the confidence of patients, but also can decrease the complications related to prolonged bed rest. TKA can bypass the above-mentioned difficulties and provide a stable knee for early full-weight bearing. In this study, all patients reached full extension and a flexion of 95° 2 weeks after surgery. Under the guidance of physical therapist, all patients practiced early full-weight bearing with walking aids as soon as possible after surgery.

Bone defect was divided into contained and noncontained types. The former is considered to be relatively easy to handle. All bone defects were filled with autogenous bone or PMMA in this study. The method of bone graft is a little different from Adolph V's recommendations for bony reconstruction, he deems that morselized allograft is better suited for reconstitution.<sup>24</sup> In this study, bone defect (mean 3.17 mm) was reduced after resection and no metal wedges or spacer with screws was used. Just 1 patient had no bone defect after resection in this series. We suspect that this situation is associated with a limited number of patients. Bone defect also affects our choice of prosthesis.

We agree with Jan Vermeire et al that stemmed femoral components should be avoided because many of these patients have or will have a proximal femur fracture risk.<sup>20</sup> As such, the stress riser between the stemmed femoral component and the hardware in the proximal femur could increase the risk of periprosthetic fractures. Moreover, a revision surgery's bone cutting is mainly in the side of the femur. Relatively, we choose cemented long-stem tibial component to bypass stress risers and to provide stability of the knee. LCCK component provides a method compensate for the missing bone, also improves fixation and help with alignment. LCCK component is also designed to provide stability for patients who lack functional collateral ligaments (1 case) or whose knees cannot be stabilized by the usual soft tissue releases. What's more, a straight or offset stem extension allows the surgeon to optimize canal fill and component positioning. Considering the reasons above, we choose a combination of NexGen LPS femoral component and NexGen LCCK tibial component.

In general, all attempts should be made to preserve the natural knee function. The ideal arthroplasty method remains controversial. This study has several shortcomings, including a limited number of patients and a short-term follow-up. Despite these shortcomings, we conclude that primary TKA is an effective

treatment for elderly patients with a complex fracture of the tibial plateau. Further follow-up is needed to confirm these short-term results.

## References

- Jansen H, Frey SP, Doht S, et al. Medium-term results after complex intra-articular fractures of the tibial plateau. *J Orthop Sci.* 2013;18(4):569–577.
- Zhang Y, Fan DG, Ma BA, et al. Treatment of complicated tibial plateau fractures with dual plating via a 2-incision technique. *Orthopedics.* 2012;35(3):e359–e364.
- Hall JA, Beuerlein MJ, McKee MD. Open reduction and internal fixation compared with circular fixator application for bicondylar tibial plateau fractures. Surgical technique. *J Bone Jt Surg Am.* 2009;91(suppl 2 Pt 1):74–88.
- Saleh KJ, Sherman P, Katkin P, et al. Total knee arthroplasty after open reduction and internal fixation of fractures of the tibial plateau: a minimum five-year follow-up study. *J Bone Jt Surg Am.* 2001;83-A(8):1144–1148.
- Weiss NG, Parvizi J, Trousdale RT, et al. Total knee arthroplasty in patients with a prior fracture of the tibial plateau. *J Bone Jt Surg Am.* 2003;85-A(2):218–221.
- Rademakers MV, Kerkhoffs GM, Siersevelt IN, et al. Operative treatment of 109 tibial plateau fractures: five-to 27-year follow-up results. *J Orthop Trauma.* 2007;21:5–10.
- Choo KJ, Morshed S. Postoperative complications after repair of tibial plateau fractures. *J Knee Surg.* 2014;27(1):11–19.
- Papagelopoulos PJ, Partsinevelos AA, Themistocleous GS, et al. Complications after tibial plateau fracture surgery. *Injury.* 2006;37:475–484.
- Frattini M, Vaienti E, Soncini G, et al. Tibial plateau fractures in elderly patients. *Chir Organi Mov.* 2009;93(3):109–114.
- Manidakis N, Dosani A, Dimitriou R, et al. Tibial plateau fractures: functional outcome and incidence of osteoarthritis in 125 cases. *Int Orthop.* 2010;34(4):565–570.
- Weiss NG, Parvizi J, Hanssen AD, et al. Total knee arthroplasty in post-traumatic arthrosis of the knee. *J Arthroplasty.* 2013;18(3 suppl 1):23–26.
- Pavone V, Boettner F, Fickert S, et al. Total condylar knee arthroplasty: a long-term follow up. *Clin Orthop.* 2001;388:18–25.
- Sextro GS, Berry DJ, Rand JA. Total knee arthroplasty using cruciate-retaining kinematic condylar prosthesis. *Clin Orthop.* 2001;388:33–40.
- Vince KG, Abdeen A. Wound problems in total knee arthroplasty. *Clin Orthop Relat Res.* 2006;452:88–90.
- Larson AN, Hanssen AD, Cass JR. Does prior infection alter the outcome of TKA after tibial plateau fracture? *Clin Orthop Relat Res.* 2009;467(7):1793–1799.
- Shah SN, Karunakar MA. Early wound complications after operative treatment of high energy tibial plateau fractures through two incisions. *Bull NYU Hosp Jt Dis.* 2007;65(2):115–119.
- Macaulay W, Yoon RS, Parsley B, et al. DFACTO Consortium. Displaced femoral neck fractures: is there a standard of care? *Orthopedics.* 2007;30:748–749.
- Schatzker J, McBroom R, Bruce D. The tibial plateau fractures: the Toronto experience 1968–1975. *Clin Orthop Relat Res.* 1979;138:94–104.
- Kini SG, Sathappan SS. Role of navigated total knee arthroplasty for acute tibial fractures in the elderly. *Arch Orthop Trauma Surg.* 2013;133(8):1149–1154.
- Vermeire J, Scheerlinck T. Early primary total knee replacement for complex proximal tibia fractures in elderly and osteoarthritic patients. *Acta Orthop Belg.* 2010;76(6):785–793.
- Wasserstein D, Henry P, Paterson JM, et al. Risk of total knee arthroplasty after operatively treated tibial plateau fracture: a matched-population-based cohort study. *J Bone Jt Surg Am.* 2014;96(2):144–150.
- Civinini R, Carulli C, Matassi F, et al. Total knee arthroplasty after complex tibial plateau fractures. *Chir Organi Mov.* 2009;93(3):143–147.
- Ziran BH, Hooks B, Pesantez R. Complex fractures of the tibial plateau. *J Knee Surg.* 2007;20(1):67–77.
- Lombardi AV, Berend KR, Adams JB. Management of bone loss in revision TKA: it's a changing world. *Orthopedics.* 2010;33(9):66.