


# Usefulness of positron-emission tomography for predicting the World Health Organization grade of thymic epithelial tumors

Takashi Kanou<sup>1</sup>  | Soichiro Funaki<sup>1</sup> | Masato Minami<sup>1</sup> | Naoko Ose<sup>1</sup> | Toru Kimura<sup>1</sup> | Eriko Fukui<sup>1</sup> | Tadashi Watabe<sup>2</sup> | Yasushi Shintani<sup>1</sup>

<sup>1</sup>Department of General Thoracic Surgery, Osaka University Graduate School of Medicine, Osaka, Japan

<sup>2</sup>Department of Nuclear Medicine and Tracer Kinetics, Osaka University Graduate School of Medicine, Osaka, Japan

## Correspondence

Takashi Kanou, Department of General Thoracic Surgery, Osaka University, Osaka, 565-0871, Japan.

Email: [kanoutakashi0999@yahoo.co.jp](mailto:kanoutakashi0999@yahoo.co.jp)

## Abstract

**Background:** It is often difficult to distinguish between thymoma and thymic carcinoma by preoperative radiological tests. While there have been some reports that the maximum standardized uptake value (SUV<sub>max</sub>) in positron emission tomography-computed tomography (PET-CT) is useful to this end, no large-scale analysis has been performed. We therefore analyzed the usefulness of the SUV<sub>max</sub> and tumor size (TS) for differentiating thymic epithelial tumors.

**Methods:** From 2011 to 2019, 129 patients with thymic epithelial tumor who underwent PET-CT before surgical treatment were enrolled. The relevance of the SUV<sub>max</sub> to the World Health Organization (WHO) histological type was assessed. To reduce the impact of the TS, the ratio of the SUV<sub>max</sub> to the TS was also investigated.

**Results:** A total of 99 thymoma cases and 30 thymic carcinoma cases were enrolled into the study. The SUV<sub>max</sub> and SUV<sub>max</sub>/TS of thymic carcinoma were significantly higher than those of thymoma (SUV<sub>max</sub>: 7.7 ± 3.4 vs. 3.3 ± 1.3,  $p < 0.01$ ; SUV<sub>max</sub>/TS: 1.5 ± 0.7 vs. 0.6 ± 0.4,  $p < 0.01$ ). Focusing on the patients with a moderate SUV<sub>max</sub> of ≤5 (84 thymoma and 4 thymic carcinoma), the SUV<sub>max</sub>/TS values of thymic carcinoma were still significantly higher than those of thymoma (1.6 ± 0.8 vs. 0.6 ± 0.4,  $p < 0.01$ ).

**Conclusions:** PET-CT might provide significant information for differentiating images of thymoma and thymic carcinoma. We experienced several cases of thymic carcinoma with a moderate SUV<sub>max</sub> of ≤5, and SUV<sub>max</sub>/TS was considered a useful parameter for differentiating such cases.

## KEYWORDS

pathology, PET-CT, radiological diagnosis, thymic epithelial tumor

## INTRODUCTION

Thymic epithelial tumor is classified based on the World Health Organization (WHO) histological classification, which is known to be related to the prognosis after complete resection.<sup>1</sup> The treatment strategy is mostly dependent on the malignant potential of the thymic tumor. However, the precise imaging diagnosis of thymic epithelial tumor remains difficult.

Although computed tomography (CT) is the most prevalent imaging examination for mediastinal tumors, fluorine-18-fluorodeoxyglucose (<sup>18</sup>F-FDG) positron emission tomography

(PET) has been considered a powerful diagnostic modality for anterior mediastinal masses.<sup>2</sup>

Recently, several reports investigated the relationship between the maximum standardized uptake value (SUV<sub>max</sub>) and the pathological diagnosis. A previous meta-analysis showed that the SUV<sub>max</sub> differed significantly among thymic epithelial tumors (low-grade thymomas, high-grade thymomas, and thymic carcinoma).<sup>3</sup> Some studies have examined the importance of the ratio of the SUV<sub>max</sub> to the tumor size (SUV<sub>max</sub>/TS) for distinguishing thymoma and thymic cancer based on radiological findings.<sup>4,5</sup> However, those reports had small cohort sizes, so further analyses,

such as those involving tumors with a moderate  $SUV_{max}$ , are required.

We therefore retrospectively analyzed the role of the  $SUV_{max}$  and  $SUV_{max}/TS$  in the pathological diagnosis of thymic epithelial tumors.

## METHODS

### Study design

The clinical characteristics and imaging examinations of thymic epithelial tumors in our institution were investigated. The relationship between the pathological diagnosis of tumor and the results of imaging examinations were retrospectively analyzed.

The study protocol was approved by the Ethical Review Board for Clinical Studies at Osaka University (control no. 18297).

### Patients

From April 2011 to December 2019, a total of 129 patients with anterior thymic epithelial tumors were examined by PET-CT and thereafter underwent surgical resection. The histological diagnosis and immunohistochemical examinations were performed by the pathologists in our institution. The tumors were divided into six subtypes (type A, AB, B1, B2, B3, C) based on the WHO classification.<sup>6</sup> These subtypes were further divided into three categories: low-grade thymoma (type A, AB, B1), high-grade thymoma (type B2, B3), and thymic carcinoma. Staging was performed in accordance with UICC TNM Classification of Malignant Tumors eighth edition and the Masaoka-Koga classification.<sup>7</sup>

### <sup>18</sup>F-FDG-PET protocol

All patients underwent <sup>18</sup>F-FDG-PET as a preoperative imaging test with integrated PET-CT as previously described.<sup>8</sup> In brief, the patients fasted for at least 4 h prior to the injection of <sup>18</sup>F-FDG. The dose of <sup>18</sup>F-FDG was calculated by the bodyweight of the patients. PET-CT was performed with a whole body scanner equipped with a 16-slice CT 1 h after the administration of <sup>18</sup>F-FDG (activity: 4 MBq/kg). The  $SUV_{max}$  was calculated using the commercially available software provided by the manufacturer. Tumor size (TS) was decided based on the maximum diameter that was described in the radiological report of thin slice computed tomography (CT) prior to any treatment.

### Statistical analysis

Statistical analyses were performed using the JMP software program for Windows version 14 (SAS Institute Inc.). Continuous

variables are expressed as the median  $\pm$  standard deviation (SD), and categorical variables as numbers. The  $SUV_{max}/TS$  was calculated using the following formula:  $SUV_{max} / \text{longest diameter on axial CT (cm)}$ . To determine the predictive value of parameters, including the  $SUV_{max}$  and  $SUV_{max}/TS$ , the area under the curve (AUC) was scored by a receiver operating characteristic (ROC) analysis. The Mann–Whitney test was used to compare the numerical variables between two groups. A *p*-value of  $\leq 0.05$  was considered statistically significant in all comparisons.

## RESULTS

### Patients

A total of 129 patients were enrolled in the current study. The clinical characteristics of the cohort are shown in Table 1. Our cohort included 58 men and 71 women. The median TS was 5.4 (1.2–15.0) cm. The pathological diagnosis was thymoma in 99 patients and thymic carcinoma in 30 patients. Based on the WHO classification, there were two type A, 16 type AB, 32 type B1, 32 type B2, and 17 type B3 tumors. Among with the patients diagnosed with thymic carcinoma, there were 25 with squamous cell carcinoma and five with undifferentiated carcinoma. The distribution of Masaoka staging was stage 1 in 49, stage 2 in 29, stage 3 in 34, and stage 4 in 17.

**TABLE 1** Patient characteristics

Variables	
Sex male/female, <i>n</i> (%)	58 (44)/71 (56)
Age, mean	56
WHO classification, <i>n</i> (%)	
A/AB	2 (1)/16 (12)
B1/B2/B3	32 (25)/32 (25)/17 (13)
Thymic cancer	30 (24)
Masaoka stage	
1	49 (37)
2	29 (22)
3	34 (26)
4	17 (14)
Myasthenia gravis, <i>n</i> (%)	14 (10)
Tumor size, mean (cm)	5.4 (1.2–15.0)
Type of resection of thymus	
Thymectomy	42 (32)
Extended thymectomy	87 (68)
Type of combined resection	
Lung	45 (35)
Pericardium	39 (30)
Brachiocephalic vein	21 (16)
Phrenic nerve	24 (19)

Abbreviation: WHO, World Health Organization.

## SUV<sub>max</sub> and SUV<sub>max</sub>/TS in thymic epithelial tumors

We investigated the relationship between the SUV<sub>max</sub> of each tumor and the pathological findings, with a focus on the differentiation of thymoma and thymic carcinoma (Figure 1a). The SUV<sub>max</sub> scores in thymoma were significantly lower than those in thymic carcinoma ( $3.3 \pm 1.3$  vs.  $7.7 \pm 3.4$ ,  $p < 0.01$ ). The cutoff value for the SUV<sub>max</sub> was 5.0, and the sensitivity and specificity for differentiating thymoma and thymic carcinoma were 0.90 and 0.75, respectively. The SUV<sub>max</sub>/TS of thymoma was also significantly lower than that of thymic carcinoma ( $0.6 \pm 0.4$  vs.  $1.5 \pm 0.7$ ,  $p < 0.01$ ) (Figure 1b). The cutoff value for the SUV<sub>max</sub>/TS was 1.0, and the sensitivity and specificity for differentiating thymoma and thymic carcinoma were 0.93 and 0.73, respectively. The AUC of each parameter was calculated as 0.93 for the SUV<sub>max</sub> and 0.90 for the SUV<sub>max</sub>/TS (Figure 1c,d).

## FDG-PET/CT parameters and tumor classification

The SUV<sub>max</sub> and SUV<sub>max</sub>/TS in thymic epithelial tumors according to the WHO classification were shown in Figure 2a,b,

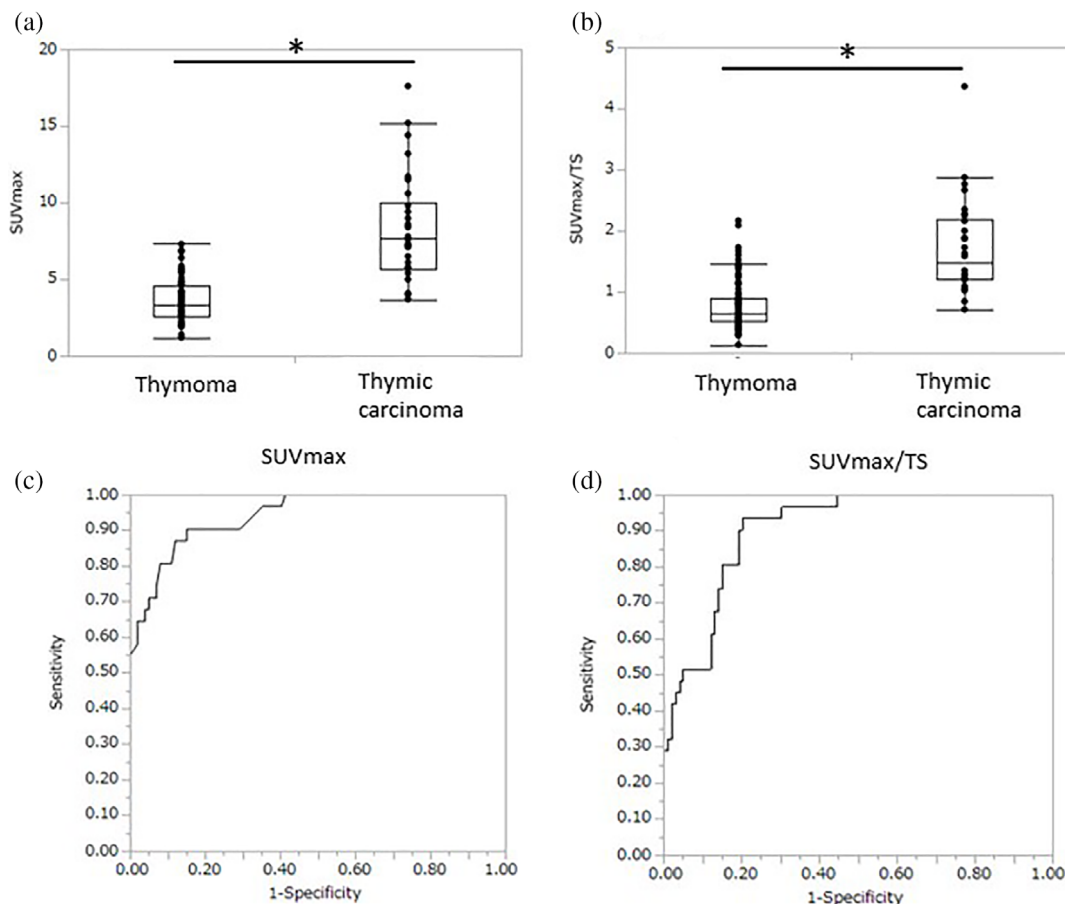
respectively. The scores of SUV<sub>max</sub> in thymic carcinoma were significantly higher than those in low- and high-grade thymoma ( $p < 0.01$ ,  $p < 0.01$ , respectively). Similarly, the SUV<sub>max</sub>/TS values of thymic carcinoma were significantly higher than those of low- and high-grade thymoma ( $p < 0.01$ ,  $p < 0.01$ , respectively).

## Relationship between the tumor stage and FDG-PET/CT parameters

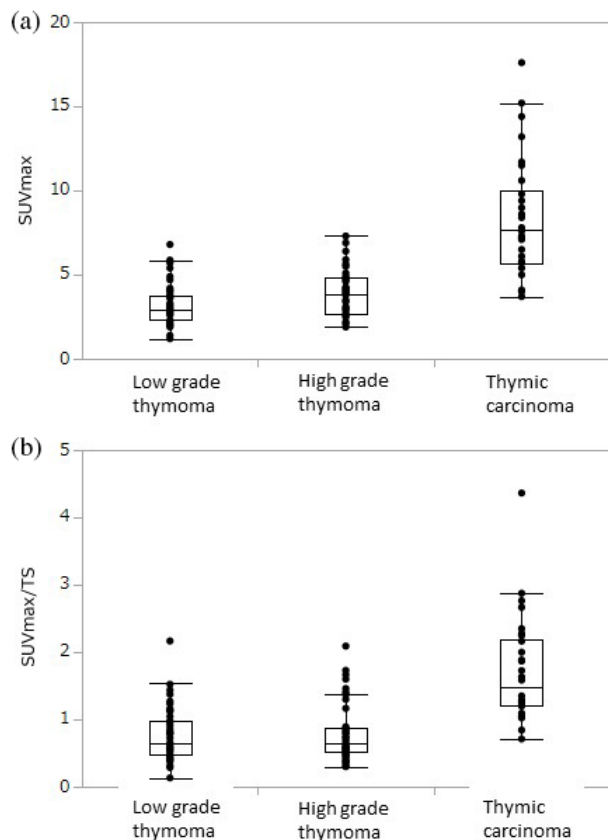
Next, the patients were divided into two categories: Masaoka stage 1 and stage 2–4. The SUV<sub>max</sub> and SUV<sub>max</sub>/TS values were plotted in accordance with the Masaoka stage (Figure 3a, b). The scores of SUV<sub>max</sub> in Masaoka stage 1 were significantly lower than those in Masaoka stage 2–4 ( $2.9 \pm 1.5$  vs.  $4.7 \pm 3.1$ ,  $p < 0.05$ ). In addition, the SUV<sub>max</sub>/TS values in Masaoka stage 1 were significantly lower than those in Masaoka stage 2–4 ( $0.7 \pm 0.5$  vs.  $0.9 \pm 0.7$ ,  $p < 0.05$ ).

## FDG-PET/CT parameters in tumors show a moderate SUV<sub>max</sub>

To investigate the relevance of SUV<sub>max</sub>/TS to the prediction of thymic carcinoma with a moderate SUV<sub>max</sub> of  $\leq 5.0$ ,



**FIGURE 1** Distribution of the SUV<sub>max</sub> and SUV<sub>max</sub>/TS values in the patients with thymoma and thymic carcinoma (a and c); area under the ROC curves (b and d). \* $p < 0.05$



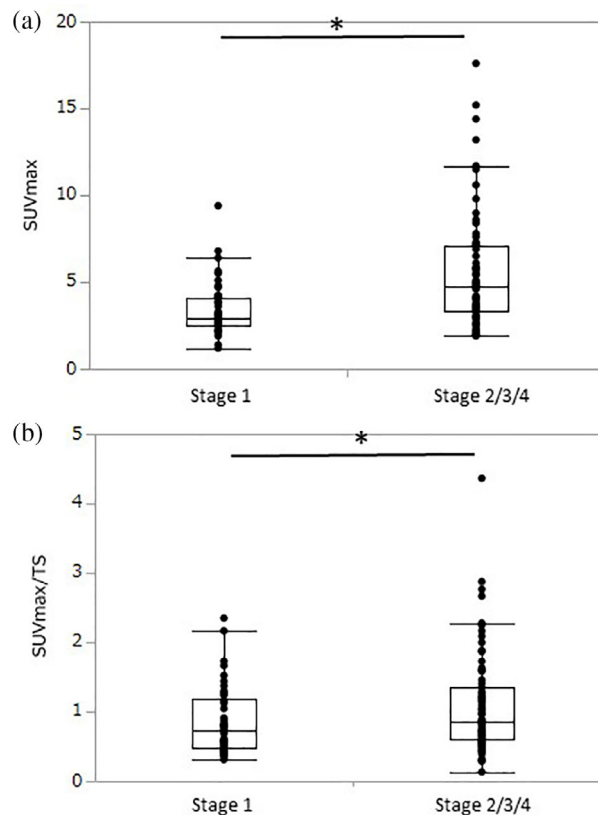
**FIGURE 2** Distribution of the  $SUV_{max}$  and  $SUV_{max}/TS$  in the patients stratified by the histological classification of the World Health Organization (a and b)

88 patients were examined, including 84 cases of thymoma and four cases of thymic carcinoma. In this subgroup, the scores of  $SUV_{max}$  in thymoma and thymic carcinoma were  $3.1 \pm 0.1$  and  $4.0 \pm 0.2$  (Figure 4a). Furthermore, the  $SUV_{max}/TS$  values of thymoma tended to be lower than those of thymic carcinoma ( $0.6 \pm 0.4$  and  $1.6 \pm 0.8$ ) (Figure 4b). An ROC curve analysis was performed in this cohort, and the AUC of the  $SUV_{max}/TS$  was 0.86 (Figure 4c). Using the cutoff value of  $SUV_{max}/TS$  as 1.0, the sensitivity and specificity for differentiating thymoma and thymic cancer were 0.75 and 0.86, respectively.

## DISCUSSION

We found that both the  $SUV_{max}$  and  $SUV_{max}/TS$  were associated with the pathological differentiation of thymic epithelial tumors. Both of those scores in thymic carcinoma were significantly higher than those in thymoma. Furthermore, to our knowledge, this is the first report to investigate the role of the  $SUV_{max}/TS$  in the differentiation of thymic epithelial tumor, especially in tumors with a moderate  $SUV_{max}$  of  $\leq 5.0$ .

A preoperative diagnosis is very important to determine the appropriate treatment strategy against thymic epithelial tumor. In cases of induction therapy, the treatment regimen

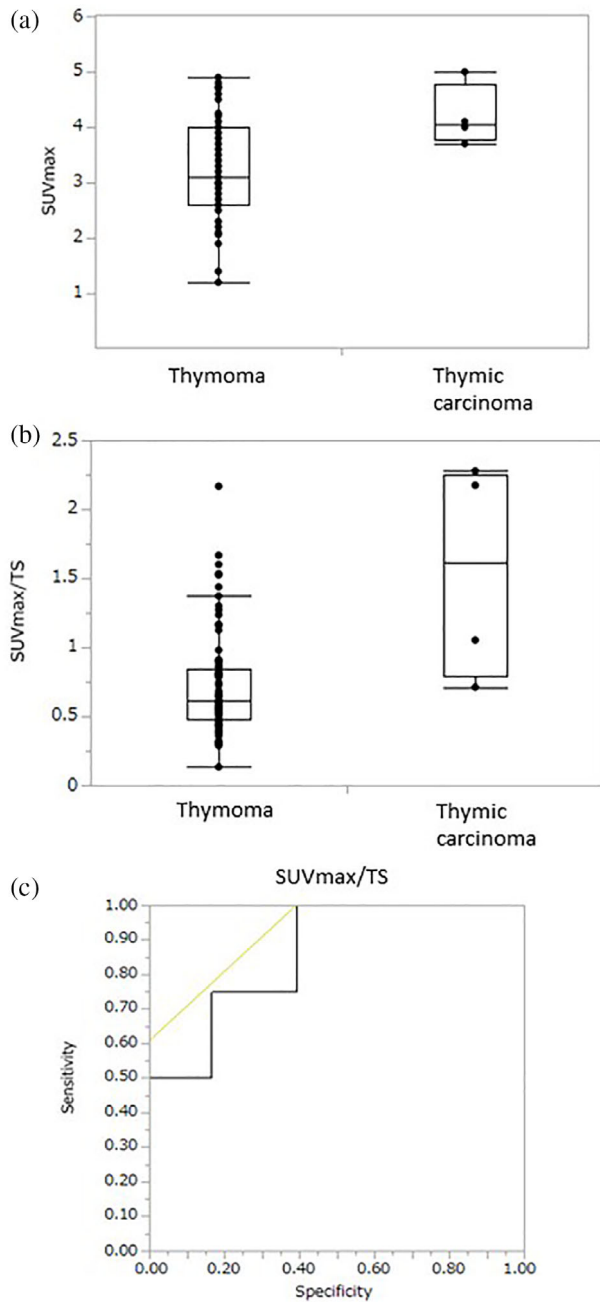


**FIGURE 3** Distribution of the  $SUV_{max}$  and  $SUV_{max}/TS$  in the patients stratified by the Masaoka staging system (a and b)

is dependent on the pathological result. A CT-guided biopsy (CTGB) is a standard maneuver for a preoperative biopsy to make a pathological diagnosis. However, a CTGB may induce complications, such as mediastinal hemorrhage.<sup>9</sup> To decrease the rate of such complications, a preoperative CTGB is sometimes avoided in mediastinal tumors of a small size or which are attached to the great vessels. In such cases, PET-CT might help identify candidates for a CTGB for the precise preoperative diagnosis.

Surgical treatment for thymic epithelial tumor includes the trans-sternal approach and minimally invasive approaches, such as video assisted thoracoscopic surgery (VATS) and robot assisted thoracoscopic surgery (RATS).<sup>10</sup> The choice of approach is important in order to acquire an appropriate surgical view for complete tumor resection.<sup>11</sup> In cases of thymoma, especially those  $\leq 5$  cm in size, our institution selects the VATS/RATS approach.<sup>12</sup> In contrast, median sternotomy is selected for resection of thymic carcinoma to obtain an appropriate surgical view for mediastinal lymph node dissection. Preoperative PET-CT provides valuable information for the differentiation of those two scenarios.

Regarding the surgical position, the supine position is selected in most cases of thymic epithelial tumor resection in our institution. However, the lateral position is sometimes preferred in cases with the tumor located in the right- or left-sided mediastinum. Based on the findings from the current study, for tumors with  $SUV_{max}$  of  $>5$  or  $SUV_{max}/TS$  of



**FIGURE 4** Distribution of the SUV<sub>max</sub> and SUV<sub>max</sub>/TS values in the patients showing a moderate SUV<sub>max</sub> ≤ 5 (a); area under the ROC curves (b)

>1.0, the supine position seems more appropriate than the lateral position due to the possibility of thymic carcinoma. From this perspective, PET-CT provides ample information to support the accurate selection of not only the surgical approach but also the surgical position.

Several studies have shown that PET-CT is useful for differentiating thymoma and thymic carcinoma based on their SUV<sub>max</sub> scores. Park et al. reported that the cutoff value of SUV<sub>max</sub> for this purpose with the maximum sensitivity was 5,<sup>13</sup> with the same score found by the ROC curve analysis. However, we sometimes encounter cases of thymic carcinoma with a moderate SUV<sub>max</sub> of ≤ 5, and the SUV<sub>max</sub>/TS

index is investigated in those patients. Lococo et al. revealed that the mean SUV<sub>max</sub>/TS value in thymoma was 0.92, and that in thymic carcinoma was 1.93. In our entire cohort, the cutoff value of the SUV<sub>max</sub>/TS for the differentiation of thymoma and thymic carcinoma was 1.0. Furthermore, in tumors showing an SUV<sub>max</sub> of ≤ 5, the cutoff value of the SUV<sub>max</sub>/TS as 1.0 also showed high sensitivity and specificity. Our findings suggest that the SUV<sub>max</sub>/TS value indicates the metabolic activity of the tumor and might reflect the malignant potential of the tumor. For this reason, we aggressively conduct PET-CT as a preoperative examination, even in cases with small tumors.

Thymic carcinoma is a rare disease, and previous studies regarding SUV<sub>max</sub>/TS have involved small sample sizes, especially for thymic carcinoma.<sup>4,5</sup> Two previous studies both involved just seven cases of thymic carcinoma each. As far as we examined, our study included the largest case number of thymic carcinoma (31 cases) as a single institution study compared with previous reports. We hope that the current results will enhance the clinical significance of the SUV<sub>max</sub>/TS in the radiological diagnosis.

We were also curious about the influence of the SUV<sub>max</sub>/TS on the prognosis of thymic epithelial tumor. Several reports have described the impact of the SUV<sub>max</sub> on the prognosis of thymoma and thymic carcinoma. Seki et al. reported that a higher SUV<sub>max</sub> reflected a lower recurrence-free survival.<sup>14</sup> Furthermore, Hamaji et al. revealed that the metabolic tumor volume and total lesion glycolysis were related to the risk of postoperative recurrence of thymic carcinoma.<sup>15</sup> In our study, the observational period was short, so it was difficult to conclude the relationship between the SUV<sub>max</sub>/TS index and the prognosis after radical resection. A further analysis will be required to investigate the influence of the SUV<sub>max</sub>/TS on the postoperative prognosis.

Several limitations associated with the present study warrant mention. First, our cohort was small, and this study was a single-institution and retrospective observational one. To validate the concept and strengthen our findings, a different cohort collected separately and prospectively will be required. Second, our cohort was limited to patients who underwent surgical treatment. Whether or not our concept can be applied to more advanced diseases with multiple pleural dissemination remains unclear.

In conclusion, the current study demonstrated the role of the SUV<sub>max</sub> and SUV<sub>max</sub>/TS as predictive features of the pathological diagnosis of thymic epithelial tumors. We expect these findings to aid surgeons in selecting the most appropriate surgical approach and treatment strategy.

#### ACKNOWLEDGMENTS

We thank Dr Brian Quinn for the English language editing.

#### CONFLICT OF INTEREST

The authors have no conflicts of interest to declare.

#### ORCID

Takashi Kanou  <https://orcid.org/0000-0003-2955-1490>

## REFERENCES

1. Rena O, Papalia E, Maggi G, Oliaro A, Ruffini E, Filosso PL, et al. World Health Organization histologic classification: an independent prognostic factor in resected thymomas. *Lung Cancer*. 2005;50(1):59–66.
2. Watanabe T, Shimomura H, Mutoh T, Saito R, Goto R, Yamada T, et al. Positron emission tomography/computed tomography as a clinical diagnostic tool for anterior mediastinal tumors. *Surg Today*. 2019;49(2):143–9.
3. Treglia G, Sadeghi R, Giovanella L, Cafarotti S, Filosso P, Lococo F. Is 18F-FDG PET useful in predicting the WHO grade of malignancy in thymic epithelial tumors? A meta-analysis. *Lung Cancer*. 2014;86(1):5–13.
4. Lococo F, Cesario A, Okami J, Cardillo G, Cavuto S, Tokunaga T, et al. Role of combined 18F-FDG-PET/CT for predicting the WHO malignancy grade of thymic epithelial tumors: a multicenter analysis. *Lung Cancer*. 2013;82(2):245–51.
5. Tomita M, Ayabe T, Tsuchiya K, Nakamura K. Fluorodeoxyglucose positron emission tomography can provide useful information for differentiating thymic epithelial tumors. *Thorac Cardiovasc Surg*. 2018;66(4):345–9.
6. Rosai J, Sobin LH. Histological classification of Tumours of the thymus. *Histological Typing of Tumours of the Thymus*. World Health Organization. International Histological Classification of Tumours. Heidelberg: Springer; 1999.
7. Nicholson AG, Detterbeck FC, Marino M, Kim J, Stratton K, Giroux D, et al. The IASLC/ITMIG thymic epithelial tumors staging project: proposals for the T component for the forthcoming (8th) edition of the TNM classification of malignant tumors. *J Thorac Oncol*. 2014;9(9):S73–80.
8. Ose N, Sawabata N, Minami M, Inoue M, Shintani Y, Kadota Y, et al. Lymph node metastasis diagnosis using positron emission tomography with 2-[18F] fluoro-2-deoxy-d-glucose as a tracer and computed tomography in surgical cases of non-small cell lung cancer. *Eur J Cardiothorac Surg*. 2012;42(1):89–92.
9. Madoff DC, Morello FA, Ahrar K, Murthy R, Hicks ME. Taneous biopsy of mediastinal lesions: different approaches and anatomic considerations. *Radiographics*. 2005;1:763–86.
10. Yoshida S, Yoshino I, Moriya Y, Hoshino H, Okamoto T, Suzuki M, et al. Video-assisted thoracoscopic surgery extended thymectomy for myasthenia gravis using manual manipulators: the radius surgical system. *Ann Thorac Surg*. 2011;92(6):2246–8.
11. Shintani Y, Funaki S, Ose N, Kanou T, Fukui E, Minami M. Surgical approach for thymic epithelial tumor. *J Thorac Dis*. 2019;11(8):E127–30.
12. Kimura T, Inoue M, Kadota Y, Shiono H, Shintani Y, Nakagiri T, et al. The oncological feasibility and limitations of video-assisted thoracoscopic thymectomy for early-stage thymomas. *Eur J Cardiothorac Surg*. 2013;44(3):214–8.
13. Park SY, Cho A, Bae MK, Lee CY, Kim DJ, Chung KY. Value of 18F-FDG PET/CT for predicting the world health organization malignant grade of thymic epithelial tumors: focused in volume-dependent parameters. *Clin Nucl Med*. 2016;41(1):15–20.
14. Seki N, Sakamoto S, Karube Y, Oyaizu T, Ishihama H, Chida M. 18F-fluorodeoxyglucose positron emission tomography for evaluation of thymic epithelial tumors: utility for World Health Organization classification and predicting recurrence-free survival. *Ann Nucl Med*. 2014;28(3):257–62.
15. Hamaji M, Koyasu S, Omasa M, Nakakura A, Morita S, Nakagawa T, et al. Are volume-dependent parameters in positron emission tomography predictive of postoperative recurrence after resection in patients with thymic carcinoma? *Surg Today*. 2021;51(2):322–6.

**How to cite this article:** Kanou T, Funaki S, Minami M, Ose N, Kimura T, Fukui E, et al. Usefulness of positron-emission tomography for predicting the World Health Organization grade of thymic epithelial tumors. *Thorac Cancer*. 2022; 13(11):1651–6. <https://doi.org/10.1111/1759-7714.14434>