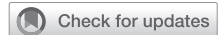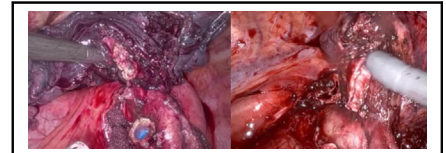


How I do it: Bronchial sleeve resection and pulmonary angioplasty techniques after induction chemo-immunotherapy



Alper Toker, MD, and Jahnvi Kakuturu, MD

Video clip is available online.



The technique to be performed on the PA could be decided after division of bronchus.

CENTRAL MESSAGE

Use of induction chemo-immunotherapy for locally advanced lung cancer is expected to increase surgical complexity. Bronchial sleeve and PA patch plasty techniques are discussed.

The incorporation of immunotherapy in neoadjuvant treatment of lung cancer has raised concerns about the technical feasibility and safety of surgery, especially in complex cases involving pulmonary artery (PA) reconstructions and bronchial sleeve resections. The inflammatory response secondary to immunotherapy often leads to hilar fibrosis, making surgical dissection around the PA more challenging, particularly in patients who have undergone neoadjuvant chemo-immunotherapy for locally advanced disease. Although certain parameters such as operative time and blood loss may not differ significantly from patients without neoadjuvant therapy, reported rates of conversion to open surgery can be as high as 54%, emphasizing the need for careful patient selection.¹ Although some studies report much lower conversion rates of 3.2%, only a small proportion of patients within the series underwent a minimally invasive approach, further highlighting the importance of patient selection.² Adding to the complexity of surgery performed after neoadjuvant chemo-immunotherapy is the sparsity of guidelines for the assessment of response or progression after therapy. Also, the issue of pseudo-progression demonstrated by several authors has not been studied in detail.^{1,3}

The rationale for use of chemo-immunotherapy in the neoadjuvant setting lies in fostering diverse T-cell production, particularly if the tumor is not surgically removed before immunotherapy.⁴ Adjuvant immunotherapy post-

tumor removal might be less effective due to reduced diversity in T-cell production.⁴ Thus, the use of immunotherapy in the neoadjuvant setting is expected to become more prevalent in earlier stages of lung cancer. Translating this to a surgical perspective, resection performed for locally advanced disease in a virgin mediastinum and hilum will decrease in patients, whereas surgeries after neoadjuvant chemo-immunotherapy with a potential for pulmonary and hilar fibrosis are expected to increase in patients.

In our current clinical practice and experience, we have noted that patients undergoing neoadjuvant chemo-immunotherapy may face different surgical challenges, classified into 3 groups:

1. Early-stage disease, lower lobes: Generally, there is minimal inflammation around the main PA, making lobectomy or segmentectomy feasible with minimally invasive techniques.
2. Patients with locally advanced stage 3 upper lobe disease: These cases may require more complex resections, potentially involving bronchial sleeve lobectomy and PA angioplasty. Surgical techniques may vary on the basis of the extent of the resection and degree of fibrosis. Minimally invasive surgery may be considered in experienced centers if only bronchial sleeve resection is needed.

From the Department of Cardiovascular and Thoracic Surgery, West Virginia University School of Medicine, Morgantown, WV.

All patients were informed about the study and signed the informed consent.

Received for publication Dec 20, 2023; revisions received Jan 26, 2024; accepted for publication Feb 7, 2024; available ahead of print Feb 17, 2024.

Address for reprints: Alper Toker, MD, 1 Medical Center Dr Box 8500, 19 Catalpa St, Morgantown, WV 26505 (E-mail: Alper.toker@wvumedicine.org).

JTCVS Techniques 2024;24:202-6

2666-2507

Published by Elsevier Inc. on behalf of The American Association for Thoracic Surgery. This is an open access article under the CC BY-NC-ND license (<http://creativecommons.org/licenses/by-nc-nd/4.0/>).

<https://doi.org/10.1016/j.jtc.2024.02.009>

3. Immunotherapy as part of definitive chemoradiation with salvage surgery: These cases demand open surgery and proximal and distal control of the PA, and may require intrapericardial access, necessitating expertise in salvage surgeries.

In the realm of PA reconstructions, various techniques exist, each with distinct characteristics. In order of decreasing complexity, these include sleeve resection of the PA with reconstruction, patch plasty of the PA, tangential arterioplasty, and simple stapling of the PA. The choice among these methods introduces not only technical challenges but also variations in outcomes and complications. Frequently, there is a concomitant need for bronchial reconstruction, which might involve sleeve bronchial resection and reconstruction, primary closure, or stapling of the bronchus. The primary focus of this report is 2-fold: (1) to emphasize the evaluation of PA invasion by tumors and the subsequent decision-making process for selecting the appropriate surgical technique for the PA; and (2) to describe PA reconstruction techniques, particularly patch plasty with bronchial sleeve surgery. The patients who have intraoperative videos included in this article provided informed consent for recording and documenting the intraoperative findings; Institutional Review Board approval was not required.

PRESURGICAL EVALUATION

Restaging

The predominant focus has been on the necessity for invasive restaging procedures, driven by the fact that a majority of studies have chosen major pathologic response (MPR) as a surrogate end point for evaluating clinical efficacy. Despite the acknowledged validity of MPR as a surrogate end point, there remains uncertainty regarding its association with disease-free survival or overall survival. This ambiguity underscores the need for additional research to delve into the relationship between MPR and these critical clinical outcomes.^{5,6} Further exploration and investigation are essential to clarify the utility and predictive value of MPR in the context of patient survival and disease progression.

Assessment of Pulmonary Artery Invasion

After neoadjuvant chemo-immunotherapy, radiologic and pathologic responses may differ, emphasizing the importance of assessing computed tomography (CT) imaging for arterial invasion. All patients should undergo a CT chest with intravenous contrast after induction therapy to assess the primary tumor response, degree of PA involvement, and feasibility of surgery. Although we do not routinely obtain positron emission tomography CT for restaging, progression of the primary tumor after induction therapy prompts a thorough evaluation for distant

metastases, and positron emission tomography CT may be useful in this circumstance. To augment the precision of the assessment, fiber optic bronchoscopy becomes an indispensable adjunct. This procedure allows for a detailed examination of the bronchus and the extent of endobronchial tumor infiltration, if present. It also provides additional information that contributes to a more comprehensive understanding of the disease extent. Integrating these imaging modalities and techniques in the preoperative assessment process ensures a thorough evaluation of both arterial and bronchial involvement, aiding in the formulation of an informed and tailored surgical approach.

Assessment of Cardiopulmonary Reserve

Assessing cardiopulmonary reserve is crucial, and standard measurements apply, the caveat being cases of complete bronchial or arterial obstruction that could be corrected with the reconstructive surgery. In such circumstances, lower than usual reference levels may be acceptable. With regard to pulmonary function tests, our thresholds for lobectomy are predicted by forced expiratory volume in 1 second and diffusing capacity of the lungs for carbon monoxide values greater than 40%. However, we do consider certain patients with predicted forced expiratory volume in 1 second and diffusing capacity of the lungs for carbon monoxide ranging from 30 to 40% if upper lobectomy is planned and the patients are able to complete a 6-minute walk test or stair climb test without limitation. All patients should undergo transthoracic echocardiography to assess cardiac function and PA pressures. Patients with pulmonary hypertension, specifically those with mean PA pressure greater than 45 mm Hg, are deemed high risk for surgical intervention.

Selection of the Pulmonary Artery Resection and Reconstruction Technique

Various approaches to managing the PA range from simply stapling the PA to sleeve resection with end-to-end anastomosis. In between these 2 ends of the spectrum are PA tangential angioplasty and PA patch plasty. Although it is preferable to know which approach will be required beforehand, the degree of PA involvement may not be apparent until the time of surgery, after division of the bronchus, either standard division or by a sleeve resection (Figure 1 and Videos 1 and 2).

Surgical Technique

The basics of our surgical plan involve the following. The surgical technique prioritizes radical lymph node dissection in the mediastinum and hilum and staging with frozen sections before proceeding with lobectomy, with a preference for keeping PA resection as the final hilar structure to be divided. PA sleeve resection is reserved for more extensive involvement, with a preference for patch plasty.

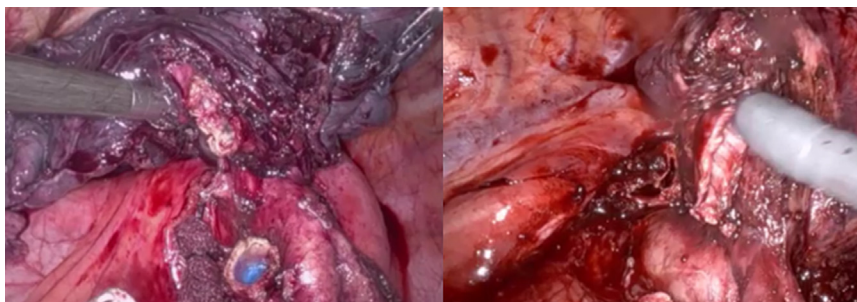
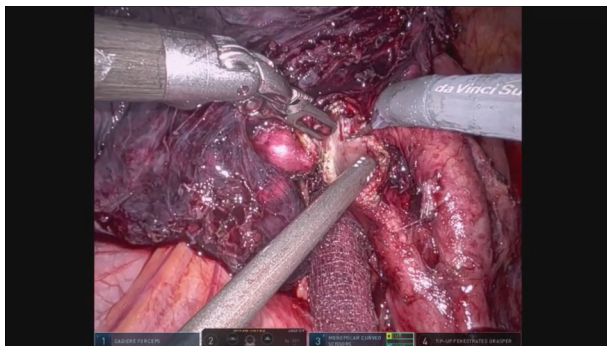


FIGURE 1. *Left:* assessment of the PA after division of bronchus. *Right:* Picture sleeve resection was performed to assess the right main PA. Both patients after neoadjuvant chemo-immunotherapy.

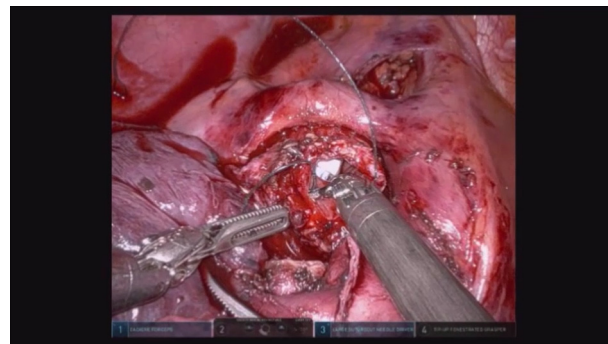
In detail, we prefer the division of the main hilar structures from the easiest to the most difficult one. Whenever there is hilar involvement by a tumor or extensive fibrosis, opening the pericardium and dividing the vein intrapericardially or performing a sleeve resection to the bronchus may be required before exploring the most involved structure: the PA (Video 1). After division of the vein or bronchus (we call this point “burning the bridges”), there can be no bailout from surgery. At this stage, the type of PA resection and reconstruction is decided. We believe any circumstance that a surgeon can place vascular clamps proximally and distally on the PA could be managed with PA tangential angioplasty or a patch plasty. In the situations of vascular sleeve and in some of the patch plasty techniques, we prefer to place one of the vascular clamps to the inferior pulmonary vein to prevent back bleeding. Videos 1 and 2 demonstrate intraoperative assessment of PA involvement during both right and left upper lobectomies in patients who received neoadjuvant chemo-immunotherapy. In the left side, the PA was amenable to stapling, whereas in the right side, the PA required a sleeve resection due to margin positivity after an arterial patch plasty (Videos 1 and 2).

Surgical Technique: Right Upper Lobe Bronchial Sleeve Resection and Pulmonary Arterial Patch Plasty After Neoadjuvant Chemo-Immunotherapy

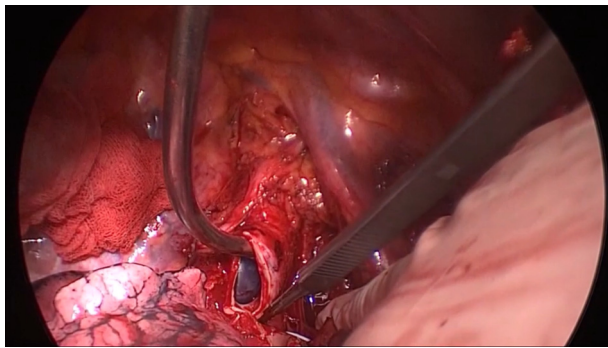
Before surgery, pulmonary function tests and echocardiography are conducted to assess the patient’s physiological suitability for the procedure. Pretreatment and post-treatment contrast-enhanced CT scans are compared to determine the necessity for reconstructive PA surgery. The patient is intubated with a left-sided double-lumen tube regardless of the surgical side preference. An anterior thoracotomy is the preferred approach, initiated from the fourth intercostal space and extending to the mid-half of the scapula posteriorly, along the lateral side of the pectoralis major, by dividing the serratus anterior muscle and preserving the latissimus dorsi muscle. We begin with a meticulous lymph node dissection performed in the mediastinum including stations 2R, 4R, 10R, 7, and 11R. The hilar structures are then divided in the following order: azygos vein, if required (which was infiltrated with the tumor in the case of Video 3), and superior pulmonary vein, with use of a vascular staple load. The bronchus is then divided with a scalpel behind the interlobar PA, specifically at the level of the origin of the



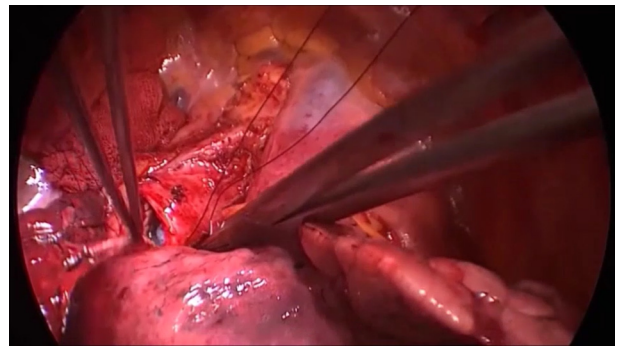
VIDEO 1. Robotic surgery and stapling of the artery after left upper lobe bronchus division. Video available at: [https://www.jtcvs.org/article/S2666-2507\(24\)00065-8/fulltext](https://www.jtcvs.org/article/S2666-2507(24)00065-8/fulltext).



VIDEO 2. Robotic right upper lobe sleeve resection was performed to adequately assess the degree of PA involvement. Once the bronchus was divided, the right upper lobe arterial branches were safely encircled and stapled. Bronchial anastomosis was then completed. Video available at: [https://www.jtcvs.org/article/S2666-2507\(24\)00065-8/fulltext](https://www.jtcvs.org/article/S2666-2507(24)00065-8/fulltext).



VIDEO 3. Division of all hilar structures after mediastinal lymph node dissection. Video available at: [https://www.jtcvs.org/article/S2666-2507\(24\)00065-8/fulltext](https://www.jtcvs.org/article/S2666-2507(24)00065-8/fulltext).



VIDEO 5. Pericardial release and separation of the arterial patch plasty with mediastinal fatty tissue and bronchial anastomosis. Video available at: [https://www.jtcvs.org/article/S2666-2507\(24\)00065-8/fulltext](https://www.jtcvs.org/article/S2666-2507(24)00065-8/fulltext).

intermediate bronchus. Attention must be paid to identify the orifices of the middle lobe bronchus and the superior segmental bronchus of the lower lobe (Video 3).

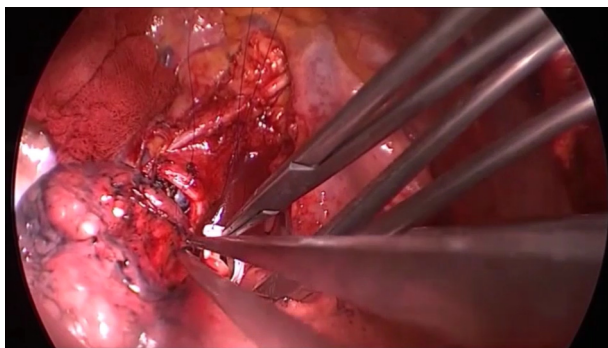
Proximal division of the right main bronchus is then performed at a level, generally leaving 2 to 3 cartilages toward the carina. The PA is then clamped proximally under the superior vena cava, and the inferior pulmonary vein is clamped extra- or intra-pericardially 3 minutes after administration of heparin (2500-5000 IU). The PA is then resected with scissors, maintaining at least 2- to 3-mm margins from the area of tumor infiltration. The specimen is sent for frozen-section analysis for arterial and bronchial margins. It is important to assess the arterial vascular margins before placing the specimen in formalin, due to potential shrinkage of the PA, once fixed (Video 3).

The patch size is then tailored to the resected pulmonary arterial dimensions rather than the defect itself. Various patches, including bovine pericardium, autologous pericardium (treated with glutaraldehyde for 5 minutes), polytetrafluoroethylene graft, and superior pulmonary vein or saphenous vein grafts, may be used. In this patient, we used a 1-mm polytetrafluoroethylene graft. The tailored

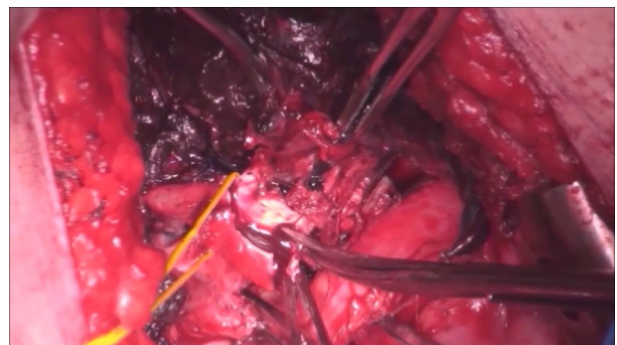
patch is sutured proximally and distally with 5/0 Prolene sutures onto the defect. By placing continuous sutures on both sides of the patch, the patch is circumferentially sutured over the PA. Unlike previous recommendations, we opt to perform PA reconstruction before bronchial reconstruction, considering it a more time-efficient approach to decrease the duration of PA clamping (Video 4).

After completing the arterial patch plasty, the inferior pulmonary vein is mobilized to decrease the tension on the bronchial anastomoses. The thymus is mobilized to cover the patch entirely over the main PA to decrease the potential risk of bronchovascular fistula development in the future. Subsequently, the bronchial anastomosis is performed with 4-0 polydioxanone sutures. An air leak test of the bronchial anastomosis is then performed by inflating the lobe without additional support around the bronchial suture line (Video 5).

In cases with more extensive involvement of the main PA, we prefer intrapericardial control of the proximal PA between the superior vena cava and the aorta (Video 6).



VIDEO 4. Reconstruction of PA with patch plasty. Video available at: [https://www.jtcvs.org/article/S2666-2507\(24\)00065-8/fulltext](https://www.jtcvs.org/article/S2666-2507(24)00065-8/fulltext).



VIDEO 6. Performance of bronchial sleeve and pulmonary arterial patch plasty by placing PA clamp between superior vena cava and aorta. Video available at: [https://www.jtcvs.org/article/S2666-2507\(24\)00065-8/fulltext](https://www.jtcvs.org/article/S2666-2507(24)00065-8/fulltext).

CONCLUSIONS

With more frequent use of induction chemo-immunotherapy for locally advanced lung cancer, surgical complexity is expected to increase. Preoperative and intraoperative assessments of the extent of PA involvement are crucial for surgical planning. Various bronchial sleeve and PA patch plasty techniques may be required during lobectomy and should be part of the thoracic surgeon's armamentarium when facing cases after chemo-immunotherapy.

Conflict of Interest Statement

The authors reported no conflicts of interest.

The *Journal* policy requires editors and reviewers to disclose conflicts of interest and to decline handling or reviewing manuscripts for which they may have a conflict of interest. The editors and reviewers of this article have no conflicts of interest.

References

1. Bott M, Yang S, Park B, et al. Initial results of pulmonary resection following neoadjuvant nivolumab in patients with resectable non-small cell lung cancer. *J Thorac Cardiovasc Surg*. 2019;158:269-276. <https://doi.org/10.1016/j.jtcvs.2018.11.124>
2. Jiang L, Huang J, Jiang S, et al. The surgical perspective in neoadjuvant immunotherapy for resectable non-small cell lung cancer. *Cancer Immunol Immunother*. 2021;70:2313-2321. <https://doi.org/10.1007/s00262-021-02847-1>
3. Gao SJ, Corso CD, Wang EH, et al. Timing of surgery after neoadjuvant chemoradiation in locally advanced non-small cell lung cancer. *J Thorac Oncol*. 2017;12:314-322. <https://doi.org/10.1016/j.jtho.2016.09.122>
4. Mittenford H, Burgers F, Haanen J, Cascone T. *Neoadjuvant Immunotherapy: Leveraging Immune System to Treat Early Stage Disease*. ASCO Educational Book; 2022:189-203.
5. Huynh C, Walsh L, Spicer J. Surgery after neoadjuvant immunotherapy in patients with resectable non-small cell lung cancer. *Transl Lung Cancer Res*. 2021;10:563-580. <https://doi.org/10.21037/tlcr-20-509>
6. Bai R, Li L, Chen X, Chen N, Song W, Cui J. Neoadjuvant and adjuvant immunotherapy: opening new horizons for patients with early-stage non-small cell lung cancer. *Front Oncol*. 2020;10:575472. <https://doi.org/10.3389/fonc.2020.575472>

Key Words: pulmonary artery reconstruction, bronchial sleeve