

Marked improvement of Churg–Strauss syndrome neuropathy by intravenous immunoglobulin and cyclophosphamide

Akira Umeda¹, Tateki Yamane¹, Jin Takeuchi¹, Yasuo Imai², Keisuke Suzuki³ & Wako Yumura⁴

¹Department of Internal Medicine, Shioya Hospital, International University of Health and Welfare, Tochigi, Japan

²Department of Pathology, Dokkyo Medical University Koshigaya Hospital, Saitama, Japan

³Department of Neurology, Dokkyo Medical University, Tochigi, Japan

⁴Department of Nephrology, International University of Health and Welfare Hospital, Tochigi, Japan

Keywords

ANCA, Churg–Strauss syndrome, eosinophils, immunoglobulin, vasculitis.

Correspondence

Akira Umeda, Department of Internal Medicine, International University of Health and Welfare, Shioya Hospital, 77 Tomita, Yaita City, 329–2145 Tochigi, Japan.
E-mail: aumeda@hf.catv.ne.jp

Received: 04 March 2014; Revised: 13 March 2014; Accepted: 13 March 2014

Respirology Case Reports 2014; **2**(2): 81–84

doi: 10.1002/rcr2.56

Abstract

A 42-year-old Japanese man developed Churg–Strauss syndrome 7 years after being diagnosed with chronic eosinophilic pneumonia. Prominent eosinophilia, subcutaneous nodules, and neuropathy in the left leg were seen. A pathological diagnosis of necrotizing vasculitis was determined by a biopsy of a subcutaneous nodule. The leg pain was severe and there was prominent atrophy of the thigh and calf, but the muscle weakness was mild. Serum anti-myeloperoxidase anti-neutrophil cytoplasmic antibody was positive. Because the initial treatment with an intravenous methylprednisolone pulse at 1 g/day for 3 days was not sufficient, a onetime treatment with intravenous cyclophosphamide at 15 mg/kg and intravenous immunoglobulin therapy (IVIG) at 400 mg/kg/day for 5 days were administered. Peripheral eosinophilia improved and the leg pain significantly improved. IVIG was repeated 1 month later and symptoms gradually improved further. The early diagnosis of Churg–Strauss syndrome and the early initiation of IVIG with cyclophosphamide were thought to be important.

Introduction

Although chronic eosinophilic pneumonia (CEP) mainly targets the lungs, Churg–Strauss syndrome (CSS) is a systemic disease with vasculitis [1]. Guidelines recommend the use of cyclophosphamide and steroids for generalized anti-neutrophil cytoplasmic antibody (ANCA)-associated vasculitis in patients with threatened organ involvement [2]. Nearly all CSS patients have been reported to show long-lasting and steroid-resistant neuralgia together with muscle weakness due to peripheral neuropathy [3]. Intravenous immunoglobulin therapy (IVIG) has been reported to be very effective as a second-line treatment for CSS patients, particularly in the case of neuropathy and/or cardiomyopathy [3–5]. Here we report on a CSS case with severe neuropathy where steroid therapy was not sufficient and IVIG therapy was initiated soon after treatment with cyclophosphamide.

The diagnosis of CSS was made according to the criteria of the American College of Rheumatology [3].

Case Report

A 42-year-old Japanese man developed CSS following a history of allergic rhinitis (22 years before), bronchial asthma (17 years before), and eosinophilic pneumonia (7 years before; Fig. 1A–C). During diagnosis of the eosinophilic pneumonia, a transbronchial lung biopsy was performed and prominent eosinophilic inflammation without vasculitis or granuloma was observed. The diffuse lung inflammatory shadows disappeared with systemic steroid therapy. The patient was followed and sometimes treated with oral prednisolone at 5–10 mg/day according to the appearance of his chest X-ray and eosinophilia. His CSS developed in September 2013 with prominent peripheral

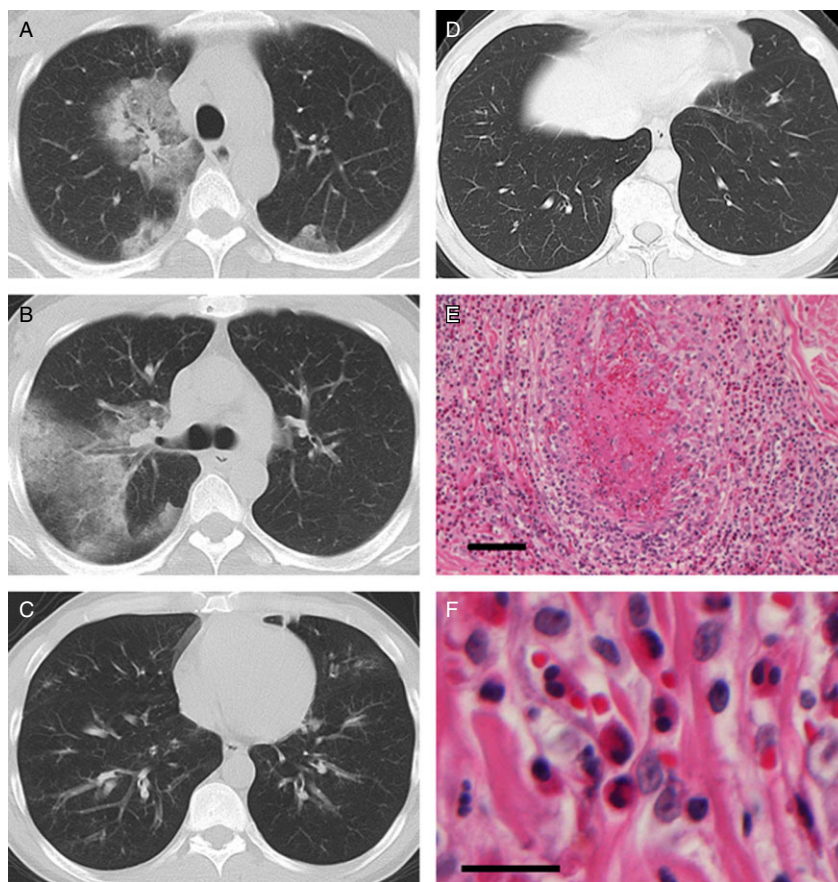


Figure 1. Chest computed tomography (CT) and microscopic images of subcutaneous nodule biopsy before the treatments with intravenous cyclophosphamide and immunoglobulin therapy. (A–C) Chest CT when this patient was diagnosed with eosinophilic pneumonia 7 years before. Bilateral infiltrative shadows had been seen, and these shadows disappeared once with steroid therapy. (D) Chest CT after the neuropathy due to Churg–Strauss syndrome developed. Small inflammatory shadows are seen in the left lower lung field. (E,F) Necrotizing vasculitis with marked eosinophilic infiltration is seen. Granuloma was not seen. Bars = 100 µm (E), 20 µm (F).

eosinophilia (40%), subcutaneous nodules on his face and right arm, and progressive atrophy along with dysesthesia and cold sensations in the left leg (Fig. 2). Neurological findings were unremarkable except for mild weakness of the left quadriceps, tibialis anterior, and gastrocnemius muscles (manual muscle test score: MMTS 4) with prominent atrophy of the left thigh and calf and dysesthesia in the sole and lateral aspect of the dorsum of the left foot. The leg pain was maximally severe (visual analog scale: VAS 100). Nerve conduction study revealed the absence of response in the left peroneal, tibial, and sural nerves. Chest computed tomography showed small inflammatory shadows in the left lower lung field (Fig. 1D). Biopsy of a face subcutaneous nodule yielded necrotizing vasculitis with marked eosinophilic infiltration without granulomas (Fig. 1E,F). Anti-myeloperoxidase ANCA was positive (12.2 U/mL).

The initial treatment with an increase in the steroid dose and the methylprednisolone pulse of 1 g/day for 3 days was

not successful (peripheral eosinophils once decreased from $1.11 \times 10^{10}/L$ to zero/L, but then swiftly increased to $5.08 \times 10^9/L$); therefore, additional treatments with intravenous cyclophosphamide at 15 mg/kg for 1 day and IVIG 400 mg/kg/day for 5 days were administered. Peripheral eosinophils improved to within normal limits and the left leg pain significantly improved (VAS 40). The muscle power significantly improved (MMTS 4+) and atrophy slightly improved. The cold sensation in the left leg also improved after IVIG. The serum anti-myeloperoxidase ANCA levels decreased to within normal limits. An additional course of IVIG was repeated 1 month later and all of the symptoms improved further. The patient clearly stated that the first IVIG (with the combination of cyclophosphamide) and the second IVIG were both effective. A third round of IVIG was carried out 1 month later, but the pain and atrophy in the left leg did not show any further significant improvement. The patient declined a fourth course of IVIG.

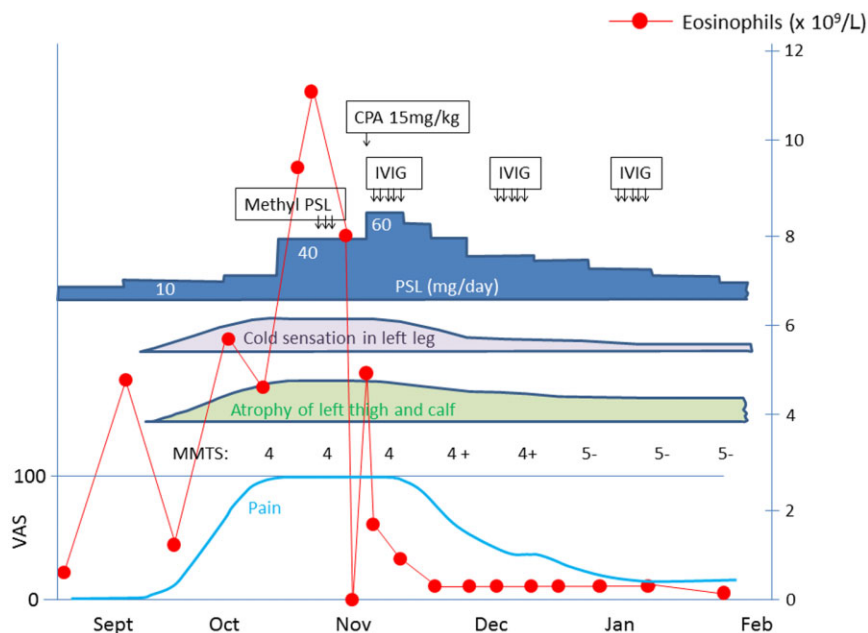


Figure 2. Clinical course. Immunglobulin was given 400 mg/kg/day for 5 days. Methyl PSL was given 1 g/day for 3 days. CPA, cyclophosphamide; IVIG, intravenous immunoglobulin therapy; MMTS, manual muscle test score (left gastrocnemius muscles); PSL, prednisolone; VAS, visual analog scale.

Discussion

We experienced a case of neuropathy with severe left leg pain due to CSS that was effectively treated with intravenous cyclophosphamide and IVIG therapy. The patient had been diagnosed with CEP 7 years prior. Golstein et al. have reported on three patients who developed CSS about 8 years after being diagnosed with CEP [1]. The interval between the onset of CEP and CSS in our case was very similar to their report. Patients diagnosed with CEP should be carefully monitored for the development of neuropathy due to CSS.

Permanent neuralgia and muscle weakness due to CSS have been reported to be less prevalent in patients treated with IVIG [4]. Although the mechanisms of the therapeutic effects of IVIG remain unclear, a delay in the diagnosis or in the treatment could increase the extent of the vasculitic damage in the nerve trunks. Tsurikisawa et al. reported that IVIG treatment decreased the number of activated eosinophils expressing CD69⁺ without changing the number of peripheral eosinophils [3, 5]. Considering the swift normalization of peripheral eosinophilia in this case (Fig. 2), cyclophosphamide was thought to decrease the total number of eosinophils. Another mechanism of IVIG may be perfusion improvement [5]. Although this patient had a cold sensation in the lower limb, it improved after the first course of IVIG. IVIG improves blood flow to nerves,

which may serve an important role in improving the neuropathy in CSS.

Currently, the Japanese drug use system regulates the new treatment of IVIG for CSS according to the guideline that IVIG should only be considered after conventional therapy with steroids is not sufficient. On the other hand, guidelines describe that the conventional therapies with steroids and cyclophosphamide should be used for ANCA-associated vasculitis [2]. Here we used IVIG and cyclophosphamide at almost the same time (Fig. 2), and the severe neuralgia was relieved significantly. Reviewing the clinical course of this patient, we feel that the effects of IVIG combined with cyclophosphamide are promising. This may be an effective combination to be considered in patients with severe neuralgia.

Acknowledgments

We thank Dr. Naoki Miyao, Department of Internal Medicine, Nihonkoku Hospital, Kanagawa, Japan, for efficient discussion.

Disclosure Statements

No conflict of interest declared.

Appropriate written informed consent was obtained for publication of this case report and accompanying images.

References

1. Golstein MA, and Steinfeld S. 1996. Chronic eosinophilic pneumonia followed by Churg–Strauss syndrome. *Rev. Rhum. Engl. Ed.* 63:624–628.
2. Lapraik C, Watts R, Bacon P, et al. 2007. BSR and BHPR guidelines for the management of adults with ANCA associated vasculitis. *Rheumatology (Oxford)* 46:1615–1616.
3. Taniguchi M, Tsurikisawa N, Higashi N, et al. 2007. Treatment for Churg–Strauss syndrome: induction of remission and efficacy of intravenous immunoglobulin therapy. *Allergol. Int.* 56:97–103.
4. Danieli MG, Cappelli M, Malcangi G, et al. 2004. Long term effectiveness of intravenous immunoglobulin in Churg–Strauss syndrome. *Ann. Rheum. Dis.* 63:1649–1654.
5. Tsurikisawa N, Taniguchi M, Saito H, et al. 2004. Treatment of Churg–Strauss syndrome with high-dose intravenous immunoglobulin. *Ann. Allergy Asthma Immunol.* 92:80–87.