



## Case Report

# Can a biologic mesh survive a *Candida krusei* infection? A case report of infection of a biologic mesh following repair of abdominal wall hernia



Elfatih I. Abter\*, Keith Apelgren, Gary Salem, Ruben Toribio

McLaren Health Systems, Lapeer Regional Medical Center, Lapeer, MI, United States

## ARTICLE INFO

## Article history:

Received 19 March 2014

Received in revised form 7 June 2014

Accepted 17 June 2014

## Keywords:

*Candida krusei*

Biologic mesh

Surgical site infection

Candida

Yeasts

## ABSTRACT

The use of biologic mesh, which is considered resistant to infection, has become common. It is preferred over synthetic mesh for use in contaminated fields. Fungal infection with infiltration of biologic mesh is rare and has not been reported. In this paper, we report a case of a patient who underwent multiple laparotomies and received multiple antibiotics and an azole antifungal. Biologic mesh was used, but it ultimately required removal because of chronic infection with *Candida krusei*. On biopsy, the yeast was found to have infiltrated the mesh.

© 2014 The Authors. Published by Elsevier Ltd. This is an open access article under the CC BY-NC-ND license (<http://creativecommons.org/licenses/by-nc-nd/3.0/>).

## Introduction

Repair of abdominal wall hernias with mesh has become common since it was first introduced in the 1950s [1]. The main benefit of using mesh is reduced recurrence of the hernia [2,3]. Various artificial mesh materials, both absorbable and non-absorbable, have been associated with a small but significant infection risk [4]. Biologic mesh was recently introduced. Its advantage is that it can be used to close abdominal wall defects in contaminated or infected fields [5]. In this paper, we report a case of infection of a biologic mesh following repair of abdominal wall hernia. *Candida krusei* was repeatedly isolated despite administration of antifungals. We also discuss the literature regarding the optimal treatment for this case.

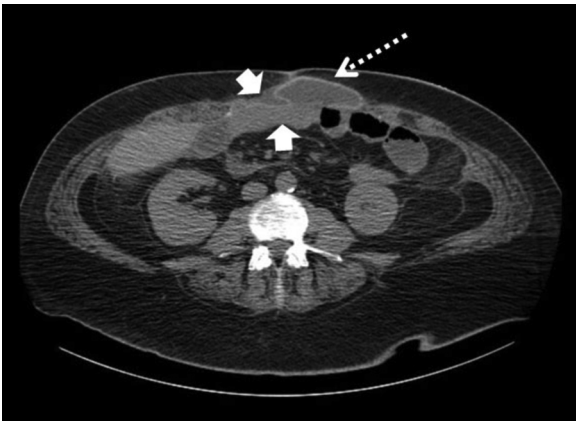
## Case report

The patient is a 40-year-old male who presented on March 15th, 2011 with a strangulated epigastric hernia. The hernia had been present for six years and was increasing in size, but the patient did not seek immediate medical care. Comorbidities included morbid obesity (BMI=45), diabetes, and nicotine abuse. He underwent emergency operation, in which small bowel resection and hernia repair were performed. The patient clinically deteriorated and was returned to the OR four days later, during which he underwent colectomy for dead bowel and

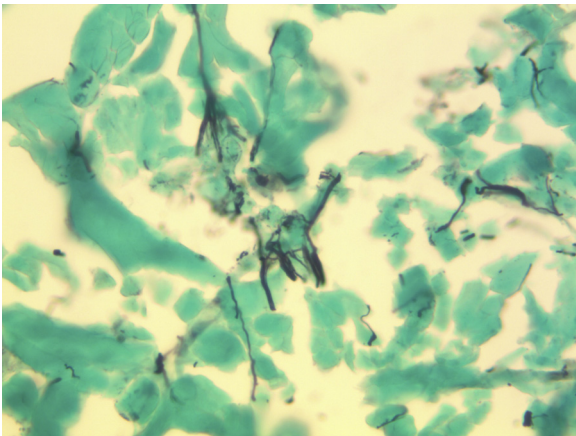
fascial debridement of the abdominal wall for necrotizing fasciitis. The patient developed sepsis, respiratory distress, and acute renal injury. Cultures obtained intraoperatively showed polymicrobial flora, including Gr. B *Streptococcus*, *Clostridium perfringens*, *Prevotella* spp., *Enterobacter* spp., and *Candida albicans*. Management with antibiotics was started with meropenem, clindamycin, and fluconazole. The latter was given for 10 days and then extended for 10 more days because new wound cultures grew *C. albicans*. The abdominal fascia was left open, and a vacuum-assisted closure device was used. The patient had a planned return to the OR two days later during which more fascia was debrided, and another small bowel resection was performed for more necrotic bowel. Ileostomy was performed. Twenty days after admission, he was returned to the OR for an anastomotic leak. Twenty-four days after admission, the patient again went to the OR for tracheostomy, further abdominal wall debridement, and placement of non-crosslinked human dermic mesh (Allomax-Bard). The antibiotics, including fluconazole, were continued. The patient returned to the OR 48 h later for re-exploration, irrigation, and removal and replacement of the mesh. On subsequent cultures, yeast organisms were seen on the Gram stain of the wound. Fluconazole was discontinued, and the patient was started on micafungin 100 mg daily. Micafungin was kept for 2 weeks. The patient later underwent skin closure over the mesh with closed suction drainage. He made a slow recovery over the next six weeks but was left with a chronically draining wound from which *C. krusei* grew on repeated cultures for a period of two months despite two consecutive courses

\* Corresponding author. Tel.: +1 2487605812.

E-mail addresses: [eabter@msn.com](mailto:eabter@msn.com), [elfatih.abter@mcclaren.org](mailto:elfatih.abter@mcclaren.org) (E.I. Abter).



**Fig. 1.** The axial image obtained as part of a CT of the abdomen and pelvis performed without contrast demonstrated a linear area of increased density (dashed arrow) corresponding to the hernia mesh at the anterior aspect of the peritoneal cavity filling the anterior facial defect with fluid both superficial and deep to this mesh (solid arrows).



**Fig. 2.** A photomicrograph showing budding yeast and pseudohyphae consistent with *Candida* species and inflammatory debris within the mesh. (Silver methenamine stain, original magnification 400 $\times$ .)

of micafungin each for a two-week duration. CT scan of the abdomen showed a large fluid collection between the skin and the mesh (Fig. 1). The patient then underwent mesh removal and drainage. Cultures from the mesh grew *C. krusei*, and histology showed fungal elements within the mesh (Fig. 2). Blood cultures were repeatedly drawn throughout the patient's inpatient and outpatient course, but none was positive for yeast. Following mesh removal, the patient was kept on micafungin for 10 days. Fungal susceptibility testing was not obtained and was deemed unnecessary because *C. krusei* is generally considered resistant to fluconazole [6], has a lower susceptibility to amphotericin B than other *Candida* species [7], and is susceptible to echinocandin antifungals [8,9].

The patient slowly made a complete recovery and finally resumed his normal activities. Nine months later, he underwent closure of his ileostomy with an uneventful recovery.

## Discussion

Infection with *C. krusei*, known for its resistance to fluconazole [6], can occur in the susceptible host following management or prophylaxis with fluconazole [7]. Recent studies showed improved survival with the use of new antifungals, such as echinocandins [8,9].

The patient we presented had multiple laparotomies, bowel resections, and serious complications, including sepsis, fasciitis, and wound infection. He received multiple antibacterials and fluconazole. Biologic mesh was used because it is theoretically superior for contaminated wounds. Biologic mesh was first approved by the FDA in 1999 for use as an alternative to leaving the abdomen open in contaminated abdominal wounds [10]. Studies have shown that this practice is usually successful [11,12]. Unlike synthetic mesh, biologic mesh can be from an animal (porcine) or human source. The human dermis mesh is made from an extracellular dermal matrix stripped from cells (acellular dermal matrix). It provides a scaffold onto which the patient's body sends blood vessels, a process that leads to remodeling and also allows blood supply and immunologic defenses; for this reason, it is theoretically resistant to infection [13,14]. An important drawback of biologic mesh, however, is its high cost [15]; the cost of human-derived mesh is higher than that of animal mesh [16]. Three recent reviews [17–19] have shed light on the issues of hernia recurrence and mesh infection with the use of biologic mesh. The data are insufficient to draw any solid conclusions on the infection risk of biologic mesh, and hernia recurrence is high.

In our case, the *C. krusei* infection persisted despite long-term surgical drainage and management with micafungin. The secretions of the wound tended to clear when the patient was receiving the antifungal, and they re-accumulated when it was stopped, with the repeat cultures growing the yeast. For this reason, a decision was made to remove the biologic mesh. In summary, biologic mesh can be used to close infected abdominal wounds. The case we presented demonstrates that such a mesh can become chronically infected with *Candida* spp. and thus require removal.

## Conflict of interest

No conflicts of interest for all of the authors.

## Funding

None.

## Ethical approval

Written informed consent was obtained from the patient for publication of this case report and accompanying images. A copy of the written consent is available for review by the Editor-in-Chief on request.

## Authors contribution

All of the authors participated significantly in management of the patient, design of the outline of the case report and review of the literature. The manuscript was written by the first and second authors. The remaining authors also helped with review, suggestions, obtaining consent and selection of images.

## Acknowledgements

We thank Drs. Nader H. Bassily and Kevin Carter for their help with the images.

## References

- [1] Usher FC, Allen Jr JE, Crosthwait RW, Cogan JE. Polypropylene monofilament: a new biologically inert suture for closing contaminated wounds. *J Am Med Assoc* 1962;179:780–2.
- [2] Burger JW, Luijendijk RW, Hop WC, Halm JA, Verdaasdonk EG, Jeekel J. Long-term follow up of a randomized controlled trial of suture versus mesh repair of incisional hernia. *Ann Surg* 2004;240:578–85.

- [3] Luijendijk RW, Hop WC, van den Tol MP, de Lange DC, Braaksma MM, IJzermans JN, et al. A comparison of suture repair with mesh repair for incisional hernia. *N Engl J Med* 2000;343:392–8.
- [4] Robinson TN, Clarke JH, Schoen J, Walsh MD. Major mesh-related complications following hernia repair. *Surg Endosc* 2005;19:1556–60.
- [5] Catena F, Ansoloni L, Gazzotti F, Gagliardi S, Di Saverio S, D'Alessandro L, et al. Use of porcine dermal collagen graft for hernia repair in contaminated fields. *Hernia* 2007;11:57–60.
- [6] Ortega M, Marco F, Soriano A, Almela M, Martínez JA, López J, et al. *Candida* species bloodstream infection: epidemiology and outcome in a single institution from 1991 to 2008. *J Hosp Infect* 2011;77:157–61.
- [7] Abbas J, Bodey GP, Hanna HA, Mardani M, Girgawy E, Abi-Said D, et al. *Candida krusei* fungemia. *Arch Intern Med* 2000;160:2659–64.
- [8] McGee WT, Tereso GJ. Successful treatment of *Candida krusei* infection with caspofungin acetate: a new antifungal agent. *Crit Care Med* 2003;31:1577–8.
- [9] Hautala T, Ikäheimo I, Husu H, Säily M, Siitonen T, Koistinen P, et al. A cluster of *Candida krusei* infections in a haematologic unit. *BMC Infect Dis* 2007;7:97–102.
- [10] Franklin Jr ME, Gonzales Jr JJ, Michaelson RP, Glass JL, Chock DA. Preliminary experience with new bioactive prosthetic material for repair of hernia defects in infected fields. *Hernia* 2002;6:171–4.
- [11] Candage R, Jones K, Luchette FA, Sinacore JM, Vandevender D, Reed 2nd RL, et al. Use of human acellular dermal matrix for hernia repair: friend or foe? *Surgery* 2008;144:703–9.
- [12] Carbonell AM, Matthews BD, Dréau D, Foster M, Austin CE, Kercher KW, et al. The susceptibility of prosthetic biomaterials to infection. *Surg Endosc* 2005;19:430–5.
- [13] Helton WS, Fisichella PM, Berger R, Horgan S, Espat NJ, Abcarian H. Short term outcomes with small intestinal submucosa for ventral abdominal hernia. *Arch Surg* 2005;140:549–62.
- [14] Milburn ML, Holton LH, Chung TL, Li EN, Bochicchio GV, Goldberg NH, et al. Acellular dermal matrix compared with synthetic implant material for repair of ventral hernia in the setting of peri-operative *Staphylococcus aureus* implant contamination: a rabbit model. *Surg Infect* 2008;4:433–42.
- [15] Hodde J, Hiles M. Constructive soft tissue remodelling with a biologic extracellular matrix graft: overview and review of the clinical literature. *Acta Chir Belg* 2007;107:641–7.
- [16] Bellows CF, Alder A, Helton WC. Abdominal wall reconstruction using biologic tissue grafts: present status and future opportunities. *Expert Rev Med Dev* 2006;3:657–75.
- [17] den Hartog D, Dur AH, Tuinebreijer WE, Kreis RW. Open surgical procedures for incisional hernias. *Cochrane Database Syst Rev* 2008;16:CD006438.
- [18] Shah BC, Tiwari MM, Goede MR, Eichler MJ, Hollins RR, McBride CL, et al. Not all biologics are equal. *Hernia* 2011;15:165–71.
- [19] Holton LH, Kim D, Silverman RP, Rodriguez ED, Singh N, Goldberg NH. Human acellular dermal matrix for abdominal wall defects: review of clinical experience and experimental data. *J Long Term Effects Med Implants* 2005;15:547–58.