

Iatrogenic Kaposi sarcoma presenting as retiform purpura during treatment of bullous pemphigoid



Liesl Schroedl, BS,^a Esther Kim, MD,^b and Mark D. Hoffman, MD^b
Chicago, Illinois

Key words: bullous pemphigoid; retiform purpura; Kaposi sarcoma.

INTRODUCTION

Kaposi sarcoma is a vascular neoplasm associated with human herpesvirus-8 and is most typically expressed in the skin. Disease presentations are currently grouped into 1 of 5 contextual types: classic, endemic, epidemic HIV-associated, nonepidemic and iatrogenic. The iatrogenic form is generally a consequence of transplantation-related immunosuppression; occurrence during immunosuppressive treatment of autoimmune disease is reported but unusual. Kaposi sarcoma may manifest clinically in a variety of guises, and at least 10 morphologies have been recognized: typical patch, plaque and nodular forms, and the more unusual lymphadenopathic, exophytic, infiltrative, ecchymotic, telangiectatic, keloidal, and cavernous/lymphangioma-like forms.¹ Retiform purpura—branching and nonblanchable purple discoloration of the skin—is generally an indicator of vasculitis or vasculopathic occlusion, and has not been described as a manifestation of Kaposi sarcoma. We present an unusual case of Kaposi sarcoma manifesting as retiform purpura in the setting of bullous pemphigoid complicated by therapy-related leukopenia, which suggests that Kaposi sarcoma might be included in the differential diagnosis for retiform purpura.

CASE PRESENTATION

A 73-year-old black man with a medical history of type II diabetes mellitus and stage 3 chronic kidney disease, whose medications included furosemide and sitagliptin, presented with generalized pruritic bullae over the face, trunk, and all extremities (Fig 1). Skin biopsies for hematoxylin-eosin

stain and direct immunofluorescence were diagnostic of bullous pemphigoid, showing a subepidermal bulla with numerous eosinophils within the bulla and dermis, and linear IgG and C3 deposition at the epidermal basement zone. Enzyme-linked immunosorbent assay result indicated markedly elevated BP180 and BP230 antibodies (both >100 U; reference range <9 U). Other laboratory study results demonstrated a white blood cell count of $7.8 \times 10^3/\mu\text{L}$, eosinophilia (36%), and absolute lymphocyte count $1.26 \times 10^3/\mu\text{L}$; hemoglobin level was 9.7 g/dL, creatinine level 1.8 mg/dL, and glomerular filtration rate 37 mL/min/1.73 m². HIV serology results were negative. The patient began receiving prednisone 60 mg daily with mycophenolate mofetil 1 g twice daily, subsequently increased to 1.5 g twice a day, and initiated use of clobetasol ointment. The patient's furosemide and sitagliptin were discontinued because of concern that they were contributing to the bullous pemphigoid. Additionally, the patient was found to have suboptimal glucose control, so he was referred to endocrinology for management before discharge.

At a follow-up visit 3 weeks after his initial presentation, the patient demonstrated clinical improvement, with no active blisters. However, he was unable to verify that he was receiving mycophenolate mofetil as prescribed, and he was uncertain about his prednisone dose. After re-explanation of the regimen, and with verbalization of understanding, mycophenolate mofetil was continued at 1.5 g twice daily, and prednisone was further tapered from 40 to 30 mg once daily; a telephone call was made the next day to reinforce this plan.

From the Pritzker School of Medicine^a and the Department of Medicine, Section of Dermatology,^b University of Chicago.

Funding sources: None.

Conflicts of interest: None disclosed.

Correspondence to: Mark D. Hoffman, MD, Department of Medicine, Section of Dermatology, University of Chicago, 5841 S Maryland Avenue MC 5067, Chicago, IL 60637. E-mail: mdhoffman@uchicago.edu.

JAAD Case Reports 2020;6:247-9.

2352-5126

© 2020 by the American Academy of Dermatology, Inc. Published by Elsevier, Inc. This is an open access article under the CC BY-NC-ND license (<http://creativecommons.org/licenses/by-nc-nd/4.0/>).

<https://doi.org/10.1016/j.jidcr.2020.01.025>

One month later, the patient presented for follow-up, and it was determined that he had been receiving mycophenolate mofetil 5 g daily and prednisone 120 mg daily. He also displayed new cribriform erosions in the perianal area, which were suggestive of cytomegalovirus and confirmed via polymerase chain reaction testing. His white blood cell count was $11.2 \times 10^3/\mu\text{L}$; absolute lymphocyte count, $0.53 \times 10^3/\mu\text{L}$. The patient consequently began receiving valganciclovir 450 mg daily. Mycophenolate mofetil was completely discontinued, and prednisone de-escalation was recommenced.

Nearly 4 months after the initial presentation, he returned for follow-up, having recently begun receiving oral antibiotics for presumed new-onset cellulitis of a leg, and was found to have retiform purpura located on the left lower extremity (Fig 2, A) and focally on the right (Fig 2, B). Punch biopsies showed Kaposi sarcoma (spindle cell proliferation, numerous slitlike vessels in the dermis and subcutis with extravasated erythrocytes, and presence of human herpesvirus-8); thrombi were also noted within blood vessels (Fig 3). Direct immunofluorescence result was negative for vascular immunoglobulin deposition. Subsequent stool guaiac and chest radiograph results were negative. By this time, the patient's medication had been tapered to prednisone 10 mg daily; it was then decreased to prednisone 5 mg daily, with plans for continued decremental dose reduction with the goal of cessation. Follow-up 1 month later showed reemergence of 1 blister, but overall the patient was stable. The Kaposi sarcoma had also improved, concomitant with normalization of his lymphopenia. The patient's prednisone was ultimately tapered off entirely, whereas omalizumab was initiated in an effort to suppress the expression of the pemphigoid² off corticosteroids while ensuring proper dosimetry governed by in-office medication administration.

DISCUSSION

Herein, we present a case of bullous pemphigoid treated with systemic corticosteroids and mycophenolate mofetil complicated by immunosuppressive sequelae that resulted from intake of dosages exceeding prescribed amounts. Bullous pemphigoid, an autoimmune skin disorder characterized by IgG and also immunoglobulin E autoantibodies against hemidesmosomal proteins BP180 and BP230, can be treated with corticosteroids, nonsteroidal anti-inflammatory agents, or both, plus adjuvant immunosuppressant therapies if disease is severe. Mycophenolate mofetil, one of these immunosuppressant therapies, is typically used in doses

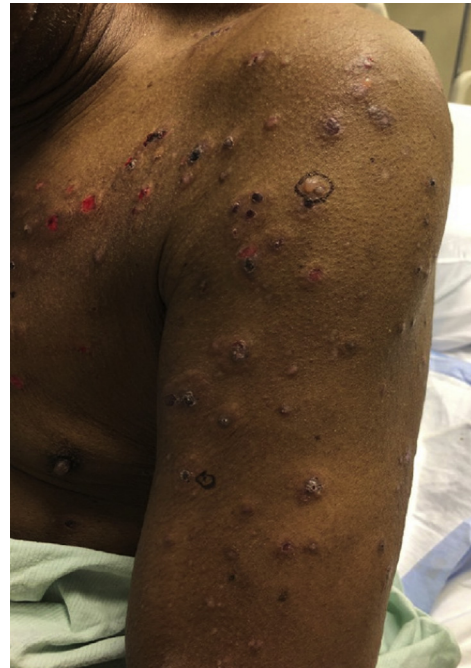

Fig 1. Numerous tense bullae, erosions, and crusted plaques present on the left side of the upper extremity and upper side of the chest on initial presentation.

of 1 to 2 g/day, but up to 3 g/day may be used if the glomerular filtration rate is greater than 25 mL/min/1.73 m². However, leukopenia may occur in up to 35% of patients at this maximal dose.³ Remarkably, reports from the 1970s describe dosages of mycophenolic acid in the treatment of psoriasis exceeding 7 g/day without significant laboratory abnormalities, although herpes simplex and herpes zoster occurred with increased frequency.⁴ However, patients were treated with only mycophenolate mofetil in this study; no corticosteroids were given concomitantly. Our patient received both mycophenolate mofetil and prednisone at high dosages, provoking his unfortunate development of cytomegalovirus and Kaposi sarcoma.

This manifestation of Kaposi sarcoma as retiform purpura in the context of mycophenolate mofetil and corticosteroid treatment for bullous pemphigoid was unique. Retiform purpura is classically associated with vasculitides such as IgA vasculitis, antineutrophil cytoplasmic antibody-positive vasculitides, and polyarteritis nodosa, or vascular occlusive phenomena related to coagulopathic syndromes, angioinvasive infections, cryoagglutination, or embolization.⁵ One case of mycophenolate mofetil-associated Kaposi sarcoma in a patient with bullous pemphigoid manifested as 3- to 10-mm bluish-red painless papulonodules,⁶ but Kaposi sarcoma manifesting as retiform purpura appears to have been undocumented until now. The retiform change in our case

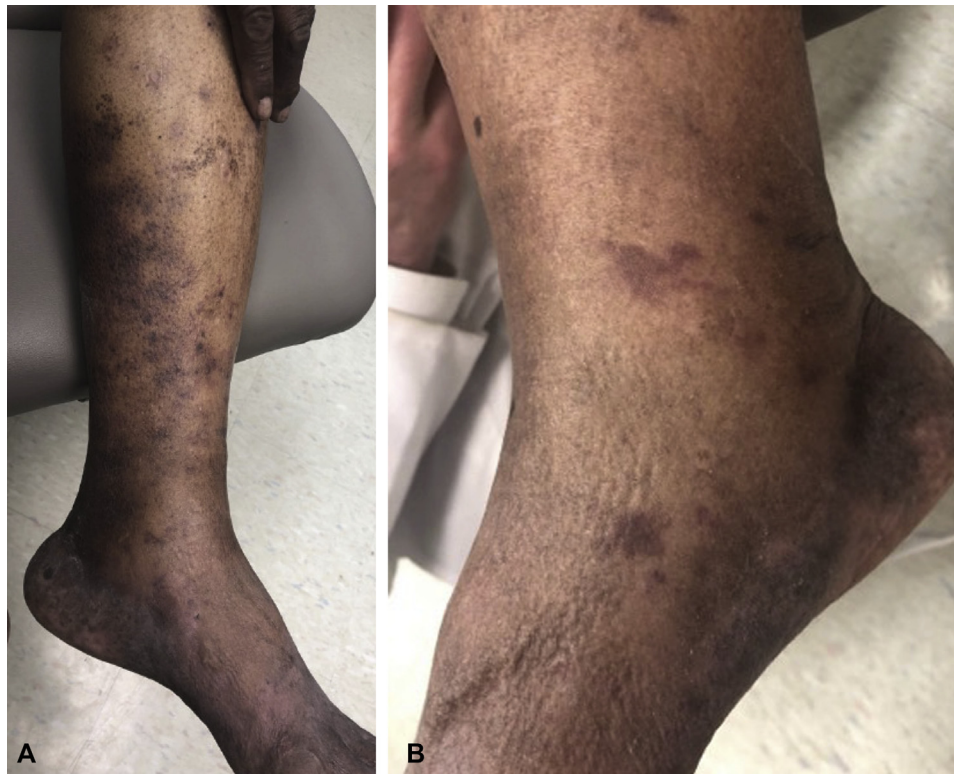

Fig 2. **A**, Retiform purpura on the left side of the lower extremity. **B**, Branching purpura focally on the medial side of the right ankle.

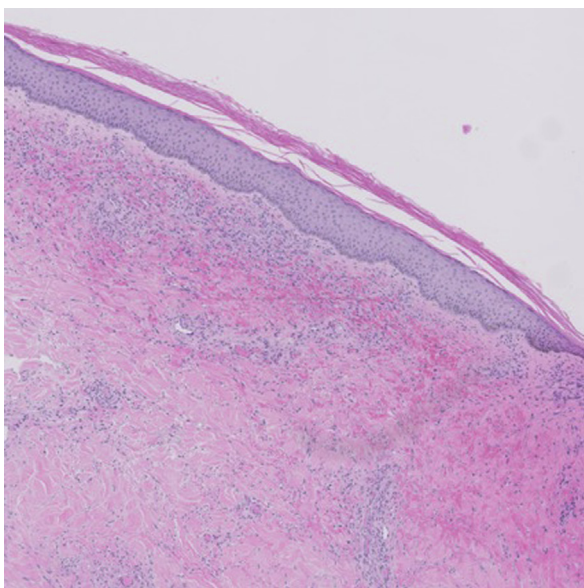


Fig 3. Kaposi sarcoma with vascular thrombi (arrows). Immunohistochemistry demonstrated strong human herpesvirus-8 labeling of the endothelial and stromal spindle cells (not shown). (Hematoxylin-eosin stain; original magnification: $\times 40$.)

was ascribed to the associated small vessel thrombosis, deemed to be a secondary phenomenon and a

feature that has also been observed in pseudo-Kaposi sarcoma⁷; there was no history of deep vein thrombosis. Our patient's unusual presentation illustrates that Kaposi sarcoma should be included in the differential diagnosis for retiform purpura, especially in the setting of immunosuppression.

REFERENCES

1. Schwartz RA. Kaposi's sarcoma: an update. *J Surg Oncol*. 2004; 87(3):146-151.
2. Vico-Alonso C, Calleja-Algarra A, Aragón-Miguel R, et al. Omalizumab as an alternative therapeutic tool in the treatment of bullous pemphigoid: a case report. *Dermatol Ther*. 2019;32(2): e12829.
3. Orvis AK, Wesson SK, Breza TS, Church AA, Mitchell CL, Watkins SW. Mycophenolate mofetil in dermatology. *J Am Acad Dermatol*. 2009;60(2):183-199.
4. Marinari R, Fleischmajer R, Schragger AH, Rosenthal AL. Mycophenolic acid in the treatment of psoriasis: long-term administration. *Arch Dermatol*. 1977;113(7):930-932.
5. Piette WW. The differential diagnosis of purpura from a morphologic perspective. *Adv Dermatol*. 1994;9:3-23. discussion 24.
6. Tremblay C, Friedmann D. Kaposi sarcoma associated with iatrogenic immunosuppression: a rare complication of bullous pemphigoid treatment. *J Cutan Med Surg*. 2017;21(5):449-451.
7. Goldblum OM, Kraus E, Bronner AK. Pseudo-Kaposi's sarcoma of the hand associated with an acquired, iatrogenic arteriovenous fistula. *Arch Dermatol*. 1985;121(8):1038-1040.