

# When Planning Screw Fracture Fixation Why the 5.5 mm Screw is the Goldilocks Screw. An Observational Computer Tomographic Study of Fifth Metatarsal Bone Anatomy in a Sample of Patients

Lukas D. Iselin, MD, Sunil Ramawat, MD, Brian Hanratty, FRCSI, MD, Georg Klammer, MD, and Peter Stavrou, MBBS, FRACS, FA Ortho A

**Abstract:** We wanted to verify our clinical experience that the 5.5 mm screw was ideal in the majority of fifth metatarsal fracture fixation. The size of a screw is important for the successful surgical treatment of these fractures in order to obtain the maximal stability while reducing the risk for iatrogenic fracture.

A sample of patients undergoing computer tomographic imaging of the foot for investigation other than fifth metatarsal pathology were recruited. The parameters of the fifth metatarsal bone anatomy were measured.

These parameters of the 5.5 mm screw were correlated with this data. The upper parameter (the diameter of the threads) was 5.5 and the lower parameter (the diameter of the shank) was 4.0 mm.

Twenty seven patients were recruited.

The proximal third internal diameter ranged from 3.6 to 7.0 mm with a mean of 5.0 mm. 93% of the metatarsals could easily accommodate the 5.5 mm screw. Two of the metatarsals had an internal diameter of < 4 mm (7%).

It is our belief that the 5.5 mm screw may be used safely in the majority of patients with fifth metatarsal fractures.

(*Medicine* 94(18):e756)

**Abbreviations:** Base d = depth on axial cut perpendicular to cortices, Base h = height on sagittal cut perpendicular to cortices, Base internal DM = diameter on the base, CL = central length MT V prox to distal on sagittal cut, DM int 1/3 = diameter proximal third/Isthmus, DM int 2/3 = diameter distal third, LL = lateral length on sagittal cut, ML = medial length on sagittal cut, MTV = fifth metatarsal bone.

Editor: Stuart Barry Polissner.

Received: October 21, 2014; revised: March 13, 2015; accepted: March 18, 2015.

From the University Hospital Basel, Department of Traumatology, Basel, Switzerland (LDI); Adelaide Orthosports Clinic, Adelaide, SA, Australia (LDI, SR, BH, PS); Department of Orthopaedics & Trauma, Luzerner Kantonsspital, Luzern, Switzerland (GK).

Correspondence: Lukas D. Iselin, University Hospital Basel, Department of Traumatology, Spitalstrasse 21, Basel CH 4031, Switzerland (e-mail: iselinlukas@mac.com).

Lukas D. Iselin and Sunil Ramawat contributed equally to this work. There has been no funding for the completion of this study. None of the authors has a conflict of interest.

Copyright © 2015 Wolters Kluwer Health, Inc. All rights reserved. This is an open access article distributed under the Creative Commons Attribution- NonCommercial License, where it is permissible to download, share and reproduce the work in any medium, provided it is properly cited. The work cannot be used commercially.

ISSN: 0025-7974

DOI: 10.1097/MD.0000000000000756

## INTRODUCTION

In our experience the 5.5 mm screw is ideal for fifth metatarsal fracture fixation. We wished to investigate why.

## BACKGROUND

Fracture to the fifth metatarsal has been shown to be a common injury. Screw size in the treatment of fifth metatarsal fractures is important; larger screws have been shown to cause iatrogenic fractures, and smaller screws have been noted to have poor purchase.<sup>1,2</sup> The range of screw sizes used to treat this fracture is from 4.5 to 6.5 mm.<sup>3,4</sup>

It was the senior author's experience that the 5.5 mm screw could be used in all cases. We wished to investigate if the concept of a "Goldilocks screw," that is, one that was not too big and not too small was appropriate.

## PATIENTS AND METHODS

Local ethical approval was gained (Ethical Committee of St. Andrews Hospital, Adelaide).

All procedures followed were in accordance with the ethical standards of the responsible committee on human experimentation (institutional and national) and with the Helsinki Declaration of 1975, as revised in 2008.

Recruitment of the sample was done locally from patients undergoing CT of their foot for other pathologies. Inclusion and exclusion criteria, see Table 1.

Twenty seven patients could be included in the study. Demographics, see Table 2.

A CT scan was taken of the whole foot (hind and forefoot). The full length of the fifth metatarsal had to be visible on the scan.

The internal parameters of bone morphology of the fifth metatarsal were measured, see Figure 2.

Correlation using the upper and lower parameters were arbitrarily chosen, but seemed reasonable as these were the dimensions of the screw.

We measured the length and height of the metatarsal bone. Additionally the inner and outer diameters of the metatarsal

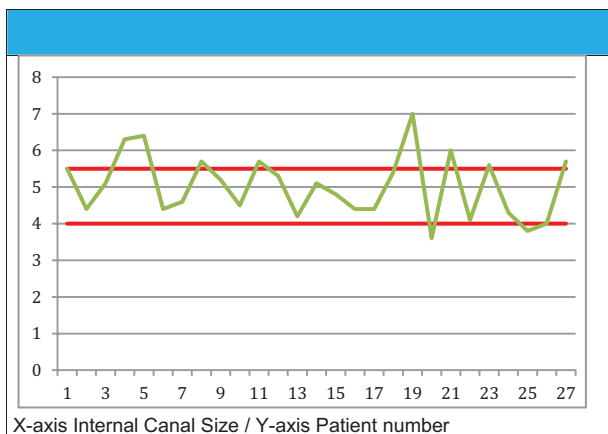
**TABLE 1.** Exclusion and Withdrawal Criteria

Patients with congenital foot deformity
Less than 18 and over 65 years of age
Osteoporosis under treatment
Previous fifth metatarsal fracture
Previous fifth metatarsal surgery

**TABLE 2.** Descriptive Data/Results

Variable	Results
Number, n	27
Age, years average (SD; min–max)	45 (20.34; 18–80)
Sex nM:nF (%:%)	14:13 (52:48)
Height cm average (SD; min–max)	172 (12.38; 152–198)
Shoe size US average (SD; min–max)	9.5 (1.976; 7.5–15)
Diameter MT V at isthmus	5.2 (0.9; 3.6–8)

Abbreviations: F = female, M = male, MT-V = 5th metatarsal bone, n = number, SD = standard deviation.



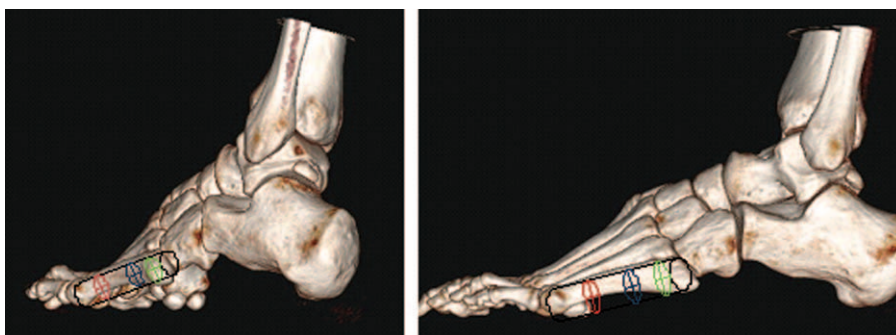**FIGURE 1.** Screw Size.

were measured at the base, at the first third, and at the second third mark.

**RESULTS**

The proximal third internal diameter ranged from 3.6 to 7.0 mm with a mean of 5.0 mm.

In 93% of the metatarsals the internal diameter was > 4 mm. Two of the metatarsals had an internal diameter of less than 4 mm (7%). Eight out of 27 (30%) of the analyzed feet revealed fifth metatarsal internal diameters with > 5.5 mm. See Figure 1.



**FIGURE 2.** 3D CT scan and measurement points.

**DISCUSSION**

The fifth metatarsal is commonly injured.<sup>5</sup> The described incidence is about 1.8 per 1000 person years.<sup>6,7</sup> Aim of the operative fracture treatment is the reduction of nonunion and mal-union rate and a quick return to daily activities or sports in athletes.<sup>8</sup> A recent systematic literature review by Roche on treatment and return to sport following basal fifth metatarsal fractures reveals that acute fractures treated nonoperatively had a lower union rate compared with fractures treated with an intramedullary screw. Delayed unions treated nonoperatively had a 50% lesser union rate than the operated ones.<sup>9</sup>

Fractures of the fifth metatarsal can be described as two types. Either of the tuberosity or of the proximal part of the diaphysis distal to the tuberosity.<sup>5</sup> A more specific classification defining clearer fracture zones has also been described by Torg. Zone 1 the proximal tubercle, Zone 2 the metatarsal-diaphyseal junction, and Zone 3 the proximal diaphysis.<sup>10,11</sup>

The fractures of the tuberosity are usually avulsion type injuries after forced inversion. The fractures to Zone 2 area seem to occur after acute injury. This area involves the fourth and fifth metatarsal articulation and is a vascular watershed area and therefore at risk of nonunion.<sup>12–14</sup>

Zone 3 is distal to the fourth and fifth metatarsal articulation. Injuries here are also associated with an increased risk of nonunion. They more often occur as stress fractures in athletes and can be seen in patients with sensory neuropathies of different etiology.<sup>15</sup>

With regard to bending stiffness Kelly et al described no significant difference in fractures treated with the 5.0 and 6.5 mm screws.<sup>2</sup>

Our study shows that the 5.5 mm can be used safely in 93% of fifth metatarsal fractures, but that in 30% of cases the purchase may not be as strong as a larger screw. Also the shank of the screw would engage with the cortex 7% of the time. Although this may unduly stress the bone the two measurements were less than a half a millimeter and may not have any clinical importance.

Strengths of this study are the accurate measurement using CT and the transformational application of this information to the clinical setting in order to simplify a surgeon’s choice of the implant planning.

A weakness of the study is that it is only descriptive/observational. Further correlation with clinical trials would have to be carried out to make firm conclusions.

**CONCLUSION**

It is our belief that the 5.5 mm screw (Goldilocks) may be used safely in the majority of patients.

We have used the 5.5 screw safely for over 10 years and have anecdotally good result from it and were trying to explain our good results. This study has highlighted that it is definitely safe in 63% in Zones 2 and 3 but potentially could cause an iatrogenic fracture in 7% and lead to delayed- or nonunion in 30% when being too loose but our clinical experience has not shown this so far.

### ACKNOWLEDGMENT

*We would like to thank the Radiology Department of St. Andrews Hospital, Adelaide with the help of the data acquisition.*

### REFERENCES

- Glasgow MT, Naranja RJ Jr, Glasgow SG, et al. Analysis of failed surgical management of fractures of the base of the fifth metatarsal distal to the tuberosity: the Jones fracture. *Foot Ankle Int.* 1996;17:449–457.
- Kelly IP, Glisson RR, Fink C, et al. Intramedullary screw fixation of Jones fractures. *Foot Ankle Int.* 2001;22:585–589.
- Metzl J, Olson K, Davis WH, et al. A clinical and radiographic comparison of two hardware systems used to treat Jones fracture of the fifth metatarsal. *Foot Ankle Int.* 2013;34:956–961.
- Porter DA, Rund AM, Dobslaw R, et al. Comparison of 4.5- and 5.5-mm cannulated stainless steel screws for fifth metatarsal Jones fracture fixation. *Foot Ankle Int.* 2009;30:27–33.
- Jones R. Fracture of the base of the fifth metatarsal bone by indirect violence. *Ann Surg.* 1902;35:697–700.2.
- Low K, Noblin JD, Browne JE, et al. Jones fractures in the elite football player. *J Surg Orthop Adv.* 2004;13:156–160.
- Leumann A, Pagenstert G, Fuhr G, et al. Intramedullary screw fixation in proximal fifth-metatarsal fractures in sports: clinical and biomechanical. *Arch Orthop Trauma Surg.* 2008;128:1425–1430.
- Fetzer GB, Wright RW. Metatarsal shaft fractures and fractures of the proximal fifth metatarsal. *Clin Sports Med.* 2006;25:139–150.
- Roche AJ, Calder JD. Treatment and return to sport following a Jones fracture of the fifth metatarsal: a systematic review. *Knee Surg Sports Traumatol Arthrosc.* 2013;21:1307–1315.
- Torg JS, Balduini FC, Zelko RR, et al. Fractures of the base of the fifth metatarsal distal to the tuberosity. Classification and guidelines for non-surgical and surgical management. *J Bone Joint Surg Am.* 1984;66:209–214.
- Lehman RC, Torg JS, Pavlov H, et al. Fractures of the fifth metatarsal distal to the tuberosity: a review. *Foot Ankle.* 1987;7:245–252.
- Dameron TB Jr. Fractures and anatomical variations of the proximal portion of the fifth metatarsal. *J Bone Joint Surg A.* 1975;57:788–792.
- Smith JW, Amoczky SP, Hersh A. The intraosseous blood supply of the fifth metatarsal: implications for proximal fracture healing. *Foot Ankle.* 1992;13:143–152.
- Shereff MJ, Yang QM, Kummer FJ, et al. Vascular anatomy of the fifth metatarsal. *Foot Ankle.* 1991;11:350–353.
- Weinfeld SB, Haddad SL, Myerson MS. Metatarsal stress fractures. *Clin Sports Med.* 1997;16:319–338.