

SHORT REPORT

Intrarachidial Misplacement of a Venous Stent for Iliofemoral Deep Vein Thrombosis

Cécile Salathé^a, Jean Bonnemain^{a,*}, Pierre Turini^a, Claude Haller^b

^a Intensive Care Unit, CHVR, Sion, Switzerland

^b Department of Vascular Surgery, CHVR, Sion, Switzerland

Introduction: Complications due to venous thrombectomy and iliofemoral stenting in a patient with May–Thurner syndrome are reported.

Report: The patient presented with a third episode of deep vein thrombosis (DVT). A computed tomography (CT) scan confirmed the clinical suspicion of left iliofemoral vein thrombosis. After thrombectomy and stenting, the patient complained of left foot paralysis. CT showed the misplaced stent to be in the intrarachidial space. Surgical removal of the stent and new endovascular stenting resulted in complete recovery.

Discussion: This is the first description of this kind of complication after stenting of the left iliofemoral vein. Peri-operative Xray appeared to confirm correct placement of the stent via bilateral femoral venous access. Is a profile control image necessary in patients with an important collateral venous network including large veins?

© 2019 The Author(s). Published by Elsevier Ltd on behalf of European Society for Vascular Surgery. This is an open access article under the CC BY-NC-ND license (<http://creativecommons.org/licenses/by-nc-nd/4.0/>).

Article history: Received 13 August 2017, Revised 31 July 2019, Accepted 5 August 2019,

Keywords: Iliofemoral stent, May–Thurner syndrome, Peri-operative radioscopy

INTRODUCTION

This report describes a surprising complication following venous stenting, involving intrarachidial stent misplacement, despite peri-operative Xray monitoring, in a patient with an important collateral venous network discovered after proximal deep vein thrombosis (DVT).

REPORT

A 68 year old woman was admitted to the emergency department with a third episode of DVT. Clinical evaluation showed phlegmasia of the left leg. A computed tomography (CT) scan confirmed left iliofemoral vein thrombosis and May–Thurner syndrome (MTS) was suspected. The patient underwent surgical thrombectomy with angioplasty and stenting of the left iliofemoral vein. During surgery, an important collateral venous network was confirmed. The guidewire for stenting of the common left iliac vein was introduced easily, and after checking the correct position using a second guidewire from a right femoral access, joining in the inferior cava vein, the stenting was completed. After surgery the patient complained of mild lower back

pain. The next morning, the patient presented a new neurological deficit in the left L5 – S1 region. A CT scan was scheduled and showed that the patient's stent had been misplaced and was located in the epidural space, passing through the L4 – L5 foramen (Fig. 1).

After reviewing the images taken during the procedure, it was understood how the monitoring Xray done before placing the stent (sinus oblique 16 × 100 mm) had shown the superposition of the inferior vena cava guidewire (from the right side) and the intrarachidial location of the second guidewire (from the left side) after recanalisation. Surgery was scheduled and the patient underwent an uncomplicated L3 – L5 laminectomy and stent extraction. The whole procedure lasted 115 minutes with a maximum 300 mL blood loss. The patient underwent a second vascular procedure to position a new stent correctly. At one month, the patient had recovered from left foot paralysis and now walks without assistance.

DISCUSSION

MTS, or iliac vein compression syndrome, is the result of the right common iliac artery compressing the left iliac vein against the lumbar spine. This is a rarely diagnosed condition, but it increases the risk of DVT of the iliac vein. Several DVT treatments have been tried in this context since it was first described in 1957,¹ such as anticoagulation, local infusion of thrombolytics, and mechanical thrombectomy, but most involved a recurrence of DVT. Current treatment guidelines for clinically relevant chronic ilioacaval or

* Corresponding author. Centre Hospitalier du Valais Romand (CHVR), Hôpital de Sion, Intensive Care Unit, Avenue du Grand-Champsec 80, CH-1951 Sion, Switzerland.

E-mail address: jean.bonnemain@gmail.com (Jean Bonnemain).

2405-6553/© 2019 The Author(s). Published by Elsevier Ltd on behalf of European Society for Vascular Surgery. This is an open access article under the CC BY-NC-ND license (<http://creativecommons.org/licenses/by-nc-nd/4.0/>).

<https://doi.org/10.1016/j.ejvssr.2019.08.002>

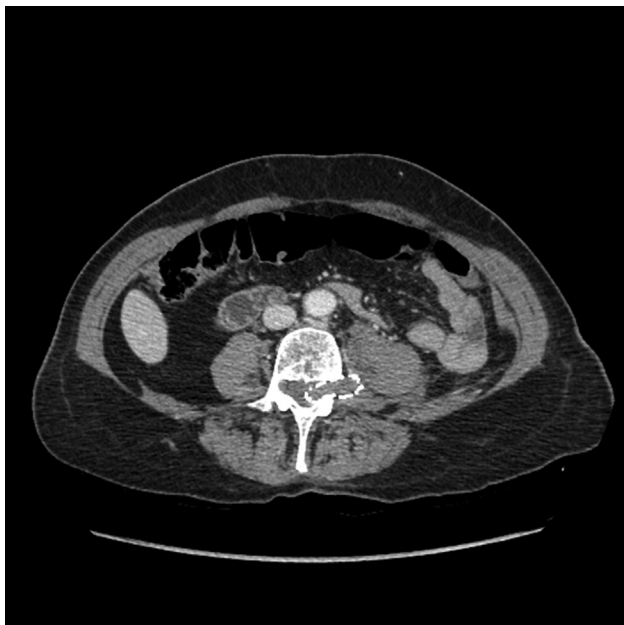

Figure 1. Computed tomography after angioplasty showing the stent passing through the foramen of L4 – L5.

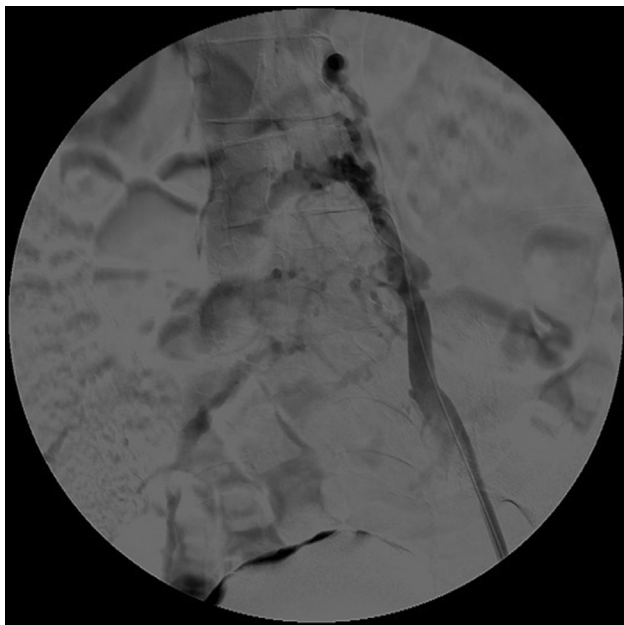


Figure 2. Angioplasty before stenting.

iliofemoral obstruction or symptomatic non-thrombotic iliac vein lesions recommend considering percutaneous angioplasty and stent placement using large self expanding stents (cl IIa, B).² Hölper *et al.* reported 19 patients who underwent combined venous balloon catheter thrombectomy, thrombolysis, and residual stenosis stenting, with a 68 month follow up.³ There were no fatal outcomes and no late re-thromboses.

Further reports followed, confirming the safety of this combined approach in patients with acute DVT and with known MTS, in groups both with and without thrombotic events.⁴ Rare complications have been described: Igari *et al.* reported two cases of re-thrombosis within seven days of

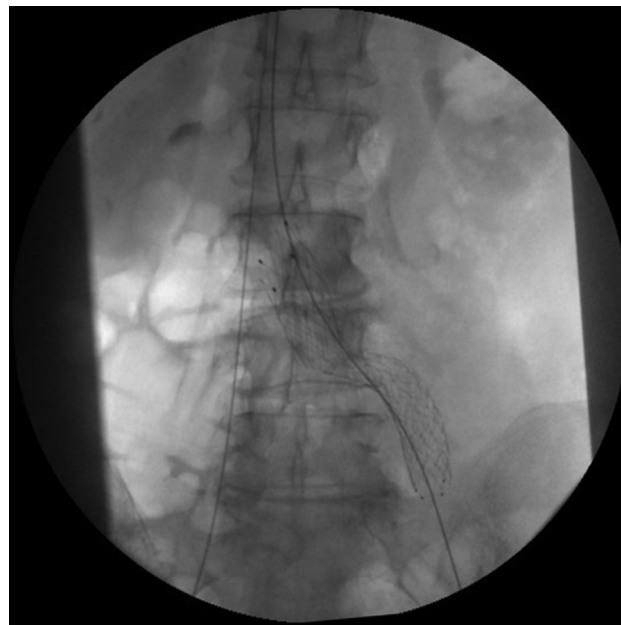


Figure 3. Monitoring Xray with the right iliofemoral guidewire joining the left iliofemoral guidewire in the inferior vena cava.

surgery,⁴ and Hagar *et al.* reported one patient with significant peri-procedural bleeding.⁵ Two cases of iliac vein rupture while performing percutaneous endoluminal interventions were reported by Adams *et al.*⁶ To the best of the authors' knowledge, the present report is the first to describe intrarachidial stent misplacement because of difficulty finding and accessing the left common femoral vein in the presence of large collateral veins (Fig. 2). Guidewire insertion was easy. Once the left guidewire was in place, a second guidewire was introduced into the right iliofemoral vein. A monitoring Xray showed the two guidewires to be apparently side by side, suggesting that they were both in the inferior vena cava (Fig. 3). In fact, the two guidewires

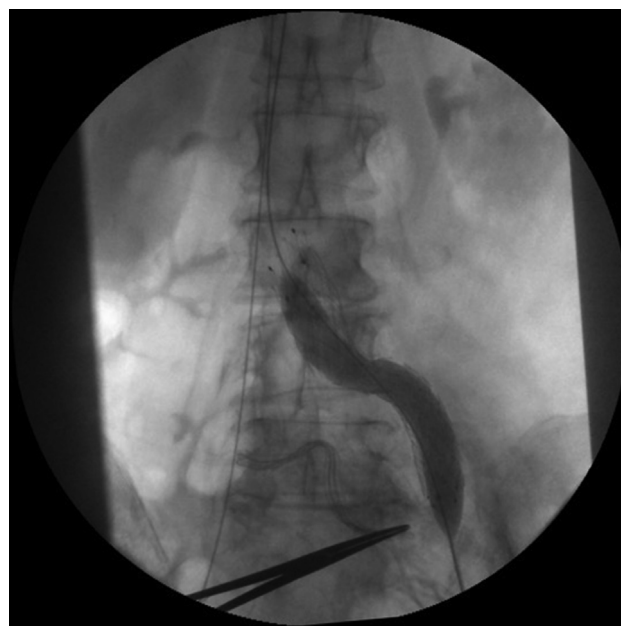


Figure 4. Xray at the end of the first procedure.

were superposed: the right guidewire was actually in the inferior vena cava, but the left guidewire was in a collateral vein entering the intrarachidial space (see Fig. 4).

CONCLUSION

This is the first description of a misplaced iliofemoral stent inside the intrarachidial space causing neurological consequences. Easy stent placement and reassuring peri-operative Xray images left no doubt that stent placement had been correct until the patient became symptomatic. To avoid this potential complication, a peri-operative profile view Xray or intravascular ultrasound would have been useful.⁷

CONFLICT OF INTEREST

None.

FUNDING

None.

REFERENCES

- 1 May R, Thurner J. The cause of predominantly sinistral occurrence of thrombosis of the pelvic veins. *Angiology* 1957;**8**:419–42.
- 2 Wittens C, Davies AH, Baekgaard N, Broholm R, Cavezzi A, Chastanet S, et al. Management of chronic venous disease: clinical practice guidelines of the European Society for Vascular Surgery (ESVS). *Eur J Vasc Endovasc Surg* 2015;**49**:678e737.
- 3 Hölper P, Kotelis D, Attigah N, Hyhlik-Dürr A, Böckler D. Long-term results after surgical thrombectomy and simultaneous stenting for symptomatic iliofemoral venous thrombosis. *Eur J Vasc Surg* 2010;**39**:349–55.
- 4 Igari K, Kudo T, Toyofuku T, Jibiki M, Inoue Y. Surgical thrombectomy and simultaneous stenting for deep venous thrombosis caused by iliac vein compression syndrome (May-Thurner syndrome). *Ann Thorac Cardiovasc Surg* 2014;**20**:995–1000.
- 5 Hagar ES, You T, Tahara R, Dillavou E, Al-Khoury G, Marone L, et al. Outcomes of endovascular intervention for May-Thurner syndrome. *J Vasc Surg Venous Lymphat Disord* 2013;**1**:270–5.
- 6 Adams MK, Anaya-Ayala JE, Davies MG, Bismuth J, Peden EK. Endovascular management of iliac vein rupture during percutaneous interventions for occlusive lesions. *Ann Vasc Surg* 2012;**26**:575.
- 7 Forauer AR, Gemmete JJ, Dasika NL, Cho KJ, Williams DM. Intravascular ultrasound in the diagnosis and treatment of iliac vein compression (May-Thurner) syndrome. *J Vasc Interv Radiol* 2002;**13**:523–7.