

A Modified Open Primary Laparoscopic Surgery Port Placement through Umbilical Tube

Bashiru Omeiza Ismaila, Barnabas T Alayande

Department of Surgery, Jos University Teaching Hospital, Jos, Plateau State, Nigeria

ABSTRACT

Background: A safe, reliable technique for primary trocar introduction is important for laparoscopic surgery. In resource-constrained settings where there is paucity of needed equipment and cost is prohibitive, a method utilizing fewer instruments will be useful. **Aim:** This study aims to describe a method of primary trocar introduction that utilizes any available port. **Methods:** A supra- or infra-umbilical incision is made into an everted tubular umbilicus. The linear alba is incised and the resultant opening bluntly developed, after which any available port is inserted using the trocar as a guide. The trocar is withdrawn while the sleeve is pushed in. **Results:** One hundred and three successful insertions were affected in 107 patients with age range of 1–75 years, with no significant gas leaks. **Conclusion:** This modified open approach is a simple and reliable way of primary port insertion. Access is gained easily in different age groups and umbilicus types.

KEYWORDS: Laparoscopic surgery, port, sleeve, trocar, umbilical tube

INTRODUCTION

Laparoscopic access is mandatory for laparoscopic surgery. The important initial step of laparoscopic surgery requires the safe insertion of the initial or primary port. Primary port insertion can potentially cause visceral and vascular injury. It is estimated that about 50% of complications in laparoscopic surgery occur during entry.^[1] Closed access techniques could result in injury to major vessels, bowel, and bladder. Open techniques of access are thought to be safer than closed methods but are also associated with similar complications.^[2,3] Several methods have been described, but many require special equipment to accomplish like the optical port.^[4] Open access techniques usually require instruments for minilaparotomy while Hasson's technique requires a special Hasson's port.

Laparoscopic surgery is technology dependent, and the required equipment is usually lacking in resource-constrained regions.^[5] For the constrained surgeon with limited equipment and choice of instruments, a safe, rapid, and reliable method of laparoscopic entry that can utilize any available trocar will be welcome.

This study describes a modified open method of primary trocar entry that has been used successfully in performing laparoscopic surgery with any available trocar.

METHODS

A total of 107 consecutive patients for laparoscopic procedures were enrolled in this study in a prospective manner. This method of primary port insertion was utilized for all the patients except those who had laparotomy incisions that traversed the umbilicus. Patients with midline incisions that did not involve the umbilicus were included in this study. In patients where primary port placement with this technique was unsuccessful, other methods, namely Veress needle through Palmer's point and Hasson's technique were utilized.

Surgical technique

A Mayo towel clip is applied to the lateral margins of the middle of the umbilicus. The application of upward traction on the umbilicus with the towel clip results in

Address for correspondence: Dr. Bashiru Omeiza Ismaila, Department of Surgery, Jos University Teaching Hospital, P. M. B. 2076, Jos, Plateau State, Nigeria.
E-mail: bashomeiza@gmail.com

This is an open access journal, and articles are distributed under the terms of the Creative Commons Attribution-NonCommercial-ShareAlike 4.0 License, which allows others to remix, tweak, and build upon the work non-commercially, as long as appropriate credit is given and the new creations are licensed under the identical terms.

For reprints contact: reprints@medknow.com

How to cite this article: Ismaila BO, Alayande BT. A modified open primary laparoscopic surgery port placement through umbilical tube. Niger J Surg 2019;25:76-9.

Access this article online	
Quick Response Code: 	Website: www.nigerianjsurg.com
	DOI: 10.4103/njs.NJS_34_18

the accentuation of the umbilical tube. This umbilical tube can usually be palpated. A small transverse skin incision, about the size of the available cannula, is made either just below or just above the umbilicus at the superior or inferior umbilical crease depending on the choice of the surgeon. Marking the skin by application of the trocar sleeve to the incision site will enable an accurate estimate of the required incision's diameter. Keeping the incision to the diameter of the sleeve reduces the chances of gas leaks. This incision is developed with artery forceps in the longitudinal plane resulting in the visualization of the umbilical tube prominently displayed in the wound [Figure 1]. A nick is made on the tube in the midline (along the linea alba and umbilical tube) with the scalpel [Figure 2], and a medium-sized artery forceps is used to penetrate the peritoneum and expand the incision [Figure 3]. Any available port is then inserted with the trocar serving as a guide. The trocar with its sleeve is inserted into the elevated orifice created through the umbilical tube [Figure 4]. While the sleeve is pushed in, the trocar is withdrawn. This ensures the trocar serves only as a guide to ensure that the sleeve gets into the peritoneal cavity and if the trocar tip is sharp there is no risk of inadvertent injury to underlying tissue. For spiral sleeves, after pushing the nonthreaded portion into the incision, a clockwise rotary movement is performed to push the threaded portion in (the reverse is performed to remove the spiral sleeve). The port is then connected to insufflation gas, and insufflation commenced [Figure 5]. Insufflation should proceed easily except if the port is extraperitoneal. The same technique is utilized in children. In event of any gas leak around the port (from a too large an incision), the towel clip is applied around to make the incision smaller.

At the end of the procedure, after deflating the abdominal cavity of gas, the towel clip is reapplied to the umbilicus and elevated. The umbilical tube is thus recreated, and the fascial access displayed. The insertion of a single size 0 absorbable suture (polydioxanone or polyglactin 910) through the center of the incision converts the 10 mm incision into two 5 mm incisions which closes the defect. Larger defects can be closed with an X stitch. Subcuticular stitches are used for the skin.

RESULTS

There were 107 patients who met the criteria with mean age of 32.1 years (range 1–75 years) who had 114 laparoscopic procedures [Table 1]. Seventy-two (67.3%) were female. Four of the patients who had associated

umbilical hernia (defect range 2–4 cm) had a primary port placement with this technique and defects were closed with nonabsorbable suture (polypropylene) through the port wound. There were four unsuccessful insertions in obese patients with very deep umbilical cicatrix. There were no injuries to viscera or vessels.

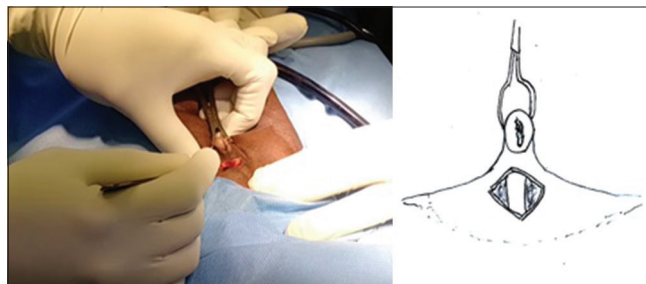


Figure 1: Everted umbilicus with incision exposing the umbilical tube

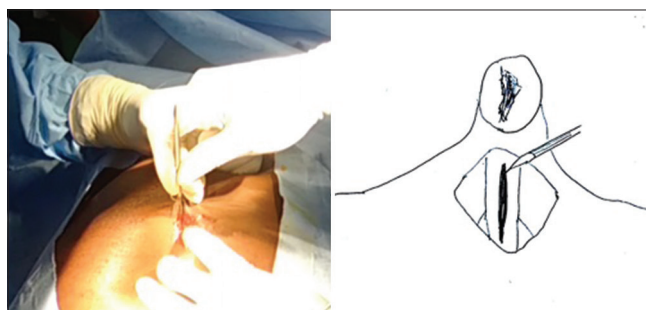


Figure 2: Nick made in the midline at linea alba and extended to umbilical tube

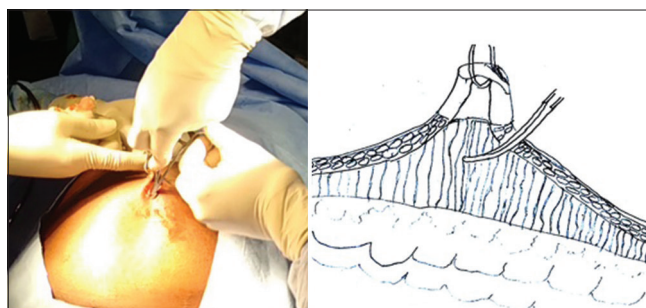


Figure 3: Peritoneum penetrated and nick widened by artery forceps

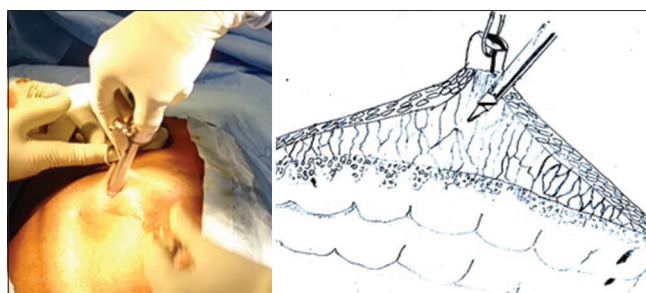


Figure 4: Trocar and sleeve inserted into incision on umbilical tube. Trocar serves as a guide and is withdrawn while sleeve is pushed in

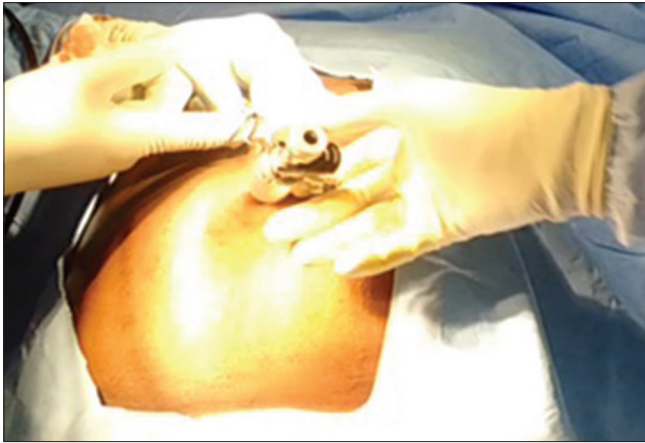

Figure 5: Sleeve ready for connection to gas tubing for insufflation

Table 1: Laparoscopic procedures (n=114)

Procedure	Frequency (%)
Laparoscopic appendectomy	38 (33.3)
Laparoscopic assisted appendectomy	14 (12.3)
Diagnostic laparoscopy	24 (21.0)
Laparoscopic cholecystectomy	23 (20.2)
Others	15 (13.2)
Total	114 (100)

DISCUSSION

Many methods have been developed for primary port placement in laparoscopic surgery.^[2-4] Popular methods are currently divided into open and closed methods largely exemplified by Hasson's technique and use of Veress needle respectively. The Hasson's method basically involves creating access to the peritoneal cavity through a minilaparotomy and insertion of a special cannula with a cone that prevents gas leakage from pneumoperitoneum.^[6] The Hasson's method is considered to be a safe method of creating pneumoperitoneum especially in patients with adhesions. The Veress needle is inserted after a tiny skin incision into the peritoneal cavity, and pneumoperitoneum achieved. The use of a Veress needle is essentially a blind technique and is thus considered a potential cause of injury. Relatively newer devices such as optical trocars can also cause entry complications.^[7,8] However, no method of entry is without complications. A meta-analysis showed a trend toward less risk of major complications with the open methods.^[3]

Apart from safety, another challenge faced in the developing world is the high cost and unavailability of laparoscopic equipment. The combinations of poverty, the high cost of equipment like trocars (disposable and reusable), and the pervasiveness of out of pocket payments make laparoscopic surgery more expensive than traditional surgery. Thus, establishing

pneumoperitoneum through the commonly described techniques may not always be feasible. Even where equipment and funds are available, with increasing health-care costs, efficient utilization of available equipment is desirable. Therefore, a reliable method that is safe and easy to perform with readily available equipment is essential for wider utilization of laparoscopic surgery.

The most important finding of this study was that a safe, open method of primary port insertion with any port available could be used for patients undergoing laparoscopic surgery. Our method does not require much ancillary equipment; what is needed include a towel clip and medium-sized artery forceps along with the trocar. The primary port placement was with reusable or disposable trocars, and these were placed without difficulty. We could also achieve primary port access in patients undergoing laparoscopic surgery who had uncomplicated umbilical hernias. In four patients, insertion of the primary port was unsuccessful. All these patients had obese abdominal walls with a deep-seated umbilical cicatrix.

That laparoscopic access to the abdomen could be obtained through the umbilical tube or stalk has been recognized by other investigators.^[9-12] Lal *et al.* described a method using an Allis tissue forceps or a towel clip to elevate the umbilical tube through a supra or infraumbilical incision but required two Allis forceps, artery forceps, and a small Lagenbeck retractor.^[10] Moberg *et al.* described a method similar to Lal's but used a towel clip instead of Allis forceps, passed a blunt reusable trocar and utilized S-shaped retractors in obese patients.^[11] Our technique is similar to that described by Sadhu *et al.*^[12] but while a blunt trocar was required initially in their description, ours used any available trocar and cannula with the trocar serving as a guide for the cannula. Our method ensures that the cannula fits snugly to the incision with no gas leaks. Sadhu *et al.* also insist on an infraumbilical skin incision while our technique is more versatile permitting access by either a supra or infraumbilical incision depending on the preference of the surgeon and anatomical target.

The utilization of any available trocar and sleeve for primary port placement in laparoscopic surgery without much ancillary instruments is a useful addition to established methods and confers a number of advantages. First, the number of instruments required for access is reduced. This makes the procedure cheaper, less cumbersome to perform, and reduces the number of instruments to be cleaned or sterilized (for reusable instruments). It also ensures that any trocar

and sleeve available can be utilized for primary open port placement. This is an important factor in resource poor settings where specific or special trocars may be unavailable. Although it was not part of the objectives of this study to determine the time taken for primary port insertion, we noticed that this method was faster compared to other methods like use of Verres needle or Hasson's method. Surgical trainees also found it easier to perform compared to the older more established methods. This is in keeping with the findings by Moberg *et al.* in their study^[11] who found that using the umbilical tube; initial port placement is a rapid and easily learned technique. Thus, it could reduce the time required for initial port placement a follow-up prospective study may be necessary to validate this.

The wide age range (1–75 years) of patients in whom this method was successfully employed without complications suggests that our method is suitable for all age groups.

There were a few limitations in our study. We did not assess the amount of time it took to insert the port utilizing our method. A follow-up randomized control trial comparing this method with established techniques is desirable.

CONCLUSION

We have described a simple, open method of laparoscopic primary port insertion through the umbilical tube, which utilizes any available trocar. This method can be used for all age groups, and our results have been encouraging in terms of ease of performance and reduction in gas leaks.

Financial support and sponsorship

Nil.

Conflicts of interest

There are no conflicts of interest.

REFERENCES

1. Krishnakumar S, Tambe P. Entry complications in laparoscopic surgery. *J Gynecol Endosc Surg* 2009;1:4-11.
2. Ahmad G, O'Flynn H, Duffy JM, Phillips K, Watson A. Laparoscopic entry techniques. *Cochrane Database Syst Rev* 2012; p. CD006583.
3. Merlin TL, Hiller JE, Maddern GJ, Jamieson GG, Brown AR, Kolbe A, *et al.* Systematic review of the safety and effectiveness of methods used to establish pneumoperitoneum in laparoscopic surgery. *Br J Surg* 2003;90:668-79.
4. Vilos GA, Ternamian A, Dempster J, Laberge PY; Clinical Practice Gynaecology Committee. Laparoscopic entry: A review of techniques, technologies, and complications. *J Obstet Gynaecol Can* 2007;29:433-47.
5. Ismaila BO, Shuaibu SI, Ale AA. Laparoscopic surgery in a Nigerian teaching hospital for 1 year: Challenges and effect on outcomes. *Niger J Med* 2013;22:134-7.
6. Hasson HM. A modified instrument and method for laparoscopy. *Am J Obstet Gynecol* 1971;110:886-7.
7. String A, Berber E, Foroutani A, Macho JR, Pearl JM, Siperstein AE, *et al.* Use of the optical access trocar for safe and rapid entry in various laparoscopic procedures. *Surg Endosc* 2001;15:570-3.
8. Thomas MA, Rha KH, Ong AM, Pinto PA, Montgomery RA, Kavoussi LR, *et al.* Optical access trocar injuries in urological laparoscopic surgery. *J Urol* 2003;170:61-3.
9. Carbonell AM, Harold KL, Smith TI, Matthews BD, Sing RF, Kercher KW, *et al.* Umbilical stalk technique for establishing pneumoperitoneum. *J Laparoendosc Adv Surg Tech A* 2002;12:203-6.
10. Lal P, Sharma R, Chander R, Ramteke VK. A technique for open trocar placement in laparoscopic surgery using the umbilical cicatrix tube. *Surg Endosc* 2002;16:1366-70.
11. Moberg AC, Petersson U, Montgomery A. An open access technique to create pneumoperitoneum in laparoscopic surgery. *Scand J Surg* 2007;96:297-300.
12. Sadhu S, Jahangir TA, Sarkar S, Dubey SK, Roy MK. Open port placement through the umbilical cicatrix. *Indian J Surg* 2009;71:273-5.