

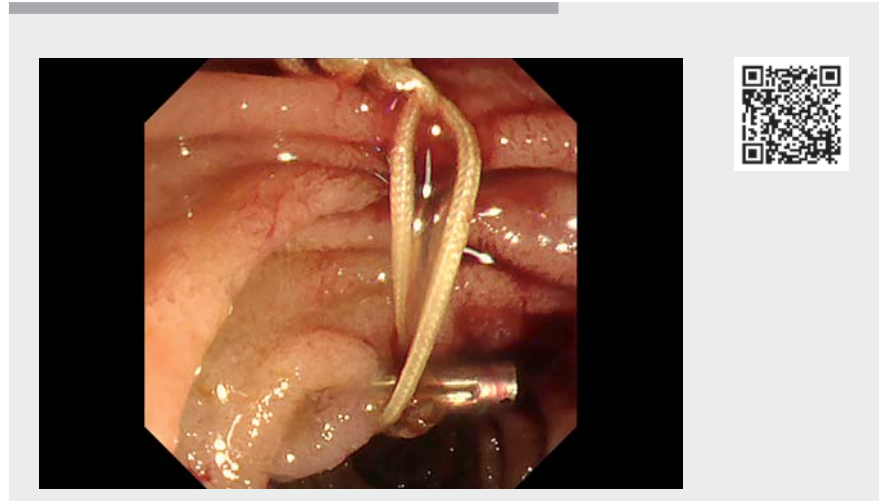
## Multiloop traction method during endoscopic hemostasis for post-sphincterotomy bleeding of the peridiverticular papilla



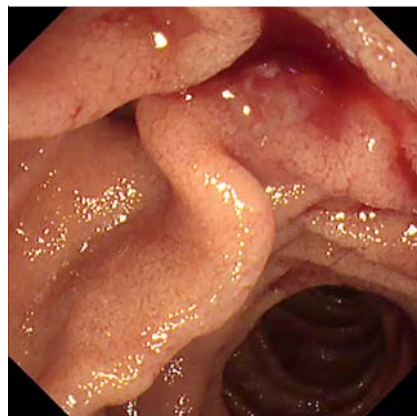
Periampullary diverticulum (PAD) is considered a risk factor for difficult biliary cannulation during endoscopic retrograde cholangiopancreatography (ERCP) because it makes the papilla unidentifiable [1]. Applying a traction force near the papilla has been reported to be effective in PAD biliary interventions [2]. We report a successful case of endoscopic hemostasis in post-sphincterotomy bleeding, using the multiloop traction method (M-loop method), in a patient with PAD [3] (▶ **Video 1**).

A 79-year-old man, taking direct oral anticoagulants (DOACs) for atrial fibrillation, presented with symptomatic common bile duct stones. His DOAC medication was temporarily discontinued on the day of the procedure. A successful endoscopic sphincterotomy (ES), with complete stone removal, was achieved.

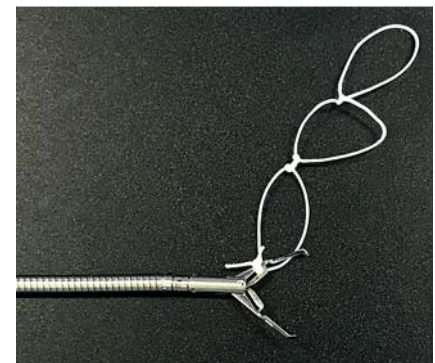
Post-ES bleeding was noted 4 days after the procedure (▶ **Fig. 1**). Achieving endoscopic hemostasis was challenging because the bleeding source was covered with duodenal mucosal folds. The M-loop method was used to locate and expose the bleeding source (▶ **Fig. 2**). A SureClip (Micro-Tech, Nanjing, China), attached to a multiple-loop-thread, was deployed to cover the mucosal fold. Additional clips were hooked onto the free loop and attached to the oral side of the duodenal wall. A traction force was generated to pull the duodenal mucosa covering the papilla upward. The bleeding point was sufficiently exposed (▶ **Fig. 3**, ▶ **Fig. 4**). A pancreatic stent was placed to avoid post-ERCP pancreatitis. Successful hemostasis was achieved with endoscopic coagulation, using a Coagrasper (Olympus, Tokyo, Japan) (▶ **Fig. 5**). The threads used in the M-loop method were cut after hemostasis. Rebleeding was not observed after restarting DOAC therapy. PAD has been reported to be a risk factor for post-ES bleeding [4]. Hemostasis for post-ES bleeding may be challenging in



▶ **Video 1** Endoscopic hemostasis, achieved using the multiloop traction method for post-sphincterotomy bleeding of the peridiverticular papilla.



▶ **Fig. 1** Endoscopy revealed that the unidentifiable bleeding source was in the peridiverticular papilla.



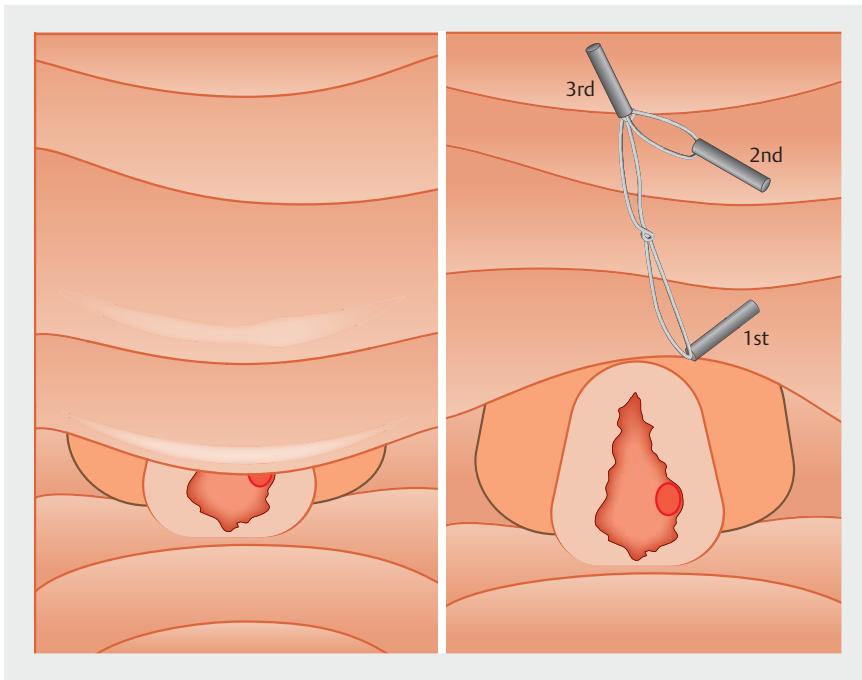
▶ **Fig. 2** How to make the multiloop traction loop (M-loop). A 3–0 silk suture thread was reeled around a 2.5-mL syringe, and multiple knots were made. The M-loop thread was recreated by repeating this process. The redundant thread of the M-loop was tied to the claw of a SureClip (Micro-Tech, Nanjing, China).

patients with PAD due to the deviation of the papilla's position. Traction, using the M-loop method, provides adequate exposure of the papilla, facilitating hemostasis in patients with post-ES bleeding.

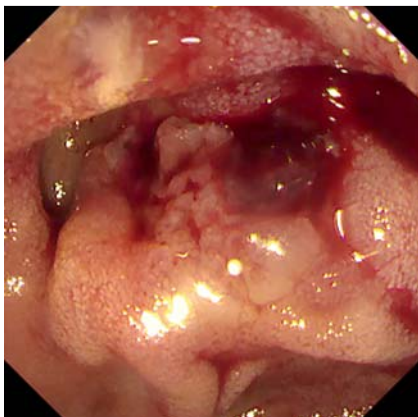
Endoscopy\_UCTN\_Code\_CPL\_1AK\_2AI

### Competing interests

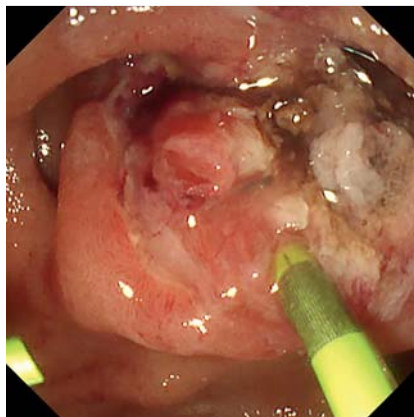
A. Katanuma has received honoraria as lecture fee from Olympus Co., Tokyo, Japan. All other authors declare that they have no conflict of interest.



► **Fig. 3** Schema before and after using the multiloop (M-loop) method.





► **Fig. 4** Endoscopic view after using the M-loop method; the bleeding source was sufficiently exposed.



► **Fig. 5** Endoscopic view after achieving successful hemostasis.

### The authors

**Kosuke Iwano, Haruka Toyonaga** , **Toshifumi Kin, Tatsuya Ishii** , **Akio Katanuma**  
Center for Gastroenterology, Teine Keijinkai Hospital, Sapporo, Hokkaido, Japan

### Corresponding author

**Kosuke Iwano, MD**  
Center for Gastroenterology, Teine Keijinkai Hospital, 1-40, 12-chome, 1-jou, Maeda, Teine-ku, Sapporo 006-8555, Hokkaido, Japan  
ksk.own@gmail.com

### References

- [1] Vaira D, Dowsett JF, Hatfield AR et al. Is duodenal diverticulum a risk factor for sphincterotomy? *Gut* 1989; 30: 939–942
- [2] Inoue R, Kawakami H, Kubota Y et al. Endoscopic biliary intervention using traction devices for periampullary diverticulum. *Intern Med* 2019; 58: 2797–2801
- [3] Ishii T, Kin T, Katanuma A. Successful intervention using multiloop traction for cases with difficult biliary cannulation due to periampullary diverticula. *Dig Endosc* 2021; 33: e111–e113
- [4] Leung JWC, Chan FKL, Sung JYY et al. Endoscopic sphincterotomy-induced hemorrhage: a study of risk factors and the role of epinephrine injection. *Gastrointest Endosc* 1995; 42: 550–554

### Bibliography

*Endoscopy* 2022; 54: E769–E770

DOI 10.1055/a-1795-7092

ISSN 0013-726X

published online 8.4.2022

© 2022. The Author(s).

This is an open access article published by Thieme under the terms of the Creative Commons Attribution-NonDerivative-NonCommercial License, permitting copying and reproduction so long as the original work is given appropriate credit. Contents may not be used for commercial purposes, or adapted, remixed, transformed or built upon. (<https://creativecommons.org/licenses/by-nc-nd/4.0/>)

Georg Thieme Verlag KG, Rüdigerstraße 14, 70469 Stuttgart, Germany



### ENDOSCOPY E-VIDEOS

<https://eref.thieme.de/e-videos>



*Endoscopy E-Videos* is an open access online section, reporting on interesting cases and new techniques in gastroenterological endoscopy. All papers include a high quality video and all contributions are freely accessible online. Processing charges apply (currently EUR 375), discounts and waivers acc. to HINARI are available.

This section has its own submission website at <https://mc.manuscriptcentral.com/e-videos>