

Anesthetic approaches in carotid body tumor surgery

Ali Sait Kavakli, Nilgun Kavrut Ozturk

Department of Anesthesiology and Reanimation, Antalya Training and Research Hospital, Antalya, Turkey

ABSTRACT

OBJECTIVE: Carotid body tumors (CBT) are benign tumors that originate from neural non-chromaffin cells that are typically localized near carotid bifurcation. Surgical removal of the tumor is the most appropriate treatment. General anesthesia is preferred anesthetic technique for CBT surgery. Basic elements of anesthetic management are protection of hemodynamic stability and maintaining cerebral perfusion pressure (CPP). The aim of this study was to evaluate anesthetic management of CBT surgery and present the literature knowledge.

METHODS: The study included 10 consecutive patients with diagnosis of CBT who underwent surgery at Antalya Training and Research Hospital, in Antalya, Turkey, between 2013 and 2016. Preoperative demographic details; comorbidities; side of surgical site; duration of operation; length of intensive care unit (ICU) and hospital stay; change of intraoperative blood pressure; use of inotropic drugs, blood products, and analgesics; postoperative visual analogue scale (VAS) pain score; and complications were recorded.

RESULTS: According to Shamblin classification, 3 tumors were type I and the remaining 7 were type II. Tumors were located on right side in 6 patients, and on left in 4. Blood loss sufficient to require transfusion was observed in 1 patient. Average intraoperative blood loss was 287 ± 68 mL. Tachycardia and hypertension were observed in 1 patient; bradycardia and hypotension were seen in 4 patients. Infusion for inotropic support was administered to 1 patient. Mean duration of operation was 109 ± 20 minutes. Mean VAS score was 4 ± 1 , mean ICU tramadol consumption was 80 ± 25 mg. Duration of stay in ICU and hospital were 2.4 ± 1.1 hours and 3.8 ± 0.7 days, respectively. Mortality and neurological complications were not seen in postoperative period.

CONCLUSION: CBT surgery requires close and complex anesthesia management. Protection of hemodynamic stability against sudden hemodynamic changes, monitoring, and maintaining CPP are the most important aspects of anesthetic management.

Keywords: Anesthetic considerations; carotid body tumors; glomus tumors.

Carotid body tumors (KBTs) are primary tumors of the chemoreceptor tissue, and they originate from paraganglionic corpuscles. Gener-

ally they are localized near carotid bifurcation [1]. They are generally benign, and they can have a malignant structure. Benign tumors are generally seen



Received: September 27, 2016 Accepted: October 12, 2016

Correspondence: Dr. Ali Sait KAVAKLI. Antalya Egitim ve Arastirma Hastanesi Anesteziyoloji ve Reanimasyon Klinigi 07100 Antalya, Turkey.

Tel: +90 242 - 249 44 00 e-mail: alisaitkavakli@hotmail.com

© Copyright 2016 by Istanbul Northern Anatolian Association of Public Hospitals - Available online at www.kuzeyklinikleri.com

between 40, and 70 years of age, while malignant CBTs emerge at younger ages [2]. The mass lesions grow slowly, however if they are not treated at an early stage, they may cause symptoms of compression, and cranial nerve dysfunction [3]. Carotid body tumors are generally benign tumors, however rarely malignant tumors can be seen. Most of them are nonfunctional, nevertheless occasionally they can be observed as tumors secreting histamine, serotonin, epinephrine, and norepinephrine. Surgical resection of the tumor is the most appropriate treatment approach [4]. Surgical resection requires experience because of the closeness of the tumor to cranial nerves, extracranial arterial structures, and complex anatomy of head and neck region.

For CBT surgery, general anesthesia is preferred. Fluctuations in blood pressure especially manipulation, and excision of the tumor require very careful monitorization by the anesthetist. Although CBTs are nonfunctional tumors, 1–3% of them possess hormonal activity [5]. This condition should be assessed during pre-anesthetic evaluation, and necessary precautions should be taken during operation. In tumors with vascular invasion, one should be prepared for the possibility of bleeding. If cross-clamping is required cerebral monitorization, and protection of cerebral perfusion are the most fundamental components of the anesthetic method.

The purpose of this study is to evaluate anesthetic approach, and reveal literature information.

MATERIALS AND METHODS

The data of 10 consecutive patients among 176 patients who underwent surgery for the management of carotid body tumor at Antalya Training and Research Hospital, Antalya, Turkey between 2013 and 2016 were retrospectively examined, and included in the analysis.

The patients who underwent throat surgery or carotid artery surgery for indications other than CBT, and those with missing file data were excluded from the study.

Patient data were retrieved by investigating patient files, and digital records.

Demographic data of the patients, their comorbidities, side, and duration of operation, hospital, and intensive care unit stays, intraoperative blood pressure, variations in heart rates, inotropic drug use, amounts of blood, and blood products used, and complications were recorded

Anesthetic management

All patients were operated under general anesthesia. For premedication 0.05 mg/kg midazolam was administered. The patients were brought into operating room, and underwent 3-channel electrocardiography, monitorization using pulse oximetry, and arterial monitorization via radial artery cannulation. Then anesthetic induction was applied.

Following routine anesthetic induction, contralateral unoperated subclavian vein was cannulated to monitor central venous pressure. Then appropriate colloid, and crystalloid infusions were performed so as to maintain central venous pressure, and mean arterial blood pressure at 8–10 mmHg, and 55–60 mmHg, respectively. Sudden drops in blood pressure were managed with 5 mg bolus doses of ephedrine. In patients whose adequate blood pressure levels could not be achieved despite adequate fluid infusion, and administration of ephedrine, inotropic support infusions were initiated.

Intraoperative cerebral monitorization was achieved using cerebral oxymetre (Masimo RD-S7A, Masimo Corp., Irvine, California, USA), and at the termination of the operation, the patients were extubated in the operating room. For the purpose of postoperative observation, the patients were brought into intensive care unit of cardiovascular surgery. When they had brought into intensive care unit of cardiovascular surgery, the patients were awake, and cooperated, and they could maintain their hemodynamic stability without the need for inotropic support. In addition absence of respiratory distress, and persistence of the blood gas analysis results within normal limits ($pO_2 > 70$ mmHg, and $pCO_2 < 50$ mmHg), and based on the criteria of VAS scores of ≤ 5 , they were discharged from the intensive care unit.

TABLE 1. Demographic data are indicated as mean±standard deviation, and numbers (percentages)

	n	%
Age (yrs) Mean±SD	53±14.1	
Gender		
Male	4	40
Female	6	60
ASA score		
ASA 1	2	20
ASA 2	4	40
ASA 3	4	40
Side of operation		
Right	7	70
Left	3	30
EF (%) Mean±SD	51±9.9	
Comorbidities		
Hypertension	5	50
Diabetes Mellitus	4	40
COPD	1	10
CAD	1	10
PAD	1	10

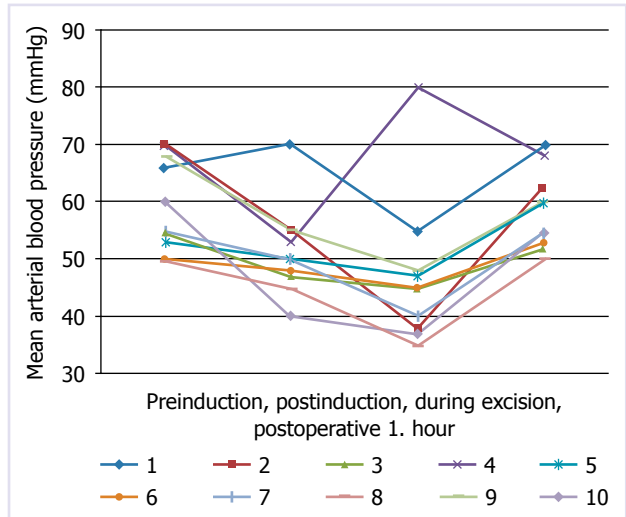
ASA: American Society of Anaesthesiologists; EF: Ejection fraction; COPD: Chronic obstructive pulmonary disease; CAD: Coronary artery disease; PAD: Peripheral artery disease; SD: Standard deviation.

Surgical technique

Through a parallel skin incision made on the sternocleidomastoid muscle, cervical region was explored. Following exploration of common carotid artery, and its branches, *n. vagus*, and *n. hypoglossus* were accessed, and protected. Dissection was started from the bifurcation of carotid artery, and advanced up to the upper edge of the tumor. In all patients, tumor, common carotid artery, and its branches were totally dissected. Major vascular injury or disruption of vascular integrity was not observed.

Statistical Analysis

SPSS version 21 Statistical Software (SPSS Inc., Chicago, IL, USA) program was used for the analysis of statistical data of the patients. All data were expressed as numbers, and percentages. The results were indicated as mean±standard deviation.

**FIGURE 1.** Mean arterial blood pressure measurement at different time intervals.

RESULTS

A total of 10 patients (male, $n=4$; 40%, and female, $n=6$; 60%) were operated at Antalya Training and Research Hospital with the diagnosis of CBT between the years 2013, and 2016. Seven of these patients applied with the complaints of painless neck mass, while the remaining 3 patients were discovered incidentally during cervical ultrasonograms obtained for various indications. Demographic data of the patients are shown in Table 1.

Right ($n=6$, 60%), and left ($n=4$; 40%) sided tumors were detected. Based on Shamblin classification, the patients were evaluated as type 1 ($n=3$; 30%), and type 2 ($n=7$, 70%). During tumor resection bleeding was observed on carotid bifurcation, and controlled with primary suturing. Mean tumor diameter was detected as 3.9 ± 1.6 cm. Cross-clamping was used in one patient, and intraluminal shunt was not employed in any patient.

Hypertension, and tachycardia developed in one patient during tumoral excision. In four patients hypotension, and bradycardia were observed during tumoral excision (Figure 1). Three patients of these 4 cases were treated with bolus doses of ephedrine. Since the remaining patient did not respond adequately to bolus doses of ephedrine, infusion of inotropic support was started. A significant difference

TABLE 2. Intra-, and post-operative data as expressed as mean±standard deviation or number (percentage)

Number (%) of patients who received bolus doses of ephedrine	4 (40%)
Number (%) of patients who were started on inotropic infusion support	1 (10%)
Mean amount of intraoperative blood loss, ml	287±68
Duration of surgery , min	109±20
Duration of anesthesia, min	124±18
Postoperative mean VAS score	4±1
Postoperative tramadol utilization, mg	80±25
Intensive care unit stay, hr	2.4±1.1
Hospital stay, day	3.8±0.7

VAS: Visual analogue scale

was not detected between preoperative, intraoperative, and postoperative peak heart rates.

Cerebral oximetry values estimated at five different timepoints (pre-induction baseline, postinduction, before, and after tumor excision, and at the termination of the operation) were compared. In none of the patients a drop of more than 25% did not occur relative to baseline values.

Mean intraoperative blood loss was 287±68 ml. One patient required blood transfusion because of abundant amounts of blood loss.

Mean total duration of surgery was 109±20 minutes. All patients were monitored in the intensive care unit during postoperative period.

Mean postoperative tramadol utilization was 80±25 mg. Mean VAS score at postoperative 0 (entrance into intensive care unit), and 1. hour was 4±1 points (Table 2).

During postoperative period permanent neurological damage, and mortality were not seen in none of the cases.

DISCUSSION

CBT is localized on superolateral regions of the throat, posteroinferior part of the corner of the lower jaw, and it can yield symptoms as solid, painless swelling increasingly growing within years

Occasionally, these tumors can be discovered incidentally. Their incidence rates have been reported between 0.06, and 3.3:100000, and they are seen more frequently in women when compared with men [6]. They can be seen at any age, however they are observed most frequently between 4. and 5. decades [7].

Cervical ultrasound is the first diagnostic tool to be applied. Computed tomography (CT), magnetic resonance (MR) imaging, and MR angiography yield information about the composition of the tumor, and the relationship between the tumor, and soft tissue, bone, and surrounding vasculature. Diagnostic accuracy, and sensitivity of computed tomographic angiography in the detection of carotid body tumors have been reported as 100 percent [8].

According to Shamblin classification, carotid body tumors are classified into 3 types based on the severity of internal carotid artery involvement [9]. In Type 1 carotid artery is minimally involved, and it is seen in 26% of the cases with CBT. This type of tumors can be easily removed. In Type 2, internal carotid artery is partially surrounded by the tumor. Its dissection is sometimes challenging, but generally it is easily extirpated. It is seen in 40% of the cases with CBT. However Type 3 is seen in 27% of the cases with CBT. It completely invades arterial structures, and so its dissection is not possible. In the treatment of these types, internal and/or external carotid arteries should be also removed. In our series, all patients were classified as Type 1, and Type 2. We didn't encounter any Type 3 patient.

Carotid body tumors has a tendency to accompany head and neck paragangliomas, malignant tumors of lungs, breast, and larynx, and they are bilateral or multiple. Therefore during preoperative evaluation the existence of other tumors should be carefully investigated.

When literature is reviewed, mostly preference for general anesthesia for CBT surgery is noted. However in some cases cited in the literature local, and regional anesthesia were applied. In a series consisting of 4 cases reported by Toktas et al. local anesthesia had been used, and any surgical complication was not seen [10]. In the literature a case

with CBT operated under cervical plexus block has been reported [11]. A patient who had been considered to have a higher risk for general anesthesia because of Eisenmenger syndrome had been operated under continuous cervical plexus block, and any complication had not been encountered. Cervical plexus block is a preferred anesthetic method for carotid artery surgery [12, 13]. However use of these methods for CBT surgery may harbor some contraindications. CBT is frequently localized on carotid bifurcation, and during regional applications, because of the hypervascularity of the tumor, unwanted punctures of the tumoral mass may be encountered. Because of risk of bleeding, needle or open biopsy is contraindicated in these tumors [14]. Since part from bleeding this condition may cause catecholamine release from the tumor, hemodynamic instability is a possibility. During application of nerve block, in order to refrain from perforation of the tumor with the needle, regional applications under ultrasound guidance may have higher procedural safety. In patients with CBT carrying higher risk for general anesthesia, preference for regional anesthesia will be more appropriate. Since we hadn't any patient with higher risk for general anesthesia, so as to refrain from complications of regional anesthesia, we preferred general anesthesia in all of our patients.

Knowing functional status of the tumor is important during preoperative evaluation for anesthetic technique. Presence of excessive catecholamine release should be investigated during preoperative period using urinary metanephrine, and vanillyl-mandelic acid measurements. During surgery for functional tumors, alpha-adrenergic blocker drugs should be at hand so as to prevent hypertensive episodes due to excessive catecholamine discharge [15]. Preoperative catecholamine levels of all of our patients were within normal limits.

Planning fluid therapy plays an important role in the maintenance of hemodynamic status. Therefore, central venous pressure should be monitored, and required resuscitation with fluid replacement should be readily available.

Invasive arterial monitorization, close follow-up of hemodynamic state is absolutely necessary for

maintenance of blood pressure during specific intervals, and blood gas analyses.

Because of the presence of potential ischemic areas, and already dilated vessels, normocapnic state should be preferred during anesthesia. Hypercapnia may result in dilation of vessels outside ischemic areas, and blood flows through these dilated vessels leading to "steal phenomenon", and worsened ischemic state. However hypocapnia further causes increases severity of vasoconstriction at ischemic areas [16].

Bleeding is one of the most important intraoperative complications. Especially during excision of the tumors which invaded carotid artery, substantial amount of blood loss can occur, and sudden hemodynamic changes can be observed. Based on Shamblin classification tumor types, CBTs of type II, and III have been found to be associated with greater amounts of blood loss, longer operation times, higher incidence of neuronal damage, more severe vascular injury, and frequent need for repair [17, 18]. Excessive blood loss during excision of the tumor, and potential complications can be predicted based on preoperative classification, and preparation of preoperative blood supply should be made accordingly. Blood loss requiring blood transfusion occurred in only one of our cases. This case was Type 2 CBT according to Shamblin classification. This bleeding occurring on the carotid bifurcation was stopped with primary suturing.

Especially in Shamblin Type 3 group where tumor invaded carotid artery, cross-clamping should be applied to preclude excessive bleeding during excision of the tumor. Especially in cases with stenosis of the contralateral carotid artery detected during clamping neurologic monitorization conveys importance. For the monitorization of neurologic status, electroencephalography [19], measurement of somatosensory evoked potentials [20], transcranial Doppler US [21], measurement of carotid stump pressure [22] and cerebral oxymetry [23] can be used. The superiority of one method over another has not been demonstrated exactly [24]. During clamping of the carotid artery, if stenosis of the contralateral carotid artery was detected, use of a shunt can be a proper alternative. During shunting, risk of

embolism or carotid artery dissection has been reported in 1–3% operated cases [25]. It has been revealed in many studies that during cross-clamping, maintenance of mean blood pressure values at nearly 20% higher levels higher than the baseline values has a protective effect on the preservation of cerebral perfusion [26]. Thus focal ischemia is avoided by ensuring optimal cerebral perfusion. It has been already known that barbiturates used during this period contribute to redistribution, and protect the tissues against focal ischemia [27]. Brain edema is associated with cytotoxic, and vasogenic edema, and it usually follows an ischemic process. Use of mannitol is useful in the reduction of this type of edema [28]. In our series we performed cerebral monitoring using cerebral oximeter in our patients. We applied cross-clamping in one of these patients because of intractable bleeding. We didn't use a shunt in this patient, while cross-clamping procedure lasted for 8 minutes, and bleeding was stopped using primary suturing. During postoperative period any neurological complication was not encountered in this patient.

Lack of any control group was the main limitation of this study which prevented comparison of data. Scarce number of patients was another limitation of the study. Studies performed with higher number of patients may further elaborate outcomes of this study

Conclusion

Surgery of carotid body tumors requires close monitorization, and complex anesthetic management. Cerebral monitorization, and preservation of cerebral perfusion are important issues especially during tumoral resection, and cross-clamping. During preoperative period, performing necessary preparations, being prepared for excess amounts of blood loss, and maintenance of optimal blood pressure levels against sudden hemodynamic changes are among the basic components of anesthetic management.

Conflict of Interest: None declared.

Financial Disclosure: The authors declared that this study has received no financial support.

REFERENCES

1. Del Guercio L, Narese D, Ferrara D, Butrico L, Padricelli A, Porcellini M. Carotid and vagal body paragangliomas. *Transl Med UniSa* 2013;6:11–5.
2. Obholzer RJ, Hornigold R, Connor S, Gleeson MJ. Classification and management of cervical paragangliomas. *Ann R Coll Surg Engl* 2011;93:596–602. [Crossref](#)
3. İlhan G, Bozok Ş, Özpak B, Güneş T, Gökalp O, Bayrak S, et al. Diagnosis and management of carotid body tumor: a report of seven cases. *Türk Göğüs Kalp Damar Cer Derg* 2013;21:194–200. [Crossref](#)
4. Mataracı İ, Rabuş MB, Kırallı K, Kıran B, Yanartaş M, Sunar H, et al. Diagnosis and surgical treatment of carotid body tumors. *Türk Göğüs Kalp Damar Cer Derg* 2008;16:86–90.
5. Offergeld C, Brase C, Yaremchuk S, Mader I, Rischke HC, Gläsker S, et al. Head and neck paragangliomas: clinical and molecular genetic classification. *Clinics (Sao Paulo)* 2012;67 Suppl 1:19–28. [Crossref](#)
6. Sajid MS, Hamilton G, Baker DM; Joint Vascular Research Group. A multicenter review of carotid body tumour management. *Eur J Vasc Endovasc Surg* 2007;34:127–30. [Crossref](#)
7. Georgiadis GS, Lazarides MK, Tsalkidis A, Argyropoulou P, Giatromanolaki A. Carotid body tumor in a 13-year-old child: Case report and review of the literature. *J Vasc Surg* 2008;47:874–880. [Crossref](#)
8. Jin ZQ, He W, Wu DF, Lin MY, Jiang HT. Color Doppler Ultrasound in Diagnosis and Assessment of Carotid Body Tumors: Comparison with Computed Tomography Angiography. *Ultrasound Med Biol* 2016;42:2106–13. [Crossref](#)
9. Shamblin WR, ReMine WH, Sheps SG, Harrison EG Jr. Carotid body tumor (chemodectoma). Clinicopathologic analysis of ninety cases. *Am J Surg* 1971;122:732–9. [Crossref](#)
10. Toktaş F, Yümün G, Gücü A, Göncü T, Eriş C, Çayır Ç, et al. Protective Surgical Procedures for Carotid Body Tumors: A Case Series. *Erciyes Med J* 2014;36:133–5. [Crossref](#)
11. Jones HG, Stoneham MD. Continuous cervical plexus block for carotid body tumour excision in a patient with Eisenmenger's syndrome. *Anaesthesia* 2006;61:1214–8. [Crossref](#)
12. Sait Kavaklı A, Kavrut Öztürk N, Umut Ayoğlu R, Sağdıç K, Çakmak G, İnanoğlu K, et al. Comparison of Combined (Deep and Superficial) and Intermediate Cervical Plexus Block by Use of Ultrasound Guidance for Carotid Endarterectomy. *J Cardiothorac Vasc Anesth* 2016;30:317–22. [Crossref](#)
13. Çoruh T, Yapıcı N, Yılmaz C, Çınar B, Maçika H, Abay G, et al. Karotis endarterektomisinde genel anestezi, servikal pleksus blokajı ve servikal epidural anestezi yöntemlerinin karşılaştırılması. *GKD Anest Yoğ Bak Dern Derg* 2000;6:30–4.
14. Köhler HF, Carvalho AL, Mattos Granja NV, Nishinari K, Kowalski LP. Surgical treatment of paragangliomas of the carotid bifurcation: results of 36 patients. *Head Neck* 2004;26:1058–63. [Crossref](#)
15. Hu K, Persky MS. Treatment of Head and Neck Paraganglio-

- mas. *Cancer Control* 2016;23:228–41.
16. Stoelting RK, Dierdorf SF. *Diseases of the nervous system, Anesthesia and Co-existing Disease*, 4th edition. Edited by Stoelting RK, Dierdorf SF. Philadelphia, Churchill Livingstone 2002. p. 233–2.
 17. Burnichon N, Brière JJ, Libé R, Vescovo L, Rivière J, Tissier F, et al. SDHA is a tumor suppressor gene causing paraganglioma. *Hum Mol Genet* 2010;19:3011–20. [Crossref](#)
 18. Luna-Ortiz K, Rascon-Ortiz M, Villavicencio-Valencia V, Herrera-Gomez A. Does Shamblin's classification predict post-operative morbidity in carotid body tumors? A proposal to modify Shamblin's classification. *Eur Arch Otorhinolaryngol* 2006;263:171–5. [Crossref](#)
 19. Guay J, Kopp S. Cerebral monitors versus regional anesthesia to detect cerebral ischemia in patients undergoing carotid endarterectomy: a meta-analysis. *Can J Anaesth* 2013;60:266–79.
 20. Malcharek MJ, Kulpok A, Deletis V, Ulkatan S, Sablotzki A, Hennig G, et al. Intraoperative multimodal evoked potential monitoring during carotid endarterectomy: a retrospective study of 264 patients. *Anesth Analg* 2015;120:1352–60. [Crossref](#)
 21. van der Schaaf IC, Horn J, Moll FL, Ackerstaff RG. Transcranial Doppler monitoring after carotid endarterectomy. *Ann Vasc Surg* 2005;19:19–24. [Crossref](#)
 22. Calligaro KD, Dougherty MJ. Correlation of carotid artery stump pressure and neurologic changes during 474 carotid endarterectomies performed in awake patients. *J Vasc Surg* 2005;42:684–9. [Crossref](#)
 23. Pedrini L, Magnoni F, Sensi L, Pisano E, Ballestrazzi MS, Cirelli MR, et al. Is Near-Infrared Spectroscopy a Reliable Method to Evaluate Clamping Ischemia during Carotid Surgery? *Stroke Res Treat* 2012;2012:156975.
 24. Li J, Shalabi A, Ji F, Meng L. Monitoring cerebral ischemia during carotid endarterectomy and stenting. *J Biomed Res* 2016;3:31.
 25. Whiten C, Gunning P. Carotid endarterectomy: intraoperative monitoring of cerebral perfusion. *Curr Anaesth Crit Care* 2009;20:42–5. [Crossref](#)
 26. Allian R, Marone LK, Meltzer J, Jeyabalam G. Carotid endarterectomy. *IntAnesthesiology Clin* 2005;43:15–38. [Crossref](#)
 27. McConkey, Kien ND. Cerebral protection with thiopentone during combined carotid endarterectomy and clipping of intraluminal aneurysm. *Anesthesia Intensive Care* 2007;30:219–22.