



## Case report

## Rho-Associated Kinase Inhibitor Eye Drops in challenging cataract surgery

Marco Antonini, Marco Coassin, Daniele Gaudenzi, Antonio Di Zazzo, MD\*

Ophthalmology, Campus Bio-Medico University, Rome, Italy

## ARTICLE INFO

## Keywords:

Fuchs' dystrophy  
Cataract surgery  
Rho inhibitor  
Corneal edema  
Transplantation

## ABSTRACT

**Purpose:** To report the impact of Rho-Associated Kinase Inhibitor Eye Drops in cases of cataract surgery performed in severe Fuchs' endothelial corneal dystrophy (FECD).

**Observations:** A patient affected by FECD stage II underwent femtosecond laser-assisted cataract surgery (FLACS), developed postsurgical corneal failure and was scheduled for endothelial keratoplasty. Compassionate treatment with Rho-Associated Kinase Inhibitor Eye Drops 4 times per day was started. A significant improvement in visual acuity and corneal failure was recorded. Thereafter, other two patients affected by FECD stage II were prophylactically treated with Rho-Associated Kinase Inhibitor Eye Drops 4 times per day for three months before FLACS with good visual and clinical outcome.

**Conclusions and Importance:** These cases expand upon the reported effects of rho-associated kinase inhibitor Ripasudil in the FECD, suggesting a role as adjuvant medical therapy in patients advised for intraocular surgery to improve endothelial function and reduce the risk of pseudophakic bullous keratopathy (PBK).

## 1. Introduction

Cataract surgery-related injuries cause severe reduction of endothelial cell density (ECD), estimated at 8.5% 1 year after the procedure.<sup>1</sup> This critical damage, particularly in the fragile elderly population, has led to several surgical precautions. New ocular viscoelastic devices (OVDs) and alternative intraoperative and postoperative techniques have been performed. Some authors also support the use of femtosecond laser-assisted procedure to minimize the endothelial cells' loss, although the real benefit is still controversial.<sup>2</sup> However, in addition to the daily surgical routine of healthy elderly patients, surgeons frequently have to face high-risk cataract surgery cases. Among these, patients affected by Fuchs' endothelial corneal dystrophy (FECD), who present reduced endothelial cell density and function, represent a wide population in which postoperative corneal failure can occur in 13% of patients, who subsequently have 70% risk of undergoing corneal transplantation.<sup>2</sup>

Although FECD medical treatment is still an unmet need in ophthalmology, in recent years a selective Rho-associated coiled coil-containing protein kinase (ROCK) inhibitor, Ripasudil, has shown promising results in supporting endothelial function in wound healing models<sup>3</sup> as well as in clinical settings in case of traumatic endothelial damage, such as transcorneal freezing<sup>4</sup> or descemetorhexis.<sup>5</sup>

We recently experienced a case of early FECD who developed pseudophakic bullous keratopathy (PBK) and was recommended for

Ripasudil eye drops, administered 4 times per day (hours 8.00, 13.00, 18.00 and 23.00 ± 30), as a compassionate treatment, while waiting for scheduled corneal surgery. After this case, we advised two patients affected by FECD to instill Rho-associated kinase inhibitor eye drops for 3 months before undergoing cataract surgery. Therefore, we aim to report how adjuvant treatment with Ripasudil can reduce the risk of corneal failure after cataract surgery in a challenging context, as well as delay the need for corneal surgery and improve the quality of life in patients waiting for scheduled corneal transplantation.

## 2. Case report 1

A male patient of 70 years came to our attention with decreased vision in right eye (OD). Best corrected visual acuity (BCVA) was 20/40 in the OD and 20/20 in the left eye (OS). His past medical history was unremarkable. Slit lamp examination demonstrated corneal endothelial coalescent guttae and NS3 grade cataract in OD. FECD stage II was diagnosed. In vivo confocal microscopy (IVCM ConfoScan4™, Nidek technologies, Gamagori, Japan) of central cornea showed a decrease in ECD (Fixed-Frame Cell Density<sup>6</sup> average OD 856 ± 106,4 cells/mm<sup>2</sup>, OS 1092,6 ± 175,9 cells/mm<sup>2</sup>), pleiomorphism and polymegathism with confluent guttae (Fig. 1 A and C).

Uneventful FLACS and IOL implantation were performed. At first post-operative day mild corneal edema was detected in OD (Fig. 2 A).

\* Corresponding author. Ophthalmology, Campus Bio-Medico University Hospital, Rome.

E-mail address: [a.dizazzo@unicampus.it](mailto:a.dizazzo@unicampus.it) (A. Di Zazzo).

<https://doi.org/10.1016/j.ajoc.2021.101245>

Received 6 March 2021; Received in revised form 2 September 2021; Accepted 13 December 2021

Available online 16 December 2021

2451-9936/© 2021 Published by Elsevier Inc. This is an open access article under the CC BY-NC-ND license (<http://creativecommons.org/licenses/by-nc-nd/4.0/>).

After 1 week, central epithelial bullae, stromal edema (thinnest point 611 $\mu$ m) and Descemet's folds were assessed. Therapeutic contact lens was applied and removed 6 weeks later. At 15th post-surgical week, BCVA of 20/20 in OD was measured and endothelial guttae with mild stromal edema (central corneal thickness (CCT) 564  $\mu$ m) in the inferior quadrants were reported (Fig. 2 B).

At 17th postsurgical week, the patient presented to our attention with a drop of BCVA to 20/32 and ocular pain, in association with inferior paracentral epithelial bullae, stromal edema and Descemet's folds (Fig. 2 C). Patient was advised for ultrathin-Descemet's stripping automated endothelial keratoplasty (ut-DSAEK) in OD. In the meanwhile, a compassionate therapy with Ripasudil eye drops 4 times per day in both eyes was started. The patient was informed about Ripasudil authorizations, limited to Japan, and indications. After 8 weeks of treatment, BCVA was improved to 20/20 and the central cornea was clear, with persistent endothelial guttae and low grade edema in inferior quadrants (Fig. 2 D). At week 40th the clinical situation was stable. IVCM of central cornea was performed demonstrating in OD no significant changes in ECD (Fixed-Frame Cell Density average OD 886,4  $\pm$  118,5 cells/mm<sup>2</sup>) (Fig. 1 B), but an improved area of localised hexagonal morphology and increased size EC. No significant changes in ECD were demonstrated in OS (Fixed-Frame Cell Density average OS 1043,2  $\pm$  121,8 cells/mm<sup>2</sup>) (Fig. 1 D).

### 3. Case report 2

A 65-year-old woman came to our attention with decreased visual acuity. BCVA was 20/40 in both eyes. Her past medical history was uneventful. Slit lamp examination demonstrated meibomian gland dysfunction, corneal endothelial coalescent guttae with corneal sub-edema and C2NS2 grade cataract. FECD stage II was diagnosed. IVCM of central cornea showed a decrease in ECD (Automated count average OD 2442 cells/mm<sup>2</sup>, OS 2118 cells/mm<sup>2</sup>), reduced pleomorphism (OD 35,4%, OS 41,9%) and increased polymegathism (OD 48%, OS 54,9%), with confluent guttae. Corneal Scheimpflug topography revealed subtle loss or regular isopachies, nasal displacement of thinnest point (CCT OD 546  $\mu$ m, OS 542  $\mu$ m) and early posterior surface focal depression. At this

time point the therapy with Rho-inhibitors eye drops 4 times per day in both eyes was started and 3 months later the patient underwent FLACS in OS and, after one week, in OD.

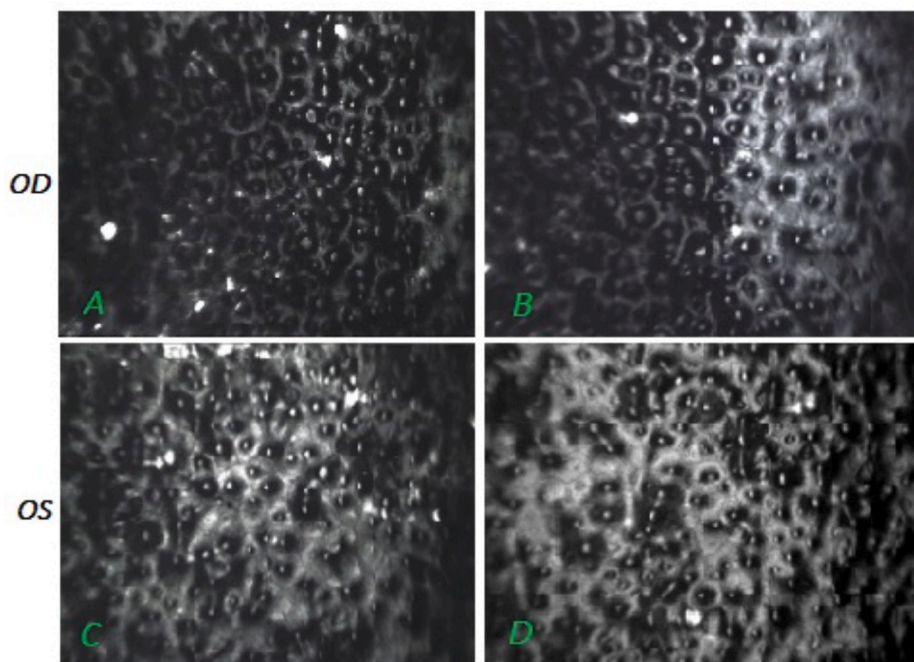
Surgery was uneventful and 1 month later the patient had UCVA 20/20 in both eyes without experiencing corneal decompensation. At slit lamp examination, confluent guttae were revealed but there were no signs of corneal edema. IVCM of central cornea was repeated, revealing unaltered ECD (automated count average OD 2643 cells/mm<sup>2</sup>, OS 2255 cells/mm<sup>2</sup>), pleiomorphism (OD 41,1%, OS 34,1%) and polymegathism (OD 43,3%, OS 51,9%), with decreased confluent guttae. Corneal topography was similar for isopachies and posterior surface depression, with CCT of 556  $\mu$ m in OD and of 554  $\mu$ m in OS.

### 3. Case report 3

A 77-year-old glaucoma patient presented with decreased visual acuity in both eyes. Presenting BCVA was 20/40 in OD and 20/63 in OS. At slit lamp examination, corneal endothelial coalescent guttae with corneal sub-edema were revealed. FECD stage II and cataracts were diagnosed in both eyes (C1NS3 grade in OD and C2NS2 grade in OS). Corneal topography revealed evident isopachies irregularity with superior nasal thinnest point displacement (CCT 591  $\mu$ m) and remarkable focal posterior surface depression. A combined procedure ut-DSAEK and FLACS was proposed, but the patient preferred to undergo only FLACS in OD. Ripasudil eye drops were prescribed 4 times per day for 3 months before surgery. At 1 week post-op, clinical examination showed central corneal stromal edema, which resolved within 1 week, achieving BCVA of 20/20 3 months after surgery. Pachymetry map, posterior elevation, nasal thinnest point position and CCT (612  $\mu$ m) were substantially unchanged.

### 4. Discussion

In FECD patient undergoing cataract surgery, treatment with Ripasudil has demonstrated a clinical role by minimizing signs of corneal failure and speeding up visual recovery, as well as improving the patient's postoperative symptoms, and, so, quality of life (Table 1).



**Fig. 1.** In vivo confocal microscopy of central cornea (IVCM ConfoScan4™, Nidek technologies, Gamagori, Japan). A: RE before surgery; B: RE after Ripasudil therapy, week 40; C: LE before surgery; D: LE after Ripasudil therapy, week 40.

In case 1, no clear changes in ECD but improvement of endothelial cells' shape and size at IVCN have been assessed. We highlighted that the qualitative improvement of corneal endothelial cell morphology was remarkable in the operated right eye compared to control fellow eye.

We believe that the corneal area which suffered major cellular distress, especially during the surgical procedure, may benefit most from Ripasudil supportive therapy. On the other hand, we did not notice improvement in fellow eye. This is consistent with findings of pilot studies that employed Rho-associated kinase inhibitors in various endothelial dysfunction with corneal edema after *trans*-corneal freezing.<sup>7</sup>

In case 2 the degree of corneal decompensation was lower based on the topographical and confocal assessment. Ripasudil has been prescribed as adjuvant therapy for 3 months before surgery, solving the preoperative corneal sub-edema within one month. Corneal topography showed unmodified isopachies and ECD count improvement in both eyes. The therapy was discontinued at 1 month follow-up and the results were stable in the following 3 months.

Patient 3 already had a severe corneal condition, but the disease did not progress significantly after surgery, although the postoperative edema took 2 weeks to fully resolve, without worsening into PBK.

To the best of our knowledge, case 1 is the first case of cataract surgery in FECD patient treated with Ripasudil. In addition to this, both the two eyes of case 2 and the treated eye of case 3 show promising results in an innovative concept of adjuvant protection for endothelial cells from surgical insults.

Rho/ROCK pathway is involved in regulating cytoskeleton, cell migration, proliferation and apoptosis<sup>8</sup> and Rho-Associated Kinase Inhibitors have proven, in animal model and in human case series, efficacy in promoting endothelial wound healing and corneal edema recovery after trauma.<sup>4,9</sup> Furthermore, topical administration of ripasudil demonstrated the ability to deactivate the inflammatory cascade and neovascularization in mouse models of grafted corneas. These effects are associated with a reduced expression of inflammation-related mRNA (Interferon (IFN) $\gamma$ , Tumor necrosis factor (TNF)- $\alpha$ , Interleukin (IL)1 $\beta$ , IL17, IL23, and IL33 mRNA were significantly downregulated) and with an increased level of the mRNA codifying for the immunoregulatory cytokine IL10.<sup>10</sup>

**Table 1**

Comparison between baseline and last visit data. F-Up: follow-up; BCVA: best corrected visual acuity; CCT: central corneal thickness; EC/mm<sup>2</sup>: endothelial cell/mm<sup>2</sup>.

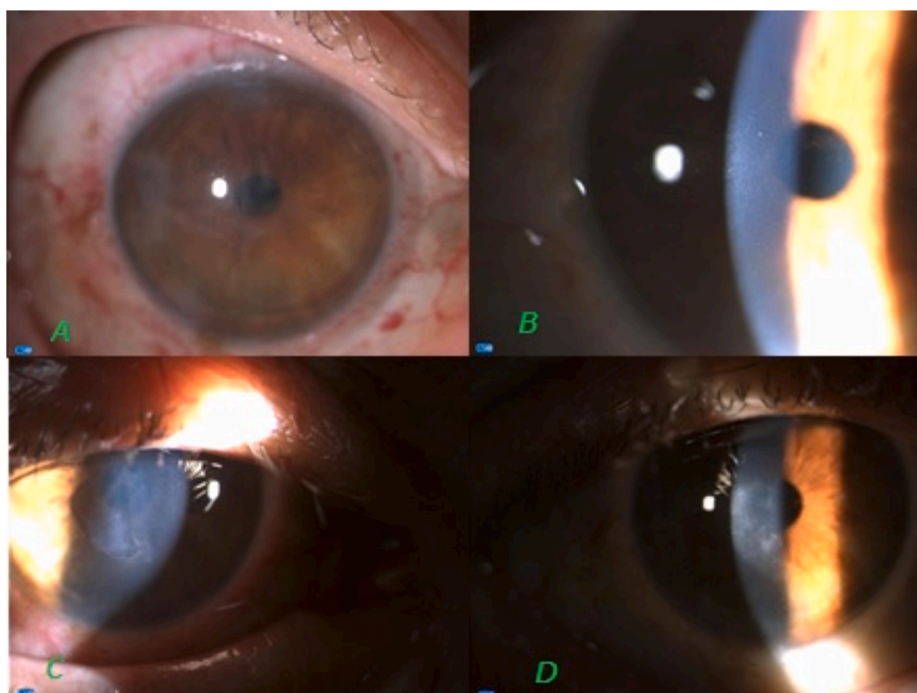
	CASE 1		CASE 2		CASE 3	
	Baseline	Last F-up	Baseline	Last F-up	Baseline	Last F-up
BCVA	20/40	20/20	20/40	20/20	20/40	20/20
CCT ( $\mu$ m)	559	572	546	556	591	612
EC/mm <sup>2</sup>	856	886,4	2442	2643	569	560

However, in case 1, by prescribing Ripasudil after surgery, the corneal edema was almost completely solved, but the usual PBK sequelae, such as sub-epithelial fibrosis, could not be avoided furtherly. Since a slowly recover and regression of fibrosis has been proven after corneal endothelial lamellar surgery,<sup>11</sup> ut-DSAEK has been performed to maximize visual outcomes in such patient. Case 2 and 3 were both at high risk of disease progression after cataract surgery according to corneal pachymetry and IVCN assessments.<sup>6</sup> Ripasudil was prescribed as adjuvant therapy 3 months before surgery and 1 month after, and we did not find any sign of disease progression at 3 months post-surgery.

Rho-Associated Kinase Inhibitor Eye Drops (Ripasudil) can be a temporary adjuvant treatment useful for delaying and preventing signs of corneal failure after cataract surgery in challenging cases, or for improving symptoms and quality of life for patients awaiting subsequent corneal surgery.

**5. Conclusions**

Our report is a significant addendum to Ripasudil benefits in FECD patients. We strongly support that Rho-associated kinase inhibitors should be considered as adjuvant therapy in cataract surgery performed in challenging contest such as Fuchs' endothelial dystrophy, delaying the disease progression to corneal failure and improving symptoms for patients waiting for subsequent corneal surgery.



**Fig. 2.** Slit lamp images of right eye. A: RE day 1 after surgery; B: RE week 15; C: RE week 17; D: RE week 35.

**Patient consent**

The patients consented to publication of the case in writing.

**Funding**

No funding or grant support.

**Authorship**

All authors attest that they meet the current ICMJE criteria for Authorship.

**Declaration of competing interest**

The following authors have no financial disclosures: M.A., M.C., D. G., A.D.Z.

**Acknowledgments**

None.

**References**

1. Bourne RRA, Minassian DC, Dart JKG, Rosen P, Kaushal S, Wingate N. Effect of cataract surgery on the corneal endothelium: modern phacoemulsification compared with extracapsular cataract surgery. *Ophthalmol*. 2004;111(4):679–685. <https://doi.org/10.1016/j.ophtha.2003.07.015>.
2. Zhu DC, Shah P, Feuer WJ, Shi W, Koo EH. Outcomes of conventional phacoemulsification versus femtosecond laser–assisted cataract surgery in eyes with Fuchs endothelial corneal dystrophy. *J Cataract Refract Surg*. 2018;44(5):534–540. <https://doi.org/10.1016/j.jcrs.2018.03.023>.
3. Okumura N, Okazaki Y, Inoue R, et al. Effect of the rho-associated kinase inhibitor eye drop (ripasudil) on corneal endothelial wound healing. *Invest Ophthalmol Vis Sci*. 2016;57(3):1284–1292. <https://doi.org/10.1167/iovs.15-18586>.
4. Koizumi N, Okumura N, Ueno M, Nakagawa H, Hamuro J, Kinoshita S. Rho-associated kinase inhibitor eye drop treatment as a possible medical treatment for fuchs corneal dystrophy. *Cornea*. 2013;32(8):1167–1170. <https://doi.org/10.1097/ICO.0b013e318285475d>.
5. Moloney G, Petsoglou C, Ball M, et al. Descemetorhexis without grafting for fuchs endothelial dystrophy-supplementation with topical ripasudil. *Cornea*. 2017;36(6):642–648. <https://doi.org/10.1097/ICO.0000000000001209>.
6. McLaren JW, Bachman LA, Kane KM, Patel SV. Objective assessment of the corneal endothelium in Fuchs' endothelial dystrophy. *Investig Ophthalmol Vis Sci*. 2014;55(2):1184–1190. <https://doi.org/10.1167/iovs.13-13041>.
7. Koizumi N, Okumura N, Ueno M, Kinoshita S. New therapeutic modality for corneal endothelial disease using Rho-associated kinase inhibitor eye drops. *Cornea*. 2014;33(11):S25–S31. <https://doi.org/10.1097/ICO.0000000000000240>.
8. Olson MF, Ashworth A, Hall A. An essential role for Rho, Rac, and Cdc42 GTPases in cell cycle progression through G1. *Science*. 1995;269(5228):1270–1272. <https://doi.org/10.1126/science.7652575>, 80.
9. Okumura N, Koizumi N, Kay EP, et al. The ROCK inhibitor eye drop accelerates corneal endothelium wound healing. *Invest Ophthalmol Vis Sci*. 2013;54(4):2493–2502. <https://doi.org/10.1167/iovs.12-11320>.
10. Inomata T, Fujimoto K, Okumura Y, et al. Novel immunotherapeutic effects of topically administered ripasudil (K-115) on corneal allograft survival. *Sci Rep*. 2020;10(1):1–11. <https://doi.org/10.1038/s41598-020-76882-w>.
11. Zola M, Kim J, Petrelli M, Schmutz L, Hashemi K, Kymionis G. Resolution of corneal fibrosis after Descemet's stripping automated endothelial keratoplasty: a case report. *Ophthalmol Ther*. 2020;9(2):349–354. <https://doi.org/10.1007/s40123-020-00244-y>.