



# Risk factors of renal trauma in children with severe Henoch-Schonlein purpura and effect of mycophenolate mofetil on pediatric renal function

Minhui Li<sup>1</sup>, Binbin Guo<sup>2</sup>, Xue Wang<sup>3</sup>, Yingying Zhang<sup>3</sup>

<sup>1</sup>Department of Pediatrics Internal Medicine, Dongying Municipal Children's Hospital, Dongying, China; <sup>2</sup>Department of Nephrology, Shengli Oilfield Central Hospital, Dongying, China; <sup>3</sup>Department of Pediatrics Internal Medicine Shengli Oilfield Central Hospital, Dongying, China

*Contributions:* (I) Conception and design: All authors; (II) Administrative support: All authors; (III) Provision of study materials or patients: All authors; (IV) Collection and assembly of data: All authors; (V) Data analysis and interpretation: All authors; (VI) Manuscript writing: All authors; (VII) Final approval of manuscript: All authors.

*Correspondence to:* Yingying Zhang, Department of Pediatrics Internal Medicine Shengli Oilfield Central Hospital, 31 Jinan Road, Dongying District, Dongying 257034, China. Email: taodao46945293832@163.com.

**Background:** Renal trauma (RT) is a common feature in children with severe Henoch-Schonlein purpura (HSP), which can elevate the chance of recurrence and trigger end-stage renal disease. The risk factors of RT in children with HSP were explored and research was conducted on relevant treatment methods.

**Methods:** A total of 120 child patients with severe HSP admitted to our hospital from January 2019 to January 2020 were selected as the research cohort, and divided into a RT group (n=45) and RT-free group (n=75) according to their condition to analyze the risk factors inducing RT in pediatric patients, and mycophenolate mofetil therapy was given to both participant groups to compare their renal function indicators, immune function indicators, and adverse reaction rates (ARR) after treatment.

**Results:** Recurrent rash, adenovirus infection, respiratory virus infection, D-dimer level, leukocyte level, urinary albumin (UA) level, and platelet level were the risk factors of RT affecting severe HSP child patients. After treatment, the renal function indicators and immune indicators of participants in both groups were significantly better than those before treatment ( $P < 0.05$ ), and these indicators of the RT-free group were significantly better than the RT group after treatment ( $P < 0.05$ ). All participants did not experience serious adverse reactions, and no significant difference was presented when comparing the ARR between the 2 groups ( $P > 0.05$ ).

**Conclusions:** Recurrent rash, adenovirus infection, respiratory virus infection, D-dimer level, leukocyte level, UA level, and platelet level are the risk factors of RT affecting children with severe HSP, and mycophenolate mofetil can improve the renal function in pediatric patients and enhance their immunity, and is thus worthy of promotion in practice.

**Keywords:** Henoch-Schonlein purpura (HSP); renal trauma (RT); mycophenolate mofetil; renal function

Submitted Aug 30, 2021. Accepted for publication Nov 26, 2021.

doi: 10.21037/tp-21-493

View this article at: <https://dx.doi.org/10.21037/tp-21-493>

## Introduction

Severe Henoch-Schonlein purpura (HSP) is a common pediatric condition, which usually involves multiple organs and leads to various degrees of purpura, abdominal pain, joint damage and other symptoms in affected

children. Renal trauma (RT) is one of the most prevalent complications in severe HSP patients, and 8% of child patients with this complication will develop renal failure, which seriously affects their long-term prognosis (1-3). Currently, clinical studies have explored the risk factors

**Table 1** Comparison of participant general information

Group	N	Gender		Mean age (years)	Mean body weight (kg)	Pathological type				
		Male	Female			Simple	Joint	Mixed	Renal	Abdominal
RT group	45	30	15	8.12±1.21	18.21±6.51	15	10	10	2	8
RT-free group	75	40	35	8.22±1.23	18.54±6.52	20	18	12	10	15
<i>t/χ<sup>2</sup></i>			2.057	0.434	0.269	0.605	0.050	0.727	2.469	0.090
P value			0.151	0.665	0.789	0.437	0.824	0.394	0.116	0.765

RT, renal trauma.

of RT affecting children with HSP, and most literature has confirmed that D-dimer level and platelet level are the risk factors affecting the prognosis of children (4-6). However, there is no report on the classification of the risk factors in HSP children with RT and children without RT. Mycophenolate mofetil, which is often used in the treatment of platelet destruction and abnormal D-dimer levels, can alleviate D-dimer levels in affected children and at the same time improve their immune function, thereby normalizing leukocyte secretion. Previous studies have applied mycophenolate mofetil to the treatment of HSP children; however, the researches did not differentiate children with RT from those free of RT. Practice has shown that mycophenolate mofetil can trigger adverse reactions, and Bukulmez *et al.* have claimed that the adverse reactions are closely related to the application dose (7). Therefore children can be classified with or without RT, and low-dose mycophenolate mofetil can be applied to children without renal trauma to reduce the incidence of adverse reactions. Based on this, to further explore the risk factors of RT affecting children with severe HSP and the effect of mycophenolate mofetil on pediatric patients' renal function, 120 children with severe HSP admitted to our hospital from January 2019 to January 2020 were selected for the study, with the results summarized as follows. We present the following article in accordance with the STROBE reporting checklist (available at <https://dx.doi.org/10.21037/tp-21-493>).

## Methods

### General information

A total of 120 severe HSP children admitted to our hospital from January 2019 to January 2020 were selected as the research cohort and divided into the RT group (n=45) and RT-free group (n=75) according to their condition, with

no statistical differences presenting in comparison of their general information ( $P>0.05$ ), see *Table 1*. All procedures performed in this study involving human participants were in accordance with the Declaration of Helsinki (as revised in 2013) (8). The study was approved by ethics committee of Shengli Oilfield Central Hospital (approval No. 20181172) and individual consent for this retrospective analysis was waived.

### Inclusion criteria

The inclusion criteria of the study were as follows: (I) the child or their family members fully understood the study process and signed the informed consent; (II) the child was diagnosed with severe HSP for the first time (9); (III) the child presented clinical symptoms such as purpura of lower limbs and abdominal pain (10,11); and (IV) the child had stable vital signs.

### Exclusion criteria

The exclusion criteria for participation in the study were as follows: (I) presence of mental problems or inability to communicate with others; (II) comorbidity of other organic diseases; (III) use of anticoagulants within 1 month before the study; (IV) presence of congenital immune diseases, or diseases such as coagulation disorders (12-15); and (V) recent administration of drugs that may cause renal function damage.

### Study methods

#### Risk factor investigation

The basic information of the participants, including their age, gender, and symptoms, was recorded in the epidemiological investigation, during which their family

members were informed of the meaning of professional terms, so as to ensure that they understood and gave relevant answers. On the day of admission, venous blood was drawn from the participants, routine blood, urine, feces tests, immunology examination, hepatic and renal function tests, and so on were conducted, and the test results were recorded.

### Treatments

All participants accepted the conventional anti-coagulation and anti-infection treatment, and orally took the mycophenolate mofetil tablets (manufactured: Hangzhou Zhongmei Huadong Pharmaceutical Co., Ltd., Hangzhou, China; NMPA approval No. H20052083) on this basis. The clinical application dosage of the tablets was 20–35 mg/(kg·d). Considering the young age of the included children, the lowest dose was selected for children without RT, and 25 mg/(kg·d) was for children with renal trauma to reduce the incidence of adverse reactions. Therefore, the dosages for the RT-free group and RT group were 20 and 25 mg/kg/d, respectively, which were taken in 2 split doses every day for 10 months.

### Diagnostic criteria

HSP diagnostic criteria. Children were diagnosed with HSP if they had skin purpura without thrombocytopenia or coagulation dysfunction, accompanied by at least one of the following items: (I) diffuse abdominal pain; (II) arthritis or joint pain; (III) IgA-based immune complex deposition in tissue biopsy.

RT diagnostic criteria: (I) low fever, sore throat and fatigue in 1–3 weeks before onset; (II) typical skin purpura mainly in the limbs, possibly accompanied by abdominal pain, joint pain, joint swelling and other extrarenal manifestations; (III) renal damage, such as hematuria, proteinuria, hypertension and renal insufficiency; and (IV) IgA-based immunoglobulin deposition in the mesangial area in renal biopsy, and hyperplasia of mesangial cells and matrix.

### Observation criteria

- (I) Single factor analysis on RT affecting severe HSP children was conducted.
- (II) Logistic regression analysis was performed to identify the high risk factors from the result of single factor analysis on RT affecting severe HSP children (16).
- (III) The effect of mycophenolate mofetil on renal function

in children was explored. The fasting peripheral venous blood was extracted in the morning, and an automatic hematology analyzer (Germany imported automatic hematology analyzer Coatron 1800 with original reagents, NMPA Certified No. 20132402724) was used to determine the serum creatinine, urine nitrogen, D-dimer, and  $\beta$ 2-MG levels (17).

- (IV) The immune indexes of the two groups were compared. The fasting peripheral venous blood was extracted in the morning, and a double-diameter immunoturbidimetric analyzer (American Beckman GEM3000 with original reagents, NMPA Certified No. 20082401894) was adopted to determine the complement C3, complement C4, and immunoglobulin A (IgA) levels.
- (V) The adverse reaction rates (ARR) of participants were compared between the 2 groups, and the adverse reactions included gastrointestinal reaction, low leucocyte amount, elevated transaminase, and hepatic dysfunction.

### Statistical processing

In this study, the data processing software SPSS 20.0 (IBM Corp., Chicago, IL, USA), and the illustration software GraphPad Prism 7 (GraphPad Software, San Diego, CA, USA) were used. The grouping was performed by random sampling method, and the missing values of the patients were deleted from total samples. Items included were enumeration data and measurement data, methods used were chi-squared ( $\chi^2$ ) test and *t*-test, and differences were considered statistically significant at  $P < 0.05$ . Logistic regression analysis was adopted for the abnormal factors (high risk factors with  $P < 0.05$ ) in the result of single factor analysis on RT affecting severe HSP children.

## Results

### Single factor analysis on RT affecting severe HSP participants

The univariate analysis showed that recurrent rash, adenovirus infection, respiratory virus infection, D-dimer level, interleukin-6 (IL-6) level, interleukin-10 (IL-10) level, leukocyte level, high density lipoprotein (HDL) level, urinary albumin (UA) level, fasting blood glucose level, coagulation index, and platelet level were the risk factors of RT affecting severe HSP participants (Tables 2,3).

**Table 2** Analysis on enumeration data of RT affecting severe HSP participants

Risk factors	RT group (n=45)	RT-free group (n=75)	$\chi^2$	P value
Gender			0.000	1.000
Male	30	50		
Female	15	25		
Age			0.640	0.424
$\geq 10$ years old	28	52		
<10 years old	17	23		
Abdominal pain			0.000	1.000
Yes	12	20		
No	33	55		
Joint swelling and pain			0.114	0.735
Yes	38	65		
No	7	10		
Recurrent rash			5.184	0.023
Yes	42	58		
No	3	17		
Alimentary tract hemorrhage			0.056	0.813
Yes	20	35		
No	25	40		
Respiratory virus infection				
Syncytial virus infection	5	10	0.127	0.722
Adenovirus infection	17	12	7.279	0.007
Influenza virus infection	13	13	2.213	0.137
No infection	10	40	11.200	0.001

RT, renal trauma; HSP, Henoch-Schonlein purpura.

### ***Multivariate logistic regression analysis on RT affecting severe HSP participants***

After logistic regression analysis, it was confirmed that recurrent rash, adenovirus infection, D-dimer level, leukocyte level, UA level, and platelet level were the risk factors of RT affecting severe HSP children (Table 4).

### ***Research on effect of mycophenolate mofetil on participants' renal function***

After treatment, the renal function indicators of children in both groups were significantly better than before ( $P < 0.05$ ),

and the renal function indicators of the RT-free group were significantly better than those of the RT group ( $P < 0.05$ ) (Table 5).

### ***Comparison of participants' immune indicators between the 2 groups***

After treatment, the immune indicators in participants of both groups were significantly better than before ( $P < 0.05$ ), and the immune indicators of the RT-free group were significantly better than those of the RT group ( $P < 0.05$ ) (Table 6).

**Table 3** Analysis on measurement data of RT affecting severe HSP child patients ( $\bar{x}\pm s$ )

Risk factors	RT group (n=45)	RT-free group (n=75)	t	P value
D-dimer (mg/L)	4.51±1.23	3.35±0.98	5.696	<0.001
IL-1 $\beta$ (ng/L)	64.21±5.23	62.69±5.24	1.539	0.126
IL-6 (ng/L)	55.62±5.14	53.59±4.98	2.136	0.035
IL-10 (ng/L)	58.98±3.68	56.14±3.54	4.192	<0.001
Leucocyte ( $\times 10^9/L$ )	7.14±2.15	15.89±4.25	12.845	<0.001
LDL (mmol/L)	3.42±0.35	3.35±0.32	1.120	0.265
HDL (mmol/L)	2.12±0.36	1.98±0.25	2.510	0.013
UA (mg/L)	50.65±10.11	21.56±10.58	14.824	<0.001
Fasting blood glucose (mmol/L)	4.15±1.21	3.41±1.00	3.623	<0.001
Coagulation index	2.56±0.21	1.45±0.25	24.956	<0.001
Platelet ( $\times 10^9/L$ )	356.65±29.98	275.65±30.55	14.159	<0.001

RT, renal trauma; HSP, Henoch-Schonlein purpura; IL-1 $\beta$ , interleukin-1 $\beta$ ; IL-6, interleukin-6; IL-10, interleukin-10; LDL, low density lipoprotein; HDL, high density lipoprotein; UA, urinary albumin.

**Table 4** Multivariate logistic regression analysis on RT affecting severe HSP children

Indicators	B	Wald value	P value	OR	95% CI
Recurrent rash	1.655	20.541	<0.001	2.587	1.956–5.121
Adenovirus infection	1.215	14.567	<0.001	2.951	1.564–5.651
Respiratory virus infection	1.752	22.065	<0.001	2.657	1.258–9.124
D-dimer level	1.424	15.658	0.002	4.514	1.904–12.711
IL-6 level	-1.147	63.265	0.142	0.351	0.257–4.823
IL-10 level	-0.256	60.256	0.122	0.354	0.354–3.568
Leukocyte level	1.435	17.265	<0.001	3.981	2.117–7.295
HDL level	-1.215	65.125	0.152	0.541	0.144–3.688
UA level	1.215	14.567	<0.001	2.951	1.564–5.651
Fasting blood glucose level	-1.124	71.759	0.125	0.326	0.145–2.657
Coagulation index	0.424	2.581	0.112	1.512	0.904–2.711
Platelet level	1.158	15.685	<0.001	2.357	1.357–4.521

RT, renal trauma; HSP, Henoch-Schonlein purpura; OR, odds ratio; CI, confidence interval; IL-6, interleukin-6; IL-10, interleukin-10; HDL, high density lipoprotein; UA, urinary albumin.

### Comparison of ARR between the 2 groups

No severe adverse reactions were reported among all participants, and no statistical difference was presented when comparing the ARR between the 2 groups ( $P>0.05$ ) (Figure 1).

A total of 3 participants in RT group and 1 participant

in RT-free group had gastrointestinal reaction ( $\chi^2=2.483$ ,  $P=0.115$ ); 1 patient in the RT group and 1 participant in RT-free group had low leucocyte level ( $\chi^2=0.136$ ,  $P=0.713$ ); 2 participants in RT group and 1 participant in RT-free group with elevated transaminase ( $\chi^2=1.117$ ,  $P=0.291$ ); and 3 participants in RT group and 1 participant in RT-free group had hepatic dysfunction ( $\chi^2=2.483$ ,  $P=0.115$ ).

**Table 5** Research on effect of mycophenolate mofetil on participants' renal function before and after treatment ( $\bar{x}\pm s$ )

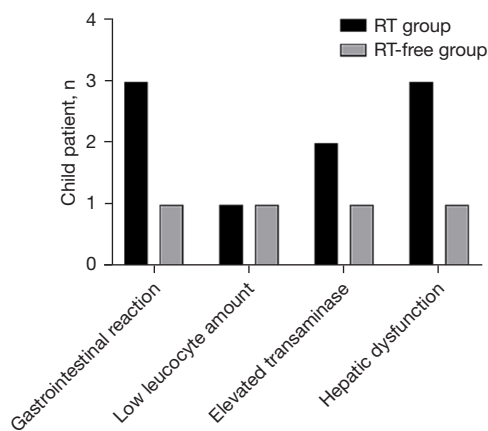
Group	Serum creatinine ( $\mu\text{mol/L}$ )		Urine nitrogen ( $\text{mmol/L}$ )		D-dimer ( $\text{mg/L}$ )		$\beta_2$ -MG ( $\text{mg/L}$ )	
	Before	After	Before	After	Before	After	Before	After
RT group	105.65 $\pm$ 12.65	86.11 $\pm$ 7.98*	5.56 $\pm$ 0.65	4.59 $\pm$ 1.22*	5.20 $\pm$ 1.11	3.45 $\pm$ 0.58*	0.98 $\pm$ 0.11	0.45 $\pm$ 0.09*
RT-free group	92.65 $\pm$ 10.68	68.98 $\pm$ 6.88*	5.19 $\pm$ 0.11	4.10 $\pm$ 0.68*	4.65 $\pm$ 0.98	2.98 $\pm$ 0.44*	0.75 $\pm$ 0.10	0.32 $\pm$ 0.12*
<i>t</i>	6.109	12.428	4.829	2.827	2.831	5.017	11.746	6.280
P value	<0.001	<0.001	<0.001	0.006	0.006	<0.001	<0.001	<0.001

\*, indicated  $P < 0.05$  compared with the indicator before treatment in same group. RT, renal trauma.

**Table 6** Comparison of participants' immune indicators before and after treatment ( $\bar{x}\pm s$ )

Group	Complement C3 ( $\text{g/L}$ )		Complement C4 ( $\text{g/L}$ )		IgA ( $\text{mg/L}$ )	
	Before	After	Before	After	Before	After
RT group	1.68 $\pm$ 0.32	1.32 $\pm$ 0.11*	0.15 $\pm$ 0.05	0.32 $\pm$ 0.08*	2.10 $\pm$ 0.87	1.51 $\pm$ 0.54*
RT-free group	1.50 $\pm$ 0.22	1.23 $\pm$ 0.10*	0.17 $\pm$ 0.06	0.40 $\pm$ 0.08*	1.89 $\pm$ 0.85	1.32 $\pm$ 0.35*
<i>t</i>	3.646	4.596	1.878	5.303	1.299	2.339
P value	<0.001	<0.001	0.063	<0.001	0.197	0.021

\*, indicated  $P < 0.05$  compared with the indicator before treatment in same group. IgA, immunoglobulin A.



**Figure 1** Between-group comparison of ARR. The horizontal axis from left to right indicates gastrointestinal reaction, low leucocyte amount, elevated transaminase, and hepatic dysfunction, and the vertical axis indicates participants (n); the black areas indicate the RT group, and the gray areas indicate the RT-free group. ARR, adverse reaction rate; RT, renal trauma.

### Discussion

The possibility of HSP complicated by RT is more than 60%, and this complication is an independent factor affecting the prognosis of children with severe HSP (18-20). At present, many studies have confirmed that recurrent rash and platelet levels are closely related to HSP complicated with RT. The recurrent rash implies the occurrence of allergic vasculitis, which can further induce glomerular inflammatory lesions that lead to RT in HSP children, and platelets accelerate the rate of immune complex deposition, so it is closely related to glomerular diseases. This study showed that the platelet level in HSP children with RT was significantly higher than in those without RT ( $P < 0.001$ ), demonstrating that under the condition of immune dysfunction, more platelets would be released from the bone marrow to maintain the amount inside the body, causing steep rise in platelet count (21-23). HSP is a disease of immune system, and its occurrence and development

are closely related to immune system disorders. In the late period of HSP, the immune factor consumption in affected children decreases, at which point platelets show a downward trend, and therefore the changes in platelet level should be observed in combination with the child's condition.

Apart from the above factors, adenovirus infection, respiratory virus infection, D-dimer level, leukocyte level, and UA level were also confirmed as risk factors of RT affecting severe HSP children via logistic regression analysis. Among them, adenovirus infection, a respiratory virus infection, was listed separately because its indicators reached the range of statistical difference. Respiratory infections are capable of uninterrupted stimulation of the immune system in children, aggravating their immune imbalance, and then causing corresponding damage to the renal basement membrane and consequent renal damage. Measurement of D-dimer is often used to detect thrombosis, and the increased presence of this substance indicates elevated blood viscosity in children and the massive accumulation of inflammatory factors at the kidney site, leading to exacerbated renal injury (24). The study results showed that pediatric participants who took mycophenolate mofetil had better IgA indicators and lower D-dimer level levels, and the positive correlation between the 2 could reflect the pathological course, namely, both the improved immune function and decreased D-dimer level could reduce RT in children, so mycophenolate mofetil could optimize their prognosis.

In the study conducted by Nikibakhsh *et al.*, the UA level was used as an indicator to evaluate the prognosis of children because the substance could not pass through the glomerular membrane but would be absorbed by the renal tubule after RT with elevated albumin filtration level, indicating that renal injury in children could be predicted by UA level (25). This study also identified UA as a risk factor for childhood kidney injury. After immune disorders occur, the leukocyte level in children will be significantly reduced, which may be related to many factors and cannot be used alone to predict renal injury in children, so complements C3 and C4, respectively reflecting renal diseases such as nephritis and immune diseases, were selected in this study as immune response indicators, with reduced C4 indicating aggravated RT in children. The study results showed that children with RT had poorer immunity than those without RT, and so did their recovery of renal function, but the effect of mycophenolate mofetil was significant. In addition, there were no serious adverse reactions noted

among all participants, indicating that the application of mycophenolate mofetil had higher safety.

In conclusion, recurrent rash, adenovirus infection, respiratory virus infection, D-dimer level, leukocyte level, and UA level are the risk factors of RT affecting severe HSP child patients, and mycophenolate mofetil can improve the renal function in children with HSP and enhance their immunity, which should be promoted in practice.

## Acknowledgments

*Funding:* None.

## Footnote

*Reporting Checklist:* The authors have completed the STROBE reporting checklist (available at <https://dx.doi.org/10.21037/tp-21-493>).

*Data Sharing Statement:* Available at <https://dx.doi.org/10.21037/tp-21-493>

*Conflicts of Interest:* All authors have completed the ICMJE uniform disclosure form (available at <https://dx.doi.org/10.21037/tp-21-493>). The authors have no conflicts of interest to declare.

*Ethical Statement:* The authors are accountable for all aspects of the work in ensuring that questions related to the accuracy or integrity of any part of the work are appropriately investigated and resolved. All procedures performed in this study involving human participants were in accordance with the Declaration of Helsinki (as revised in 2013). The study was approved by ethics committee of Shengli Oilfield Central Hospital (approval No. 20181172) and individual consent for this retrospective analysis was waived.

*Open Access Statement:* This is an Open Access article distributed in accordance with the Creative Commons Attribution-NonCommercial-NoDerivs 4.0 International License (CC BY-NC-ND 4.0), which permits the non-commercial replication and distribution of the article with the strict proviso that no changes or edits are made and the original work is properly cited (including links to both the formal publication through the relevant DOI and the license). See: <https://creativecommons.org/licenses/by-nc-nd/4.0/>.

## References

- Hasanzadeh S, Alavi SM, Masnavi E, et al. Case Report: Polyarteritis nodosa or complicated Henoch-Schönlein purpura (IgAV), a rare case. *F1000Res* 2018;7:49.
- Roman C, Dima B, Muyschont L, et al. Indications and efficiency of dapsone in IgA vasculitis (Henoch-Schönlein purpura): case series and a review of the literature. *Eur J Pediatr* 2019;178:1275-81.
- Cho SM, Di Lorenzo R, Myles JL, et al. Severe hyperhomocysteinemia manifesting as moyamoya vasculopathy and Henoch-Schönlein purpura. *Neurology* 2018;91:321-3.
- Gaillard N, Arquizan C. Reader response: Severe hyperhomocysteinemia manifesting as moyamoya vasculopathy and Henoch-Schönlein purpura. *Neurology* 2019;92:1119-20.
- Cho SM, Di Lorenzo R, Myles JL, et al. Author response: Severe hyperhomocysteinemia manifesting as moyamoya vasculopathy and Henoch-Schönlein purpura. *Neurology* 2019;92:1120.
- Côté JM, Meunier RS, Tremblay JA, et al. Henoch-Schönlein purpura in pregnancy: A case report. *Obstet Med* 2018;11:195-7.
- Bukulmez A, Dursun E, Ofu AT, et al. Henoch-Schönlein Purpura in childhood: a tertiary care hospital experience in Turkey. *Int J Contemp Pediatrics* 2018;5:686-9.
- World Medical Association. World Medical Association Declaration of Helsinki: ethical principles for medical research involving human subjects. *JAMA* 2013;310:2191-4.
- Buscatti IM, Casella BB, Aikawa NE, et al. Henoch-Schönlein purpura nephritis: initial risk factors and outcomes in a Latin American tertiary center. *Clin Rheumatol* 2018;37:1319-24.
- Weissman AS, Patel VS, Mushfiq O. Case of Gut Necrosis in Adult-Onset Immunoglobulin A Vasculitis (Henoch-Schönlein Purpura). *J Investig Med High Impact Case Rep* 2020. doi:10.1177/2324709620925565.
- Arunath V, Athapathu AS, Hoole TJ, et al. Severe Disfiguring Scalp and Facial Oedema due to Henoch-Schönlein Purpura in a Child. *Case Rep Pediatr* 2020;2020:8823611.
- Cardoso FS, Dias D, Mendes M, et al. A fatal case of severe gastrointestinal and renal involvement in Henoch-Schönlein purpura. *J Nephrothol* 2019;8:31.
- Tachikawa Y, Yazawa K, Kawai K, et al. Improvement of anaphylactoid purpura in a patient with ascending colon cancer after colectomy. *ANZ J Surg* 2019;89:1339-41.
- Yamabe H, Kaizuka M, Tsunoda S, et al. Henoch-Schönlein Nephritis Manifesting with Purpura 15 years after Diagnosis of IgA Nephropathy. *Case Rep Nephrol* 2019;2019:1042648.
- Zhang X, Nima Z, Zhang S, et al. Efficacy Analysis of Glucocorticoids in the Treatment of Allergic Purpura in Tibetan Children. *Int J Clin Med* 2021;12:14-22.
- Umapathi KK, Thavamani A, Puliyeel M. Predictors of In-Hospital Mortality in Thrombotic Thrombocytopenic Purpura in Children in the United States: A Population Analysis. *J Pediatr Hematol Oncol* 2020;42:e340-4.
- Batu ED, Sarı A, Erden A, et al. Comparing immunoglobulin A vasculitis (Henoch-Schönlein purpura) in children and adults: a single-centre study from Turkey. *Scand J Rheumatol* 2018;47:481-6.
- Ghosh SA, Patrick J, Maw KZ. Acute kidney injury and nephrotic syndrome associated with eltrombopag therapy in chronic idiopathic thrombocytopenic purpura. *BMJ Case Rep* 2021;14:e241462.
- Cervantes F, Montserrat E, Rozman C, et al. Low-dose vincristine in the treatment of corticosteroid-refractory idiopathic thrombocytopenic purpura (ITP) in non-splenectomized patients. *Postgrad Med J* 1980;56:711-4.
- Namal Rathnayaka R, Ranathunga PAN, Kularatne SA. Thrombotic Microangiopathy, Hemolytic Uremic Syndrome, and Thrombotic Thrombocytopenic Purpura Following Hump-nosed Pit Viper (Genus: *Hypnale*) Envenoming in Sri Lanka. *Wilderness Environ Med* 2019;30:66-78.
- de St Maurice A, Nyakarahuka L, Purpura L, et al. Rift Valley Fever: A survey of knowledge, attitudes, and practice of slaughterhouse workers and community members in Kabale District, Uganda. *PLoS Negl Trop Dis* 2018;12:e0006175.
- Romão de Souza V Jr, Beatriz Cavalcante de Oliveira A, Maria Vanderlei A, et al. Inherited thrombotic thrombocytopenic purpura mimicking immune thrombocytopenic purpura during pregnancy: a case report. *J Med Case Rep* 2018;12:15.
- Arslansoyu Çamlar S, Soyulu A, Akil İ, et al. Henoch-Schönlein purpura, post-streptococcal glomerulonephritis and acute rheumatic carditis after Group A  $\beta$ -haemolytic streptococcal infection. *Paediatr Int Child Health* 2018;38:73-5.
- Vigna E, Petrunaro A, Perri A, et al. Efficacy of eculizumab in severe ADAMTS13-deficient thrombotic thrombocytopenic purpura (TTP) refractory to standard



- therapies. *Transfus Apher Sci* 2018;57:247-9.
25. Nikibakhsh AA, Mahmoodzadeh H, Karamyyar M, et al. Treatment of complicated henoch-schönlein purpura with mycophenolate mofetil: a retrospective case series report.

*Int J Rheumatol* 2010;2010:254316.

(English Language Editor: J. Jones)

**Cite this article as:** Li M, Guo B, Wang X, Zhang Y. Risk factors of renal trauma in children with severe Henoch-Schonlein purpura and effect of mycophenolate mofetil on pediatric renal function. *Transl Pediatr* 2021;10(12):3166-3174. doi: 10.21037/tp-21-493