

Umbilical Negative Pressure Dressing for Transumbilical Appendectomy in Children

Federico G. Seifarth, MD, Neilendu Kundu, MD, Alfredo D. Guerron, MD, Mary M. Garland, MD, Michaela W. G. Gaffley, MD, Sarah Worley, MD, Colin G. Knight, MD

ABSTRACT

Background and Objectives: Transumbilical laparoscopic-assisted appendectomy (TULAA) carries a high risk for surgical site infection. We investigated the effect of a bio-occlusive umbilical vacuum dressing on wound infection rates after TULAA for patients with acute appendicitis and compared to it with a conventional 3-port appendectomy with a nonvacuum dressing.

Methods: This study was a retrospective chart review of 1377 patients (2–20 years) undergoing laparoscopic appendectomy for acute appendicitis in 2 tertiary care referral centers from January 2007 through December 2012. Twenty-two different operative technique/dressing variations were documented. The 6 technique/dressing groups with >50 patients were assessed, including a total of 1283 patients.

Results: The surgical site infection rate of the 220 patients treated with TULAA and application of an umbilical vacuum dressing with dry gauze is 1.8% (95% CI, 0.0–10.3%). This compares to an infection rate of 4.1% (95% CI, 1.3–10.5%) in 97 patients with dry dressing without vacuum. In the 395 patients who received an umbilical vacuum dressing with gauze and bacitracin, the surgical site infection rate was found to be 4.3% (95% CI, 2.7–6.8%).

Conclusions: Application of an umbilical negative-pressure dressing with dry gauze lowers the rate of umbilical

site infections in patients undergoing transumbilical laparoscopic-assisted appendectomy for acute appendicitis.

Keywords: Appendicitis, Appendectomy, TULAA, Vacuum dressing, Wound Infection.

INTRODUCTION

Laparoscopic appendectomy is one of the most frequent surgical procedures in children and has become the surgical standard for appendicitis.¹ The increased use of laparoscopy for appendectomy in the pediatric population within the past 2 decades has led to a significant decrease in postoperative morbidity, including the incidence of surgical site infection.^{2,3}

In recent years numerous variations of the conventional 3-port laparoscopic appendectomy (TPLA) have been described. Particularly, single-incision surgery or the use of a reduced number of laparoscopic ports has become popular. The transumbilical laparoscopic-assisted appendectomy (TULAA) combines the convenience of the open technique with the benefits of a minimally invasive approach by the use of a 0°, 10-mm laparoscope with inbuilt working channel. This technique requires one umbilical port. A blunt 5-mm laparoscopic grasper is used to gently mobilize and exteriorize the appendix through the umbilical port site to proceed with the appendectomy in conventional open fashion.

As with any technique that applies extracorporeal resection of the inflamed appendix, wound infection is a legitimate concern. This extracorporeal, laparoscopically assisted single-incision technique is expected to carry a higher risk for surgical site infection compared with the 3-port laparoscopic appendectomy.^{4,5}

Previous reports suggest the application of a simple postoperative vacuum dressing to reduce the risk of surgical site infections after intracorporeal single-incision appendectomy in children.⁶ This dressing can be applied on any umbilical or periumbilical incision. Compacted dry gauze is placed directly into the umbilicus and is covered with a bio-occlusive transparent film (Tegaderm; 3M, Minneapo-

Department of Pediatric Surgery, Kalispell Regional Healthcare, Kalispell, Montana, USA (Dr Seifarth).

Dermatology and Plastic Surgery Institute (Dr Kundu) and Quantitative Health Sciences (Ms Worley), Cleveland Clinic Foundation, Cleveland, Ohio, USA.

Department of Surgery, Duke University, Durham, North Carolina, USA (Dr Guerron).

Department of Internal Medicine, Wake Forest Baptist Hospital, Winston-Salem, North Carolina, USA (Drs Garland and Gaffley).

Department of Pediatric Surgery, Nicklaus Children's Hospital, Miami, Florida, USA (Dr Knight).

Address correspondence to: Federico G. Seifarth, MD, Department of Pediatric Surgery, Kalispell Regional Healthcare, 1333 Surgical Services Drive, Kalispell, MT 59901. Phone: 406-407-1345, Fax: 406-752-8220, E-mail: fseifarth@krmc.org

DOI: 10.4293/JSLS.2016.00070

© 2016 by JSLS, *Journal of the Society of Laparoendoscopic Surgeons*. Published by the Society of Laparoendoscopic Surgeons, Inc.

lis, Minnesota, USA). The air within the gauze is evacuated with a 22-gauge needle on a syringe, tunneled laterally through the subcutaneous tissue into the gauze. A vacuum is created by aspirating the air (**Figure 1**).⁷

The purpose of this study was to determine whether this low-cost, bio-occlusive umbilical vacuum dressing lowers the rate of surgical site infection after extracorporeal laparoscopic-assisted appendectomies for acute appendicitis.

MATERIALS AND METHODS

Following institutional review board (IRB) approvals, data were obtained through a query of institutional electronic medical record (EMR) databases at 2 tertiary care children's hospitals (Cleveland Clinic Children's Hospital, Cleveland, Ohio, USA, and Nicklaus Children's Hospital, Miami, Florida, USA). Patients between 2 and 20 years of age who underwent laparoscopic appendectomy for acute appendicitis from January 2007 through December 2012 were identified by using the International Classification of Disease, 9th revision. We identified 1377 patients who had been operated on by 10 pediatric surgeons. All involved surgeons had at least 2 years' experience in performing the surgeries. Patients with a histological diagnosis of gangrenous, suppurative, or perforated appendicitis were excluded. All patients were routinely followed up 3–4 weeks after the initial operation; earlier in cases with umbilical symptoms like drainage, erythema, or pain out of proportion.

A total of 22 operative technique/dressing variations were documented in 1377 patients undergoing appendectomy for acute appendicitis. Of these variations, 6 were used in 50 or more patients and accounted for 1283 (93%) of the procedures performed.

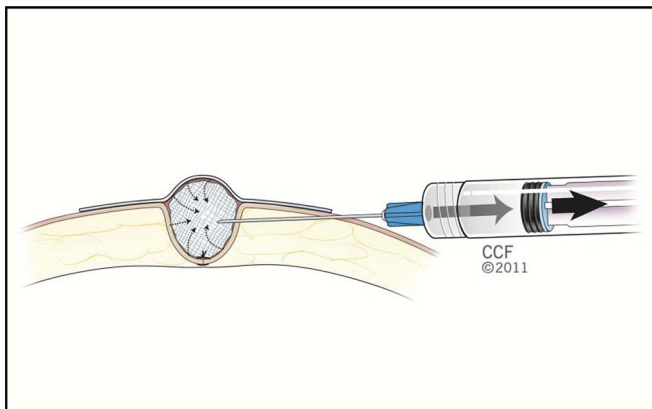


Figure 1. Vacuum dressing technique.⁷

Statistical Methods

The goal of the statistical analysis was to determine whether application of an umbilical vacuum dressing lowers the rate of surgical site infections within a group with the identical surgical technique. Wound infection rates and relative risks for wound infection rates between groups were calculated with 95% CI. The 6 most common technique/dressing groups were compared on wound infection rates by using Fisher's exact test at an overall significance level of 0.05; pairwise comparisons of groups on the wound infection rate were performed with the Bonferroni correction of the significance level ($0.05/15 = 0.003$). SAS 9.4 software (Cary, North Carolina, USA) was used for analysis.

RESULTS

Of 1283 patients, the 6 most common technique/dressing combinations used for more than 50 individuals were the following:

Group 1 (n = 107): three-port laparoscopic appendectomy (TPLA) with intracorporeal amputation of the appendix, periumbilical camera port access, and protected retrieval of the appendix. Dermabond dressing (Ethicon, Somerville, New Jersey, USA). Infection rate, 2.8% (95% CI 0.6–8.3%).

Group 2 (n = 408): PLA with intracorporeal amputation, periumbilical camera port access, and protected retrieval of the appendix. Steri-Strip dressing (3M). Infection rate, 0.74% (95% CI, 0.1–2.2%).

Group 3 (n = 56): TPLA with intracorporeal amputation, transumbilical camera port access, umbilical vacuum dressing (UVD) with gauze without bacitracin. Infection rate, 1.8% (95% CI, 0.0–10.3%).

Group 4 (n = 97): TULAA with extracorporeal amputation, transumbilical camera port access, and occlusive umbilical dressing with gauze without vacuum. Infection rate, 4.1% (95% CI: 1.3–10.5%).

Group 5 (n = 395): TULAA with extracorporeal amputation, transumbilical camera port access, UVD with absorbent cotton or gauze, and bacitracin. Infection rate, 4.3% (95% CI: 2.7, 6.8%).

Group 6 (n = 220): TULAA with extracorporeal amputation, transumbilical camera port access, UVD with gauze without bacitracin. Infection rate, 2.7% (95% CI: 1.1, 6.0%).

Table 1 defines subcohort characteristics of all patients with acute appendicitis. **Figure 2** summarizes infections rates for groups 1 to 6 in a line graph with 95% CI.

Table 1.
Subcohort Characteristics of All Patients With Acute Appendicitis

Factor	Total (N = 1283)
Sex, n (%)	
Male	765 (60)
Female	518 (40)
Age (y), median [Q1, Q3]	12 [9, 15]
Age <5 y, n (%)	36 (3)
Diagnosis, n (%)	
Acute appendicitis	1283 (100)
Procedure, n (%)	
TULAA	712 (55)
TPLA with Endocatch	305 (24)
TPLA without Endocatch	266 (21)
Extra/intracorporeal amputation, n (%)	
Intracorporeal amputation	571 (45)
Extracorporeal amputation	712 (55)
Access, n (%)	
Periumbilical	515 (40)
Transumbilical	768 (60)
Dressing, n (%)	
UVD with gauze no bacitracin	276 (22)
UVD with cotton/gauze + bacitracin	395 (31)
Occlusive dressing with gauze no bacitracin, no vacuum	97 (8)
Dermabond	107 (8)
Steri-Strips	408 (32)
Technique/dressing group, n (%)	
1. TPLA, periumbilical, intracorporeal, Dermabond® dressing	107 (8)
2. TPLA, periumbilical, intracorporeal, Steri-Strip™ dressing	408 (32)
3. TPLA, transumbilical, intracorporeal, UVD with gauze without Bacitracin	56 (4)
4. TULAA, transumbilical, extracorporeal, occlusive umbilical dressing with gauze without vacuum	97 (8)
5. TULAA, transumbilical, extracorporeal, UVD with absorbent cotton/gauze and Bacitracin	395 (31)
6. TULAA, transumbilical, extracorporeal, UVD with gauze without Bacitracin	220 (17)
Wound infection (Y/N), n (%)	34 (3)

Patients of group 2 with periumbilical port placement for conventional 3-port laparoscopic appendectomy with intracorporeal amputation of the appendix and retrieval of the inflamed appendix in an Endocatch bag (Medtronic-Covidien, Minneapolis, Minnesota, USA) or through the port and application of a Steri-Strip (3M) dressing had the lowest wound infection rate (0.74%). Individuals of Group 3 who underwent the same operation, but via transumbilical access with a vacuum dressing, had a higher infection rate (1.8%; relative risk 2.4; 95% CI 0.26–22.9).

Within the groups undergoing TULAA via vertical transumbilical access and extracorporeal amputation of the appendix, patients with the UVD showed lower infection rates (Group 6, 2.7%) when compared with those with occlusive umbilical dressing without vacuum application (Group 4, 4.1%, relative risk 0.66; 95% CI, 0.19–2.2) or UVD with bacitracin (Group 5, 4.3%, relative risk 0.63; 95% CI, 0.25–1.6). Of all patients with UVD after TULAA, those with UVD composed of dry gauze and Tegaderm (Group 6, 2.7%) showed the lowest infection rate (**Table 2**). Addition of bacitracin or omission of vacuum application led to higher infection rates (Groups 5/4: 4.3%/4.1%).

DISCUSSION

Within the past 2 decades laparoscopic appendectomy has evolved to the gold standard of surgical care for appendicitis. In Canada, the incidence of laparoscopic appendectomy increased from 28.8% to 66.4% from 2004–2010 with an associated reduction of hospital stay for both acute and perforated appendicitis.⁸

The incidence of postoperative wound infections in children ranges from 2.2 to 3.1% for the conventional 3-port laparoscopic appendectomy compared to 3.7% for the open appendectomy.^{2,3}

The TULAA is a popular alternative to the conventional 3-port appendectomy. It has been shown to be associated with lower cost and results comparable to those of the conventional 3-port laparoscopic appendectomy.^{9–13}

As expected, the rate of surgical site infections for TULAA were higher compared to those following the standard TPLA, where the inflamed appendix or appendiceal stump is never in direct contact with the surgical incision.⁴

Operative technique and dressing type were the surgeon's choice, and patients may have been preferentially selected for TPLA or TULAA based on body habitus or surgeon experience or preference. In addition to this high

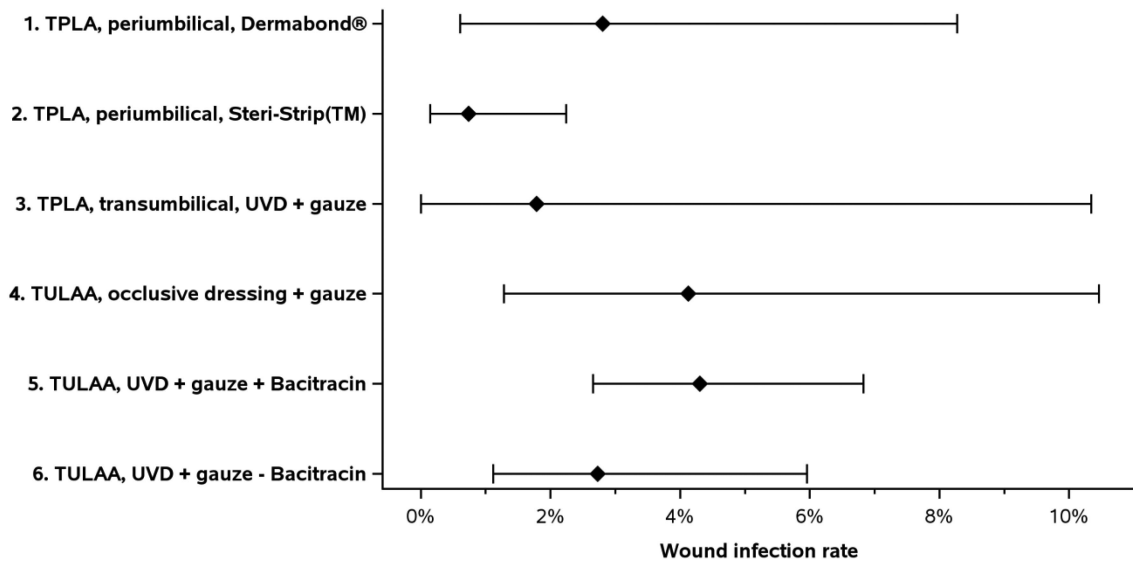


Figure 2. Wound infection rates by group with 95% CI.

Table 2.
Patients Undergoing TULAA (Groups 4–6)

Factor	Group 4	Group 5	Group 6
	TULAA	TULAA	TULAA
	Occlusive Umbilical Dressing With Gauze Without Vacuum	UVD With Absorbent Cotton/Gauze and Bacitracin	UVD with Gauze Without Bacitracin
	Total	Total	Total
	(n = 712)	(n = 395)	(n = 220)
Sex, n (%)			
Male	427 (60)	235 (59)	135 (61)
Female	285 (40)	160 (41)	85 (39)
Age (y), median [Q1, Q3]	11 [8, 15]	11 [9, 14]	12 [9, 15]
Age <5 y, n (%)	21 (3)	12 (3)	5 (2)
Wound infection (Y/N), n (%) 95% CI	4 (4.1) (1.3%, 10.5%)	17 (4.3) (2.7%, 6.8%)*	6 (2.7) (1.1%, 6.0%)

Pairwise comparisons of groups on wound infections rate were performed using the Bonferroni correction to the significance level.

*Significantly different from Group 2.

level of selection bias by 10 different surgeons, our study was limited by its retrospective nature with the inherent risk of inaccurate documentation of selected cases. To be able to compare infection rates between different types of procedures and dressings, we excluded patients with suppurative or perforated appendicitis. The surgical site infection rate of patients with all types of appendicitis undergoing TULAA with umbilical vacuum dressing (dry

gauze, no bacitracin) was 4.1% in our cohort. This result seems to reflect previously reported data.

In a single-center, retrospective review including 416 patients, Ohno et al¹⁴ reported a wound infection rate of 7.5% for transumbilical appendectomy for acute, phlegmonous, or perforated appendicitis. Stylianos et al¹³ found an infection rate of 8%, in a cohort of 508 patients with similar distribution

of appendicitis stages. Other series with 262 and 372 patients at all stages of appendicitis reported wound infection rates of 0.4%¹⁵ and 11.1%,¹¹ respectively.

Stanfill et al⁵ compared rates of surgical site infection between TULAA and TPLA in a retrospective study of 131 patients and found a significantly higher wound infection rate of 2.1% when applying TULAA versus 1.2% in patients after conventional TPLA.

In our study, conventional TPLA had a significantly lower surgical site infection rate compared to TULAA with identical dressings. Access site (periumbilical versus transumbilical) and type of dressing were found to have a significant impact on the documented rate of wound infections. Patients undergoing TPLA with periumbilical port access and a Steri-Strip dressing were found to have the lowest surgical site infection rate with 0.74% followed by patients who underwent TPLA via transumbilical access and a UVD with dry gauze (1.8% infection rate). The small sample size of 56 patients puts this result in perspective but could be an indicator for the potential of the UVD to prevent wound infections. Patients who underwent TPLA but had a Dermabond dressing on the periumbilical access wound had a higher wound infection rate (2.8%) than did patients with the Steri-Strip dressing (0.74% infection rate). We speculate that the occlusive nature of Dermabond favors wound infections.

Between the groups of patients undergoing TULAA via vertical transumbilical access, we noted that patients with the application of a UVD with dry gauze had a lower infection rate (2.7%) versus those whose umbilicus was covered with an occlusive dressing composed of dry gauze and Tegaderm (4.1% infection rate). Of note, the infection rate of patients undergoing TULAA with a UVD composed of dry gauze was found to be lower than for patients undergoing an intracorporeal TPLA appendectomy with periumbilical camera port access and a Dermabond dressing (2.7% versus 2.8%). A layer of bacitracin on the wound seemed to abolish the potential of UVD to reduce the rate of surgical site infections, substantiated by the higher infection rate of 4.3% in the group treated with TULAA and a UVD with bacitracin. Although the antibiotic ointment prevents the dressing from sticking to the incision, it also seals the incision and attenuates the effect of the vacuum on the wound edges and decreases the effectiveness of the dressing in absorbing wound secretions.

The technique and possible benefits of the UVD have been described in previous publications.^{6,7,16} Its suggested properties are comparable to the well-studied mechanism of action of commercial wound vacuum devices for accel-

erated wound healing and decreased infection rates in selected wounds. These mechanisms of action, observed from -25 to -150 mm Hg, are attributed to increased blood flow, promotion of angiogenesis, induction of cell proliferation, and possibly bacterial clearance.^{17,18} In a cohort of 183 patients, Muensterer et al⁶ found a lower infection rate (1%) in patients undergoing single-incision intracorporeal laparoscopic appendectomy with UVD versus 7% in patients with approximating Steri-Strips. Muensterer attributed the decreased wound infection rate to the clearance of wound secretions by the vacuum dressing. This report adumbrates the promise of this dressing but describes only its application on clean wounds after intracorporeal appendectomy in contrast to potentially contaminated incisions after extracorporeal appendectomy in TULAA. Another difference lies in the short duration of the dressing that was removed after 2 d in this study compared to 7 d in our cohort.

CONCLUSION

Transumbilical access and extracorporeal amputation of the appendix carries a higher risk for postoperative surgical site infections compared to conventional intracorporeal appendectomy via periumbilical incision and application of Steri-Strips.

In this retrospective study, application of an umbilical negative-pressure dressing lowered the rate of umbilical site infections significantly. A prospective trial is necessary to substantiate these findings.

References:

1. Masoomi H, Nguyen NT, Dolich MO, Mills S, Carmichael JC, Stamos MJ. Laparoscopic appendectomy trends and outcomes in the United States: data from the Nationwide Inpatient Sample (NIS), 2004–2011. *Am Surg*. 2014;80:1074–1077.
2. Gasior AC, St Peter SD, Knott EM, Hall M, Ostlie DJ, Snyder CL. National trends in approach and outcomes with appendicitis in children. *J Pediatr Surg*. 2012;47:2264–2267.
3. Nataraja RM, Loukogeorgakis SP, Sherwood WJ, Clarke SA, Haddad MJ. The incidence of intraabdominal abscess formation following laparoscopic appendectomy in children: a systematic review and meta-analysis. *J Laparoendosc Adv Surg Tech A*. 2013;23:795–802.
4. Iqbal CW, Ostlie DJ. The minimally invasive approach to appendectomy: is less better? *Eur J Pediatr Surg*. 2012;22:201–206.
5. Stanfill AB, Matilsky DK, Kalvakuri K, Pearl RH, Wallace LJ, Vegunta RK. Transumbilical laparoscopically assisted ap-

pendectomy: an alternative minimally invasive technique in pediatric patients. *J Laparoendosc Adv Surg Tech A*. 2010;20:873–876.

6. Muensterer OJ, Keijzer R. A simple vacuum dressing reduces the wound infection rate of single-incision pediatric endosurgical appendectomy. *JSLS*. 2011;15:147–150.

7. Seifarth FG, Knight CG. A simple postoperative umbilical negative-pressure dressing. *Adv Skin Wound Care*. 2013;26:26–29.

8. Cheong LH, Emil S. Pediatric laparoscopic appendectomy: a population-based study of trends, associations, and outcomes. *J Pediatr Surg*. 2014;49:1714–1718.

9. D'Alessio A, Piro E, Tadini B, Beretta F. One-trocar transumbilical laparoscopic-assisted appendectomy in children: our experience. *Eur J Pediatr Surg*. 2002;12:24–27.

10. Koontz CS, Smith LA, Burkholder HC, Higdon K, Aderhold R, Carr M. Video-assisted transumbilical appendectomy in children. *J Pediatr Surg*. 2006;41:710–712.

11. Kulaylat AN, Podany AB, Hollenbeak CS, Santos MC, Rocco DV. Transumbilical laparoscopic-assisted appendectomy is associated with lower costs compared to multiport laparoscopic appendectomy. *J Pediatr Surg*. 2014;49:1508–1512.

12. Pappalepore N, Tursini S, Marino N, Lisi G, Lelli Chiesa P. Transumbilical laparoscopic-assisted appendectomy (TULAA): a

safe and useful alternative for uncomplicated appendicitis. *Eur J Pediatr Surg*. 2002;12:383–386.

13. Stylianos S, Nichols L, Ventura N, Malvezzi L, Knight C, Burnweit C. The “all-in-one” appendectomy: quick, scarless, and less costly. *J Pediatr Surg*. 2011;46:2336–2341.

14. Ohno Y, Morimura T, Hayashi S. Transumbilical laparoscopically assisted appendectomy in children: the results of a single-port, single-channel procedure. *Surg Endosc*. 2012;26:523–527.

15. Sesia SB, Haecker FM, Kubiak R, Mayr J. Laparoscopy-assisted single-port appendectomy in children: is the postoperative infectious complication rate different? *J Laparoendosc Adv Surg Tech A*. 2010;20:867–871.

16. Hahm SJ, Burd RS. Cotton ball-vacuum compression for dressing small wounds. *Pediatr Surg Int*. 2003;19:748.

17. Moues CM, Heule F, Hovius SE. A review of topical negative pressure therapy in wound healing: sufficient evidence? *Am J Surg*. 2011;201:544–556.

18. Moues CM, van Toorenbergen AW, Heule F, Hop WC, Hovius SE. The role of topical negative pressure in wound repair: expression of biochemical markers in wound fluid during wound healing. *Wound Repair Regen*. 2008;16:488–494.