

MINI-FOCUS ISSUE: ELECTROPHYSIOLOGY

ADVANCED

CASE REPORT: CLINICAL CASE

# Successful Percutaneous Retrieval of an Embolized Left Atrial Appendage Occluder

Federico Ferraris, MD, Michele Millesimo, MD, Matteo Anselmino, MD, PhD, Davide Castagno, MD, PhD, Alessandro Vairo, MD, Gianluca Alunni, MD, Gaetano Maria De Ferrari, MD

## ABSTRACT

A 75-year-old man with a previous mitral valve repair experienced embolization of a left atrial appendage occlusion device in the left atrium. The device was successfully retrieved using a double snaring technique, without the need for open surgery. This is an unusual report of left atrial appendage occluder retrieval, confirming the feasibility of the technique and the high flexibility of the device. (**Level of Difficulty: Advanced.**) (J Am Coll Cardiol Case Rep 2022;4:101689)  
© 2022 The Authors. Published by Elsevier on behalf of the American College of Cardiology Foundation. This is an open access article under the CC BY-NC-ND license (<http://creativecommons.org/licenses/by-nc-nd/4.0/>).

A 75-year-old man noticed dyspnea and fatigue 1 week after undergoing concomitant atrial fibrillation (AF) cryoablation and left atrial appendage occlusion (LAAO) with a Watchman FLX device (Boston Scientific Corporation). He did not seek medical attention but underwent the planned transesophageal echocardiography (TEE) 3 months after the procedure. TEE showed embolization of the device in the left atrium.

## MEDICAL HISTORY

The patient had undergone mitral valve repair surgery in 2019 after a chordal rupture (P2 triangular resection and 30-mm ring positioning). Two years

later he experienced an ischemic stroke after a palpitation episode. A loop recorder was implanted, and monitoring confirmed paroxysmal AF. He was then prescribed a novel oral anticoagulant (NOAC), Class Ic antiarrhythmic and beta-blocker therapy. Because the symptomatic AF recurred despite the antiarrhythmic medication, he was referred for catheter ablation. He agreed to participate in the ongoing OPTION (Comparison of Anticoagulation with Left Atrial Appendage Closure After AF Ablation) trial and was randomized to the device group (AF ablation + LAAO). Preprocedural imaging included TEE and cardiac computed tomography angiography (CCTA), which ruled out LAA thrombi and showed a chicken-wing LAA morphology. After uncomplicated pulmonary vein isolation with cryoenergy, a percutaneous LAA closure was performed during the same session. Fluoroscopy, angiography, and intraprocedural TEE were used to guide the delivery.

The patient was in sinus rhythm during the entire procedure. His left atrial mean pressure was 10 mm Hg. An LAA ostium of 21 mm and depth of 26.7 mm were measured on TEE after the ablation and

## LEARNING OBJECTIVES

- To review LAAO embolization incidence and technique of retrieval
- To confirm feasibility of percutaneous retrieval of a left atrial appendage closure device.

From the Division of Cardiology, Cardiovascular and Thoracic Department, Città della Salute e della Scienza University Hospital of Turin, Turin, Italy.

The authors attest they are in compliance with human studies committees and animal welfare regulations of the authors' institutions and Food and Drug Administration guidelines, including patient consent where appropriate. For more information, visit the [Author Center](#).

Manuscript received March 2, 2022; revised manuscript received September 27, 2022, accepted October 28, 2022.

**ABBREVIATIONS  
AND ACRONYMS****AF** = atrial fibrillation**CCTA** = cardiac computed tomography angiography**LAA** = left atrial appendage**LAAO** = left atrial appendage occlusion**NOAC** = novel oral anticoagulant**TEE** = transesophageal echocardiography

confirmed with fluoroscopy. An LAA closure device of 27 mm was deployed in the appendage. After tug test, the final implantation position was evaluated with TEE, showing compression to 21 mm, no tilting and no leak (**Figure 1**).

The antithrombotic regimen for the device group was market-approved NOAC and aspirin until the 3-month TEE and clinical evaluation.

**INVESTIGATIONS**

The 3-month TEE showed migration of the LAA occluder on the atrial side of the mitral valve plane (**Figure 2, Video 1**), causing significant valvular obstruction (mean gradient 8 mm Hg). There were no thrombi in the LAA and no shunt across the interatrial septum. The loop recorder did not show AF recurrence. During the 3 months of rivaroxaban 20 mg plus aspirin 100 mg daily, there were no bleeding events. The patient was planned for an attempt at percutaneous device retrieval, and the previous dose of NOAC was given 24 hours before the procedure. At hospital admission, the results of physical examination were unremarkable, with blood pressure of 135/80 mm Hg, peripheral oxygen saturation of 98%, heart rate of 73 beats/min, and body temperature of 36 °C.

**MANAGEMENT**

The procedure was performed with the patient under general anesthesia, with TEE and fluoroscopy guidance. Using a right femoral vein access, 2 separate transseptal punctures were performed, and 2

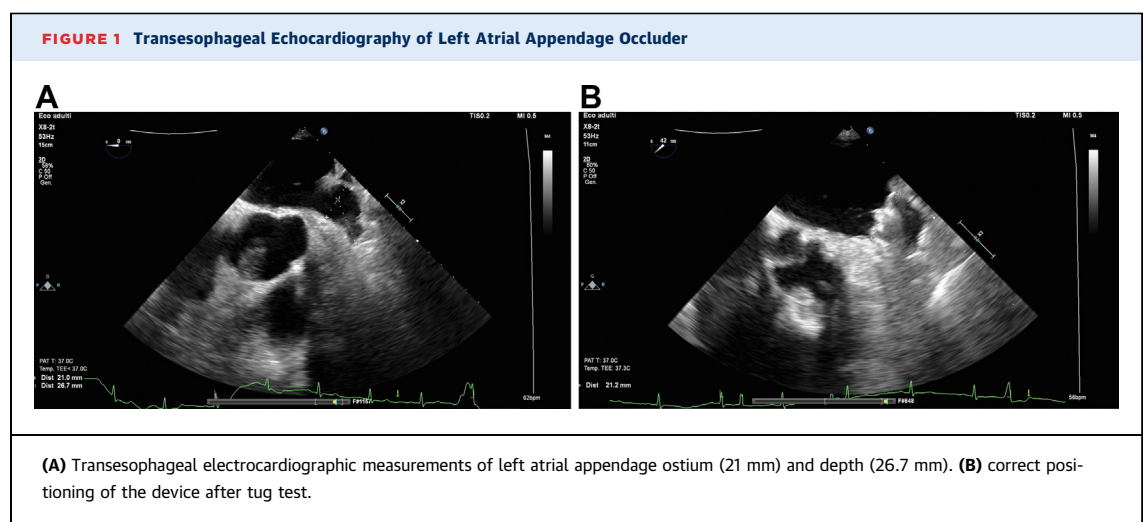
steerable introducers were positioned in the left atrium (8-F and 12-F). A left femoral arterial access was precautionarily obtained in the event of a distal embolization of the device. During the procedure, the activated clotting time was maintained at  $\geq 300$  seconds.

The device was immobilized with a biptome advanced through the 12-F introducer (**Figure 3, Video 2**) and encircled along its transverse axis by an Osypka Lasso snare catheter, inserted through the 8-F introducer (**Figure 4, Videos 3 and 4**).

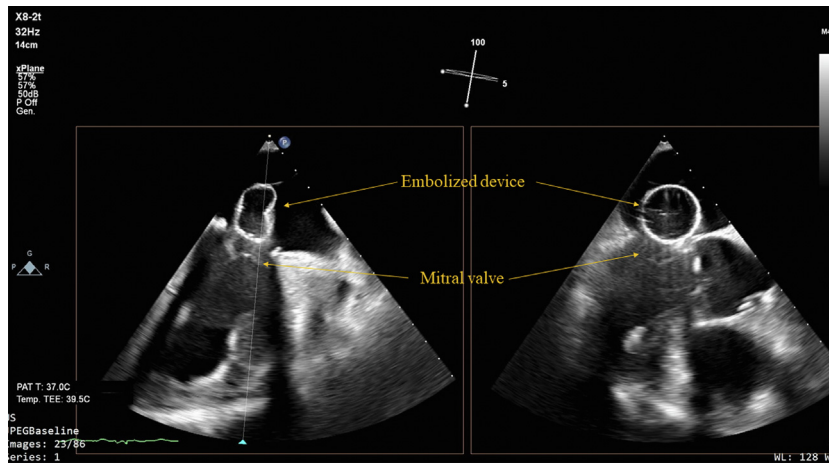
The tightening of the snare catheter gave the device an hourglass shape, with its atrial side pointing upward. The biptome was swapped with a second snare catheter, which was able to catch the device close to its proximal end (**Figures 5 and 6, Videos 5 and 6**). The first snare catheter was then loosened, and traction was applied to the second one. Being pulled from a site close to the former allocation of the screw, the device collapsed almost entirely in the 12-F introducer (**Figure 7, Video 7**). The 12-F introducer with the device inside was removed together with the 8-F introducer after placement of a figure-of-eight suture. Post-procedural TEE revealed no damage to the mitral valve apparatus and a minimal interatrial septum shunt

**DISCUSSION**

Device embolization is a known complication of LAA closure, with an average reported rate of  $<0.5\%$ . The majority of cases (89%) occur either during the procedure or during the hospital stay,<sup>1</sup> whereas other series report late (ie,  $>4$ -6 weeks) embolization in up to one third of cases.<sup>2</sup>



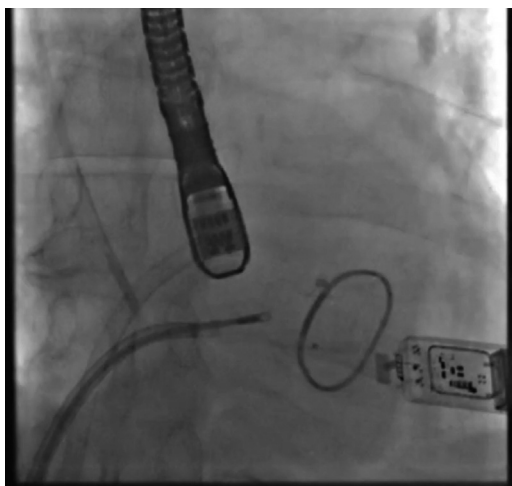
**FIGURE 2** Migration of the Device in Left Atrium



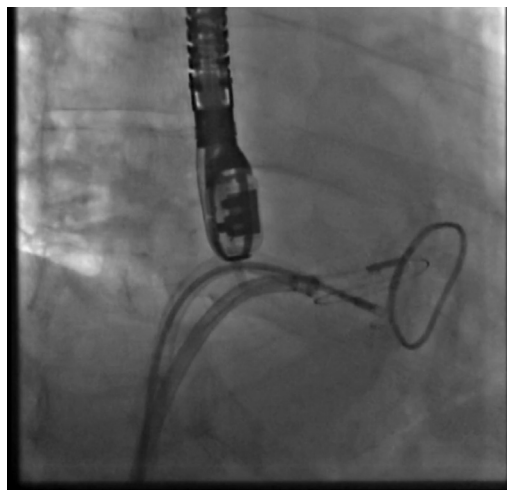
At the moment of the occluder release all the PASS criteria (Position, Anchoring, Size, and Seal)<sup>3</sup> were fulfilled: the device was positioned properly without tilting; the result of a tug test was normal, suggesting proper anchoring; the compression rate was 22%, within the suggested rate of 10% to 30%; and there were no leaks. We hypothesized a role of the concomitant AF cryoablation, inasmuch as delivery of cryoenergy at the ridge between the LAA and the left superior pulmonary vein results in significant edema of this region,<sup>4,5</sup> and suboptimal procedural outcomes

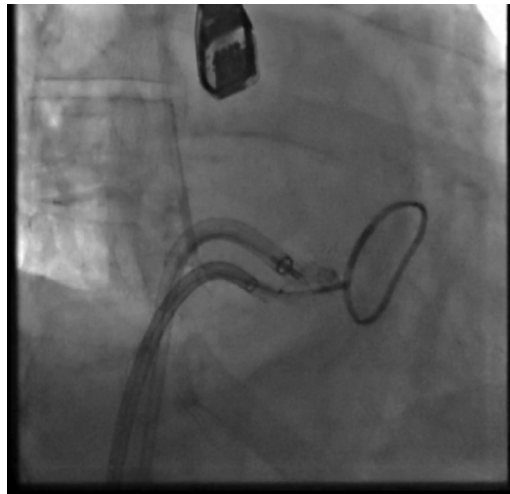
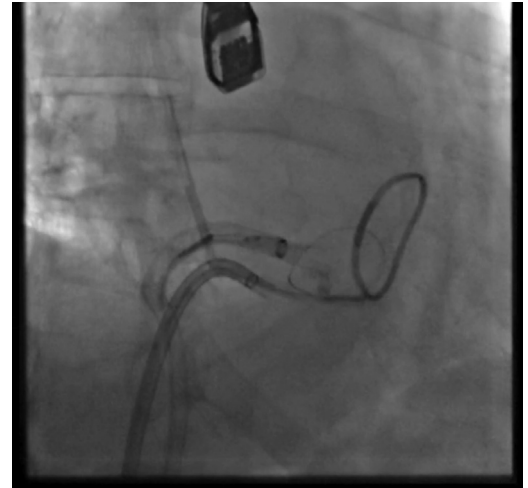using this strategy have been reported.<sup>6</sup> Concomitant AF ablation and LAAO, given the similarities in their procedural steps, provide the advantages of a single procedure, virtually leading to improved resource use and cost effectiveness, and previous small studies reported outcomes,<sup>7,8</sup> but there is concern that the postablation edema of the ridge between the left superior pulmonary vein and the appendage may lead to underestimation of the appendage size. Results of the ongoing OPTION trial will provide further insight regarding this particular issue. Of note, the

**FIGURE 3** Immobilization of the Device With a Biopptome Positioned in the 12-F introducer



**FIGURE 4** Inserted Through the 8-F Introducer, a Snare Catheter Encircles the Device Along Its Transverse Axis

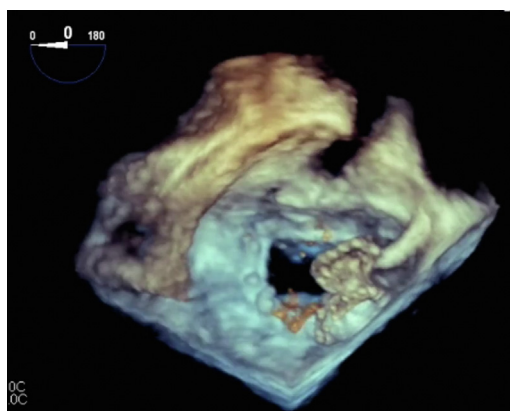


**FIGURE 5** Encircled Device by the Snare Catheter Along Its Transverse Axis**FIGURE 7** The Device Collapsed Almost Entirely in the Introducer After Losing the First Snare Catheter and Applying Traction the Second One

appendage ostium was echocardiographically measured also during the retrieval procedure, presumably after resolution of ablation-related edema, showing no difference from the implant evaluation.

Previous mitral valve repair probably prevented embolization of the device in the left ventricle or in the aorta, without the need of a retrograde femoral arterial approach.<sup>9</sup> However, according to literature recommendation,<sup>10</sup> we decided to use 1 of the 2 left atrial accesses to secure the device as a safety precaution.

Once the device was stabilized with the bioptome, the retrieval was relatively straightforward, confirming the high flexibility properties of the device.

**FIGURE 6** Bioptome was Swapped With a Second Snare Catheter That Was Able to Catch the Device Close to Its Proximal End

## FOLLOW-UP

No complication was observed during the hospital stay or at the 3-month follow-up visit. The patient's dyspnea resolved immediately after the retrieval procedure. He did not undergo reimplantation, and aspirin was stopped.

## CONCLUSIONS

Device embolization is a rare complication of LAAO and can occur with any available percutaneous occluder. This is an unusual report of a successful percutaneous retrieval of an embolized left atrial appendage closure device. Although the left atrial position has facilitated the procedure, we confirm the feasibility of the double snaring technique also with this device.

## FUNDING SUPPORT AND AUTHOR DISCLOSURES

This research was supported by a grant from the Italian Ministry of Health: "Giovani Ricercatori-Ricerca Finalizzata", project number GR-2016-02362088; the funder had no role in this study. The authors have reported that they have no relationships relevant to the contents of this paper to disclose.

**ADDRESS FOR CORRESPONDENCE:** Dr. Michele Millesimo, Division of Cardiology, Cardiovascular and Thoracic Department, Città della Salute e della Scienza University Hospital of Turin, Corso Bramante 88, 10126 Turin, Italy. E-mail: [michele.millesimo@gmail.com](mailto:michele.millesimo@gmail.com). Twitter: [@MiMillesimo](https://twitter.com/MiMillesimo).

---


## REFERENCES

1. Reddy VY, Gibson DN, Kar S, et al. Post-approval U.S. experience with left atrial appendage closure for stroke prevention in atrial fibrillation. *J Am Coll Cardiol*. 2017;69:253-261.
2. Aminian A, Lalmand J, Tzikas A, Budts W, Benit E, Kefer J. Embolization of left atrial appendage closure devices: A systematic review of cases reported with the watchman device and the Amplatzer cardiac plug: Embolization of left atrial appendage closure devices. *Catheter Cardiovasc Interv*. 2015;86:128-135.
3. Glikson M, Wolff R, Hindricks G, et al. EHRA/EAPCI expert consensus statement on catheter-based left atrial appendage occlusion: An update. *EuroIntervention*. 2020:151133-151180.
4. Miyazaki S, Nakamura H, Kajiyama T, Watanabe T, Iesaka Y. Early tissue reaction after second-generation cryoballoon ablation evaluated with intracardiac echocardiography: Evidence of acute tissue edema after ablation. *Int Heart J*. 2019;60:618-623.
5. Baran J, Lewandowski P, Smarż K, Sikorska A, Zaborska B, Kutakowski P. Acute hemodynamic and tissue effects of cryoballoon ablation on pulmonary vessels: The IVUS-Cryo study. *J Am Heart Assoc*. 2017:e005988.
6. van Rijn D, Hendriks AA, Noten AMME, van Heerebeek L, Khan M. Practical applications of concomitant pulmonary vein isolation and left atrial appendix closure device implantation. *J Am Coll Cardiol Case Rep*. 2021;3:1409-1412.
7. Fassini G, Gasperetti A, Italiano G, et al. Cryoballoon pulmonary vein ablation and left atrial appendage closure combined procedure: A long-term follow-up analysis. *Heart Rhythm*. 2019;16:1320-1326.
8. Phillips KP, Romanov A, Artemenko S, et al. Combining left atrial appendage closure and catheter ablation for atrial fibrillation: 2-year outcomes from a multinational registry. *Europace*. 2019;22:225-231.
9. Maan A, Turagam M, Dukkupati S, Reddy V. Percutaneous extraction of a migrated WATCHMAN™ device after seven months. *J Innov Card Rhythm Manag*. 2021;12:4573-4575.
10. Afzal MR, Ellis CR, Gabriels J, et al. Percutaneous approaches for retrieval of an embolized or malpositioned left atrial appendage closure device: A multicenter experience. *Heart Rhythm*. 2020;17:1545-1553.

---

**KEY WORDS** ablation, atrial fibrillation, occluder

---

 **APPENDIX** For supplemental videos, please see the online version of this paper.