



Would it have happened without Christmas? Thoracic emphysema and allergic bronchopulmonary aspergillosis in a juvenile cystic fibrosis patient with the G551D mutation receiving ivacaftor

To the Editor:

We report on a then 13-year-old female patient with cystic fibrosis (CF) compound heterozygous for the mutations G551D and N1303K. Despite a history of intermittent pulmonary colonisation with *Pseudomonas aeruginosa* and moderate pulmonary haemorrhages before initiating ivacaftor, our patient still had a good pulmonary function (forced expiratory volume in 1 s (FEV₁) 95–105% predicted) at baseline. Furthermore, she had a stable nutritional status by pancreatic enzyme replacement therapy (PERT) above 7000 IE lipase·kg⁻¹ body weight per day. Nevertheless, when the cystic fibrosis transmembrane conductance regulator (CFTR)-modulator ivacaftor was introduced in April 2013 and approved for CF patients carrying a gating mutation, *i.e.*, G551D [1–3], she improved considerably. Her pulmonary function increased by more than 20% to above average, resulting in an FEV₁ of 128% pred (3.43 L). Simultaneously, the patient reduced and eventually stopped her enzyme substitution. Yet, her nutritional status remained stable (body mass index >50th percentile) without increase in stool frequency or other clinical signs of maldigestion. In parallel, her sweat chloride improved from 87.5 to 29.6 mmol·L⁻¹ (to the normal range). It is noteworthy that she took trumpet lessons and even joined her school's big band in her leisure time.

Rather unexpectedly, on 28 December 2013, the patient was admitted to hospital for severe dyspnoea and hypoxia with only 85% transcutaneous oxygen saturation. Chest radiography ruled out new pulmonary infiltrates, albeit it revealed a cervical-thoracic emphysema (figure 1). While inhalation of β₂-agonists only had marginally positive effects, she stabilised considerably with oxygen supplementation, so that the attending physicians proceeded without a computed tomography scan. Pulmonary function testing on 29 December 2013 revealed a drop in FEV₁ to 35% pred (0.94 L) and a massive hyperinflation (residual volume 298% pred).

Initial treatment with oral ciprofloxacin did not stabilise her clinical status and microbiological cultures from sputum as well as infection parameters in blood remained negative with C-reactive protein below 5 mg·L⁻¹ and leukocyte counts within the normal range; only the proportion of eosinophils was considerably increased at 12%. Previously, the patient's total and specific IgE and IgG against *Aspergillus fumigatus* had been slightly elevated. Nevertheless, the patient's critical clinical status together with the history of changes in their living environment prompted our therapy: for a long time, the family kept a guinea pig in their living room. That year, however, they decided to place their Christmas tree in the space usually occupied by the pet's hutch. To put up the tree, the pet's cage was moved into our CF patient's bedroom, together with its hay for bedding. Presumably, the resulting exposure of the patient to



@ERSpublications

Potent CFTR modulators improve CF manifestations far beyond expectations, including reduction of risk of typical complications. This is the first report of a patient who developed life-threatening ABPA and emphysema after overwhelming improvement. <https://bit.ly/2P96PTY>

Cite this article as: Mainz JG, Erdmann N, Duckstein F, *et al.* Would it have happened without Christmas? Thoracic emphysema and allergic bronchopulmonary aspergillosis in a juvenile cystic fibrosis patient with the G551D mutation receiving ivacaftor. *ERJ Open Res* 2021; 7: 00758-2020 [<https://doi.org/10.1183/23120541.00758-2020>].

Copyright ©The authors 2021. This version is distributed under the terms of the Creative Commons Attribution Non-Commercial Licence 4.0. For commercial reproduction rights and permissions contact permissions@ersnet.org



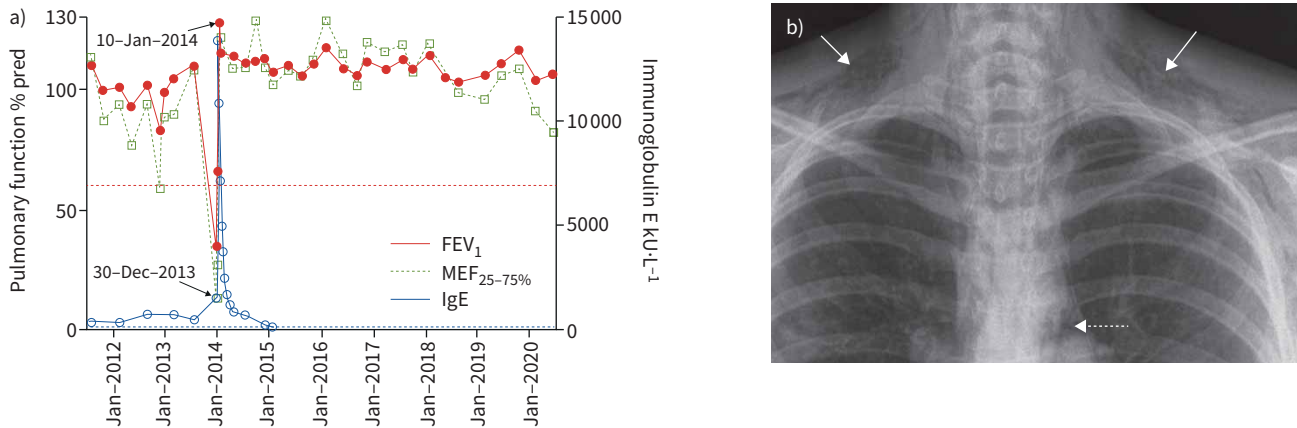


FIGURE 1 a) Changes in pulmonary function and total immunoglobulin (Ig) E related to allergic bronchopulmonary aspergillosis, and b) a thoracic radiograph, showing interstitial (lined arrows) and mediastinal (dotted arrow) emphysema on 30 December 2013. FEV₁: forced expiratory volume in 1 s; MEF: mid-expiratory flow at 25–75% of forced vital capacity.

A. fumigatus allergens in the guinea pig's bedding was a root cause for her exacerbation. To make matters worse, on Christmas Eve, unaware of her inflamed airways due to allergen-exposure, our patient played Christmas carols on her trumpet near the Christmas tree.

We initiated therapy for allergic bronchopulmonary aspergillosis (ABPA) including systemic steroid treatment combined with itraconazole. 4 days later, laboratory findings confirmed our decision: total IgE levels, which were previously slightly elevated at 517 kU·L⁻¹, skyrocketed to 13 858 kU·L⁻¹. At the same time, other markers of ABPA increased significantly (specific IgE and IgG for *A. fumigatus* from 14.80 to 54.30 kU·L⁻¹, and from 75.50 to 128 mg·L⁻¹, respectively; ABPA-specific IgE against recombinant *A. fumigatus* antigens 4 and 6: from 1.88 to 8.63 kU·L⁻¹, and from 3.44 to >100.00 kU·L⁻¹, respectively).

With cessation of allergen exposure and starting the systemic therapy, the patient stabilised considerably in the coming days, reaching FEV₁ and forced vital capacity values of 108 and 122% pred after only 2 weeks. In parallel, her total IgE, as well as all further markers for ABPA, normalised in the following months (figure 1).

The reported changes in living environment as a cause for the patient's crucial exposure to *A. fumigatus*, well-known to be abundant in hay, triggered her first manifestation of ABPA [4]. Enhanced central airway pressure when playing the trumpet added to the resulting severe airway inflammation and obstruction as key clinical symptoms of ABPA, which we surmised to be causative for her cervical and pulmonary interstitial emphysema. A combination of both prompted critical pulmonary deterioration and hypoxia, so that the patient required hospitalisation, oxygen supplementation and urgent medical treatment.

Our case report is noteworthy, as our patient had stabilised prior to this threatening exacerbation under therapy with ivacaftor to an extent beyond our and the patient's expectation: pulmonary function reached outstanding values and pancreatic function recovered to the extent that PERT could be ceased without revealing symptoms of maldigestion and weight loss.

The highly potent CFTR-modulator ivacaftor has been available for patients carrying the rare G551D mutation since 2012 [2, 3]. *In vitro*, it enhances the opening probability of defective CFTR channels in so-called gating-mutations, like G551D, by up to 50% [5]. In these patients, a dysfunctional channel is present in apical membranes of exocrine glands [6]. Despite its considerably higher complexity, such effects can now also be achieved for more than 60% of CF patients carrying the most frequent mutation F508del [7]. In patients homozygous for F508del, in the endoplasmic reticulum, the defectively folded channel protein is disposed of during intracellular CFTR processing. Now, in the USA and many European countries, the triple-combination of two potent CFTR-correctors (tezacaftor and elxacaftor) allows further processing and presence of the channel on cell surfaces in patients carrying only one F508del mutation. Here again, ivacaftor as a third component enhances the opening probability of the ion channel [7]. As with CF patients with a gating mutation treated with ivacaftor, triple modulator therapy leads to a mean increase in FEV₁ above 10%. At the same time, it allows a considerable weight gain in often malnourished patients. The future will reveal whether pancreatic insufficiency may be compensated to some extent, as a recent publication on three CF siblings carrying a G551D mutation suggests [8].

Most interestingly, our case report shows that substantial improvement of pulmonary and extrapulmonary involvement in CF patients receiving a potent CFTR-modulating therapy does not protect against ABPA,

a typical CF complication [4]. Moreover, our patient revealed the highest hyperergic immunological response on exposure to aspergillus allergens that we have seen, with IgE levels at the limit of the measurement range. Consequently, we still must consider typical CF complications like ABPA, even if under CFTR-modulator therapy patients improve to an extent seen in our juvenile patient [9–11].

Our case report contradicts expectations deriving from recent publications which suggest that recovery of CFTR function would reduce susceptibility to ABPA, as disposition for hyperergic immunological reactions, e.g. to mould.

In a mouse model, ALLARD *et al.* [12] showed that *A. fumigatus* hyphal antigen exposure in CFTR-deficient and $\Delta F508$ -mutant mice generates an enhanced T-helper (Th)2-immune response with profound lung inflammation. In humans, mutations in the *CFTR*-gene appear to be a single relevant risk factor for development of ABPA. In a systematic review, the risk for development of ABPA was calculated with an odds ratio of 10.39 (95% CI 4.35–24.79) in subjects carrying a CFTR mutation [9]. Hence, effective CFTR-modulation should be expected to reduce such a risk.

In addition, therapy with CFTR-modulators was shown to reduce CF patients' airway colonisation with *A. fumigatus* [13]. Furthermore, overshooting inflammatory responses against *A. fumigatus* was shown to decline significantly during CFTR-modulating therapies: *Aspergillus*-induced reactive oxygen species, liberated from CF patients' mononuclear (peripheral blood mononuclear cells) and polymorphonuclear cells (PMNs), were elevated in CF patients, compared with healthy controls. Remarkably, pretreatment with ivacaftor alone ($p < 0.01$) or in combination with lumacaftor ($p < 0.01$) led to a significant reduction of this overshooting inflammatory response. Therefore, CFTR modulation is expected to have immunomodulatory effects preventing *Aspergillus*-induced inflammation in CF.

However, these effects on PMNs may not be crucial in ABPA where the lymphatic system assumes a central role, with liberation of Th2 cytokines, like interleukin (IL)-4, IL-5 and IL-13, leading to abundant production of total and specific IgE and IgG antibodies by B-lymphocytes directed against *A. fumigatus* and to a hypersensitivity reaction.

In the present literature, we did not find reports on effects of CFTR-modulators on lymphatically driven hypersensitivity ABPA reactions according to type I (IgE) and type III (IgG-immunocomplexes) mediated reactions, as classified by Coombs and Gell.

In conclusion, only a combination of two factors associated with the Christmas season, *i.e.* the changes in our patient's living environment as well as her traditional Christmas carolling, caused classical CFTR-associated complications of ABPA, despite her previous substantial improvements with CFTR-modulating therapy. Further studies are required to understand these complex interactions.

Jochen G. Mainz^{1,2,3}, Nina Erdmann¹, Franziska Duckstein¹ and Carlos Zagoya¹

¹Cystic Fibrosis Center, Brandenburg Medical School (MHB) University, Klinikum Westbrandenburg, Brandenburg an der Havel, Germany. ²CF Center, Jena University Hospital, Jena, Germany. ³Faculty of Health Sciences, joint Faculty of the Brandenburg University of Technology Cottbus-Senftenberg, the Brandenburg Medical School Theodor Fontane and the University of Potsdam, Germany.

Correspondence: Jochen G. Mainz, Cystic Fibrosis Center, MHB University, Klinikum Westbrandenburg, Brandenburg an der Havel, Germany, Klinik für Kinder- und Jugendmedizin, Hochstrasse 29, 14770 Brandenburg an der Havel, Germany. E-mail: j.mainz@klinikum-brandenburg.de

Received: 16 Oct 2020 | Accepted: 20 March 2021

Acknowledgements: The authors are grateful for the patient's support and continuous interest. We thank Hans-Joachim Mentzel, Jena University Hospital, for the provision of the patient's chest radiograph.

Conflict of interest: J.G. Mainz reports grants for investigator-initiated trials from Vertex Corp. during the conduct of the study, and personal fees for advisory boards and lectures from Chiesi, Mylan and Vertex outside the submitted work. N. Erdmann has nothing to disclose. F. Duckstein has nothing to disclose. C. Zagoya has nothing to disclose.

References

- 1 Accurso FJ, Rowe SM, Clancy JP, *et al.* Effect of VX-770 in persons with cystic fibrosis and the G551D-CFTR mutation. *N Eng J Med* 2010; 363: 1991–2003.
- 2 Davies JC, Wainwright CE, Canny GJ, *et al.* Efficacy and safety of ivacaftor in patients aged 6 to 11 years with cystic fibrosis with a G551D mutation. *Am J Respir Crit Care Med* 2013; 187: 1219–1225.
- 3 Ramsey BW, Davies J, McElvaney NG, *et al.* A CFTR potentiator in patients with cystic fibrosis and the G551D mutation. *N Eng J Med* 2011; 365: 1663–1672.
- 4 Stevens DA, Moss RB, Kurup VP, *et al.* Allergic bronchopulmonary aspergillosis in cystic fibrosis – state of the art: cystic fibrosis foundation consensus conference. *Clin Infect Dis* 2003; 37: Suppl. 3, S225–S264.

- 5 Van Goor F, Hadida S, Grootenhuis PDJ, *et al.* Rescue of CF airway epithelial cell function in vitro by a CFTR potentiator, VX-770. *Proc Natl Acad Sci USA* 2009; 106: 18825–18830.
- 6 Rowe SM, Miller S, Sorscher EJ. Cystic fibrosis. *N Eng J Med* 2005; 352: 1992–2001.
- 7 Middleton PG, Mall MA, Drevinek P, *et al.* Elexacaftor-tezacaftor-ivacaftor for cystic fibrosis with a single Phe508del allele. *N Eng J Med* 2019; 381: 1809–1819.
- 8 Mainz JG, Arnold C, Hentschel J, *et al.* Effects of ivacaftor in three pediatric siblings with cystic fibrosis carrying the mutations G551D and F508del. *Arch Bronconeumol* 2018; 54: 232–234.
- 9 Agarwal R, Khan A, Aggarwal AN, *et al.* Link between CFTR mutations and ABPA: a systematic review and meta-analysis. *Mycoses* 2012; 55: 357–365.
- 10 Lebecque P, Pepermans X, Marchand E, *et al.* ABPA in adulthood: a CFTR-related disorder. *Thorax* 2011; 66: 540–541.
- 11 Mueller C, Torrez D, Braag S, *et al.* Partial correction of the CFTR-dependent ABPA mouse model with recombinant adeno-associated virus gene transfer of truncated CFTR gene. *J Gene Med* 2008; 10: 51–60.
- 12 Allard JB, Poynter ME, Marr KA, *et al.* Aspergillus fumigatus generates an enhanced Th2-biased immune response in mice with defective cystic fibrosis transmembrane conductance regulator. *J Immunol* 2006; 177: 5186–5194.
- 13 Currie AJ, Main ET, Wilson HM, *et al.* CFTR modulators dampen aspergillus-induced reactive oxygen species production by cystic fibrosis phagocytes. *Front Cell Infect Microbiol* 2020; 10: 372.