

Pancreatic Injury Caused By A Fall From Height: Transection at the Tail

Yüksekten Düşme Nedeniyle Oluşan Pankreas Yaralanması: Kuyrukta Kopma

Cem OKTAY,¹ Dilek DURMAZ,² Ozgur Onder KARADENİZ,³ Soner ISIK⁴

¹Department of Emergency Medicine, Akdeniz University Faculty of Medicine, Antalya;

²Department of Emergency Medicine, Sevkett Yılmaz Training and Research Hospital, Bursa;

³Department of Emergency, Balıkesir State Hospital, Balıkesir;

⁴Department of Emergency, Antalya Life Hospital, Antalya

SUMMARY

Isolated pancreatic injury due to blunt abdominal trauma is rare and may be clinically difficult to diagnose. Parenchymal injuries may not be recognized during initial evaluation. We report the case of a 30-year-old male presented to the Emergency Department (ED) with the complaint of persistent abdominal pain, nausea, and vomiting. His medical history revealed that he fell from a height of approximately 1.5 meters 1 day ago and hit an iron block. He was presented and discharged from another hospital ED. Contrast enhanced computerized tomography (CECT) of the abdomen was ordered during his second presentation and revealed pancreatic parenchymal contusion, laceration, and transection at the tail of pancreas. Our findings suggest that, when there is high index of suspicion for pancreatic injury, a CECT should always be ordered.

Key words: Abdominal trauma; computed tomography; pancreatic injury.

ÖZET

Künt abdominal travmaya bağlı izole pankreas yaralanması nadirdir ve klinik olarak tanı konulması zordur. Parankimal yaralanmalar ilk değerlendirme sırasında ayırt edilemeyebilir. Bu yazıda, devam eden karın ağrısı, bulantı ve kusma yakınması ile acil servise başvuran 30 yaşındaki bir hasta sunuldu. Hastanın öyküsünde bir gün önce 1.5 metre yükseklikten demir bir blok üzerine düştüğü ve başvurduğu başka bir hastanenin acil servisinden taburcu edildiği öğrenildi. İkinci başvurusu sırasında kontrastlı batın tomografisi çekildi ve pankreas parankiminde kontüzyon, laserasyon ve pankreas kuyruk kesiminde kopma tespit edildi. Pankreas yaralanmasına ait yüksek şüphe mevcut ise kontrastlı batın tomografisi her zaman istenmelidir.

Anahtar sözcükler: Karın travması; bilgisayarlı tomografi; pankreas yaralanması.

Introduction

Isolated pancreatic injury due to the blunt abdominal trauma is rare and accounts for less than 1% of all trauma admissions.^[1] Most pancreatic injuries occur in young men.^[1,2] Pancreatic injuries often accompany rapid decelerating injury and result from a direct epigastric blow that compresses the organ against the vertebral column.^[2,3] Blunt trauma

to the pancreas may be clinically difficult to diagnose and the injuries may not be recognized during initial evaluation or even surgery. Unfortunately, the rate of pancreatic complications was higher in the blunt trauma patients with a delayed diagnosis when compared with those patients diagnosed within 24 hours.^[4] We present a case with an atypical location of pancreatic injury a fall from height and

Submitted: July 01, 2013 **Accepted:** July 24, 2013 **Published online:** September 13, 2013

Correspondence: Dr. Cem Oktay. Akdeniz Üniversitesi Tıp Fakültesi, Acil Tıp Anabilim Dalı, 07059 Antalya, Turkey.

e-mail: cemoktay@akdeniz.edu.tr

© 2014 Emergency Medicine Association of Turkey. Production and Hosting by Elsevier B.V. Originally published in [2014] by Kare Publishing. This is an open access article under CC BY-NC-ND license (<http://creativecommons.org/licenses/by-nc-nd/4.0/>)

Turk J Emerg Med 2014;14(2):93-95 doi: 10.5505/1304.7361.2014.23230



late presentation. In addition, we review the importance of ordering contrast enhanced computerized tomography (CECT) for patients with persistent nonspecific symptoms following abdominal trauma.

Case Report

A 30-year-old male was presented to the emergency department (ED) of Akdeniz University Hospital with complaints of abdominal pain, nausea and vomiting. History revealed that he fell from a height of approximately 1.5 meters and hit an iron block 10 hours ago. He presented to another hospital ED soon after the event and his medical history revealed that repeated hemoglobin levels, abdominal ultrasonography (US), and abdominal computed tomography (CT) were normal. He was discharged with a diagnosis of abdominal trauma with no organ injury after a few hours of follow-up.

He presented to our ED with persistent nausea and vomiting. Initial vital signs were normal; blood pressure: 143/93 mmHg; heart rate: 84/min.; respiratory rate: 24/min.; temperature: 37.0 °C. There was an abrasion on the left upper quadrant on abdominal examination and he had tenderness at the same abdominal region, however; guarding or rebound tenderness were not noted. Initial leukocyte count and serum lipase levels were elevated (23,590/mm³ and 1419 U/L, respectively) where as his hemoglobin level was 16.3 g/dL.

US revealed free fluid accumulation of maximally 60 mm in the perihepatic, perisplenic, pelvic, and left perirenal area of the abdominal cavity. CECT of the abdomen was ordered and uncovered pancreatic parenchymal contusion, laceration, and transection at the tail of pancreas (Figure 1). The patient was admitted to the general surgery and under-

went to emergency laparotomy. Distal pancreatectomy with splenectomy was performed. His body temperature was elevated a day after the surgery and antibiotherapy was changed to imipenem/cilastatin sodium. Pleural effusion of 80 mm was noted on the left pleural space on the third day post-surgery. Respiratory disease consultation was offered to monitor the amount of fluid, since the accumulation was thought to be caused by transdiaphragmatic transition. He was discharged on the 13th day post-surgery with complete recovery.

Discussion

Blunt trauma to the pancreas usually results from road traffic accidents. For example, when an unrestrained driver is thrown onto the steering wheel or a motorcyclists or children on bicycles fall onto the handlebars. Mainly, transection occurs at the neck of the pancreas over the vertebral bodies due to the deceleration injury during blunt trauma to the epigastric region.^[2,4-7]

Patients usually present late and have minimal symptoms and signs.^[8] An early normal serum amylase does not exclude major pancreatic trauma.^[2,3,9] On the other hand, amylase levels may be elevated from nonpancreatic sources. However, persistently elevated or rising serum amylase levels should prompt further evaluation of the pancreas and other abdominal viscera.^[3]

Although abdominal US has the ability to detect small amounts of fluid in the abdomen, it misses the diaphragm, bowel, pancreatic, and solid organ injuries.

CECT is the best investigation on diagnosing pancreatic injuries and should be done in all cases with clinically suspected

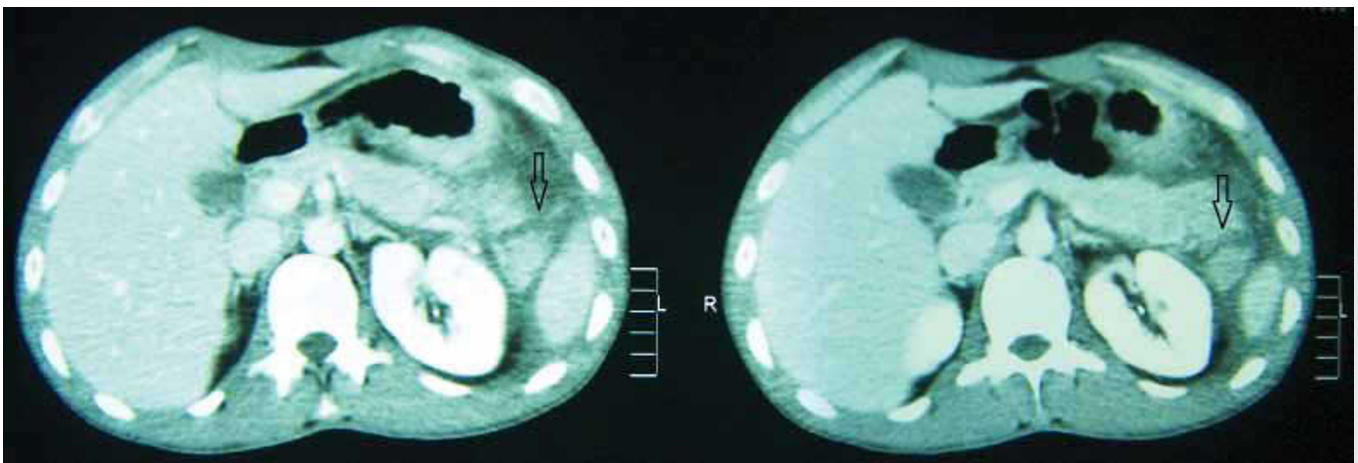


Figure 1. Axial contrast enhanced CT image of the abdomen demonstrating pancreatic parenchymal contusion, laceration and transection at the tail of pancreas (arrows).

isolated pancreatic trauma.^[2] Despite all, CT scanning may be initially normal with acute blunt pancreatic injuries. The ability of CT scanning to facilitate accurate diagnosis of pancreatic injury depends on the quality of the CT scanner, the imaging technique, the experience of the observer, and the timing of the examination.^[10] Within the first 12 h after the injury, CT scans may appear normal in a significant fraction of injuries.^[11-13] This is due to the obscuration of the fracture plane, hemorrhage, and close apposition of the pancreatic fragments.^[11,13] CT scan diagnoses of the pancreatic injuries revealed variable sensitivity and specificity because many findings are subtle, absent or, at times, slow to develop. The sensitivity and specificity of a CT scan in detecting pancreatic trauma of all grades has been reported to be around 80%.^[12-15]

Direct signs of pancreatic injury on CT include pancreatic laceration, transection, and comminution. At the site of injury or transection, fluid collections, such as hematomas, pseudocysts, and abscesses, are often seen communicating with the pancreas. Peripancreatic fluid and focal enlargement of the pancreatic tissue also suggest pancreatic injury. Useful secondary signs are peripancreatic fat stranding, hemorrhage, and fluid between the splenic vein and pancreas.^[6,9,16]

In conclusion, a high index of suspicion for isolated pancreatic injury is necessary in patients with specific upper abdominal injuries during initial ED evaluation and contrast enhanced CT should always be ordered. Repeat scanning at 12 to 24 hours should also be considered to detect an abnormality which may be initially ambiguous or subtle.

Conflict of Interest

The authors declare that there is no potential conflicts of interest.

References

1. Akhrass R, Yaffe MB, Brandt CP, Reigle M, Fallon WF Jr, Malanconi MA. Pancreatic trauma: a ten-year multi-institutional experience. *Am Surg* 1997;63:598-604.
2. Beckingham IJ, Krige JE. ABC of diseases of liver, pancreas, and biliary system: Liver and pancreatic trauma. *BMJ* 2001;322:783-5. [CrossRef](#)
3. American College of Surgeons Committee on Trauma. Advanced Trauma Life Support for Doctors. 8th ed. Chicago: American College of Surgeons; 2008. p. 111-26.
4. Kao LS, Bulger EM, Parks DL, Byrd GF, Jurkovich GJ. Predictors of morbidity after traumatic pancreatic injury. *J Trauma* 2003;55:898-905. [CrossRef](#)
5. Krige JE, Kotze UK, Hameed M, Nicol AJ, Navsaria PH. Pancreatic injuries after blunt abdominal trauma: an analysis of 110 patients treated at a level 1 trauma centre. *S Afr J Surg* 2011;49:58-64.
6. Visrutaratna P, Na-Chiangmai W. Computed tomography of blunt abdominal trauma in children. *Singapore Med J* 2008;49:352-9.
7. Mittal GS, Kumar S. Isolated pancreatic injury in case of blunt trauma abdomen. *JK Science* 2007;9:148-50.
8. Klin B, Abu-Kishk I, Jeroukhimov I, Efrati Y, Kozer E, Broide E, et al. Blunt pancreatic trauma in children. *Surg Today* 2011;41:946-54. [CrossRef](#)
9. Tan KK, Chan DX, Vijayan A, Chiu MT. Management of pancreatic injuries after blunt abdominal trauma. Experience at a single institution. *JOP* 2009;10:657-63.
10. Jurkovich GJ. The duodenum and pancreas. In: Mattox KL, Feliciano DV, Moore EE, editors. *Trauma*. 4th ed. New York: McGraw-Hill; 2000. p. 735-62.
11. Akhrass R, Kim K, Brandt C. Computed tomography: an unreliable indicator of pancreatic trauma. *Am Surg* 1996;62:647-51.
12. Cirillo RL Jr, Koniaris LG. Detecting blunt pancreatic injuries. *J Gastrointest Surg* 2002;6:587-98. [CrossRef](#)
13. Jeffrey RB Jr, Federle MP, Crass RA. Computed tomography of pancreatic trauma. *Radiology* 1983;147:491-4.
14. Almamamy HH, Guraya SY. Computed tomography for pancreatic injuries in pediatric blunt abdominal trauma. *World J Gastrointest Surg* 2012;4:166-70. [CrossRef](#)
15. Leppäniemi AK, Haapiainen RK. Risk factors of delayed diagnosis of pancreatic trauma. *Eur J Surg* 1999;165:1134-7. [CrossRef](#)
16. Milia DJ, Brasel K. Current use of CT in the evaluation and management of injured patients. *Surg Clin North Am* 2011;91:233-48. [CrossRef](#)