



Case report

Intra-abdominal propylene suture fragment leading to complete small bowel obstruction: A case report

Niharika Khanal^{a,1}, Anjila Thapa^{a,*}, Akash Raut^a, Bikal Ghimire^a, Susan Pradhan^a,
 Sujan Shrestha^b

^a Department of GI and General Surgery, MMC, IOM, Tribhuvan University, Nepal

^b Surgical Gastroenterology, Department of GI and General Surgery, MMC, IOM, Tribhuvan University, Nepal

ARTICLE INFO

Keywords:

Adhesions

Propylene

Small bowel obstruction

Laparotomy

ABSTRACT

Introduction: Propylene sutures are non-absorbable sterile surgical sutures, which when present intra-abdominally act as a foreign body leading to adhesion formation. Post-operative adhesions are a common cause of bowel obstruction, with complete closed loop obstruction presenting as a surgical emergency.

Case details: A 66-year-old man who had undergone a laparotomy for bowel obstruction two years back, presented to our emergency department with features of complete bowel obstruction. Midline laparotomy revealed propylene suture and intra peritoneal adhesions acting as a constricting band around the jejunum to be the cause.

Discussion: Adhesions are common perturbing problem after surgeries. The presence of a foreign body further incites the process of adhesion formation by causing hindrance to the fibrinolysis process. In this case, the adhesive bands acted synergistically with the encircling propylene suture material from the previous surgery in causing a complete loop obstruction.

Conclusion: Propylene sutures used in routine surgical procedures can migrate intra-abdominally, and lead to adhesion formation. Adhesions along with the non-absorbable suture can cause complete bowel obstruction.

1. Introduction

Formation of adhesive bands is a common postoperative complication frequently needing surgical intervention [1]. Small bowel obstruction amounts for approximately 20% of emergency surgeries for abdominal pain [2]. The most common cause for obstruction is intra-peritoneal adhesions [3]. Complete bowel obstruction is a severe form of obstruction characterized by absence of air or fluid in the distal small bowel. A special radiographic variant of complete obstruction is the closed loop type where two points along the course of the bowel are obstructed at close locations. The obstruction is most commonly due to a single constricting lesion pinching on the bowel segments at the root of the mesentery. This leads to a U or C loop segment as seen on imaging with no distal or proximal outlets for decompression. This sort of obstruction makes ischemia and necrosis of the bowel a likely possibility due to twisting of the incarcerated segment along the axis of obstruction [4,5]. Propylene sutures are non-absorbable sterile surgical sutures. They are commonly employed for soft tissue approximation and

ligation. Like other suture material, it too can act as a foreign material inciting the formation of adhesive bands.

Here we present the case of a patient presenting with features of bowel obstruction secondary to adhesion complicated by the presence of propylene sutures as a foreign body. The paper is in line with the SCARE 2020 criteria [6].

2. Case presentation

Our patient is a 66-year-old male, who had previously undergone an exploratory laparotomy two years back in another center for bowel obstruction. However, he was unable to provide detailed information regarding the management done. He presented to the emergency department with complaints of generalized, progressive abdominal pain for three days accompanied by four episodes of vomiting, and one episode of bright red blood per rectum approximately 1 ml in volume. The vomiting was bilious and associated with nausea. The patient had not passed feces for two days and flatus for one day, prior to

* Corresponding author.

E-mail address: anjilathapa1613@gmail.com (A. Thapa).

¹ Equal contribution and sharing first authorship.

presentation. There was no fever and bladder habits were normal. He was under medication for COPD and hypertension, and had completed treatment for pulmonary tuberculosis approximately 25 years ago.

On examination, he was tachycardic and general physical examination findings were normal. Per abdominal examination revealed an irreducible, tender swelling in the periumbilical region. An erect abdominal X-ray (Fig. 1) showing dilated proximal peripheral bowel loops, and collapsed distal ileal/large bowel loops and abdominal USG showing minimal ascites, supported our provisional diagnosis of complete small bowel obstruction with signs of strangulation. His lab parameters were as follows: TLC - 11,900/cumm, Hb - 16 g%, and Platelets - 404,000/cumm. Biochemistry revealed the following parameters: AST - 16U/L, ALT - 18U/L, ALP - 105U/L and total bilirubin - 24 μ mol/L. His INR was 1.09.

Midline laparotomy revealed multiple bands present, with 10 cm non-viable jejunum with a narrow lumen, approximately 190 cm proximal to the ileocecal junction. The foreign body i.e. prolene suture from the previous surgery was found to be encircling the nonviable jejunal segment along with the root of the mesentery (Fig. 2). The proximal bowel loops were dilated and minimal ascites was noted. Sharp dissection was used to release the bands, foreign body (prolene) removed and resection of the nonviable jejunal segment was done. Hand-sewn method was used to perform the end-to-end anastomosis following resection with full thickness interrupted absorbable polyglactin sutures used for the mucosa and interrupted 3-0 silk used for the outer seromuscular layer. A 20 Fr drain was kept in the pelvis, and the abdomen was closed in layers after securing hemostasis.

Post-operatively, NG intubation was maintained for 3 days, and oral feed was initiated after the patient started to pass flatus. His post-operative period was uneventful and was discharged on the 8th post-operative day. On follow up the patient exhibited normal wound healing with no further complications.

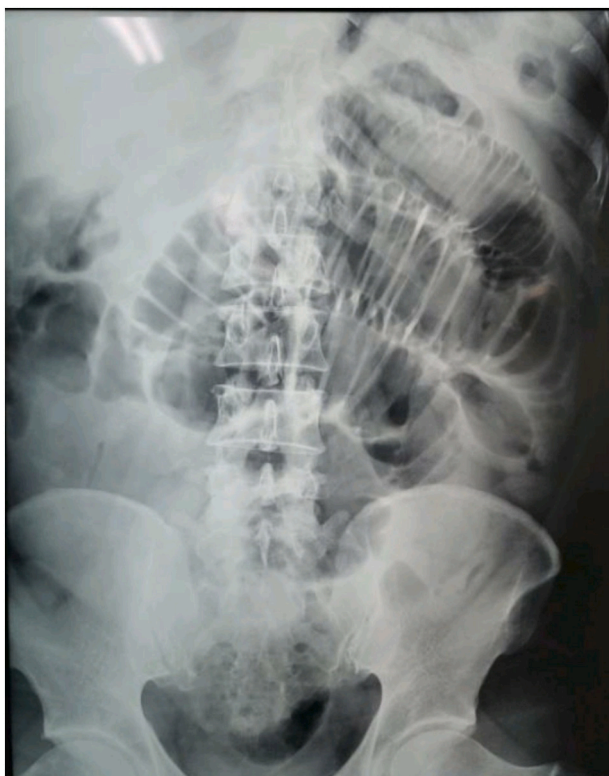

Fig. 1. Plain abdominal X-ray showing dilated proximal peripheral bowel loops, and collapsed distal ileal/large bowel loops.

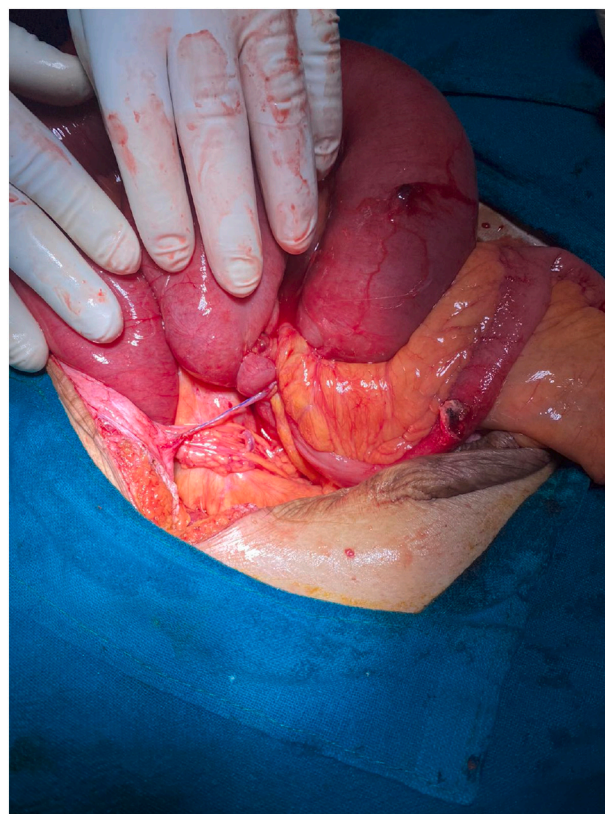


Fig. 2. Intra-abdominal adhesive band seen to be encircling the jejunum.

3. Discussion

The United States estimates 1% of all hospitalizations, 3% of emergency surgical admissions to general surgical hospitals and 4% of emergency laparotomies are done for bowel obstruction, usually secondary to adhesions [7]. In India, adhesions are listed as the most common cause of bowel obstruction followed by intestinal tuberculosis and obstructed/strangulated hernia [8]. Studies report that 93% to 100% of patients undergoing transperitoneal surgery will develop adhesions [9]. Foreign bodies such as intraperitoneal mesh, glove powder, suture material, and spilled gallstones also contribute to significant adhesion formation [10]. This correlates with our case, with adhesive bands acting synergistically with the encircling prolene suture material from the previous surgery in causing the obstruction.

Surgical incisions lead to peritoneal irritation which incites a cascade of inflammation [11]. Ideally the healing process begins just hours after the insult, leading to deposition of fibrin [12]. The healing ends with fibrinolysis and reepithelialization after a few days. This process is shackled in patients who undergo surgery because the surgical trauma decreases the amount of plasminogen activator inhibitor and tissue oxygenation [13]. The improper fibrinolysis is made worse by the presence of a foreign body, which in our case happens to be the prolene suture [14]. Prolene suture is a non-absorbable suture often used for skin closure after a laparotomy. The prolene suture encircling the closed bowel loop as a result of intra-abdominal migration is a rather unusual finding that can be attributed to either the poor surgical technique employed during the previous procedure or lack of proper wound care. Suture materials are known to evoke a foreign body reaction which makes the process of fibrinolysis more difficult [15]. The adhesions formed as a result of this are therefore bands of collagenous tissues.

Reports of bowel obstruction due to the intra-abdominal migration of barbed sutures used in laparoscopic myomectomy further support the tendency of suture materials to lead to adhesion formation and

subsequent bowel obstruction [16]. Intra-abdominal migration of mesh used in the repair of umbilical hernia via open method has been reported to cause strangulated intestinal obstruction [17]. The tendency of the mesh causing complications upon migration is dependent on the composition of the mesh with higher rates being reported in polypropylene or PTFE mesh [18].

Good surgical technique is quintessential for prevention of adhesions. Maintenance of optimum hemostasis throughout and minimal tissue handling are essential to limit peritoneal injury [19]. Packing with abrasive sponges can also incite adhesion formation. Non-reactive suture materials like silk suture have less likelihood of contributing to adhesion formation than non-absorbable sutures, which have greater tendency of causing a foreign body reaction.

Similarly, use of physical and liquid barriers also has been reported to decrease the likelihood of adhesion formation, but they increase the cost of the overall procedure and therefore are avoided in settings like ours. There are case reports where migration of the suture used in a laparoscopic myomectomy was not prevented by the use of adhesion barriers such as Sprayshield™ (Covidien, Waltham, MA), with the unraveled V-loc suture leading to obstruction of the small bowel [20]. The failure of the adhesion barriers, which work by separating opposing surfaces till reperitonization occurs is attributed to their absorption within 4 weeks, whereas most sutures used have delayed absorption periods up to 180 days [16].

The current Bologna guidelines for management of adhesive small bowel obstruction recommend initial conservative non-operative management. In cases where there is strong suspicion of bowel strangulation and necrosis, laparoscopic management can be attempted when less than two laparotomies have been performed in the past, and a single adhesive band is anticipated. The open method is also accepted as per availability of expertise and equipment [21]. We opted for an emergency laparotomy because of the clinical deterioration of the patient, complete nature of obstruction and lack of laparoscopic expertise in the Emergency Department. Adhesiolysis was supplemented by resection anastomosis due to the discovery of a non-viable jejunal segment around the adhesions and prolene.

4. Conclusion

A fragment of Polypropylene suture material can also migrate and get embedded in the bowels leading to a fibrous band formation causing intestinal obstruction.

Ethical approval

Ethical approval is not required for case reports as per our country's protocols.

Consent

Written informed consent was obtained from the patient for publication of this case report and accompanying images. A copy of the written is available for review by the Editor-In-Chief of this journal on request.

Funding

N/A.

Provenance and peer reviewed

Not commissioned, externally peer reviewed.

Author contribution

NK, and AT drafted the manuscript under the guidance of BG. BG was

the main guiding faculty. AR, SP, and SS assisted in writing and editing the manuscript. SP, SS and BG were the managing surgeons in this case. All authors contributed to the article and approved the submitted version.

Registration of research studies

N/A.

Guarantor

Anjila Thapa (corresponding author).

Declaration of competing interest

The authors declare no conflict of interest.

References

- [1] H. Ellis, B.J. Moran, J.N. Thompson, M.C. Parker, M.S. Wilson, D. Menzies, et al., Adhesion-related hospital readmissions after abdominal and pelvic surgery: a retrospective cohort study, *Lancet* 353 (9163) (1999) 1476–1480.
- [2] R.M. Gore, R.I. Silvers, K.H. Thakrar, D.R. Wenzke, U.K. Mehta, G.M. Newmark, et al., Bowel obstruction, *Radiol. Clin. N. Am.* 53 (6) (2015) 1225–1240, <https://doi.org/10.1016/j.rcl.2015.06.008>.
- [3] G. Miller, J. Boman, I. Shrier, P.H. Gordon, Etiology of small bowel obstruction, *Am. J. Surg.* 180 (1) (2000) 33–36.
- [4] E.J. Balthazar, B.A. Birnbaum, A.J. Megibow, R.B. Gordon, C.A. Whelan, D. H. Hulnick, Closed-loop and strangulating intestinal obstruction: CT signs, *Radiology* 185 (3) (1992) 769–775.
- [5] S Wills Obstruction Intestine: A New 635 636.
- [6] R.A. Agha, T. Franchi, C. Sohrabi, G. Mathew, A. Kerwan, A. Thoma, et al., The SCARE 2020 guideline: updating consensus surgical CAse REport (SCARE) guidelines, *Int. J. Surg.* 84 (2020) 226–230.
- [7] G. Miller, J. Boman, I. Shrier, P.H. Gordon, Natural history of patients with adhesive small bowel obstruction, *Br. J. Surg.* 87 (9) (2000) 1240–1247.
- [8] P. Prakash, N. Ahmad, Baittha KSL, S.R. Sinha, A. Deoraj, A. Chaudhary, Study of etiology, fatal outcome and different surgical techniques in the management of small bowel obstruction, *Acad. J. Surg.* 2 (1) (2019) 13–15.
- [9] D. Menzies, H. Ellis, Intestinal obstruction from adhesions - how big is the problem? *Ann. R. Coll. Surg. Engl.* 72 (1) (1990) 60–63.
- [10] R.W. Luijendijk, D.C.D. De Lange, C.C.A.P. Wauters, W.C.J. Hop, J.J. Duron, J. L. Pailler, et al., Foreign material in postoperative adhesions, *Ann. Surg.* 223 (3) (1996) 242–248.
- [11] B.W.J. Hellebrekers, T. Kooistra, Pathogenesis of postoperative adhesion formation, *Br. J. Surg.* 98 (11) (2011) 1503–1516.
- [12] G.S. DiZerega, J.D. Campeau, Peritoneal repair and post-surgical adhesion formation, *Hum. Reprod. Update* 7 (6) (2001) 547–555.
- [13] N.M. Fletcher, Z.L. Jiang, M.P. Diamond, H.M. Abu-Soud, G.M. Saed, Hypoxia-generated superoxide induces the development of the adhesion phenotype, *Free Radic. Biol. Med.* 45 (4) (2008) 530–536.
- [14] C.A. Cagici, O. Cakmak, N. Bal, H. Yavuz, I. Tuncer, Effects of different suture materials on cartilage reshaping, *Arch. Facial Plast. Surg.* 10 (2) (2008) 124–129.
- [15] A.M. Lock, R. Gao, D. Naot, B. Coleman, J. Cornish, D.S. Musson, Induction of immune gene expression and inflammatory mediator release by commonly used surgical suture materials: an experimental in vitro study, *Patient Saf. Surg.* 11 (1) (2017) 1–8.
- [16] Lee Etc, Wong Fws, Small bowel obstruction from barbed suture following laparoscopic myomectomy - a case report, *Int. J. Surg. Case Rep.* 16 (2015) 146–149, <https://doi.org/10.1016/j.ijscr.2015.09.039>.
- [17] B. District, W. Bengal, Asia S, *JMSCR* 3 (1) (2015) 3683–3691. January.
- [18] D. Gandhi, S. Marcin, Z. Xin, B. Asha, D. Kaswala, B. Zamir, Chronic abdominal pain secondary to mesh erosion into cecum following incisional hernia repair: a case report and literature review, *Ann. Gastroenterol.* 24 (4) (2011) 321–324.
- [19] A. Rocca, G. Aprea, G. Surfaro, M. Amato, A. Giuliani, M. Paccone, et al., Prevention and treatment of peritoneal adhesions in patients affected by vascular diseases following surgery: a review of the literature, *Open Med.* 11 (1) (2016) 106–114.
- [20] L.M. Kindinger, T.E. Setchell, T.S. Miskry, Bowel obstruction due to entanglement with unidirectional barbed suture following laparoscopic myomectomy, *Gynecol. Surg.* 9 (3) (2012) 357–358.
- [21] R.P.G. Broek, P. Krielen, S. Di Saverio, F. Coccolini, W.L. Biffi, L. Ansaloni, et al., Bologna guidelines for diagnosis and management of adhesive small bowel obstruction (ASBO), *World J. Emerg. Surg.* 13 (1) (2018) 13–24, <https://doi.org/10.1186/s13017-018-0185-2>.