

Received: 2017.10.14
Accepted: 2017.11.28
Published: 2018.05.20

Combined Coronary Artery Bypass Graft (CABG) Surgery and Lung Resection for Lung Cancer in Patients More than 50 Years-of-Age

Authors' Contribution:
Study Design A
Data Collection B
Statistical Analysis C
Data Interpretation D
Manuscript Preparation E
Literature Search F
Funds Collection G

AC 1 **Ban Liu***
CE 2 **Chao Chen***
BE 3 **Chang Gu***
BE 4 **Qifan Li***
BC 5 **Jingjing Liu**
BE 2 **Yiwei Pu**
CF 2 **Yu Lin**
BC 2 **Zilun Wei**
BC 4 **Zhi Li**
AG 5,6 **Yangyang Zhang**

1 Department of Cardiology, Shanghai Tenth Peoples' Hospital, Tongji University School of Medicine, Shanghai, P.R. China
2 The First Clinical Medical College of Nanjing Medical University, Nanjing, Jiangsu, P.R. China
3 Department of Thoracic Surgery, Shanghai Chest Hospital, Shanghai Jiao Tong University, Shanghai, P.R. China
4 Department of Cardiothoracic Surgery, The First Affiliated Hospital with Nanjing Medical University, Nanjing Medical University, Nanjing, Jiangsu, P.R. China
5 Key Laboratory of Arrhythmias of the Ministry of Education of China, East Hospital, Tongji University School of Medicine, Shanghai, P.R. China
6 Department of Cardiovascular Surgery, East Hospital, Tongji University School of Medicine, Shanghai, P.R. China

* Ban Liu, Chao Chen, Chang Gu and Qifan Li contributed equally to this work

Corresponding Author: Yangyang Zhang, e-mail: zhangyangyang_wy@vip.sina.com

Source of support: This work was funded by the Major Talent Summit of Jiangsu Province (Grant No. 2015-WSW-019), and Shanghai Science and Technology Commission Guiding Project (Grant No. 14411971000)

Background: The co-existence of coronary heart disease (CHD) and lung cancer is increasing in an increasingly aging population. The aim of this study was to evaluate patient outcome from combined off-pump coronary artery bypass graft (CABG) surgery and lung resection in patients more than 50 years-of-age.


Material/Methods: A retrospective clinical study of 23 patients with a mean age of 70.2±8.4 years (range, 51–86 years) included 18 men and five women with CHD and lung cancer who underwent a single operation with combined off-pump CABG surgery and lung resection, for non-small cell lung cancer (NSCLC) (n=22) and small cell lung cancer (n=1). Surgical approaches included: median sternotomy in six patients; left lateral thoracotomy in nine patients; a median sternotomy in three patients; median sternotomy combined with thoracoscopic lobectomy in five patients.

Results: In the retrospective study of 23 patients, there were no deaths and no new cases of myocardial infarction (MI) in the immediate perioperative period. During the follow-up period, six patients died from lung cancer metastasis or recurrence; one patient died of acute renal failure; and one patient died from the effects of chemotherapy. The remaining 15 patients underwent postoperative follow-up for between 3–79 months with no deaths and no new cases of MI.

Conclusions: For patients who are more than 50 years-of-age and who have CHD and lung cancer, a single combined operation that includes off-pump CABG and lung resection can be safe and effective.

MeSH Keywords: **Coronary Artery Bypass, Off-Pump • Lung Neoplasms • Operations Research**

Full-text PDF: <https://www.medscimonit.com/abstract/index/idArt/907545>



2774



3



1



29



Background

Worldwide, lung cancer has a high mortality rate and remains the leading cause of cancer-associated death [1]. Cigarette smoking is recognized to be the major risk factor for lung cancer, and the relationship between cigarette smoking and the risk of lung cancer has been proven for several decades [2]. In China, during the past two decades, there has been an increase in the prevalence of smoking in Chinese men, which is reported to be as high as 52.9%, leading to the increasing incidence of lung cancer [3]. In China, lung cancer in non-smoking women is mainly due to a family history lung cancer and to passive smoke inhalation from cigarettes or fires used in cooking [4]. Smoking is also one of the major risks for coronary heart disease (CHD), due to its effects on the aggregation of platelet and constriction of blood vessels [5].

The population of patients with combined lung cancer and CHD is expected to increase, and surgical treatment for both conditions is shifting to older patients due to the increasingly aging population and the improvements in patient diagnosis. It has been reported that at least 5% of patients who require lung resection due to lung cancer also require coronary artery bypass graft surgery [6].

However, the presence of CHD increases the surgical morbidity of patients with lung cancer [7]. This fact creates a clinical dilemma for surgeons on how to decide on the best treatment for with combined early lung cancer and severe CHD, but because surgical techniques have continued to improve, it is now possible to conduct combined coronary artery bypass graft (CABG) surgery and lobectomy for lung cancer in a single combined surgical procedure [8,9].

The co-existence of CHD and lung cancer is increasing in an increasingly aging population who may be at increased risk of the complications of general anesthesia. Therefore, the aim of this retrospective clinical study was to evaluate patient outcome from combined off-pump CABG surgery and lung resection for lung cancer in patients more than 50 years-of-age in a single center in China.

Material and Methods

Patients

All patients included in the study, or their legal representatives, signed written informed consents to participate in the study and for all surgical procedures. The study was approved by the local Institutional Review Board (IRB) of the First Affiliated Hospital, Nanjing Medical University, China. All

clinical procedures were performed in accordance with current clinical guidelines and regulations.

A retrospective clinical study included 23 patients who were diagnosed with lung cancer and severe coronary heart disease (CHD) and who underwent combined surgical treatment between May 2009 and December 2016. The patients in the study had a mean age of 70.2 ± 8.4 years (range, 51–86 years) and included 18 men and five women with CHD and lung cancer. All patients underwent a single operation with combined off-pump coronary artery bypass graft (CABG) surgery and lung resection, for non-small cell lung cancer (NSCLC) (n=22) and small cell lung cancer (n=1).

Patients who were selected for the study were symptomatic, with symptoms that included a cough, chest pain or chest discomfort after exercise. Clinical examination, blood serum analysis, and cardiac echocardiography were performed for all patients. Each patient underwent coronary angiography, and pre-operative evaluation by positron emission tomography (PET) or computed tomography (CT) imaging, or combined PET/CT imaging, pulmonary function tests, or bronchoscopy.

More than half of the patients (n=15) included in the study had a triple-vessel coronary artery disease (CAD). Echocardiography showed that the average left ventricular ejection fraction (LVEF) was 64.38%. Patients with lung cancer were classified and staged pre-operatively in accordance with the 2001 World Health Organization (WHO) classification of lung tumors and using the TNM staging system [10]. Of the 23 patients included in the study, 61% of the patients had stage I lung cancer (14 patients). The clinical characteristics of the patients included in the study are summarized in Table 1.

The combined surgical procedure

Surgery was performed under general anesthesia with double-lumen endotracheal tube intubation. The lung and cardiac surgical procedures were carried out simultaneously. Coronary anastomoses were performed first on the beating heart using off-pump CABG surgery, followed by the lobectomy for resection of lung cancer.

The CABG procedure included harvesting of an arterial or venous graft followed by aortocoronary bypass graft implantation. All the patients received complete coronary revascularization. Single left internal mammary artery (LIMA) was used in one patient who had stenosis of the left anterior descending (LAD) coronary artery; both the LIMA and a saphenous vein graft (SVG) were used in nine patients; the saphenous vein graft (SVG) alone was used in 12 patients; both the SVG and the radial artery was used in one patient.

Table 1. Characteristics of patients underwent combined off-pump coronary artery bypass grafting and pulmonary resection.

Preoperative variables	Number of patients (means ±SD or%)
Age(y, mean ±SD)	51–86 (70.2±8.4)
Female (n,%)	5 (22)
NYHA class (n,%)	
I	3 (13.0)
II	18 (78.3)
III	2 (8.7)
Comorbidities (n,%)	
Hypertension	15 (65.2)
Hyperlipidemia	2 (8.7)
Diabetes mellitus	7 (30.4)
Cerebrovascular artery disease	13 (56.5)
Smoking (n,%)	13 (56.5)
CAD Class (n,%)	
Stable angina	19 (82.6)
Unstable angina	4 (17.4)
Number of disease vessels (n, mean ±SD)	1–3 (2.6±0.7)

SD – standard deviation; NYHA – New York Heart Association; CAD – coronary artery disease.

Surgical approaches included: median sternotomy in six patients; left lateral thoracotomy in nine patients; a median sternotomy in three patients; median sternotomy combined with thoracoscopic lobectomy in five patients. The thoracoscopic lobectomy was performed through three incisions, without rib spreading, with a working incision of between 2.5–4.0 cm in length. The thoracoscopic lobectomy procedures were performed by a standardized three port anterior approach, as previously described by Hansen et al. [11]. A complete lymphadenectomy was performed, if necessary. To achieve complete lymph node dissection, the operating table was rotated to provide an improved visual operative field. Video-assisted thoracoscopic surgery (VATS) was used with headlamp auxiliary lighting. The details of the lung resection and the number of anastomosed vessels are summarized in Table 2.

Separate pleural and mediastinal drainage tubes were used in all patients at the end of the surgical procedure, and low molecular-weight heparin (LMWH) was given to all patients until

hospital discharge. Treatments to prevent platelet aggregation included acetylsalicylic acid (ASA), ticagrelor, or clopidogrel were commenced.

Patient follow-up

The patients were all followed up postoperatively at one month, three months, and at six months after hospital discharge. At follow-up, all patients underwent a physical examination, electrocardiogram (ECG), chest X-ray, and echocardiography. After the first six months of follow-up, patients were followed up every six months, either through clinic attendance, or by telephone interview.

Statistical analysis

The JMP Pro 11 statistical software program (SAS Institute, Cary, NC, USA) was used for statistical analysis. The Kaplan–Meier method was used to analyze patient overall survival (OS).

Results

Patient morbidity and mortality

This study included 23 patients with a mean age of 70.2±8.4 years (range, 51–86 years) and included 18 men and five women with CHD and lung cancer. The combined surgical procedures were carried out in a group of patients more than 50 years-of-age.

No early postoperative patient mortality occurred, and no myocardial ischemia occurred. The mean operation time was 333.6±89.8 minutes, and the quantity of intraoperative bleeding was 613.0±358.4 ml. The mean drainage from the drainage tubes during the first 24 hours postoperatively was 392.2±296.0 ml. The chest tubes and mediastinal drains were maintained for three days postoperatively, or longer if the daily drainage was >150 ml.

The mean length of hospital stay was 19.2±12.3 days, with a mean duration of stay in the intensive care unit (ICU) of 40.4±32.4 hours. During the period of hospitalization, two patients required a re-thoracotomy for postoperative bleeding. One patient had a sternal dehiscence and a sudden cardiac arrest, five days following surgery, diagnosed as a postoperative pulmonary thromboembolism, and was resuscitated successfully by rescued by cardiopulmonary resuscitation (CPR). There was one case of postoperative acute renal failure, treated with hemofiltration. There were two patients who were re-admitted to ICU for atrial fibrillation and acute respiratory failure. All patients recovered and were discharged from the hospital. The details of the peri-operative course of the patients in the study are shown in Table 3.

Table 2. Surgery variables of patients underwent combined off-pump coronary artery bypass grafting and pulmonary resection.

Case	Histology/staging	Cardiac procedure	Lung procedure	Incision
1	Adenocarcinoma/I A	CABG×2	LUL	Median sternotomy and left lateral thoracotomy
2	Squamous cell lung cancer/II A	CABG×4	LUL	Median sternotomy and left lateral thoracotomy
3	Adenocarcinoma/I B	CABG×2	RML	Median sternotomy and right lateral thoracotomy
4	Adenocarcinoma/III A	CABG×4	LLL	Median sternotomy
5	Adenocarcinoma/I B	CABG×3	Right upper + lower WR	Median sternotomy
6	Adenocarcinoma/III A	CABG×4	LLL	Left lateral thoracotomy
7	Adenocarcinoma/III A	CABG×1	LLL	Left lateral thoracotomy
8	Adenocarcinoma/I B	CABG×3	Left upper + right upper WR	Median sternotomy
9	Adenocarcinoma/II B	CABG×3	LLL	Left lateral thoracotomy
10	Squamous cell lung cancer/I A	CABG×1	Left pneumonectomy	Left lateral thoracotomy
11	Adenocarcinoma/IA	CABG×4	RUL	Median sternotomy and thoracoscopic lobectomy
12	Adenocarcinoma/IB	CABG×2	LLL	Left lateral thoracotomy
13	Small cell lung cancer/IA	CABG×4	Right upper WR	Median sternotomy
14	Adenocarcinoma/III A	CABG×3	LLL	Left lateral thoracotomy
15	Adenocarcinoma/IA	CABG×2	RLL	Median sternotomy and thoracoscopic lobectomy
16	Squamous cell lung cancer/I B	CABG×2	Left pneumonectomy	Left lateral thoracotomy
17	Adenocarcinoma/III A	CABG×4	Right lower WR	Median sternotomy and thoracoscopic lobectomy
18	Squamous cell lung cancer/III A	CABG×2	LUL	Left lateral thoracotomy
19	Adenocarcinoma/II B	CABG×3	RUL	Median sternotomy
20	Squamous cell lung cancer/I B	CABG×2	Right upper WR	Median sternotomy
21	Squamous cell lung cancer/I B	CABG×2	Right lower WR	Median sternotomy and thoracoscopic lobectomy
22	Squamous cell lung cancer/I A	CABG×3	LLL	Left lateral thoracotomy
23	Adenocarcinoma/I A	CABG×2	RLL	Median sternotomy and thoracoscopic lobectomy

CABG – coronary artery bypass grafting; LLL – left lower lobectomy; LUL – left upper lobectomy; RLL – right lower lobectomy; RUL – right upper lobectomy; WR – wedge resection; RML – right middle lobectomy.

Patient follow-up

During the follow-up period, six patients died from lung cancer metastasis or recurrence; one patient died of acute renal failure; and one patient died from the effects of chemotherapy. The remaining 15 patients underwent postoperative follow-up for between 3–79 months with no deaths and no new cases of MI.

No case was lost to follow-up. No patient had cardiovascular events, including MI, sustained ventricular tachycardia, heart failure, or sudden cardiac death postoperatively. There were eight patients who died during the follow-up, of whom, one patient died of acute renal failure three months postoperatively, and one patient died due to intolerance to chemotherapy five months postoperatively.

Table 3. Surgical outcomes and postoperative complications.

Variables	Interquartile range/number	Means ±SD/%
Operation time (hour)	155–470	333.6±89.8
Intraoperative blood loss (ml)	200–2000	613.0±358.4
Postoperative drainage (ml)	580–9390	3066±2215
Time of ICU (hours)	14.8–114.4	40.4±32.4
Time of hospital stay (days)	8–57	19.2±12.3
Overall complications		
Absent	17	73.9
Present	6	26.1
Bleeding (n)	2	8.7
Sternal dehiscence (n)	1	4.3
Renal failure (n)	1	4.3
Acute respiratory failure	1	4.3
Atrial fibrillation (n)	1	4.3

SD – standard deviation; ICU – Intensive Care Unit.

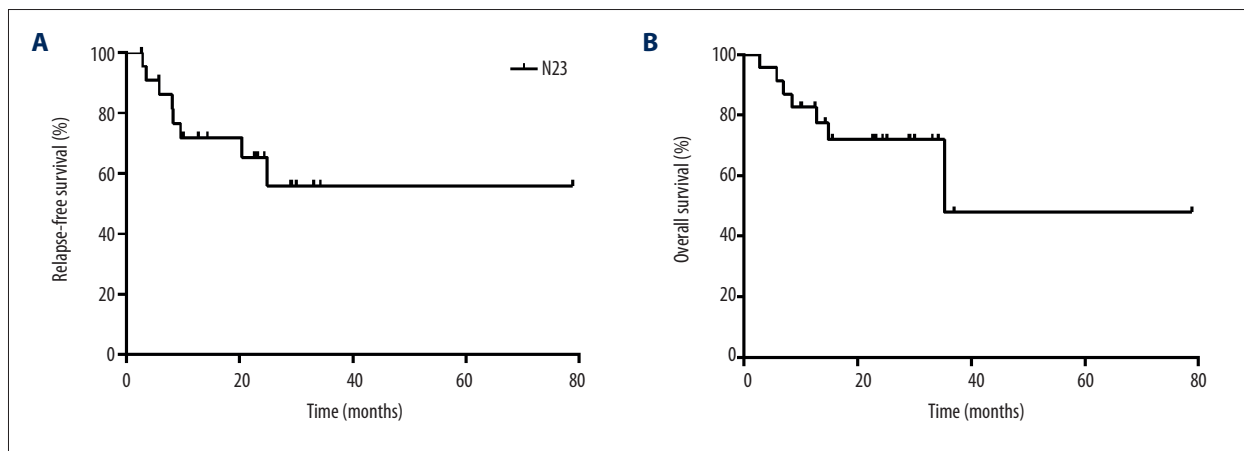


Figure 1. Kaplan-Meier survival curves for relapse free survival (A) and overall survival (B) according to the patients in our study.

Of the six patients who died of cancer metastasis or cancer recurrence, death occurred at between 7–35 months postoperatively. Of the patient deaths at follow-up from lung cancer, four patients were diagnosed as lung cancer stage IIIA, one patient as stage IIB, two patients as stage IB, and one patient had stage IA lung cancer.

The remaining 15 patients who survived at the end of the study were followed-up from between 3–79 months, with a median follow-up period of 22.7 months. The 5-year survival rate was 47.9% according to the Kaplan-Meier survival analysis (Figure 1).

Discussion

Cardiovascular disease and lung cancer are both associated with cigarette smoking, which has become more common in China. Prompt treatment of coronary heart disease (CHD) is required to minimize the perioperative risk of the lung surgery for lung cancer. However, it can be difficult to treat patients who require both cardiac surgery and lung resection for lung cancer at the same time, especially for patients with severe CHD [12,13].

Recent advances in surgical techniques have led to an increase in the proportion of patients with CHD undergoing percutaneous coronary intervention (PCI). The early and mid-term

outcomes of patients with CHD following treatment with PCI or coronary artery bypass graft (CABG) have been investigated in a propensity-matched study, which showed that although PCI was associated with lower rates of periprocedural stroke, major bleeding, and acute renal injury, CABG was associated with reduced rates of early and late recurrent ischemia and reduced repeat revascularization procedures [14]. Therefore, stent placement should be avoided in patients who are being considered for surgery soon after coronary intervention. Previously reported studies have shown a preference for a two-stage procedure, where coronary intervention is performed first, followed by lung resection with surgical treatment requiring an interval of between six and 12 weeks after coronary stenting [15].

When lung cancer has been diagnosed, surgical resection should be performed as soon as possible. Patients also require intensive anticoagulation following coronary artery stenting, but this is associated with a high risk for hemorrhagic complications. The high coagulation state associated with malignancy may also influence the patency of the coronary artery stent [16]. If the CABG is performed first, the postoperative recovery period required may also postpone the surgery for lung resection, which may result in tumor progression. However, if lung tumor resection surgery is performed first, the perioperative risk of severe coronary artery impairment can cause fatal complications [17]. The two-stage approach also requires two rounds of general anesthesia, two separate chest incisions, and a longer overall hospital stay. It may be difficult to persuade patients to undergo further surgical procedures in a relatively short period. Therefore, simultaneous management of both diseases can avoid the need for a second operation, decrease perioperative stress and pain, and may have economic benefits by decreasing treatment costs and the costs of hospital stay [18].

In this study, a one-stage approach was used, and off-pump CABG was performed. The mid-term mortality and long-term morbidity between off-pump CABG and on-pump coronary revascularization were comparable. However, extracorporeal circulation can increase the concentration of free oxygen radicals, which leads to cell damage [19], inhibits the immune system, enhances tumor growth, and can promote tumor metastases [20]. Off-pump CABG can reduce bleeding during tumor resection, due to the decreased intraoperative heparin dose. CABG is usually performed first, as it is the most aseptic of the two surgical procedures. Also, when CABG is performed first, it can ensure that there is an adequate intraoperative coronary artery blood supply to avoid intraoperative myocardial ischemia and cardiac dysfunction.

The CABG procedure often requires a median sternotomy, which fully exposes the heart and major cardiac vessels, and offers the opportunity to undertake revascularization in a timely way

when there is myocardial ischemia. However, lung cancer resection with a median sternotomy may be associated with technical problems, as left lower lobectomy is difficult to perform through a median sternotomy. The use of a two-incision approach to open both pleural cavities can lead to significant postoperative discomfort, more pain and an increased incidence of early postoperative complications. In this study, performed in a single center, the clinical experience of the surgeons resulted in the use of a single incision approach for the combined surgical procedures. Two surgical approaches were used in three patients, who received a medial sternotomy and lateral thoracotomy; single surgical incisions were used in 15 patients, of whom six patients underwent median sternotomy, and nine patients underwent lateral thoracotomy. The single left lateral thoracotomy was performed for the CABG and left lower lobectomy or left pneumonectomy. Five patients underwent a median sternotomy and video-assisted thoracoscopic surgery (VATS) as an approach for CABG and right lobectomy. In general, the tumor size and localization determine the surgical approach of the one-stage operation.

Thoracoscopic equipment was used to minimize the incision size and minimize postoperative pain. A previous study has shown that evaluation of postoperative pain, according to the visual analog scale (VAS) of Scott-Huskisson, showed that median sternotomy was less painful than posterolateral thoracotomy [21]. The use of the internal mammary artery retractor and auxiliary thoracoscopic equipment allowed improved vision of the hilar and mediastinal anatomy. The use of disposable tracheal endoscopic and vascular closure devices used in the lobectomy allowed for easier and safer surgical resection, and avoided contamination from the pulmonary resection to the CABG. Because previous studies have shown that thoracoscopic lobectomy was superior in terms of length of stay, postoperative pain, preserving pulmonary function, and postoperative complications when compared with open lobectomy [22,23], in this study, technology was used that was most appropriate for the patients clinically. The surgical approach for the CABG procedures was determined by the degree and extent of the coronary artery occlusions; arterial and venous grafts were both used, and the left internal mammary artery (LIMA) was used, as in many CABG procedures.

In this study, there was no postoperative in-hospital mortality. However, previously published studies have shown an in-hospital mortality of the combined surgical procedure of between 0–6.5% [24,25]. In this study, the postoperative complications were monitored. There were two patients who required re-exploration for postoperative bleeding. Postoperative acute renal failure is mainly determined by the degree of the surgical trauma and the preoperative renal function. Patients with lung cancer and who underwent harvesting of the LIMA as a graft may have had impaired healing of the sternotomy incision,

resulting in sternal dehiscence. Pulmonary embolism is highly influenced by the increased coagulation state in patients with cancer. In this study, cardiac arrhythmia and acute respiratory failure occurred in one patient (4.3%). In this study, all postoperative complications were diagnosed quickly and treated appropriately.

The findings of this study are supported by previous studies that have shown that the one-stage approach did not increase the surgical trauma and affect postoperative recovery [26]. The cumulative survival rate in this study was 47.9% at five years. Previous studies have reported 5-year overall survival rate that varied from 64–67% [18,27]. The overall 5-year survival rate of stage I–III lung cancer is 60–80%, 40–60%, and 6.7–20.8%, respectively [28,29]. The reasons for the lower survival rate from lung cancer in our hospital are believed to be that there were up to 26% of patients included in this study who were diagnosed with stage III lung cancer, and more lobectomy cases (65.2%) were included, compared with previously published studies.

This study had several limitations, as it was a small, non-controlled, retrospective study that was performed at a single center. Future large-scale, multicenter, controlled clinical studies are recommended.

References:

1. Siegel RL, Fedewa SA, Miller KD et al: Cancer statistics for Hispanics/Latinos, 2015. *Cancer J Clin*, 2015; 65(6): 457–80
2. Doll R, Hill AB: Smoking and carcinoma of the lung; Preliminary report. *Br Med J*, 1950; 2(4682): 739–48
3. Yang G: Global Adult Tobacco Survey (GATS) China 2010 Country Report, 2011
4. Yu YW, Wang CP, Han YF et al: [Meta-analysis on related risk factors regarding lung cancer in non-smoking Chinese women]. *Zhonghua Liu Xing Bing Xue Za Zhi*, 2016; 37(2): 268–72 [in Chinese]
5. Shah PK, Helfant RH: Smoking and coronary artery disease. *Chest*, 1988; 94(3): 449–52
6. Dyszkiewicz W, Jemielity MM, Piwkowski CT et al: Simultaneous lung resection for cancer and myocardial revascularization without cardiopulmonary bypass (off-pump coronary artery bypass grafting). *Ann Thorac Surg*, 2004; 77(3): 1023–27
7. Ciriaco P, Carretta A, Calori G et al: Lung resection for cancer in patients with coronary arterial disease: analysis of short-term results. *Eur J Cardiothorac Surg*, 2002; 22(1): 35–40
8. Yang Y, Xiao F, Wang J et al: Simultaneous surgery in patients with both cardiac and noncardiac diseases. *Patient Prefer Adherence*, 2016; 10: 1251–58
9. Elami A, Korach A, Rudis E: Lung cancer resection or aortic graft replacement with simultaneous myocardial revascularization without cardiopulmonary bypass. *Chest*, 2001; 119(6): 1941–43
10. Brambilla E, Travis WD, Colby TV et al: The new World Health Organization classification of lung tumours. *Eur Respir J*, 2001; 18(6): 1059–68
11. Hansen HJ, Petersen RH, Christensen M: Video-assisted thoracoscopic surgery (VATS) lobectomy using a standardized anterior approach. *Surg Endosc*, 2011; 25(4): 1263–69
12. Mann DL, Krone RJ: Cardiac disease in cancer patients: an overview. *Prog Cardiovasc Dis*, 2010; 53(2): 80–87
13. Chan J, Rosenfeldt F, Chaudhuri K, Marasco S: Cardiac surgery in patients with a history of malignancy: Increased complication rate but similar mortality. *Heart Lung Circ*, 2012; 21(5): 255–59
14. Ben-Gal Y, Moses JW, Mehran R et al: Surgical versus percutaneous revascularization for multivessel disease in patients with acute coronary syndromes: Analysis from the ACUITY (Acute Catheterization and Urgent Intervention Triage Strategy) trial. *JACC Cardiovasc Interv*, 2010; 3(10): 1059–67
15. Chassot PG, Delabays A, Spahn DR: Preoperative evaluation of patients with, or at risk of, coronary artery disease undergoing non-cardiac surgery. *Br J Anaesth*, 2002; 89(5): 747–59
16. Kaluza GL, Joseph J, Lee JR et al: Catastrophic outcomes of noncardiac surgery soon after coronary stenting. *J Am Coll Cardiol*, 2000; 35(5): 1288–94
17. Lonsky V, Stetina M, Habal P, Markova D: Congenital absence of the left pericardium in combination with left pulmonary artery hypoplasia, right aortic arch, and secundum atrial septal defect. *Thorac Cardiovasc Surg*, 1992; 40(3): 155–57
18. Rao V, Todd TR, Weisel RD et al: Results of combined pulmonary resection and cardiac operation. *Ann Thorac Surg*, 1996; 62(2): 342–46
19. Utoh J, Yamamoto T, Miyauchi Y: Is an increase in neutrophil leukotriene-generating capacity a specific phenomenon for cardiopulmonary bypass? *J Thorac Cardiovasc Surg*, 1995; 110(1): 276–77
20. Byrne JG, Leacche M, Agnihotri AK et al: The use of cardiopulmonary bypass during resection of locally advanced thoracic malignancies: A 10-year two-center experience. *Chest*, 2004; 125(4): 1581–86
21. Omran N, Habal P, Mandak J, Chek JL: Broncho-pleural fistula following vacuum-assisted closure therapy. *J Card Surg*, 2013; 28(4): 397–98
22. Onaitis MW, Petersen RP, Balderson SS et al: Thoracoscopic lobectomy is a safe and versatile procedure: Experience with 500 consecutive patients. *Ann Surg*, 2006; 244(3): 420–25
23. Swanson SJ, Herndon JE 2nd, D'Amico TA et al: Video-assisted thoracic surgery lobectomy: Report of CALGB 39802 – a prospective, multi-institution feasibility study. *J Clin Oncol*, 2007; 25(31): 4993–97
24. Brutel de la Riviere A, Knaepen P, Van Swieten H et al: Concomitant open-heart surgery and pulmonary resection for lung cancer. *Eur J Cardiothorac Surg*, 1995; 9(6): 310–14

Conclusions

The findings of this retrospective clinical study have shown that for patients who are more than 50 years-of-age and who have coronary heart disease (CHD) and lung cancer, a single combined operation that includes off-pump coronary artery bypass graft (CABG) surgery and lung resection can be safe and effective. These findings applied particularly to patients with early-stage lung cancer and when thoracoscopic equipment was used to minimize the incision size and reduce postoperative pain.

Acknowledgements

We wish to thank Prof. Yongfeng Shao, Prof. Xiaowei Wang, Dr. Jianwei Qin, Dr. Yanhu Wu, Dr. Lei Wei, Dr. Weidong Gu, Dr. Jinfu Zhu, Dr. Xiaohu Lu, Dr. Xiang Liu, Dr. Xiangxiang Zheng, Dr. Haoliang Sun, Dr. Luyao Ma, Dr. Yihu Tang and Dr. Wei Zhang for help given in this study.

Conflict of interest

None.

25. Schoenmakers MC, van Boven WJ, van den Bosch J, van Swieten HA: Comparison of on-pump or off-pump coronary artery revascularization with lung resection. *Ann Thorac Surg*, 2007; 84(2): 504–9
26. Kovacicova K, Omran N, Mandak J: Combined surgical treatment of lung cancer and heart diseases. *Bratisl Lek Listy*, 2014; 115(12): 776–80
27. Ma X, Huang F, Zhang Z et al: Lung cancer resection with concurrent off-pump coronary artery bypasses: Safety and efficiency. *J Thorac Dis*, 2016; 8(8): 2038–45
28. Gorenstein LA, Sonett JR: The surgical management of stage I and stage II lung cancer. *Surg Oncol Clin N Am*, 2011; 20(4): 701–20
29. Chen XR, Liang JZ, Ma SX et al: Consolidation chemotherapy improves progression-free survival in stage III small-cell lung cancer following concurrent chemoradiotherapy: A retrospective study. *Onco Targets Ther*, 2016; 9: 5729–36