



## Pectoralis major tendon reconstruction using an iliotibial band autograft



Kyle J. Decker, BS<sup>a,\*</sup>, Philip G. Ghobrial, BS<sup>a</sup>, Steven C. Chudik, MD<sup>b,c,d,e</sup>

<sup>a</sup>Loyola University Chicago Stritch School of Medicine, Maywood, IL, USA

<sup>b</sup>Hinsdale Orthopaedics, Westmont, IL, USA

<sup>c</sup>Orthopaedic Surgery and Sports Medicine Teaching and Research Foundation, Westmont, IL, USA

<sup>d</sup>Illinois Bone and Joint Institute, Chicago, IL, USA

<sup>e</sup>AMITA Health, La Grange, IL, USA

### ARTICLE INFO

#### Keywords:

Pectoralis major tendon  
chronic rupture  
reconstruction  
iliotibial band  
autograft

Rupture of the pectoralis major (PM) tendon is an uncommon injury that is most frequently observed in young men between the ages of 20 and 40 years.<sup>3</sup> The incidence of PM tendon rupture has risen significantly in the past decade and has been attributed to the increasing popularity of both weight lifting for fitness and anabolic steroids use.<sup>3</sup> Clinical manifestations of PM tendon rupture include pain, ecchymosis, asymmetry of the anterior axillary fold, and shortening deformity of the retracted muscle.<sup>3,10</sup> Magnetic resonance imaging can be helpful for diagnosis, but visualization of the torn PM tendon can be difficult, especially in the chronic presentation; therefore, careful history and clinical examination are important to avoid a misdiagnosis.

The chronicity of the injury is an important factor that influences the ability to technically repair the PM tendon. Acute PM tendon ruptures can be managed operatively or non-operatively, with operative repair displaying clinically superior improvements in functional status, isokinetic strength, isometric strength, cosmesis, and the degree of resting deformity.<sup>5,10</sup> In chronic ruptures, however, primary repair is often more challenging owing to degradation in tendon quality and associated muscle retraction and atrophy. In such cases, significant involution of the PM tendon can render primary repair impossible; thus, complete reconstruction of the deficient tendon is often the most viable treatment.<sup>6,17,19</sup>

Various operative techniques for PM tendon reconstruction have been successful for treating chronic PM ruptures with the

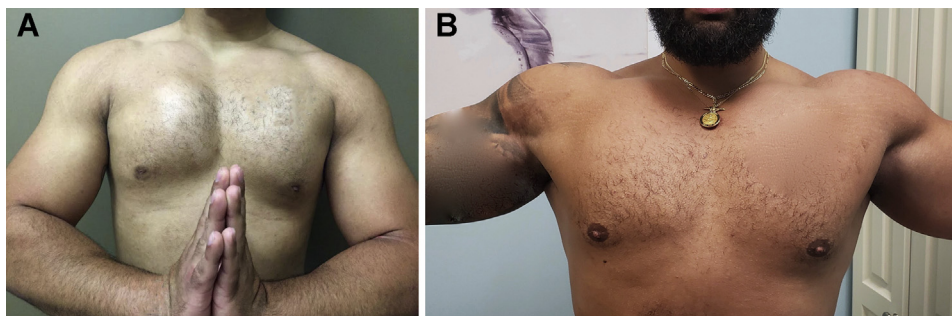
utilization of hamstring autografts, bone patellar tendon autografts, Achilles tendon allografts, hamstring tendon allografts, and dermal allografts.<sup>2,7,8,13,15,17,20</sup> This case report describes the reconstruction of a chronically ruptured PM tendon using an autologous iliotibial band (ITB) graft. The decision to reconstruct the tendon using an autologous ITB graft developed from its availability, ease of harvest, low donor-site morbidity, biocompatibility, and the ability to fashion it into similar band-like dimensions of the PM tendon.

### Case report

A 23-year-old man presented to our clinic with a chief complaint of a right shoulder injury and persistent weakness. The injury occurred 6 months before his initial visit when he experienced a sudden and audible “pop” in his right shoulder during the eccentric phase of a bench press lift. After the swelling and ecchymosis resolved, he was unable to regain his strength, particularly when performing the bench press. Physical examination of the right shoulder revealed an anterior axillary deformity, medial retraction of the PM muscle with simulated contraction, tenderness of the PM tendon insertion, and full passive range of motion (Fig. 1, A). Strength testing showed weakness in scapular protraction (4 of 5) with pain. Adduction, internal rotation, and external rotation strength were normal (5 of 5). He was neurovascularly intact. He was diagnosed with a chronic PM tendon rupture, and treatment options were discussed with him including the potential need for a graft to reconstruct the tendon.

\* Corresponding author: Kyle J. Decker, BS, 1300 N Milwaukee Ave., Chicago, IL 60622, USA.

E-mail address: [Kdecker3@luc.edu](mailto:Kdecker3@luc.edu) (K.J. Decker).

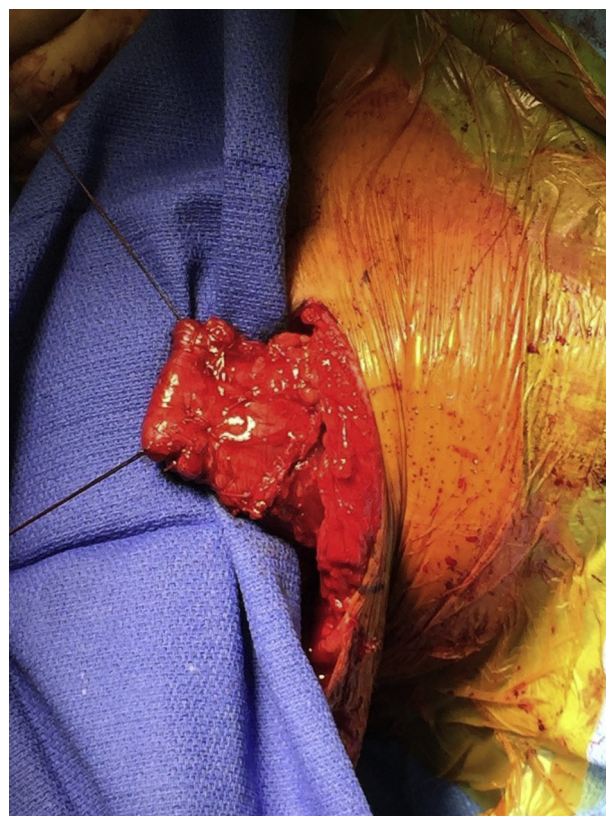


**Figure 1** A, Preoperative photo taken 1 day before surgery with loss of anterior axillary fold. B, Postoperative photo taken 2 years after surgery with restored cosmesis.

### Surgical technique

The chronic nature of the tear potentially required reconstruction with a free soft-tissue graft, so open reconstruction of the PM tendon using a contralateral autologous ITB graft was planned. He was placed in the beach-chair position, and the right shoulder and chest were prepared, draped, and sealed with an adhesive iodine impregnated drape with the right arm free. The lateral aspect of the contralateral left thigh was also prepared, draped, and sealed with an adhesive iodine impregnated drape for potential ITB graft harvest. A limited incision was made over the anterior shoulder along the deltopectoral interval to expose the PM insertion site for hardware placement. The deltopectoral interval was opened, and the full length of the insertion site on the humerus was identified just lateral to the biceps groove and prepared with a curette. The intervening scar tissue was followed with medial dissection both deep and superficial to mobilize the retracted muscle of the PM. The tendinous portion was essentially absent beyond the muscle, and therefore, tendon reconstruction was required to regain sufficient length to reach the insertion and help grasp the remaining medial musculotendinous tissue. The shoulder wound was packed with antibiotic-soaked laparotomy gauze sponge and our attention turned to the ITB graft harvest site.

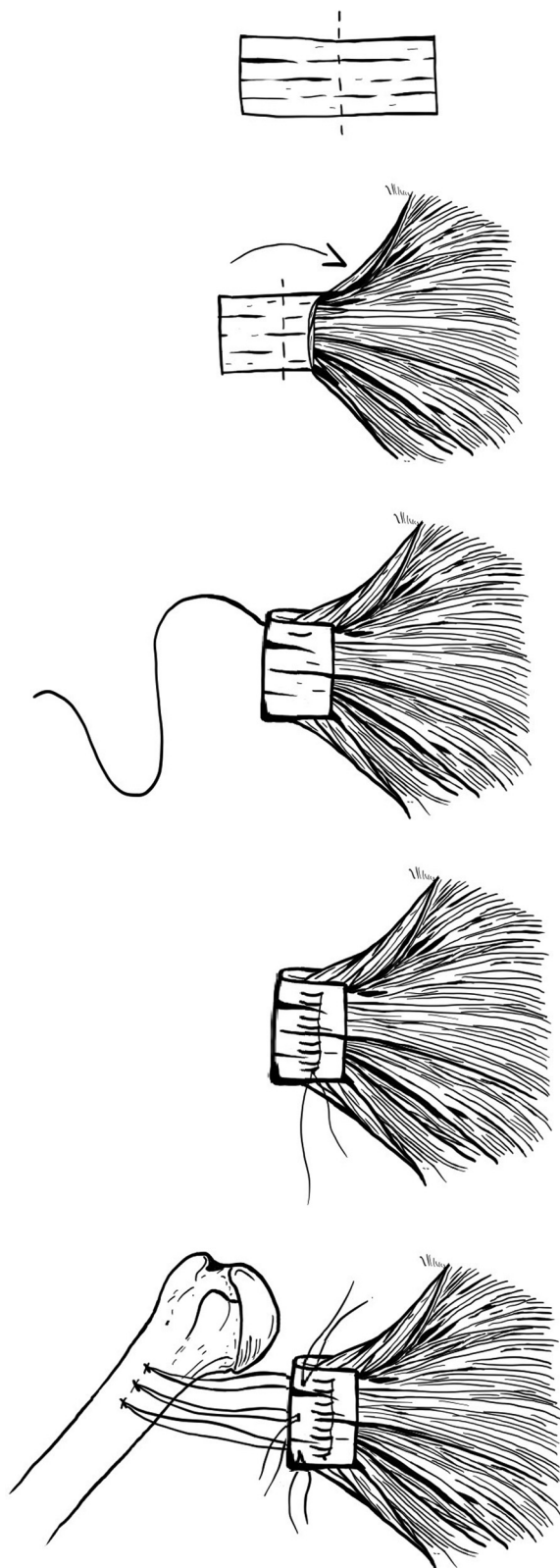
The autologous ITB graft harvest was performed by sharply longitudinally incising the skin over the lateral aspect of the mid-thigh and dissecting down through subcutaneous tissue to the level of the fascia and the ITB. Then, with long Metzenbaum scissors, we dissected deep and superficially to free the ITB and harvested a central 15-cm-long by 6- to 8-cm-wide free graft. The free ITB graft was folded over the lateral tendon-deficient end of the PM muscle with 5-6 cm of graft covering the anterior and posterior aspects of distal muscle belly (Fig. 2), while the remaining 2 cm of length was used to reconstruct the all-tendinous portion (Fig. 3). Sutures were passed anterior to posterior and back again through the graft and pectoralis muscle to secure the graft to the muscle. Then, with the graft secured to the PM muscle, three double-loaded anchors were inserted equally spaced along the humeral insertion site with one at both the proximal and distal ends of the insertion site. Both limbs of one of the sutures from each of the three anchor locations were passed in simple mattress fashion through the respective site on the folded end of the tendon graft. Then a single limb from each remaining suture of each of the three anchors was passed from lateral to medial and back along the free folded edge of the tendon graft in a locking modified Krackow fashion and the opposite limb was passed posterior to anteriorly at the lateral edge. With the arm adducted and internal rotated, the suture limbs were tensioned and tied. A complete schematic of this technique is displayed in Figure 3. Both surgical wounds were irrigated, closed, and dressed in sterile fashion.



**Figure 2** Intraoperative photo. The ITB graft folded over PM with sutures running anterior to posterior in a modified Krackow fashion. PM, pectoralis major; ITB, iliotibial band.

### Postoperative care and rehabilitation

Postoperatively, he was put in a sling immobilizer with a waist strap to keep the arm adducted and internally rotated for 6 weeks. During this time, he progressed with active assisted range of motion of the elbow, wrist, and hand. For weeks 7 and 8, he remained in the sling and was allowed passive supine flexion (in resting internal rotation) to 45 degrees, abduction to 30 degrees, and external rotation to neutral rotation with arm at the side. For weeks 9 and 10, the sling was discontinued and gentle active and active assisted range of motion and isometric strengthening with the arm in resting adduction was allowed. For weeks 11 to 14, we gradually restored shoulder range of motion and progressed to light isotonic PM (in midrange of motion), rotator cuff, biceps and triceps muscle strengthening activities. From week 15 onwards, aggressive range-of-motion exercises were incorporated as necessary and gradual



**Figure 3** Schematic of PM reconstruction with the ITB graft. PM, pectoralis major; ITB, iliotibial band.

progressive strengthening exercises were followed by sport specific activities. Heavy bench press was discouraged before 6 months postoperatively. In this case, shoulder flexion progressed to 165 degrees at 12 weeks, and he exhibited full range of motion and 5/5

adduction strength at 22 weeks. At 5 months, he was able to return to normal activity. At a two-year follow-up, he stated that the power in his right shoulder was now greater than it was before the injury as measured by his maximum bench press lift.

**Outcomes**

Cosmesis, full functional range of motion, and symmetrical strength with pectoralis weight-training exercises were restored (Fig. 1, B). As per the clinical outcome scale for PM tendon ruptures developed by Bak et al,<sup>1</sup> “excellent” outcomes are classified as pain free with fully restored range of motion, symmetrical manual adduction strength, no cosmetic complaints, and return to activity without restriction. Our patient met each of these criteria and was thus classified as an excellent outcome. He was able to return to activity with no restrictions as evident by an increase in his prior bench press maximum weight. Manual adduction strength was symmetrical at 22 weeks postoperatively. Donor-site morbidity was unremarkable aside from a 3-inch well-healed scar with some minor hypertrophy. He denied weakness or functional muscle problems such as cramping, pain with exertion, or fatiguability. He denied any problems with the donor site.

**Discussion**

We describe a successful case of surgically reconstructing a chronic PM rupture with an autologous ITB graft to illustrate the technique and potential for the use of an ITB graft in this setting. In a meta-analysis of 112 cases, Bak et al<sup>1</sup> concluded that the standard practice for acute tears was primary surgical repair with better clinical outcomes associated with early intervention. Chronic tears, however, are more difficult to manage with regard to tissue quality and tendon retraction.<sup>8</sup> In cases of chronic rupture with limited muscle belly retraction, primary repair was still demonstrated to have the best clinical outcomes.<sup>3,18</sup> Techniques using medial fascial release have been detailed in an effort to mobilize the myotendinous unit sufficiently to allow primary repair in these scenarios.<sup>3</sup> In the case of significant muscle belly retraction, primary approximation of tendon to the insertion site may not be possible, thus reconstruction of the tendon is necessary.

Cases of complete PM tendon reconstruction represent less than 5% of all documented ruptures.<sup>19</sup> PM reconstruction procedures have used a variety of grafts, including hamstring autografts, bone-patellar tendon autografts, Achilles tendon allografts, hamstring tendon allografts, and dermal allografts.<sup>2,7,8,13,15,17,20</sup> The usage of autologous grafting in reconstruction techniques has become increasingly popular owing to avoidance of tissue rejection and infections.<sup>2,17</sup> Both Schachter et al<sup>18</sup> and Baverel et al<sup>3</sup> were successful in reconstruction of the PM tendon using a hamstring autograft. Their patients recovered in “excellent” standings with magnetic resonance imaging confirmation of continuity between PM tendon and graft. Zacchilli et al<sup>19</sup> performed PM reconstruction using Achilles tendon allografts on 3 military patients with significantly chronic tears unaddressed for approximately 2 years. Their clinical outcomes ranked one patient as “excellent” and the other two as “good.” The potential limitations of using an Achilles tendon allograft include exposing patients to a risk of disease transmission and limited incorporation of the graft. Use of an autologous ITB or hamstring graft avoid these complications and may pose a higher benefit-to-risk outcome if donor-site morbidity is minimal. The successful outcomes reported from these cases of PM reconstruction supports their efficacy when primary repair is not viable.

We present this case as an alternative technique for chronic PM tendon ruptures with an irreparable tendon. In primary repair, suture anchors are widely accepted for fixation to the bone and were

thus used for this reconstruction.<sup>14</sup> In numerous studies, they were proven to provide predictable return of strength, cosmesis, and high patient satisfaction.<sup>1,14,17</sup> Contralateral ITB autograft was our graft choice for several reasons. The ITB autograft avoids the potential risks for disease transmission and failure of graft incorporation while providing a graft that can be fashioned with flat and wide dimensions with an anatomic resemblance to the PM tendon. Well-known complications related to hamstring and bone-patellar tendon-bone autograft donor-site morbidity such as anterior knee pain and flexion weakness were avoided by choosing the ITB.<sup>9</sup> In dealing with the broad insertion site of the PM tendon ( $73.3 \pm 10.0$  mm)<sup>5</sup>, we chose to harvest a graft that would best address the length of the site in addition to the gap between muscle and bone. Our graft measures approximately 15 cm in length (approximately 7.5 cm folded) and 8 cm in height. When folded, 5–6 cm covered the distal muscle belly anteriorly and posteriorly, while the rest of the length (approximately 2 cm) filled the gap. The dual-sided anchorage of the graft to the PM (ie sandwiching the muscle between the two graft flaps) provided exceptional fixation (Fig. 3). The simplicity of this technique eliminated the need to weave fibers together as running the sutures anterior to posterior served effective.

Autologous ITB grafts have also been used in several other reconstruction procedures, including reconstruction of the anterior cruciate ligament, acetabular labral, superior capsule of the shoulder, and trauma-associated soft-tissue defects.<sup>4,11,12,16</sup> Having documented their successful clinical outcomes, these studies further demonstrate the versatility of the ITB graft as a viable autologous material for tendon reconstruction. The potential morbidity associated with harvesting the autologous graft includes wound infection, superficial phlebitis, seroma, muscle hernia, and deep vein thrombosis; however, these are rarely seen in practice.<sup>11,12,16</sup> ITB autograft morbidity is primarily limited to cosmetic findings. In a study that performed 169 anterior cruciate ligament reconstructions with ITB autografts, the authors found the donor-site morbidity to be markedly decreased compared with the gold standard patella bone-tendon-bone autograft.<sup>12</sup> In addition, a case series dealing with acetabular labral reconstruction of 75 patients using ITB autografts observed no reported donor site complications, pain, or weakness.<sup>16</sup> Given the literature regarding minimal donor-site morbidity and the excellent outcome observed in this case, the ITB graft has potential to be a viable tissue for reconstruction of PM tendon ruptures.

## Conclusion

We present this case report describing the successful treatment of a chronic PM tendon rupture with an autologous ITB graft. The ITB provides an accessible source for tissue with dimensions similar to the native pectoralis major tendon, making it a desirable graft choice for reconstruction of chronic PM tendon ruptures. Prospective outcome studies on the use of a free autologous ITB graft for PM reconstruction will be helpful to better determine outcomes and complications of this procedure.

## Disclaimers

Funding: No funding was disclosed by the author(s).

Conflicts of interest: The authors, their immediate families, and any research foundations with which they are affiliated have not received any financial payments or other benefits from any commercial entity related to the subject of this article.

Patient consent: Obtained.

## References

- Bak K, Cameron EA, Henderson JJ. Rupture of the pectoralis major: a meta-analysis of 112 cases. *Knee Surg Sports Traumatol Arthrosc* 2000;8:113–9.
- Baverel L, Messedi K, Piéto G, Crenn V, Gouin F. Pectoralis major tear with retracted tendon: how to fill the gap? reconstruction with hamstring autograft and fixation with an interference screw. *Case Rep Orthop* 2017;2017:2095407. <https://doi.org/10.1155/2017/2095407>.
- Butt U, Mehta S, Funk L, Monga P. Pectoralis major ruptures: a review of current management. *J Shoulder Elbow Surg* 2015;24:655–62. <https://doi.org/10.1016/j.jse.2014.10.024>.
- Chahla J, Soares E, Bhatia S, Mitchell JJ, Philippon MJ. Arthroscopic technique for acetabular labral reconstruction using iliotibial band autograft. *Arthrosc Tech* 2016;5:671. <https://doi.org/10.1016/j.eats.2016.02.025>.
- Dannenbaum JH, Eckhoff MD, Galvin JW, Bean BK, Wilson DJ, Arrington ED. Pectoralis major tendon insertion anatomy and description of a novel anatomic reference. *J Surg Orthop Adv* 2018;27:39–41.
- de Castro Pochini A, Ejinisman B, Andreoli CV, Monteiro GC, Silva AC, Cohen M, et al. Pectoralis major muscle rupture in athletes: a prospective study. *Am J Sports Med* 2010;38:92–8. <https://doi.org/10.1177/0363546509347995>.
- Dehler T, Pennings AL, ElMaraghy AW. Dermal allograft reconstruction of a chronic pectoralis major tear. *J Shoulder Elbow Surg* 2013;22:e18–22. <https://doi.org/10.1016/j.jse.2013.06.021>.
- Flint JH, Wade AM, Giuliani J, Rue JP. Defining the terms acute and chronic in orthopaedic sports injuries: a systematic review. *Am J Sports Med* 2014;42:235–41. <https://doi.org/10.1177/0363546513490656>.
- Freedman KB, D'Amato MJ, Nedeff DD, Kaz A, Bach BR Jr. Arthroscopic anterior cruciate ligament reconstruction: a metaanalysis comparing patellar tendon and hamstring tendon autografts. *Am J Sports Med* 2003;31:2–11. <https://doi.org/10.1177/03635465030310011501>.
- Haley CA, Zacchilli MA. Pectoralis major injuries: evaluation and treatment. *Clin Sports Med* 2014;33:739–56. <https://doi.org/10.1016/j.csm.2014.06.005>.
- Hu R, Ren YJ, Yan L, Xiao ZH, Ding F, Li F, et al. A free anterolateral thigh flap and iliotibial band for reconstruction of soft tissue defects at children's feet and ankles. *Injury* 2015;46:2019–23. <https://doi.org/10.1016/j.injury.2015.06.046>.
- Jørgensen U, Bak K, Ekstrand J, Scavenuis M. Reconstruction of the anterior cruciate ligament with the iliotibial band autograft in patients with chronic knee instability. *Knee Surg Sports Traumatol Arthrosc* 2001;9:137–45.
- Long M, Enders T, Trasolini R, Schneider W, Cappellino A, Ruotolo C. Pectoralis major tendon reconstruction using semitendinosus allograft following rupture at the musculotendinous junction. *JSES Open Access* 2019;3:328–32. <https://doi.org/10.1016/j.jses.2019.08.007>.
- Mooers BR, Westermann RW, Wolf BR. Outcomes following suture-anchor repair of pectoralis major tears: a case series and review of the literature. *Iowa Orthop J* 2015;35:8–12.
- Neumann JA, Klein CM, van Eck CF, Rahmi H, Itamura JM. Outcomes after dermal allograft reconstruction of chronic or subacute pectoralis major tendon ruptures. *Orthop J Sports Med* 2018;6:2325967117745834. <https://doi.org/10.1177/2325967117745834>.
- Philippon MJ, Arner JW, Crawford MD, Bolia IK, Briggs KK. Acetabular labral reconstruction with iliotibial band autograft: outcome and survivorship at a minimum 10-year follow-up. *J Bone Joint Surg Am* 2020;102:1581–7. <https://doi.org/10.2106/JBJS.19.01499>.
- Schachter AK, White BJ, Namkoong S, Sherman O. Revision reconstruction of a pectoralis major tendon rupture using hamstring autograft: a case report. *Am J Sports Med* 2006;34:295–8. <https://doi.org/10.1177/0363546505278697>.
- Schepesis AA, Grafe MW, Jones HP, Lemos MJ. Rupture of the pectoralis major muscle. Outcome after repair of acute and chronic injuries. *Am J Sports Med* 2000;28:9–15.
- Zacchilli MA, Fowler JT, Owens BD. Allograft reconstruction of chronic pectoralis major tendon ruptures. *J Surg Orthop Adv* 2013;22:95–102. <https://doi.org/10.3113/jsoa.2013.0095>.
- Zafra M, Muñoz F, Carpintero P. Chronic rupture of the pectoralis major muscle: report of two cases. *Acta Orthop Belg* 2005;71:107–10.