

Re-Endothelialization of Bare Stroma after Descemet's Detachment due to Macroperforation during Deep Anterior Lamellar Keratoplasty

Zahra Ashena¹, Mayank A. Nanavaty^{1,2}

¹Sussex Eye Hospital, Brighton and Sussex University Hospitals NHS Trust, Brighton, United Kingdom, ²Brighton and Sussex Medical School, University of Sussex, Brighton, United Kingdom

Abstract

Purpose: To report a case with spontaneous re-endothelialization of bare stroma after subtotal detachment of Descemet's membrane (DM) due to macroperforation during deep anterior lamellar keratoplasty (DALK).

Methods: Case report.

Results: A 64-year-old patient underwent DALK for deep stromal scarring secondary to herpetic keratitis. During manual dissection, DM macroperforation occurred, and this was successfully managed intraoperatively and postoperatively. The DM with host posterior stroma remained attached for 10 months when it detached from the bare donor stroma. The cornea remained clear, with uncorrected distance visual acuity (UCVA) of 0.17 logMAR. After graft suture removal 30 months later, he was noted to have regular astigmatism and cataract for which he underwent phacoemulsification with toric intraocular lens implantation. Twenty-four months following his cataract surgery and 58 months following his DALK, his UCVA remains 0.17 logMAR and the cornea remains clear with no evidence of edema. His average specular count at 58 months was 1296 cell/mm².

Conclusion: This case shows a very good visual outcome with clear cornea at 58 months despite of large DM detachment which happened 10 months following manual DALK with intraoperative macroperforation.

Keywords: Deep anterior lamellar keratoplasty, Descemet's membrane, Endothelial cells, Keratoplasty

Address for correspondence: Mayank A. Nanavaty, Sussex Eye Hospital, Brighton and Sussex University Hospitals NHS Trust, Eastern Road, Brighton BN2 5BF, United Kingdom.

E-mail: mayank.nanavaty@nhs.net

Submitted: 02-Mar-2020; **Revised:** 15-Apr-2020; **Accepted:** 03-May-2020; **Published:** 12-Dec-2020

INTRODUCTION

Deep anterior lamellar keratoplasty (DALK) is the gold standard surgery for anterior corneal pathologies, including keratoconus, corneal scarring, dystrophies, and degenerations, in the presence of healthy endothelium.¹ Compared to penetrating keratoplasty, it provides advantages such as better globe integrity and reduced risk of suprachoroidal hemorrhage, graft rejection, and endothelial cell loss.¹ The stroma can be separated from the Descemet's membrane (DM)

and endothelium using manual dissection, femtosecond laser, or through injection of air, saline, or viscoelastic material just anterior to the DM.¹ DM perforation is not an uncommon intraoperative complication in DALK, and the incidence ranges between 1.3% and 54.3%.² Nevertheless, a good visual outcome is reported in various case series of DALK in spite of this complication.²⁻⁴ The pathophysiology of endothelial cell migration and repopulation in the area of bare stroma (over the DM perforation) is not fully understood. However, recent evidence from the studies on Descemet's membrane

This is an open access journal, and articles are distributed under the terms of the Creative Commons Attribution-NonCommercial-ShareAlike 4.0 License, which allows others to remix, tweak, and build upon the work non-commercially, as long as appropriate credit is given and the new creations are licensed under the identical terms.

For reprints contact: WKHLRPMedknow_reprints@wolterskluwer.com

How to cite this article: Ashena Z, Nanavaty MA. Re-endothelialization of bare stroma after Descemet's detachment due to macroperforation during deep anterior lamellar keratoplasty. *J Curr Ophthalmol* 2020;32:423-6.

Access this article online

Quick Response Code:



Website:
www.jcurrophthalmol.org

DOI:
10.4103/JOCO.JOCO_79_20

endothelial keratoplasty (DMEK) suggest migration and repopulation of endothelial cells, both from donor and host's DM on the bare recipient's stroma leading to the transparent cornea.^{5,6} Dirisamer *et al.*⁵ suggested that the presence of donor endothelium in the recipient anterior chamber (AC), as well as direct physical contact between donor and host tissues, may be prerequisites for endothelial repopulation of the recipient posterior cornea and/or recovery of corneal clarity.

We report a case of DALK with a DM macroperforation with late postoperative detached DM and re-endothelialization of donor stroma.

CASE REPORT

We report this case after obtaining appropriate consent for publication from the patient. A 64-year-old male with a history of left eye herpes simplex virus keratitis, previous amniotic membrane transplant for recurrent non-healing epithelial defect, deep stromal scar, and the best corrected distance visual acuity (BCVA) of 0.3 underwent DALK in January 2015. During manual dissection of the anterior corneal lamella, a DM macroperforation was noted (approximately 4 mm in its maximum diameter). Gentle manual dissection was continued away from the location of macroperforation. Manual lamellar dissection was completed without converting to penetrating keratoplasty, and AC was maintained with repeated air injections during the entire procedure.¹ An 8.25-mm donor corneal button was prepared. The DM was stripped, and the donor stroma was transplanted with sixteen 10-0 nylon interrupted sutures. At the end of the procedure, air was injected into the AC to tamponade the host's DM to the donor stroma. The pupil was dilated with G. cyclopentolate 1% qds for 7 days. The patient also received tablet acetazolamide 250 mg qds for 3 days along with G. Tobradex (Alcon Laboratories, Fort Worth, Texas, USA) qds for a month and tablet aciclovir 400 mg 5 times a day for 2 weeks. On the following day, double AC sign¹ was noticed and the patient underwent rebubbling with air in the AC a week later as the double AC did not resolve spontaneously. The double AC took over 8 days following the rebubbling to settle. The patient still remains on G. loteprednol once a day along with tablet aciclovir 400 mg bd. He had no recurrences of herpetic keratitis till 58 months, postoperatively.

At 4 weeks postoperatively, the uncorrected distance visual acuity (UCVA) was 0.75 logMAR and BCVA was 0.3 logMAR. The patient was followed up in the corneal clinic almost every 6–8 weeks post-settlement after the resolution of double AC. The DM was noted to be attached to the stroma until 8 months postoperatively. Following this, at 10 months, a distinct separation was noted between host posterior corneal lamella (DM with some posterior stroma) and donor stroma [Figure 1a and b]. There was no corneal edema or redetachment noted until 8 months postoperatively. On the next visit at month 10, the DM was noted to be detached with donor cornea. The patient did not report any gross deterioration of vision between months 8 and 10. Slit-lamp examination

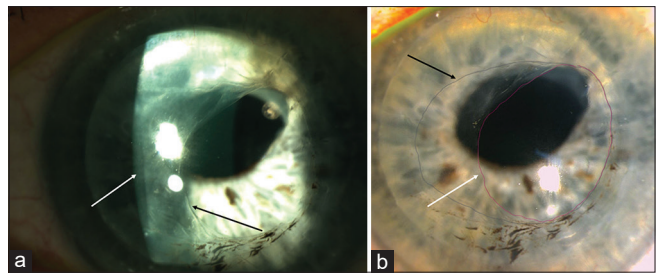


Figure 1: (a) Clear deep anterior lamellar keratoplasty (DALK) graft at 58 months postoperatively with clear gap between DALK stroma and host Descemet's membrane (DM) with fibrosed margin of DM tear. White arrow showing the clear gap. Black arrow showing the fibrosed margin. (b) Clear DALK with borders of the macroperforation and detached DM at 58 months postoperatively. White arrow identifies the border of the area with the DM defect. Black arrow identifies the area not covered by DM

showed an eccentric defect in the host posterior lamella (DM with some posterior stroma) measuring 5 mm by 4.5 mm in size with fibrosing edge of the defect [Figure 1a and b]. The cornea was clear with no evidence of sectoral or diffuse edema. Corneal ocular coherence tomography showed a clear detachment of host posterior lamellar (DM with some posterior stroma) from the donor stroma [Figure 2]. There was an area of bare donor stroma measuring 6.5 mm by 5 mm involving the visual axis [Figure 1a and b]. Two and a half years later, the graft sutures were removed, but by this time, he had developed cataract. Examination at this stage showed 6.5 diopters of regular corneal astigmatism with UCVA of 1.0 logMAR. He underwent successful phacoemulsification with toric intraocular lens implant (Rayner T-flex [Rayner, Worthing, UK] with an 8-diopter sphere and 9.5-diopter cylinder implanted at 8° axis and expected postoperative spherical equivalent of – 0.2 diopters), which improved his UCVA to 0.17 logMAR. Two years down the line following his cataract surgery and 58 months following his DALK, his UCVA remains 0.17 logMAR and the cornea remains clear with no evidence of edema [Figure 1a and b]. A specular microscopy performed using CellChek[®] specular microscopy (Konan Medical, Irvine, USA) in all quadrants confirms the presence of endothelial cells on the stromal side of the donor cornea at 58 months [Figure 3].

DISCUSSION

It is already known that the risk of DM perforation in DALK is significantly increased when the ratio of the stromal scar depth to minimum corneal thickness is >0.79.⁷ Intraoperatively, this complication can be managed successfully with intracameral injection of air bubble to tamponade the DM and by a gentle manual dissection in a centripetal fashion, starting away from the perforation, to prevent further extension of the DM hole.¹ The use of fibrin glue to seal the detached DM to the donor's stroma⁸ and stromal suturing techniques⁹ are also described in literature to manage this. In early postoperative stage, careful observation is necessary to assess any double AC, which may

resolve spontaneously.¹ The rate of appearance of the double AC is reported to be up to 60% following DM perforation.¹ The late postoperative sequelae of DM perforations include postoperative DM detachment, higher endothelial cell loss, endothelial decompensation, and interface scarring.² However, the good visual outcomes are reported following the successful management of micro or macroperforations.

Kodavoor *et al.*³ reported a good visual and anatomical outcome in 16 patients with keratoconus, pellucid marginal degeneration, and macular corneal dystrophy, who underwent DALK with micro (12 eyes) and macroperforation (4 eyes defined as perforation >1 mm). In their report, postoperatively, the vision improved significantly in all patients with BCVA of 0.28 ± 0.09 logMAR.³ Furthermore, in a study of 101 eyes with DM perforation during DALK by Huang *et al.*,² 78.2% of the patients had microperforation and the rest developed macroperforation (defined as any defect >0.5 mm). Cases with intraoperative DM perforations were reported to have equivalent visual outcomes compared to those without DM perforations and did not have any increased risk of graft failure or rejection at postoperative years 1 and 3.² In fact, 78% of the eyes with perforation and 68% of the eyes without perforation developed BCVA of 6/12 or better 3 years after the surgery. Similarly, Senoo *et al.*⁴ reported no statistically significant difference between the BCVA in 54 eyes that underwent DALK between the groups with and without DM perforation.

Passos *et al.*¹⁰ reported a case who had a spontaneous detachment of the DM after 5 months of DALK. However, unlike our case, they preserved the donor DM, and therefore, their donor cornea remained clear despite the DM detachment. In another report by Lin *et al.*,¹¹ where the donor DM was not preserved, the donor cornea remained clear despite persistent detachment of DM and multiple rebubbling attempts before it finally attached spontaneously. We hypothesize two possible explanations for the cause of DM detachment 10 months after DALK. First, like Passos *et al.*,¹⁰ we believe that perhaps in cases with DM perforations, the recipient DM is not entirely attached to the donor stroma despite multiple rebubbling attempts, and there may be areas that maintain virtual spaces in the peripheral cornea without real adherence which are not apparent clinically. This may be responsible for the reduced adherence of the donor button to the DM from the recipient, facilitating a late detachment. Second, in our case, over time, there was a significant fibrosis near the edges of the detached DM defect (as also noted by Passos *et al.*¹⁰ at 5 months). This fibrosis may have caused further traction on the remainder of the host posterior lamella which did not allow spontaneous reattachment (as noted in case by Lin *et al.*¹¹), and this traction may have led to the DM detachment remaining stable over 58-month period.

The pathophysiology of migration and repopulation of endothelial cells over the bare stroma overlying the

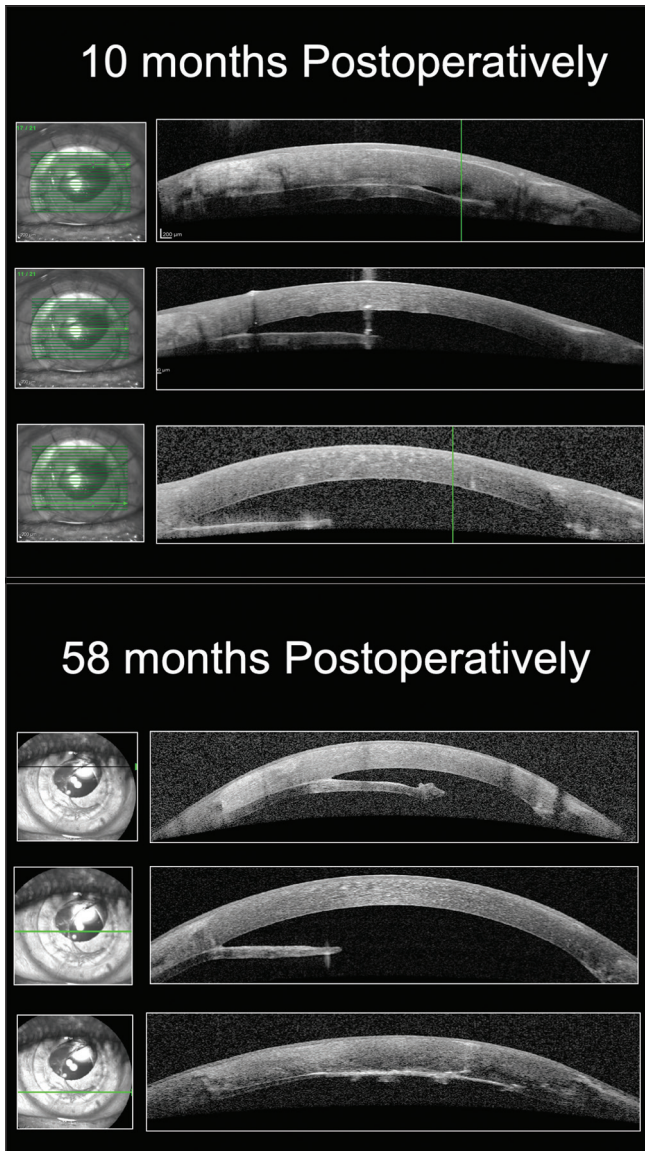


Figure 2: Ocular coherence tomography scans at 10 and 58 months postoperatively

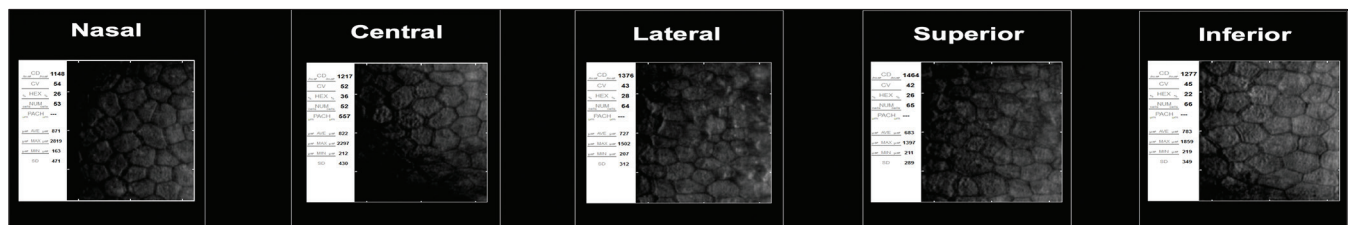


Figure 3: Specular microscopy in nasal, central, lateral, superior, and inferior quadrants of the cornea at 58 months

macroperforation is still unknown, but recent DMEK studies showing re-endothelialization may explain the presence of clear cornea over the macroperforation in our case. Dirisamer *et al.*⁵ described corneal re-endothelialization following complicated DMEK in 36 eyes out of consecutive 150 DMEK cases. Spontaneous corneal clearance was reported in 28 eyes with decentered, partially detached or upside-down grafts.⁵ They noticed healthy endothelial cells with endothelial cell density similar to the control group (eyes with fully attached and centered grafts) on the recipient's corneal stroma.⁵ This indicated that apart from migration, the endothelial cells still have the capacity to regenerate.⁵ In another report, Daravagka *et al.*¹² described three cases with DMEK for Fuchs endothelial dystrophy (FED), with complete graft detachment and spontaneous corneal clearance. The patients were monitored closely without any intervention and noticed that the cornea cleared spontaneously in all cases within 3 months.¹⁰ Specular microscopy confirmed regeneration of endothelial cells on the recipient stroma in all three eyes in their series.¹² In our case, the patient had attached host DM for approximately 9.5 months after rebubbling, but the cornea was still clear over the macroperforation site despite of bare stroma. We believe that during this time, there was re-endothelialization of the bare stroma and gradual repopulation of endothelial cells beyond the bare stroma just before or after the detachment of the host DM at 10 months leading to a reasonable endothelial cell count in all five regions of the cornea.

Similarly, there have been reports of spontaneous corneal clearance following Descemet's stripping without any endothelial keratoplasty in patients with FED.⁶ The authors documented that the new endothelial cells had the functional properties of healthy corneal endothelium and produced a normal cornea with no structural alteration.⁶ They reported corneal endothelial cells supplemented with rho-associated protein kinase inhibitor, when injected into the AC, repopulated, and self-organized on the posterior surface of the cornea.⁶

In summary, it was already known that the outcome of eyes with DM perforation during DALK was good, but there is emerging evidence that endothelial cells migrate and repopulate in time over bare stroma over the site of DM perforation and on the bare stroma which is not in physical contact with the DM. To our knowledge, this is the first report of DM macroperforation, followed by subtotal separation of DM from the donor stroma due to fibrosis of the edges of macroperforation, with clear cornea despite subsequent phacoemulsification procedure and excellent visual outcomes.

Declaration of patient consent

The authors certify that they have obtained all appropriate patient consent forms. In the form, the legal guardian has given his consent for images and other clinical information to be reported in the journal. The guardian understands that names and initials will not be published and due efforts will be made to conceal identity, but anonymity cannot be guaranteed.

Financial support and sponsorship

Nil.

Conflicts of interest

There are no conflicts of interest.

REFERENCES

1. Nanavaty MA, Vijjan KS, Yvon C. Deep anterior lamellar keratoplasty: A surgeon's guide. *J Curr Ophthalmol* 2018;30:297-310.
2. Huang OS, Htoon HM, Chan AM, Tan D, Mehta JS. Incidence and outcomes of intraoperative descemet membrane perforations during deep anterior lamellar keratoplasty. *Am J Ophthalmol* 2019;199:9-18.
3. Kodavoor SK, Deb B, Ramamurthy D. Outcome of deep anterior lamellar keratoplasty patients with intraoperative descemet's membrane perforation: A retrospective cross-sectional study. *Indian J Ophthalmol* 2018;66:1574-9.
4. Senoo T, Chiba K, Terada O, Hasegawa K, Obara Y. Visual acuity prognosis after anterior chamber air replacement to prevent pseudo-anterior chamber formation after deep lamellar keratoplasty. *Jpn J Ophthalmol* 2007;51:181-4.
5. Dirisamer M, Dapena I, Ham L, van Dijk K, Oganis O, Frank LE, *et al.* Patterns of corneal endothelialization and corneal clearance after descemet membrane endothelial keratoplasty for fuchs endothelial dystrophy. *Am J Ophthalmol* 2011;152:543-550.
6. Kinoshita S, Koizumi N, Ueno M, Okumura N, Imai K, Tanaka H, *et al.* Injection of cultured cells with a ROCK inhibitor for bullous keratopathy. *N Engl J Med* 2018;378:995-1003.
7. Ozmen T, Yesilirmak N, Aydin B, Ceylanoglu KS, Atalay HT, Akata F. Prediction of descemet membrane perforation during deep anterior lamellar keratoplasty in patients with keratoconus with stromal scar. *Eye Contact Lens* 2018;44 Suppl 2:S176-9.
8. Alharbi SS, Alameer A. Use of fibrin glue in the management of descemet membrane perforation during deep anterior lamellar keratoplasty. *Middle East Afr J Ophthalmol* 2019;26:168-71.
9. Nasr Hashem A, Toles SS, Samir A. Novel technique for the management of macroperforation during deep anterior lamellar keratoplasty. *Clin Ophthalmol* 2019;13:2075-80.
10. Passos ML, Coral Ghanem V, Piccinini AL, Coral Ghanem R. Late Detachment after DALK in a Patient with Descemet Membrane Microperforation. *Ophthalmology @ Point of Care* 2017;1:e45-e46.
11. Lin X, Wu Y, Fu Y, Dai Q. Spontaneous reattachment of descemet membrane detachment after deep anterior lamellar keratoplasty: A case report. *Medicine (Baltimore)* 2018;97:e0032.
12. Daravagka M, Nestler A, Wiedemann P, Girbardt C. Corneal clearance and central endothelial cell repopulation despite graft detachment after descemet membrane endothelial keratoplasty. *GMS Ophthalmol Cases* 2019;9:Doc14.