

## Bosworth and modified Phemister techniques revisited. A comparison of intraarticular vs extraarticular fixation methods in the treatment of acute Rockwood type III acromioclavicular dislocations<sup>☆</sup>



Engin Cetinkaya<sup>a, c, \*</sup>, Yavuz Arıkan<sup>a, c</sup>, Kubilay Beng<sup>a, c</sup>, Harun Mutlu<sup>b</sup>,  
Merter Yalçınkaya<sup>a</sup>, Onat Üzümcügil<sup>c</sup>

<sup>a</sup> Baltalimani Bone and Joint Diseases Training and Research Hospital, İstanbul, Turkey

<sup>b</sup> GOP Taksim Training and Research Hospital Department of Orthopaedics and Traumatology, İstanbul, Turkey

<sup>c</sup> Kolan Hospital, İstanbul, Turkey

### ARTICLE INFO

#### Article history:

Received 7 November 2016

Received in revised form

5 March 2017

Accepted 19 September 2017

Available online 9 October 2017

#### Keywords:

Acromioclavicular separation

Type 3 separation

Bosworth screw

Phemister procedure

### ABSTRACT

**Objective:** The aim of this study was to compare the long-term clinical and radiological results of Acromioclavicular (AC) fixation with K-wires (the modified Phemister procedure) and Coracoclavicular (CC) fixation with the Bosworth screw in the surgical treatment of Type 3 AC joint dislocations.

**Methods:** Thirty-two patients with complete set of medical records and who received surgical treatment between September 2005 and January 2009 due to acute Rockwood Type 3 AC joint dislocation and properly attended their follow-ups were retrospectively evaluated. Sixteen patients (13 males, 3 females; mean age: 38, range: 24–52 years) were treated with CC fixation with Bosworth screw (Group 1), and the other 16 (12 males, 4 females; mean age: 53.3, range: 38–64 years) with AC fixation using K-wires (Group 2).

**Results:** The mean follow-up time was 96 months for Group 1 and 93 months for Group 2 patients ( $p > 0.05$ ). The mean Constant–Murley score at the final follow-up was 84.7 in Group 1 and 87.3 in Group 2 ( $p = 0.069$ ). Radiological evaluation of the patients revealed AC arthrosis in 2 and 3 patients in Group 1 and 2, respectively. In Group 2, one patient had a recurrent dislocation, three patients had AC arthrosis and two patients had ossification in the CC ligament (Fig. 2).

There was no superficial or deep wound infection in Group 1, while two patients from Group 2 had a superficial wound infection.

**Conclusions:** Our results suggest that both techniques are reliable and provide adequate reduction and similar outcomes in terms of functionality and pain levels, following the reduction of Type 3 AC joint dislocations. With lower rates of wound site infection in the early and AC arthrosis in the late post-operative period, CC fixation method with the Bosworth screw may be a better surgical option than AC fixation method with K-wires.

**Level of Evidence:** Level III, Therapeutic study.

© 2017 Turkish Association of Orthopaedics and Traumatology. Publishing services by Elsevier B.V. This is an open access article under the CC BY-NC-ND license (<http://creativecommons.org/licenses/by-nc-nd/4.0/>).

<sup>☆</sup> This study was conducted at İstanbul Training and Research Hospital, İstanbul and GOP Taksim Training and Research Hospital, İstanbul.

\* Corresponding author. Baltalimani Bone and Joint Diseases Training and Research Hospital, Rumelihisari Cad. No: 62, Baltalimani, Sariyer, İstanbul, Turkey. Fax: +90 212 323 70 82.

E-mail addresses: [drengincetinkaya@gmail.com](mailto:drengincetinkaya@gmail.com) (E. Cetinkaya), [doctoryavuzarikan@gmail.com](mailto:doctoryavuzarikan@gmail.com) (Y. Arıkan), [kubilaybeng@yahoo.com](mailto:kubilaybeng@yahoo.com) (K. Beng), [drharunmutlu@yahoo.com](mailto:drharunmutlu@yahoo.com) (H. Mutlu), [merter\\_99@hotmail.com](mailto:merter_99@hotmail.com) (M. Yalçınkaya), [onatuzumcugil@yahoo.com](mailto:onatuzumcugil@yahoo.com) (O. Üzümcügil).

Peer review under responsibility of Turkish Association of Orthopaedics and Traumatology.

### Introduction

Acromioclavicular (AC) injuries are among the most common injuries of the shoulder and comprise 21% of the dislocations in the shoulder region.<sup>1</sup> These injuries may be encountered following a simple fall or high-energy trauma.<sup>2</sup> Acromioclavicular ligaments provide horizontal stability of the AC joint whereas coracoclavicular (CC) ligaments provide the vertical stability. Injuries of these ligaments will cause displacement of the clavicle toward

the proximal or posterior of the acromion and lead to three major complications; pain, loss of function, and cosmetic defects.

Today, AC dislocations are classified under six groups according to Rockwood.<sup>3</sup> Coracoclavicular ligaments are intact in Type 1 and 2 dislocations whereas AC ligaments are intact in Type 1 but completely torn in Type 2 dislocations. Both ligament complexes are completely torn in Type 3 dislocations. The clavicle is displaced into the trapezius muscle in Type 4 dislocations. In Type 5 dislocations, the lateral of the clavicle loses its muscle support and is displaced toward the subcutaneous tissue. In the rarely encountered Type 6 dislocations, the distal clavicle is inferiorly displaced toward the subacromial bursa. Type 1 and 2 dislocations are usually treated with conservative methods<sup>4,5</sup> whereas surgical treatment is preferred in Type 4, 5 and 6 dislocations.<sup>6</sup> The optimal treatment modality for Type 3 dislocations, however, is still a matter of debate.<sup>7,8</sup> Surgical methods include AC fixation with Kirschner wires (K-wires), CC fixation with screws, fixation with hook-plate, and arthroscopic fixation techniques but there is no study in the literature that verifies the superiority of any of the above methods over another with solid proofs.

In our study, we compared the long-term clinical and radiological results of AC fixation with K-wires (the modified Phemister procedure) with CC fixation with the Bosworth screw in surgical treatment of Type 3 AC joint dislocations.

## Patient and methods

Thirty-two patients with complete set of medical records and who received surgical treatment between September 2005 and January 2009 due to acute Rockwood Type 3 AC joint dislocation and properly attended their follow-ups were retrospectively evaluated. Sixteen patients (Group 1; 13 males, 3 females; mean age: 38, range: 24–52 years) were treated with CC fixation with the Bosworth screw and the other 16 (Group 2; 12 males, 4 females; mean age: 53.3, range: 38–64 years) with AC fixation with K-wires.

Following the debridement of the fragmented articular disc region, the torn CC ligaments were primarily repaired with no. 2 non-absorbable sutures (Ethicon) and open reduction was performed on the AC joint. Then, CC fixation was performed on Group 1 patients using one half-threaded cancellous, bicortical Bosworth screw with pulling effect, which extended into both the coracoid and the clavicle for maintenance of the reduction. Two K-wires were used for AC fixation in Group 2. To avoid proximal migration following

surgical wound closure in Group 2 patients, the ends of the K-wires were left outside the skin, bent and cut off.

All patients were immobilized for three weeks in the postoperative period with shoulder bandaging. Supervised pendular and climbing exercises were begun on Day 1. Active and passive range of motion (ROM) and proprioceptive exercises were given after the third week. Ninety degrees of shoulder abduction was allowed until the end of the sixth week. The K-wires were removed without anesthesia at the end of the sixth week in the outpatient clinic. Screws were removed under local anesthesia at the end of Week 10 in the operating room. Following the removal of the hardware, abduction of the joint beyond 90° was allowed.

Complications of infection, pin migration, implant failure, and loss of reduction were investigated in the early postoperative term. In the long-term, patients were evaluated with the Constant–Murley shoulder scoring system for pain, shoulder ROM, muscle strength, and limitation of daily activities at their final follow-up. Patients' subjective pain levels were measured with the visual analog scale (VAS). Acromioclavicular joint alignment, recurrent dislocation, presence of AC arthrosis or ossification in the CC ligaments was evaluated on the anteroposterior shoulder radiographs (Figs. 1 and 2).

The Mann–Whitney U test was used in statistical comparison of the Constant–Murley shoulder and VAS scores of both patient groups. The level of statistical significance was set at  $p < 0.05$ .

## Results

The mean period of follow-up was 96 (range: 86–100) months for Group 1 and 93 (range: 71–111) months for Group 2 patients (Mann–Whitney U test,  $p > 0.05$ ) (Table 1, Fig. 1).

The mean Constant–Murley score at the final follow-up was 84.7 (range: 70–100) in Group 1 and 87.3 (range: 45–100) in Group 2 (Mann–Whitney U test,  $p = 0.557$ ) (Table 1).

Mean VAS scores were measured 1.8 (range: 0–5) for Group 1 and 2.8 (range: 0–5) for Group 2 patients at the final visits (Mann–Whitney U test,  $p = 0.187$ ) (Table 1).

Upon functional evaluation of the patients, three patients (25%) had excellent, seven (58%) had good and two had (17%) fair results in Group 1. In Group 2, seven patients (58%) had excellent, four (33%) had good and one (9%) had poor results.

Radiological evaluation of the patients revealed two recurrent dislocations in two patients, AC arthrosis in two patients and

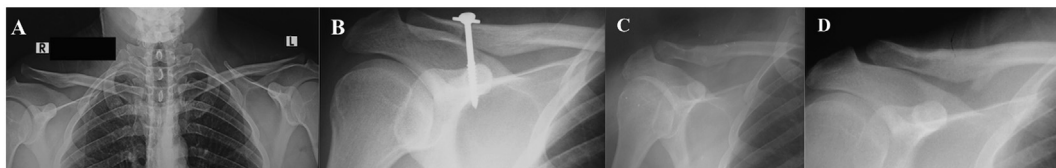


Fig. 1. (A) Type 3 acromioclavicular injury. (B) Postoperative image showing the fixation with screw. (C) Image from the postoperative 8th week, following removal of the screw. (D) Image from the postoperative 90th month.

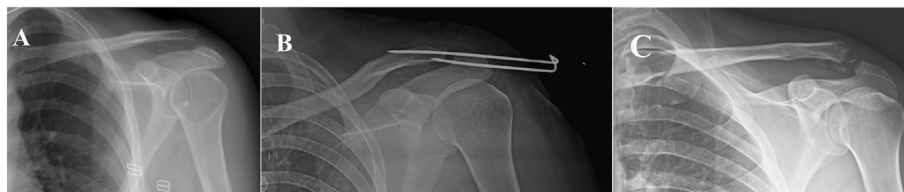

Fig. 2. (A) Type 3 acromioclavicular injury. (B) Postoperative image showing the fixation with K-wire. (C) Image from the postoperative 72nd month showing the ligament ossification.

**Table 1**  
Comparison of Constant–Murley Scores, VAS, follow up period between two groups.

	Group 1 (Bosworth) median (min.–max.)	Group 2 (Modified Phemister) median (min.–max.)	p Value Mann–Whitney U test
Constant–Murley	86 (70–100)	89 (45–100)	0,069
VAS	2 (1–3)	3 (2–4)	0,0187
Follow-up (months)	96 (86–100)	93 (71–111)	>0,05
Complications			
Ligament ossification	18% (n = 3)	12% (n = 2)	
Wound infection	None (n = 0)	12% (n = 2)	
Recurrent dislocation	12% (n = 2)	6,5% (n = 1)	
ACJ arthrosis	12% (n = 2)	18% (n = 3)	

ossification in the CC ligament in three patients from Group 1. In Group 2, one patient had a recurrent dislocation, three patients had ACJ arthrosis and two patients had ossification in the CC ligament (Fig. 2).

Two patients from Group 2 had superficial infections on the surgical wound site, treated with wound care.

## Discussion

The ideal treatment of modality for Type 3 dislocations of the AC joint is still controversial.<sup>1,4,9,10</sup> Studies have shown that conservative treatment provide similar results in terms of muscle strength, pain level, ROM and functionality but has no superiority over surgical treatment.<sup>11–13</sup> However, in a meta-analysis investigating the outcomes of surgical and conservative treatment in Rockwood Type 3 AC dislocations, no difference was found between conservative and surgical treatment in terms of strength, pain, throwing capacity and arthrosis formation and that conservative treatment had worse cosmetic results.<sup>8</sup> As we thought restoring the anatomy of the AC joint to its state before the injury was of essence<sup>14</sup> and no study has shown the superiority of conservative treatment over the surgical, we preferred employing the surgical method for our patients.

Despite the use of various methods in surgical treatment of Type 3 AC joint dislocations, such as, K-wire, hook-plate, screw, synthetic sling materials, and ligament reconstruction<sup>1,4,15,16</sup> the debate still continues for which method is the most efficient one.<sup>1,4,9,10</sup> The main goal in the treatment of AC joint dislocations is to return the patients to their activity levels before injury. Good clinical results and maintenance of the reduction were achieved in the long-term through fixation of the AC joint with K-wires or through CC fixation using screws,<sup>17–21</sup> however, there is no study comparing the long-term results of these two surgical methods.

Coracoclavicular fixation with screws has yielded successful functional results.<sup>1,21</sup> In addition, it was demonstrated that the method in achieving the closest performance to the original CC ligament strength is to send the screw through the coracoid bicortically.<sup>22</sup> Thus, we used a half-threaded cancellous screw with pulling effect to pass through both cortices of the coracoid and concluded that a solid fixation with screws and maintenance of the anatomical reduction produced successful functional results in our patient group treated with this technique. In fixation of the AC joint with K-wires, the joint reduction is maintained by penetration through the AC joint. Successful functional results in the long-term have been recently reported with application of this method.<sup>17,19</sup> The number of K-wires used and whether the wire is threaded or not are the two parameters that affect the results of this technique.<sup>23,24</sup> Loss of stabilization due to failure of the hardware may occur when a single K-wire is used.<sup>25</sup> and fixation with threaded K-wires provides better stability when compared to non-threaded

wires.<sup>24</sup> We used two non-threaded K-wires in our study to obtain a more stable joint fixation and were able to achieve a rate of 93% in terms of stability. The reason to fixation failure in one case where we failed to achieve proper stability may be our preference of using a non-threaded K-wire and several insertions of the wire into the bone in an attempt to achieve proper reduction. In addition, migration of the wire toward the proximal is possible with application of this method. As a matter of fact, migration into the lungs, heart and major veins have been previously reported.<sup>26,27</sup> For this reason, we think bending the end of the wire left outside the skin is of great importance before cutting the tip off, as we practiced.

Studies could not demonstrate a significant difference between repairing and not repairing the torn ligaments in fixation of the AC joint.<sup>28</sup> Repair of the CC ligament, which is not proposed in the original Bosworth's method of fixation with screws,<sup>29</sup> was advocated by Rockwood and Young in the surgical treatment of AC injuries.<sup>6</sup> In a study investigating the recent treatment modalities, repair of the ligaments was shown to yield successful results in acute injuries.<sup>2</sup> As ligament repair has a positive effect on ligament healing and our aim was to restore the original anatomy,<sup>30</sup> ligament repair was performed in both groups. Ossification in the CC ligament was observed in the late term in 25% of Group 1 and 16% of Group 2 patients. This situation, reported to be possibly associated with the bone fragments crumbled during drilling or with calcium deposition in soft tissues induced by bone morphogenetic proteins,<sup>31</sup> had no negative impact on our clinical results.<sup>11,32</sup> As the incidence of ligament ossification in our study was similar to those in which no ligament repair was performed,<sup>31</sup> and ligament ossification had been also reported in patients treated conservatively,<sup>11</sup> we concluded that the complication is not related with the ligament repair and that the ligament repair had a significant effect on the superior functional results we achieved in our patients.

One of the complications of the AC dislocation treatment observed in the long term is arthrosis of the AC joint.<sup>8</sup> Failure to achieve joint reduction or excessive loading on the AC joint following reduction of the CC joint are thought to cause this complication.<sup>14,31</sup> Reduction was achieved in our patients, however, we did not perform any procedure in order to eliminate the excessive loading on the joint. Nowadays, resection of the distal clavicle is recommended in presence of arthrotic findings, especially in chronic dislocations, to achieve successful results.<sup>2</sup> On the other hand, many authors suggested that arthrosis had no effect on clinical results.<sup>11,33</sup> Conversely, we observed worse clinical results in patients with arthrotic findings in their AC joints when compared to those without arthrosis. Although joint alignment was completely achieved in both groups of patients, we believe the excision of the articular disc and disruption of the original integrity of the AC joint due to the advancement of K-wires from the acromion to the clavicle by passing through the joint in Group 2 patients led to arthrosis.

Another complication that may be encountered following the treatment of AC joint dislocations is recurrent dislocation. The main reasons to this are either failure or early removal of the hardware.<sup>34</sup> Removal of temporary fixation materials are not recommended before complete soft tissue healing.<sup>10</sup> But then again, keeping these materials longer than necessary might lead to joint stiffness, thus, the ideal time for removal of these materials was determined to be from the 6th to 12th week.<sup>10</sup> However, if a cortical screw instead of a cancellous one is used for fixation, redislocation may be observed again before material removal.<sup>1</sup> The complication was observed following the hardware removal in all our patients with recurrent dislocations. Although we removed the hardware within the time frame recommended in the literature, we still believe further eligible studies are required to put forward the ideal time frame for hardware removal and the scientific need for it.

Wound site infection is a possible complication of both surgical procedures in the postoperative term.<sup>16,33</sup> Infection may also develop following fixations performed with non-absorbable synthetic materials or anchors.<sup>1,35</sup> In a meta-analysis comparing the outcomes of conservative and surgical treatment, the risk of infection after surgical treatment was found significantly higher. However, the same study also showed that the surgical treatment was usually preferred over the conservative as the incidence of infection was relatively lower with the surgical treatment of the complication.<sup>8</sup> To our best knowledge, no study has been carried out to compare the infection risks between various surgical techniques. We did not encounter a wound site infection in Group 1. However, two patients (13%) from Group 2 had superficial infections. As the rate of infection was low in our study, we did not make any statistical comparison. Nevertheless, as the complication was observed in Group 2 patients only, we believe leaving the tips of the K-wires outside the skin might have increased the risk of wound site infection.

Major limitations of our study include its lack of prospective planning, absence of a conservatively treated patient group and its small number of patients. However, homogeneity of the patient groups and type of injury and comparison of the long-term results of the two most popular surgical techniques in the literature renders our study an authentic one.

## Conclusions

In conclusion, we believe both surgical techniques are reliable and provide adequate reduction and similar outcomes in terms of functionality and pain levels, following the reduction of Type 3 AC joint dislocations and that one has no significant superiority over the other. As it leads to lower rates of wound site infection in the early and AC arthrosis in the late postoperative period, we believe CC fixation method with the Bosworth screw is a better surgical option than AC fixation method with K-wires.

## Conflicts of interest

No conflict of interest.

## References

- Esenyel CZ, Ozturk K, Bulbul M, Ayanoglu S, Ceylan HH. Coracoclavicular ligament repair and screw fixation in acromioclavicular dislocations. *Acta Orthop Traumatol Turc*. 2010;44:194–198.
- Li X, Ma R, Bedi A, Dines DM, Altchek DW, Dines JS. Management of acromioclavicular joint injuries. *J Bone Jt Surg*. 2014;96:73–84.
- Rockwood Jr CA. Injuries to the acromioclavicular joint. In: Rockwood Jr CA, Green DP, eds. *Fractures in adults*. 2nd ed. vol. 1. Philadelphia: JB Lippincott; 1984:974–982.
- Balke M, Schneider MM, Shafizadeh S, Bähis H, Bouillon B, Banerjee M. Current state of treatment of acute acromioclavicular joint injuries in Germany: is there a difference between specialists and non-specialists? A survey of German trauma and orthopaedic departments. *Knee Surg Sports Traumatol Arthrosc*. 2013;23:1447–1452.
- Beitzel K, Cote MP, Apostolakis J, et al. Current concepts in the treatment of acromioclavicular joint dislocations. *Arthroscopy*. 2013;29:387–397.
- Collins DN. Disorders of the acromioclavicular joint. In: Rockwood Jr CA, Matsen III FA, Wirth MA, Lippitt SB, Fehring EV, Sperling JW, eds. *The shoulder*. 4th ed. vol. 4. Philadelphia: Saunders Elsevier; 2009:453–526.
- Gstettner C, Tauber M, Hitzl W, Resch H. Rockwood type III acromioclavicular dislocation: surgical versus conservative treatment. *J Shoulder Elbow Surg*. 2008;17:220–225.
- Smith TO, Chester R, Pearse EO, Hing CB. Operative versus non-operative management following Rockwood grade III acromioclavicular separation: a meta-analysis of the current evidence base. *J Orthop Traumatol*. 2011;12:19–27.
- Salzmann GM, Walz L, Schoettle PB, Imhoff AB. Arthroscopic anatomical reconstruction of the acromioclavicular joint. *Acta Orthop Belg*. 2008;74:397–400.
- Fraser-Moodie JA, Shortt NL, Robinson CM. Injuries to the acromioclavicular joint. *J Bone Jt Surg Br Vol*. 2008;90:697–707.
- Calvo E, López-Franco M, Arribas IM. Clinical and radiologic outcomes of surgical and conservative treatment of type III acromioclavicular joint injury. *J Shoulder Elbow Surg*. 2006;15:300–305.
- Schlegel TF, Burks RT, Marcus RL, Dunn HK. A prospective evaluation of untreated acute grade III acromioclavicular separations. *Am J Sports Med*. 2001;29:699–703.
- Spencer Jr E. E. Treatment of grade III acromioclavicular joint injuries: a systematic review. *Clin Orthop Relat Res*. 2007;455:38–44.
- Tauber M. Management of acute acromioclavicular joint dislocations: current concepts. *Arch Orthop Trauma Surg*. 2013;133:985–995.
- Takase K, Yamamoto K. Changes in surgical procedures for acromioclavicular joint dislocation over the past 30 years. *Orthopedics*. 2013;36:1277–1282.
- Larsen EILIF, Bjerg-Nielsen ARNE, Christensen POUL. Conservative or surgical treatment of acromioclavicular dislocation. A prospective, controlled, randomized study. *J Bone Jt Surg*. 1986;68:552–555.
- Leidel BA, Braunstein V, Kirchhoff C, Pilotto S, Mutschler W, Biberthaler P. Consistency of long-term outcome of acute Rockwood grade III acromioclavicular joint separations after K-wire transfixation. *J Trauma Acute Care Surg*. 2009;66:1666–1671.
- Sirveaux F, Traversari R, Roche O, Mole D. Outcome more than ten years after surgical treatment of acromioclavicular disjunction. *J Bone Jt Surg Br*. 2001;83:36–37.
- Lizaur A, Sanz-Reig J, Gonzalez-Parreño S. Long-term results of the surgical treatment of type III acromioclavicular dislocations an update of a previous report. *J Bone Jt Surg Br Vol*. 2011;93:1088–1092.
- Bektaşer B, Bozkurt M, Oğgüder A, Solak S, Oğuz T. Surgical treatment of type III acromioclavicular joint dislocations by a modified Bosworth technique. *Turkish J Trauma Emerg Surg*. 2004;10:245–249.
- Assaghir YM. Outcome of exact anatomic repair and coracoclavicular cortical lag screw in acute acromioclavicular dislocations. *J Trauma Acute Care Surg*. 2011;71:50–54.
- Harris RI, Wallace AL, Harper GD, Goldberg JA, Sonnabend DH, Walsh WR. Structural properties of the intact and the reconstructed coracoclavicular ligament complex. *Am J Sports Med*. 2000;28:103–108.
- Lögters TT, Briem D, Lohde C, et al. K-wire arthrodesis and coracoclavicular augmentation of complete acromioclavicular separations: functional and subjective results. *Eur J Trauma Emerg Surg*. 2008;34:43–48.
- Eskola A, Vainionpää S, Korkala O, Santavirta S, Grönblad M, Rokkanen P. Four-year outcome of operative treatment of acute acromioclavicular dislocation. *J Orthop Trauma*. 1991;5:9–13.
- Mayr E, Braun W, Eber W, Rüter A. Treatment of acromioclavicular joint separations. Central Kirschner-wire PDS-augmentation. *Der Unfallchirurg*. 1999;102:278–286.
- Mazet R. Migration of a Kirschner wire from the shoulder region into the lung. *J Bone Jt Surg*. 1943;25:477–483.
- Moneim MS, Balduini FC. Coracoid fracture as a complication of surgical treatment by coracoclavicular tape fixation: a case report. *Clin Orthop Relat Res*. 1982;168:133–135.
- Di Francesco A, Zoccali C, Colafarina O, Pizzoferrato R, Flamini S. The use of hook plate in type III and V acromio-clavicular Rockwood dislocations: clinical and radiological midterm results and MRI evaluation in 42 patients. *Injury*. 2012;43:147–152.
- Bosworth BM. Acromioclavicular separation. New method of repair. *Surg Gynecol Obstet*. 1941;73:866–871.
- Kennedy JC. Complete dislocation of the acromioclavicular joint: 14 years later. *J Trauma Acute Care Surg*. 1968;8:310–318.
- Ye T, Ouyang Y, Chen A. Evaluation of coracoclavicular stabilization of acute acromioclavicular joint dislocation with multistrand titanium cables. *Eur J Orthop Surg Traumatol*. 2014;24:1061–1066.
- Motta P, Bruno L, Maderni A, Tosco P, Mariotti U. Acromioclavicular motion after surgical reconstruction. *Knee Surg Sports Traumatol Arthrosc*. 2012;20:1012–1018.
- Taft TN, Wilson FC, Oglesby JW. Dislocation of the acromioclavicular joint. An end-result study. *J Bone Jt Surg*. 1987;69:1045–1051.
- Bannister GC, Wallace WA, Stableforth PG, Hutson MA. The management of acute acromioclavicular dislocation. A randomised prospective controlled trial. *J Bone Jt Surg Br Vol*. 1989;71:848–850.
- Basyoni Y, El-Ganainy AE, Aboul-Saad M. Acromioclavicular joint reconstruction using anchor sutures: surgical technique and preliminary results. *Acta Orthop Belg*. 2010;76:307–311.