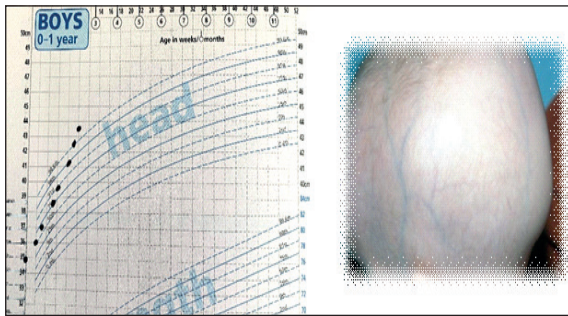


Curiositas - Head Cases

QUIZ 1 - UG Quiz

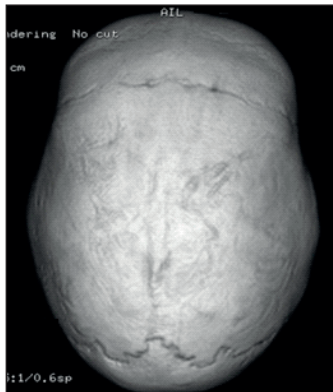


A 10-week-old infant is referred to your rapid response clinic by their health visitor with concerns regarding a rapid increase in their head circumference.

1. What abnormalities are seen in the images?
2. What is the most likely diagnosis and what other clinical signs and symptoms might you find?
3. What are the potential causes?
4. What management options are available?

Ruth Campbell (Year 5 Medical Student, QUB),
Dr Jennifer Wallace (Paediatric Registrar, RBHSC),
Dr Peter Mallett (Consultant Clinical Academic Paediatrician, RBHSC/QUB),
Dr Ben McNaughten (Consultant Paediatrician, RBHSC)

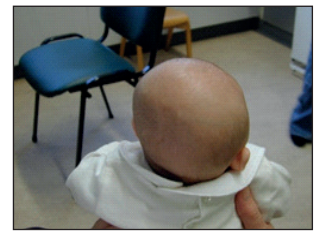
QUIZ 2 - PG Quiz



1. What is the diagnosis?
2. What signs might you notice on clinical assessment?
3. What are the complications of this condition if left untreated?

Megan O'Doherty (Year 4 Medical Student, Queen's University Belfast),
Dr Stephen Mullen (Paediatric Emergency Medicine Consultant, RBHSC),
Mr Mano Shanmuganathan (Consultant Paediatric Neurosurgeon, RBHSC)

QUIZ 3 - Historical



1. Who is the TV presenter in image (a) and what campaign did she launch?
2. Why might she inadvertently be responsible for the clinical signs seen in the infant shown in image (b)?

Cara Lucas (Year 4 Medical Student, Queen's University Belfast),
Mr Roy McConnell (Consultant Paediatric Neurosurgeon, RBHSC),
Dr Andrew Thompson (Consultant Paediatrician, RBHSC),
Dr Ben McNaughten (Consultant Paediatrician, RBHSC).

QUIZ 4 - And Finally...



1. Why is this the man we call when we have head problems?
2. Why might he also be useful if ship-wrecked on an "Island"?

Ruairi McGowan (Year 4 Medical Student, Queen's University Belfast),
Dr Andrew Thompson (Consultant Paediatrician, RBHSC),
Dr Ben McNaughten (Consultant Paediatrician, RBHSC)

CONSIDER CONTRIBUTING TO CURIOSITAS?

Please refer to 'Curiositas: Guidelines for contributors' <http://www.ums.ac.uk/curiositas.html> and email curiositas@ums.ac.uk with your ideas and submissions.



Curiositas: Answers

QUIZ 1

- The first image is a growth chart which demonstrates that the child has a rapidly increasing head circumference measurement which is crossing the centiles. The second image shows that the child has macrocephaly with distended scalp veins.
- The most likely diagnosis is hydrocephalus. Other clinical signs that may be present include a wide open or bulging fontanelle, a broad forehead, 'setting sun' eye sign or squint (strabismus). Common symptoms include general irritability, lethargy, vomiting, poor feeding and/or seizures. The underlying pathogenesis can often be attributed to an abnormality affecting either the production of, and/or drainage and/or reabsorption of, cerebrospinal fluid (CSF). Congenital causes include anatomical abnormalities such as neural tube defects (e.g. myelomeningocele or other forms of spina bifida), Chiari malformations, syndromic or genetic disorders. Acquired causes include hydrocephalus attributed to intracranial haemorrhage (particularly intraventricular haemorrhage secondary to prematurity), intracranial infections, or benign and neoplastic brain tumours.
- If a child is neurologically stable, non-surgical management may include close surveillance or pharmacologic management such as diuretics and corticosteroids, to decrease CSF production or aide reabsorption. In some acquired cases, such as infections and tumours, treating the cause may resolve the hydrocephalus. In acute or severe cases of hydrocephalus, surgical treatment is often required. This may involve ventriculoperitoneal (VP) shunt insertion or endoscopic third ventriculostomy (ETV). In cases of antenatal hydrocephalus, recent advances in foetal imaging and surgical techniques offer the possibility of in-utero surgical intervention, with potentially life-changing effects.
 - Thomale UW. Integrated understanding of hydrocephalus — a practical approach for a complex disease. *Childs Nerv Syst.* 2021;37(1):3313-24.
 - Deshmukh SN, Yadav AT. Clinical study and management of hydrocephalus in children. *Int Surg J.* 2020; 7(4): 1258-62.
 - Kahle KT, Kulkarni AV, Limbrick DD, Warf BC. Hydrocephalus in children. *Lancet.* 2016; 387(10020):788-99.
 - Tomyz LD, Hale AT, George TM. Emerging insights and new perspectives on the nature of hydrocephalus. *Pediatric Neurosurg.* 2017;52(6):361-8

QUIZ 2

- The diagnosis is sagittal craniosynostosis (scaphocephaly). Craniosynostosis involves the premature fusion of one or more of the cranial sutures. Scaphocephaly is the most common subtype, accounting for 40 to 55% of isolated cases. Other subtypes include coronal, metopic, lambdoid and syndromic.
- Scaphocephaly may present with progressive slowing of serial head circumference measurements on the infant's growth chart, ridging of the sutures, rhomboid (rugby ball) head shape and premature closure of the fontanelles. Clinical presentation alone is diagnostic in approximately 98% of patients.
- Complications associated with craniosynostosis include increased intracranial pressure and inhibition of brain growth from prolonged uncorrected restriction of cranial growth. There may also be associated impairments in cognitive and neurodevelopmental function, including global developmental delay, poor feeding and weight gain. Cranial nerve involvement can also result in visual, hearing and speech deficits. Poor self-esteem and social isolation can often occur due to the abnormal appearance.


- Greenwood J, Flodman P, Osann K, Boyadjiev SA, Kimonis V, *et al* Familial incidence and associated symptoms in a population of individuals with nonsyndromic craniosynostosis. *Genet Med.* 2014; 16(4):302-10.
- Hamm JA, Robin NH. Newborn craniofacial malformations: orofacial clefting and craniosynostosis. *Clin Perinatol.* 2015; 42(2):321-36, viii. doi: 10.1016/j.clp.2015.02.005
- Lazner M, Craver L, Goodhead H, Wilkinson H, Iliadis K. Paediatric Clinical Practice Guideline. Management of the odd shaped head (Plagiocephaly). Brighton: Brighton and Sussex University Hospitals, NHS Trust. 2020.

QUIZ 3

- This is Anne Diamond, a British TV presenter and journalist. She is well known from launching the 'Back to Sleep' campaign in December 1991, following the death of her son, Sebastian, in his cot at just four months old. This campaign sought to reduce the number of infant deaths from sudden infant death syndrome (SIDS). SIDS is classified as the sudden death of an infant that is considered healthy, usually during a period of sleep. By educating parents to place their babies on their back to sleep, it resulted in a reduction of SIDS cases in the UK. In 1989 there were 1,545 cases of SIDS and a year after the campaign was launched, the number of cases fell to 647 in 1992.
- As a result of her campaign, the incidence of positional plagiocephaly has increased. This is due to parents being advised to place their babies on their back (supine) whilst sleeping. Plagiocephaly is a medical term that refers to an asymmetrical appearance to an infant's head, that can result from placing a baby supine which leads to flattening and deformation of the back of the head. This positioning is supported by research that highlighted the correlation between SIDS and prone sleeping.
 - Kinney H, Thach, B. The sudden infant death syndrome. *N Engl J Med.* 2009; 361(8); 795-805.

QUIZ 4

- This is Mr Mano Shanmuganathan. Mr Shanmuganathan is a paediatric neurosurgeon appointed to the Belfast Trust in 2014. He is an expert in craniofacial abnormalities in children and runs a joint craniofacial clinic for children in Northern Ireland alongside neurosurgical colleagues in Liverpool's Alder Hey Children's Hospital. He trained as a Paediatric Neurosurgeon in Edinburgh and Aberdeen and completed his higher sub-speciality training in Paediatric Neurosurgery and Craniofacial Surgery in Great Ormond Street Hospital and the National Hospital for Neurology and Neurosurgery, London.



- In 2019 Mano survived being stranded on a desert island for 35 days as part of 'Treasure Island,' a TV show hosted by Bear Grylls. Not only did he survive, but he was crowned King of the Island taking home the cash prize which he subsequently donated to the Belfast Children's Hospital charity.



UMJ is an open access publication of the Ulster Medical Society (<http://www.ums.ac.uk>).

The Ulster Medical Society grants to all users on the basis of a Creative Commons Attribution-NonCommercial-ShareAlike 4.0 International Licence the right to alter or build upon the work non-commercially, as long as the author is credited and the new creation is licensed under identical terms.