

[ CASE REPORT ]

## Paraneoplastic Cerebellar Degeneration and Lambert-Eaton Myasthenic Syndrome with SOX-1 Antibodies

Shinichi Wada<sup>1</sup>, Mayu Kamei<sup>1</sup>, Naoko Uehara<sup>1,2</sup>, Koji Tsuzaki<sup>1,2</sup> and Toshiaki Hamano<sup>1,2</sup>

### Abstract:

A 69-year-old man was admitted to our hospital for progressive muscle weakness in both lower limbs and limb ataxia (day 0). Nerve conduction studies showed low compound muscle action potential amplitudes at rest and increased amplitudes after maximum voluntary contraction. Blood testing revealed SOX-1 antibodies. He was diagnosed with paraneoplastic cerebellar degeneration and Lambert-Eaton myasthenic syndrome (PCD-LEMS). He died from aspiration pneumonia on day 9. Small-cell lung carcinoma (SCLC), which had not been obvious on computed tomography, was found during the autopsy. Patients with PCD-LEMS who test positive for SOX-1 antibodies should be carefully evaluated for SCLC.

**Key words:** Lambert-Eaton myasthenic syndrome, paraneoplastic cerebellar degeneration, small cell lung carcinoma, SOX-1 antibodies, autopsy

(Intern Med 60: 1607-1610, 2021)

(DOI: 10.2169/internalmedicine.5934-20)

### Introduction

Lambert-Eaton myasthenic syndrome (LEMS) is a paraneoplastic or primary autoimmune neuromuscular junction disorder (1). In some LEMS cases, the mechanism involves voltage-gated calcium channel (VGCC) antibodies expressed on small-cell lung carcinomas (SCLCs), with the antibodies acting on presynaptic nerve terminals and diminishing the release of acetylcholine (2). Of all LEMS cases, 50% to 60% are related to SCLC, but 30% of patients with LEMS have no malignant tumors (3).

The presenting symptoms of LEMS are mainly muscle weakness in the limbs, especially the lower legs, and autonomic dysfunction. However, 10% of patients with LEMS develop limb ataxia and are classified as having paraneoplastic cerebellar degeneration with Lambert-Eaton myasthenic syndrome (PCD-LEMS) (4, 5). Most PCD-LEMS cases are associated with SCLC (6). In addition, SOX-1 antibodies, which are antibodies to glial nuclei in the cerebellum, are often found in patients with SCLC (7, 8). Thus, patients with PCD-LEMS associated with SOX-1 antibodies are more likely to have SCLC than those without these anti-

bodies, and a careful examination to find SCLC is necessary.

We herein report a patient with PCD-LEMS who tested positive for SOX-1 antibodies in whom computed tomography (CT) failed to detect any lung tumors, but a definitive diagnosis of SCLC was made by an autopsy.

### Case Report

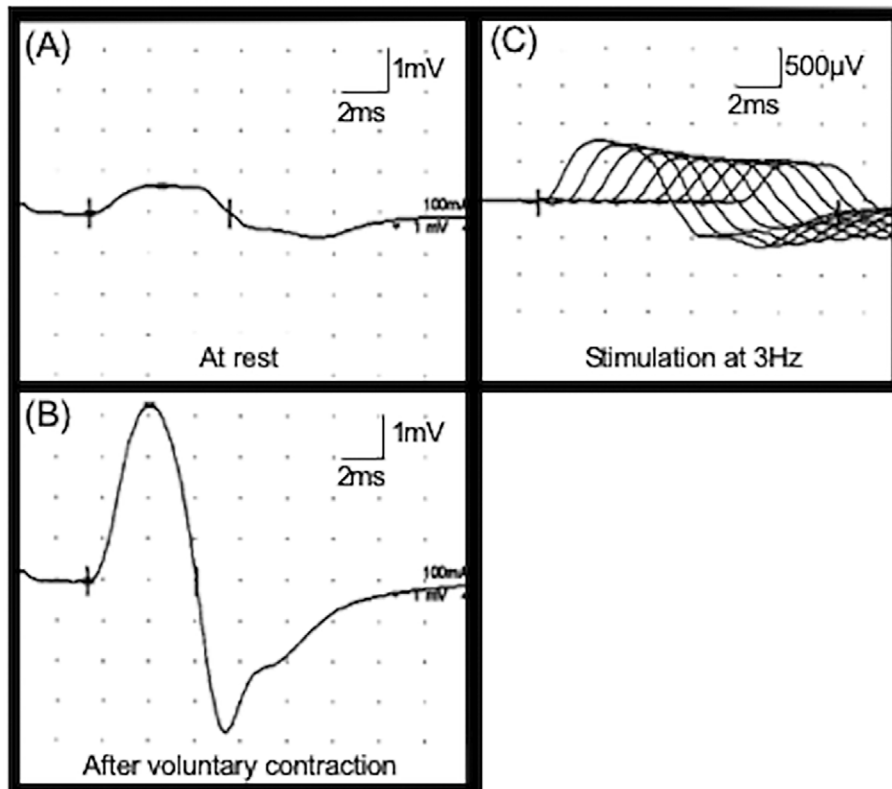
A 69-year-old man was admitted to our hospital with progressive gait disturbance (day 0). He had experienced difficulty walking for the seven months prior to admission. His symptoms gradually deteriorated, and he became unstable when standing on one leg. Two months prior to admission, he began to stagger when walking and required a handrail when using stairs. He had a medical history of dyslipidemia, and he previously smoked cigarettes (Brinkman index: 980).

He had a blood pressure of 86/49 mmHg and a body temperature of 36.8°C. A neurological examination revealed dysarthria, proximal muscle weakness of both lower limbs (Medical Research Council Scale for Muscle Strength: 4), limb ataxia, a wide-based gait, and dry mouth. Deep tendon reflexes were absent but recovered after voluntary contrac-

<sup>1</sup>Department of Neurology, Kansai Electric Power Hospital, Japan and <sup>2</sup>Division of Clinical Neurology, Kansai Electric Power Medical Research Institute, Japan

Received: July 21, 2020; Accepted: September 28, 2020; Advance Publication by J-STAGE: December 15, 2020

Correspondence to Dr. Shinichi Wada, ichi\_basstrombone@yahoo.co.jp



**Figure 1.** Nerve conduction studies of the right median nerve. (A) A low compound muscle action potential (CMAP) amplitude at rest (0.7 mV). (B) An increased CMAP amplitude after voluntary contraction (4.3 mV). (C) A decremental response on repetitive nerve stimulation testing at 3 Hz (30.5%).

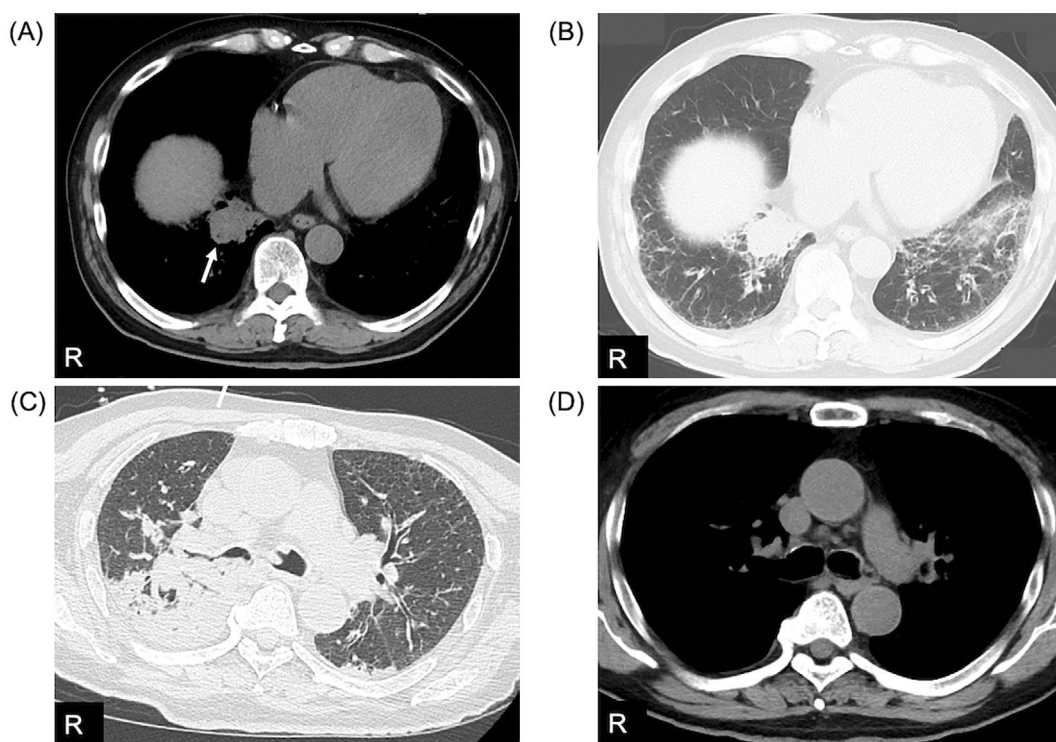
tion. The results from a complete blood count and biochemical testing, including liver and kidney function testing, were normal. He tested negative for anti-acetylcholine receptor and anti-muscle-specific tyrosine kinase antibodies. Cerebrospinal fluid analysis results were normal. Nerve conduction studies showed reduced compound muscle action potential (CMAP) amplitudes in the right median, ulnar, and tibial nerves. A pronounced CMAP amplitude increase was found in the right median nerve after strong contraction (Fig. 1A, B). Repetitive stimulation testing of the right median nerve showed a decremental response at 3 Hz (Fig. 1C). No obvious incremental response was observed by repetitive stimulation testing at 30 Hz. Chest CT on day 2 showed a 31-mm mass in the right lower hilar region and consolidation in both lower lobes of the lungs, suggesting aspiration pneumonia (Fig. 2A, B). No abnormality was found on brain magnetic resonance imaging or brain single-photon emission CT.

The patient was diagnosed with PCD-LEMS and treated with pyridostigmine 60 mg/day from day 5. However, his respiratory condition gradually deteriorated due to the pneumonia from day 6 (Fig. 2C), and he died on day 9. Other autoantibody blood test results were confirmed after his death, as follows: anti-P/Q-type VGCC antibodies (63.8 pmol/L, normal value:  $\leq 20.0$  pmol/L) and SOX-1 antibodies (+++) were positive, but other tumor-associated autoantibod-

ies, including Hu and Yo antibodies, were negative. An autopsy was performed, and the mass observed on CT was not a tumor but an abscess. However, an 18-mm tumor without metastasis, which not been detected by CT performed before the autopsy (Fig. 2D), was found in the right upper hilar region, and it was pathologically confirmed to be SCLC. We considered the final diagnosis to be PCD-LEMS associated with SCLC.

## Discussion

To our knowledge, this is the first reported case of PCD-LEMS with positive SOX-1 antibodies. SOX protein is considered to play a role in the differentiation of airway epithelial cells, and it is present in SCLC (7). SOX-1 antibodies react to the nuclei of Bergmann glial cells in the cerebellum and induce cerebellar ataxia (8, 9). As SOX-1 antibodies are found in 41% of patients with SCLC, they may indicate that PCD is associated with SCLC (3). In addition, SOX-1 antibodies are expected to be useful in distinguishing paraneoplastic LEMS from LEMS without malignant tumors (10). In a previous study, SOX-1 antibodies were negative in patients with LEMS without malignant tumors but positive in 64 % of patients with LEMS associated with SCLC (11). However, whether or not SOX-1 antibodies are helpful in diagnosing various neurological disorders, including PCD-



**Figure 2.** Chest computed tomography (CT) during admission. CT performed on day 2 showed a 31-mm mass in the right lower hilar region; this was found to be an abscess during the autopsy (arrow) (A). Consolidation due to pneumonia was detected (B). CT performed on day 8 showed the development of severe pneumonia (C). The autopsy revealed small-cell lung carcinoma (SCLC) in the right upper hilar region, although no mass lesion suggesting SCLC had been observed around this region on CT performed on day 2 (D). R: right

LEMS associated with SCLC, is unclear (12). Further studies will be needed to verify the clinical usefulness of SOX-1 antibodies.

Although the sensitivity of CT for detecting lung tumors was 88.9% in previous reports, we had difficulty identifying tumors on plain CT in the present case (13). Tumors present in the hilar regions are sometimes difficult to detect (14). Furthermore, SCLC in patients with LEMS patients may not be easy to detect at an early stage because immune reactions by antibodies in paraneoplastic syndromes may suppress tumor growth (2). Kanamori et al. also reported a patient with LEMS due to SCLC without an apparent primary lesion, although the results of SOX-1 antibody testing were not available (15). Our patient died within a short period, but we believe that additional examinations, including contrast-enhanced CT, bronchoscopy, and positron emission tomography-CT, would have been useful for SCLC detection because his blood examination revealed SOX-1 antibodies.

As an autopsy revealed the presence of SCLC for the first time in this case, supporting the fact that the primary lesion is often difficult to find in LEMS patients. Although SOX-1 antibodies, which indicate the presence of SCLC, are reportedly related to LEMS, the usefulness of measuring SOX-1 antibodies in patients with PCD-LEMS in clinical practice remains unclear. The potential presence of SCLC should be more carefully assessed in patients with PCD-LEMS who

test positive for SOX-1 antibodies, even if no mass lesion suggesting malignancy is detected by CT.

**The authors state that they have no Conflict of Interest (COI).**

## References

1. Kesner VG, Oh SJ, Dimachkie MM, Barohn RJ. Lambert-Eaton myasthenic syndrome. *Neuro Clin* **36**: 379-394, 2018.
2. Sutton I, Winer JB. The immunopathogenesis of paraneoplastic neurological syndromes. *Clin Sci* **102**: 475-486, 2002.
3. Stich O, Klages E, Bischler P, et al. SOX antibodies in sera from patients with paraneoplastic neurological syndromes. *Acta Neurol Scand* **125**: 326-331, 2012.
4. Nakao YK, Motomura M, Fukudome T, et al. Seronegative Lambert-Eaton myasthenic syndrome: study of 110 Japanese patients. *Neurology* **59**: 1773-1775, 2002.
5. Titulaer MJ, Wirtz PW, Kuks JBM, et al. The Lambert-Eaton myasthenic syndrome 1988-2008: a clinical picture in 97 patients. *J Neuroimmunol* **201-202**: 153-158, 2008.
6. Koriyama H, Kyoraku I, Yamashita S, Shiomi K, Matsumoto N, Nakazato M. Synchronous appearance and improvement with anti-cancer chemotherapy of paraneoplastic cerebellar degeneration and Lambert-Eaton myasthenic syndrome complicated with small cell lung cancer. *Rinsho Shinkeigaku* **53**: 104-108, 2013 (in Japanese, Abstract in English).
7. Lipka AF, Verschuuren JJGM, Titulaer MJ. SOX1 antibodies in Lambert-Eaton myasthenic syndrome and screening for small cell lung carcinoma. *Ann N Y Acad Sci* **1275**: 70-77, 2012.

8. Tschernatsch M, Gross O, Kneifel N, Kaps M, Blaes F. SOX-1 autoantibodies in patients with paraneoplastic neurological syndromes. *Autoimmun Rev* **8**: 549-551, 2009.
9. Sabater L, Titulaer M, Saiz A, Verschuuren A, Gure AO, Graus F. SOX1 antibodies are markers of paraneoplastic Lambert-Eaton myasthenic syndrome. *Neurology* **70**: 924-928, 2008.
10. Sabater L, Hoftberger R, Boronat A, Saiz A, Dalmau J, Graus F. Antibody repertoire in paraneoplastic cerebellar degeneration and small cell lung cancer. *PLoS One* **8**: e60438, 2013.
11. Titulaer MJ, Klooster R, Potman M, et al. SOX antibodies in small-cell lung cancer and Lambert-Eaton myasthenic syndrome: frequency and relation with survival. *J Clin Oncol* **27**: 4260-4267, 2009.
12. Berger B, Dersch R, Ruthardt E, Rasiah C, Rauer S, Stich O. Prevalence of anti-SOX-1 reactivity in various neurological disorders. *J Neurol Sci* **369**: 342-346, 2016.
13. Toyoda Y, Nakayama T, Kusunoki Y, Iso H, Suzuki T. Sensitivity and specificity of lung cancer screening using chest low-dose computed tomography. *Br J Cancer* **98**: 1602-1607, 2008.
14. Miki S, Nomura Y, Hayashi N, et al. Prospective study of spatial distribution of missed lung nodules by readers in CT lung screening using computer-assisted detection. *Acad Radiol*. Forthcoming.
15. Kanamori K, Yahata T, Otsuka K, Imanaka M, Yokota I. A case of small cell lung carcinoma without apparent primary lesion accompanying Lambert-Eaton myasthenic syndrome. *Nihon Kokyuki Gakkai Zasshi* **47**: 1151-1155, 2009 (in Japanese, Abstract in English).

The Internal Medicine is an Open Access journal distributed under the Creative Commons Attribution-NonCommercial-NoDerivatives 4.0 International License. To view the details of this license, please visit (<https://creativecommons.org/licenses/by-nc-nd/4.0/>).