



Since January 2020 Elsevier has created a COVID-19 resource centre with free information in English and Mandarin on the novel coronavirus COVID-19. The COVID-19 resource centre is hosted on Elsevier Connect, the company's public news and information website.

Elsevier hereby grants permission to make all its COVID-19-related research that is available on the COVID-19 resource centre - including this research content - immediately available in PubMed Central and other publicly funded repositories, such as the WHO COVID database with rights for unrestricted research re-use and analyses in any form or by any means with acknowledgement of the original source. These permissions are granted for free by Elsevier for as long as the COVID-19 resource centre remains active.



ELSEVIER



Research

Chest Computed Tomography findings in patients with corona virus disease 2019 (COVID-19): An initial experience in three centres in Ghana, West Africa

Benjamin Dabo Sarkodie, MD, FWACS^a, Yaw Boateng Mensah, MBChB, FWACS^{a*}, Harold Ayetey^b, Klenam Dzeffi-Tettey^c, Edmund Brakohiapa^a, Andrew Kaminta^d and Ewurama Idun^e

^a Department of Radiology, University of Ghana Medical School, Accra, Ghana

^b Department of Medicine, University of Cape Coast School of Medicine, Cape Coast, Ghana

^c Department of Radiology, Korlebu Teaching Hospital, Accra, Ghana

^d Department of Radiology, Quest Medical Imaging Center, Accra, Ghana

^e Department of Radiology, 37 Military Hospital, Accra, Ghana

ABSTRACT

Background: Radiological examinations have a significant role in the diagnosis and management of Coronavirus disease 2019 (COVID-19), the disease caused by the novel coronavirus SARS-CoV-2. Many COVID-19 patients show typical Chest Computed Tomography (CT Scan) features which can aid in the diagnoses and triaging of such patients. This is especially so in resource-limited settings where access to molecular diagnostic techniques such as Reverse Transcription Polymerase Chain Reaction (RT-PCR) is not optimal. We report chest CT findings in 28 patients diagnosed with COVID-19 in Ghana.

Objective: To document common chest CT scan findings amongst patients with COVID-19 infection in Ghana.

Method: Chest CT scans of twenty-eight COVID-19 patients (n = 28) were retrieved and reviewed independently by two experienced radiologists and their findings documented. Two 64 and one 32 slice spiral CT scanners were used at three centres.

Results: Chest CT Images from 16 males (57.1.7%) and 12 females (42.9%) patients aged between 36 and 65 years with mean age of 55.9 years (SD-8.4years) were evaluated. Of these, 21 (75.0%) of them were COVID-19 patients who were undiagnosed at the time of imaging while 7 (25.0%) were known confirmed COVID-19

patients. On the chest CT scans (n = 28), 17 (66.7%) patients showed predominantly ground glass opacities while 12 (42.9%) had evidence of consolidation predominantly. In 26 (92.9%) of the patients, the opacities were bilateral and peripheral in distribution. None of these patients had pleural effusion.

Conclusion: COVID-19 patients tend to manifest typical imaging features on chest CT scan. The most common chest imaging finding was bilateral, peripheral and predominantly basal ground glass opacities. Importantly, these findings were frequently obtained before PCR diagnosis. Chest CT scan can help in the diagnosis and triaging of suspected or confirmed COVID-19 patients in jurisdictions with limited PCR diagnostic capacity and can improve early isolation, contact tracing and treatment thus helping to reduce community spread, morbidity and mortality.

RÉSUMÉ

Contexte : Les examens radiologiques jouent un rôle important sans le diagnostic et la gestion de la maladie à coronavirus 2019 (COVID-19), la maladie causée par le nouveau coronavirus SARS-CoV-2. Plusieurs patients atteints de la COVID-19 présentent des caractéristiques typiques dans les radiographies et tomodensitométries

Contributors: All authors contributed to the conception or design of the work, the acquisition, analysis, or interpretation of the data. All authors were involved in drafting and commenting on the paper and have approved the final version.

Funding: This study did not receive any specific grant from funding agencies in the public, commercial, or not-for-profit sectors.

Competing interests: All authors have completed the ICMJE uniform disclosure form at www.icmje.org/coi_disclosure.pdf and declare: no financial relationships with any organizations that might have an interest in the submitted work in the previous three years; no other relationships or activities that could appear to have influenced the submitted work.

Ethical approval: Before this study ethical clearance was sought and approved by the Euracare Ethics and Research protocol committee (Ref Number EADHC 102/20-20). The study was also in compliance with the Helsinki declaration.

* Corresponding author.

E-mail address: ybmensah@yahoo.com (Y.B. Mensah).

(TDM) thoraciques qui peuvent aider au diagnostic et au triage de ces patients. C'est particulièrement le cas dans les milieux où les ressources sont limitées, où l'accès aux techniques de diagnostic moléculaire comme l'analyse par RT-PCR (Reverse Transcription Polymerase Chain Reaction) n'est pas optimal. Nous présentons un rapport sur les constats des TDM et radiographies thoraciques pour 12 patients ayant reçu un diagnostic de COVID-19 au Ghana.

Objectif : Documenter les constats communs en radiographie et TDM thoraciques chez les patients ayant une infection liée à la COVID-19 au Ghana.

Méthodologie : Les TDM thoraciques de neuf patients et les radiographies thoraciques de trois patients atteints de la COVID-19 (n = 12) ont été extraits et examinés de façon indépendante par deux radiologues expérimentés, et leurs conclusions ont été documentées. Deux appareils de TDM à 64 coupes et un appareil à 32 coupes ont été utilisés dans trois centres. Une machine de radiographie numérique a été utilisée pour obtenir les radiographies thoraciques.

Résultats : Les images de huit hommes (66,7%) et quatre femmes (33,3%) âgés de 36 à 65 ans (âge médian: 52,9, écart-type: 8,7 ans) ont été évaluées. Cinq de ces patients (41,7%) étaient des

Keywords: COVID-19; Chest; CT; SARS; Imaging

Introduction

The novel coronavirus disease 2019 (COVID-19) is an infectious disease caused by the severe acute respiratory syndrome coronavirus-2 (SARS-CoV-2).^{1,2} SARS-CoV-2 is related to severe acute respiratory syndrome (SARS) and Middle East respiratory syndrome (MERS), which are also members of the coronavirus family responsible for respiratory complications including acute respiratory distress syndrome (ARDS).

The first three cases were reported in Wuhan, China, in December 2019 before spreading to many parts of the world by February 2020.² The World Health Organisation (WHO) confirmed reports of person-to-person spread and subsequently declared the disease a pandemic on March 11, 2020.^{3,4} Since being declared a pandemic, COVID-19 has spread rapidly to over 210 countries and territories, with over 23 million cases and 808,681 deaths reported globally with 43,622 confirmed cases with 263 deaths in Ghana as at August 24, 2020 according to the Johns Hopkins University Coronavirus Resource Centre website (<https://coronavirus.jhu.edu/map.html>).

Fever, cough, and difficulty in breathing are common COVID-19 symptoms.⁵ Like all epidemics, the best way to prevent widespread transmission is to test, isolate, and treat individuals with suspected or confirmed COVID-19.⁶ The gold standard for testing for the novel coronavirus is the Reverse Transcription Polymerase Chain Reaction (RT-PCR) method.⁶⁻⁸ Due to the highly transmissible nature of COVID-19, the number of individuals who require testing is typically very high and potentially overwhelming for health systems. Indeed, problems with testing efficiency, reliability,

patients COVID-positifs qui n'avaient pas reçu de diagnostic au moment de l'imagerie, alors que sept (58,3%) avaient déjà reçu un diagnostic positif. Parmi les patients ayant eu une TDM thoracique (n = 9), six (66,7%) présentaient principalement des infiltrats en verre dépoli alors que quatre (44,4%) présentaient principalement des signes de consolidation. Chez sept patients (77,8%), les infiltrats affichaient une distribution bilatérale et périphérique. Toutes les radiographies thoraciques présentent une consolidation bilatérale et périphérique, principalement dans les lobes pulmonaires inférieurs.

Conclusion : Les patients atteints de la COVID-19 tendent à présenter des caractéristiques typiques sur les images radiographiques et TDM thoraciques. L'aspect le plus fréquent en imagerie thoracique est un infiltrat en verre dépoli bilatéral, périphérique et principalement basal. Il est important de noter que ces constats ont souvent été obtenus avant le diagnostic PCR. Les images radiographiques et TDM thoraciques peuvent donc aider au diagnostic et au triage des patients chez qui une infection COVID-19 est suspectée ou confirmée dans les régions présentant une capacité d'analyse RT-PCR limitée et peuvent améliorer les décisions d'isolement précoce, de traçage des contacts et de traitement, contribuant ainsi à réduire la contamination communautaire, la morbidité et la mortalité.

and delays with results availability have been reported,⁷ with obvious implications for disease control and transmission prevention.

Typical chest radiograph and computed tomography (CT) scan findings in COVID-19 patients have recently been published in several reputable journals.⁹⁻¹² Atypical or organising pneumonia with airspace opacities (akin to consolidation or ground glass opacities) with bilateral, peripheral, and bi-basal predominant distribution were considered typical findings of the disease. Pleural effusion is considered a rare feature.¹² These reported typical CT features are clearly important for diagnosis and/or triaging of patients with COVID-19.

Chest radiography is the first-line imaging modality in the management of patients with COVID-19 in many centres due to its availability and portability, especially in resource-limited settings, although it has a low sensitivity.¹² Some hospitals have dedicated CT scan suites for imaging of COVID-19 patients but many more lack that level of imaging capacity. Contamination is a big issue in the imaging of COVID-19 patients. The decontamination required after imaging can adversely affect workflow in radiology units. Indeed, the American College of Radiology recommends the use of mobile X-ray units for these patients as they are easier to decontaminate.¹² A significant number of patients who initially test negative on the RT-PCR test but have characteristic COVID-19 features on chest imaging have tested positive on a PCR second test.^{13,14}

Though a lot of information on imaging findings of COVID-19 has been documented in parts of Asia and the West, no such information is available in Ghana and West Africa. The majority of cases in March 2020 and soon after were

Table 1
Characteristics of the CT scanner used at the study centres.

Parameter	Centre 1	Centre 2	Centre 3
Scanner Make	Canon Aquilion Start 32	Siemens SOMATOM Perspective 64	GE Discovery 64
Model	TSX-037A	10,495,243	CT 750
Year Of Manufacture	2019	2015	2016
Tube Voltage	120 kv	120 kv	120 kv
Matrix	512 × 512	512 × 512	512 × 512
Slice thickness	1 mm	1 mm	1 mm
Detector width	0.625 mm	0.625 mm	0.625

imported. Given the increasing number of infected individuals locally and globally as well as the establishment of community transmission it is necessary for radiologists, radiographers and clinicians managing COVID-19 to be conversant with the key chest imaging findings of the disease in Ghanaian patients. These imaging findings might be helpful for the identification and management of COVID-19 patients, particularly in resource-limited settings where delays and false negative test results could have massive implications for disease control. This study aims to document the chest CT scan findings in patients who were affected by the COVID-19 in the early stages of the disease in Ghana and find out if the imaging pattern are similar or different to what has been documented in literature.

Methods

Before this study ethical clearance was sought and approved by the Euracare Ethics and Research protocol committee (Ref Number EADHC 102/20-20). The study was also in compliance with the Helsinki declaration.

Chest CT scan findings of 28 COVID-19 patients were retrieved from the Picture Archiving and Communication System (PACS) of the radiology units of the Korle Bu Teaching Hospital, Euracare Advanced Diagnostic and Heart Centre and Quest Imaging Centre all in Accra, Ghana. All images were reviewed independently by two radiologists with 8 and 15 years of experience, respectively. The radiologists were blinded to the RT-PCR status of the patients at the time they were reading the images and they were asked

Table 2
Demographic and clinical characteristics of patients who had CT scan and chest radiography.

	Age	Sex	Comorbidities	Drug history	Symptoms	Initial COVID-19 PCR test results	Key imaging finding
1	61	M	DM	NIL	General Malaise, Dyspnea	Unknown	GGO,ST
2	42	M	NIL	NIL	Cough	Positive	GGO,CDN
3	46	F	HPT	NIL	Fever, Chest pain	Positive	GGO,ST
4	54	M	NIL	NIL	Cough	Unknown	GGO
5	60	F	NIL	NIL	Chest Pain	Unknown	GGO,CDN
6	56	M	NIL	NIL	Dyspnea	Positive	GGO,CDN
7	54	F	NIL	HCQ	Cough	Unknown	GGO,CDN
8	65	F	NIL	HCQ	Dyspnea	Positive	Normal
9	36	M	NIL	HCQ	Dyspnea	Positive	Nor mal
10	30	F	UNKNOWN	NIL	Malaise	Unknown	GGO
11	34	F	UNKNOWN	NIL	Cough	Unknown	GGO
12	50	M	UNKNOWN	NIL	Malaise	Unknown	GGO
13	64	M	UNKNOWN	NIL	Cough	Unknown	GGO
14	60	M	UNKNOWN	NIL	Cough and Malaise	Unknown	GGO,ST
15	67	M	UNKNOWN	NIL	breathlessness	Unknown	GGO,ST
16	77	F	UNKNOWN	NIL	Cough	Unknown	GGO
17	38	M	UNKNOWN	NIL	Cough	Unknown	GGO
18	39	M	UNKNOWN	NIL	Malaise	Unknown	GGO
19	52	M	UNKNOWN	NIL	Cough	Unknown	GGO
20	50	F	UNKNOWN	NIL	PE	Unknown	GGO,CDN
21	79	M	UNKNOWN	NIL	Malaise	Unknown	GGO
22	78	M	UNKNOWN	NIL	Malaise	Unknown	GGO,CDN
23	67	M	UNKNOWN	NIL	Respiratory distress	Unknown	GGO
24	50	F	UNKNOWN	NIL	Cough	Unknown	GGO,CDN
25	59	F	UNKNOWN	NIL	Malaise	Unknown	GGO,CDN
26	53	M	UNKNOWN	NIL	Cough	Unknown	GGO,CDN
27	65	M	UNKNOWN	NIL	Malaise	Unknown	GGO,CDN
28	58	F	UNKNOWN	NIL	Malaise	Unknown	GGO,CDN

Key: M, Male; F, Female; GGO, Ground glass opacities; CDN, Consolidation; ST, Intra/interlobular thickening.

to document the imaging features suggestive of COVID-19 pneumonia on the images as has been reported in literature. Differing conclusions were resolved by consensus with a third radiologist of 12 years' experience.

Patients with confirmed or suspected COVID-19 infection were imaged between 20 March and July 20, 2020. Chest CT scan images were acquired using a 32 slice Canon and two 64 slice Siemens and Canon spiral CT scanners respectively (Table 1). Non contrast enhanced chest images were acquired. The optimum tube voltage, matrix, slice thickness and tube current for each machine were set appropriately. All patients were scanned in the supine position and at end-inspiration from the cricoid cartilage to the L2 vertebrae ensuring the entire lung is imaged. Appropriate post-processing of images was undertaken and digitally stored at the imaging institution. Patients' name and other identifiers were kept confidential.

The patients who had CT scan at these centres did not have prior chest radiographs in the imaging archives used for the study. Those who had chest radiographs did not have any CT scan study at the time of this study.

Results

Chest CT scan images of 16 (57.1%) males and 12 (42.9%) females patients aged between 36 and 65 years with a mean age of 55.9 years (SD-8.4 years) were evaluated in the study.

A total of 28 CT scan images were evaluated. Twenty-one (75.0%) of them were undiagnosed COVID-19 patients at the time of imaging while seven (25.0%) were known confirmed COVID-19 patients. The demographic characteristics, clinical features and key imaging findings of the patients have been summarised in Tables 2 and 3. Of the patients who had a chest CT scan, 17 (60.7%) showed predominantly ground glass opacities (Fig. 1) while 12 (42.9%) had predominant consolidation (Fig. 2). In 26 patients (92.9%), the opacities were bilateral and peripheral in distribution. Other features noted were bronchiectasis in 2 patients (7.1%), ground glass opacities with intra- and interlobular septal thickening (crazing paving-Fig. 3) in 4 patients (14.3%). Fourteen patients showed both consolidation and ground glass opacities (Fig. 3) whilst 2 patients had normal CT scan findings.

Table 3
Commonly observed radiological features in patients studied.

Chest ct scan findings	No of patients n (%)
Bilateral and peripheral disease pattern	26 (92.9)
Consolidation	12 (42.9)
Ground glass opacities	17 (60.1)
Bronchiectasis	2 (22.2)
Crazy paving	4 (22.2)
Bronchovascular thickening	3 (33.3)
Pleural effusion	0 (0)
Normal	2 (22.2)

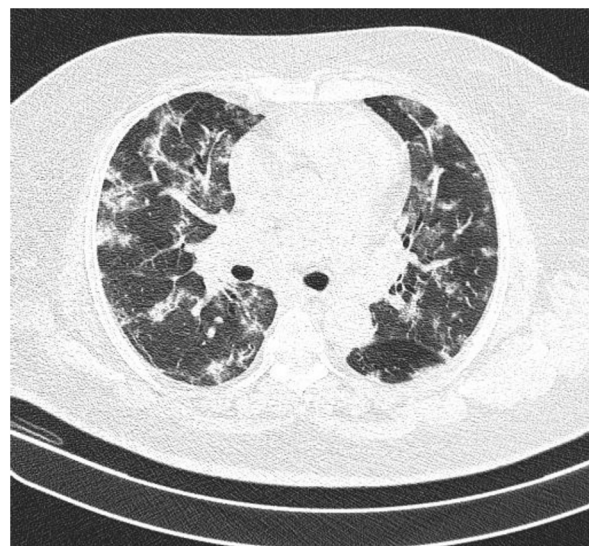


Fig. 1. Axial CT scan of the thorax, lung window showing diffuse ground glass opacities in both lung fields.

Discussion

Many of the recognised radiological features of COVID-19 are observed on chest CT scan, which has been reported to be a very sensitive imaging tool for diagnosing COVID-19 pneumonia.^{11,15} It is more sensitive than chest radiography. This has been attributed to the relative timing of chest radiography versus chest CT imaging in the management of the disease. Chest radiography is often performed at the onset of symptoms, when the disease may be mild, thus yielding insignificant or less marked imaging findings. Chest CT scans are often done when patients have a relatively severe illness at the onset of the disease or further along in the course of their

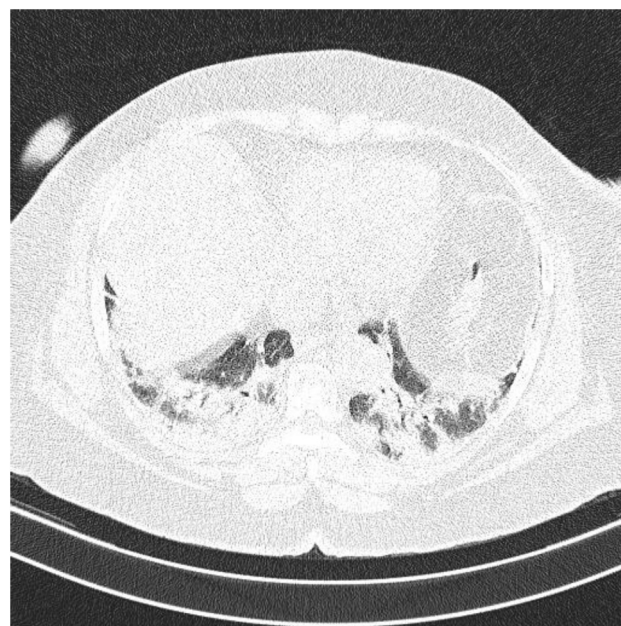

Fig. 2. Axial CT scan of the Thorax showing consolidation at both lung bases.

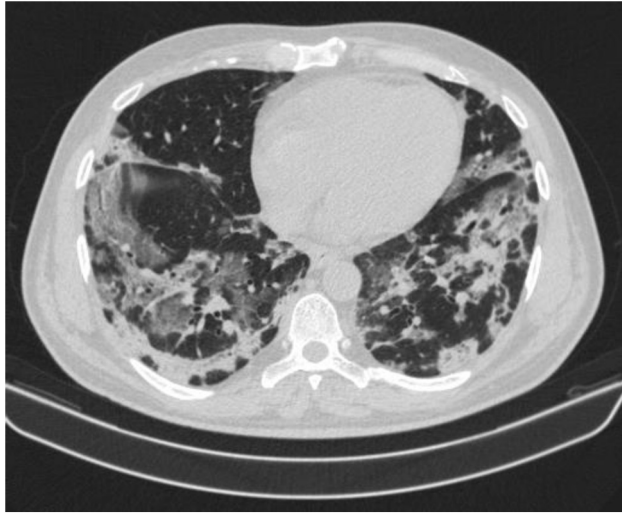


Fig. 3. Axial CT scan of the Thorax showing a combination of crazy paving and consolidation.

disease when they more likely to manifest documented characteristic imaging findings of COVID-19.¹⁶ This was evident in our study. The CT scan finding noted in our patients were consistent with what has been documented supporting the believe that CT scan can play a major role in the management of COVID-19 patient in Ghana as has been done elsewhere.

The major characteristic findings on chest CT for the coronavirus disease 2019 in our study was ground-glass opacity 60.9%, followed by consolidation 42.9%, with 14.3% showing a “crazy-paving” pattern. These findings are consistent with chest CT findings in a study of 62 COVID-19 patients in China which also found ground glass opacities in 61.3% and consolidation in 35.5% of the patients.^{13,16} Other studies have demonstrated bilateral, subpleural ground glass opacities on their initial CT scans.¹⁷ None of the patients presented with pleural effusion supporting reports that pleural effusion is a rare imaging finding in COVID-19 patients.¹²

In our study, chest CT scans features suggestive of COVID-19 significantly aided clinical decision-making, leading to the rapid isolation of twenty-three patients prior to PCR confirmation of SARS-CoV-2 infection. This emphasises the need for radiologists and clinicians to be conversant with imaging findings of COVID-19. Chest CT scan can be a useful adjunct in the management of COVID-19 cases in Ghana, where access to PCR testing and test results has been sub-optimal. This is complemented by the fact that CT scan centres are currently more available than RT-PCR testing sites in Ghana. This imaging modality may therefore be helpful in efforts to limit the spread of the disease by helping to identify patients and their contacts while awaiting their RT-PCR results.¹²

Two of our patients whose RT-PCR results were not known at the time of imaging subsequently tested negative. However, due to their highly suggestive CT scan findings, the RT-PCR tests were repeated, and they came out positive. The initial false negative RT-PCR results despite significant

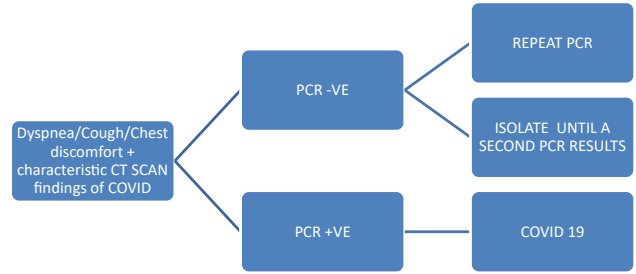


Fig. 4. Suggested algorithm for patients with characteristic COVID findings on Chest CT with negative PCR.

chest imaging findings have also been attributed to sampling errors which result in insufficient cellular material for detection or improper extraction of nucleic acids from clinical materials.¹⁶ Like us, many centres now recommend a second or even a third PCR test for patients presenting with symptoms attributable to SARS-CoV-2 infection despite a negative PCR test especially in the context of characteristic chest CT findings.¹³

We suggest that patients with symptoms of COVID-19 and highly suggestive CT scan of the chest imaging findings, but a negative PCR test result should have a repeat PCR test. An algorithm for such patients (Fig. 4) is recommended.

It is worth mentioning that the significant role of imaging in the management of COVID-19 calls for the education of radiographers on these basic chest imaging findings in these patients. This will help improve patient management by the radiologists, especially those who may not review images in real-time. It will also ensure that a proper cleaning protocol is followed after imaging of previously unsuspected cases, that demonstrate characteristic radiological features of COVID-19.

The study is limited by the fact that all the patients whose images were used did not have repeat imaging to follow disease progression. The total sample size is also small; therefore, biases cannot be eliminated.

Conclusion

COVID-19 patients tend to manifest typical imaging features on chest CT scan and radiography images. The most common chest imaging finding was bilateral, peripheral and predominantly basal ground glass opacities. Importantly, these findings were frequently obtained before PCR diagnosis. Chest CT scan and radiography can help in the diagnosis and triaging of suspected or confirmed COVID-19 patients in jurisdictions with limited PCR diagnostic capacity and can improve early isolation, contact tracing and treatment thus helping to reduce community spread, morbidity and mortality.

References

1. Shereen MA, Khan S, Kazmi A, Bashir N, Siddique R. COVID-19 infection: origin, transmission, and characteristics of human coronaviruses. *J Adv Res.* 2020;24:91–98.

2. Zhu N, et al. A novel coronavirus from patients with pneumonia in China, 2019. *N Engl J Med.* 2020;382(8):727–733.
3. Yu P, Zhu J, Zhang Z, Han Y, Huang L. A familial cluster of infection associated with the 2019 novel coronavirus indicating potential person-to-person transmission during the incubation period. *J Infect Dis.* 2020;221:1757–1761.
4. Li Q, et al. Early transmission dynamics in Wuhan, China, of novel coronavirus-infected pneumonia. *N Engl J Med.* 2020;382(13):1199–1207.
5. Rabaan AA, et al. SARS-CoV-2, SARS-CoV, and MERS-COV: a comparative overview. *Infez Med.* 2020;28(2):174–184.
6. Huang C, et al. Clinical features of patients infected with 2019 novel coronavirus in Wuhan, China. *Lancet.* 2020;395(10223):497–506.
7. Lippi G, Simundic AM, Plebani M. Potential preanalytical and analytical vulnerabilities in the laboratory diagnosis of coronavirus disease 2019 (COVID-19). *Clin Chem Lab Med.* 2020. <https://doi.org/10.1515/cclm-2020-0285>.
8. Uhteg K, et al. Comparing the analytical performance of three SARS-CoV-2 molecular diagnostic assays. *J Clin Virol.* 2020;127:104384.
9. Chung M, et al. CT imaging features of 2019 novel coronavirus (2019-nCoV). *Radiology.* 2020;295(1):202–207.
10. Lei P, Huang Z, Liu G, et al. Clinical and computed tomographic (CT) images characteristics in the patients with COVID-19 infection: what should radiologists need to know? *J X Ray Sci Technol.* 2020. <https://doi.org/10.3233/XST-200670>.
11. Wang H, Wei R, Rao G, Zhu J, Song B. Characteristic CT findings distinguishing 2019 novel coronavirus disease (COVID-19) from influenza pneumonia. *Eur Radiol.* 2020. <https://doi.org/10.1007/s00330-020-06880-z>.
12. Wong HYF, Lam HY, Fong AH, et al. Frequency and distribution of chest radiographic findings in COVID-19 positive patients. *Radiology.* 2019;201160.
13. Xue H, Jin Z. The appropriate position of radiology in COVID-19 diagnosis and treatment-current status and opinion from China. *Chin J Acad Radiol.* 2020:1–3.
14. Ai T, Yang Z, Hou H, et al. Correlation of chest CT and RT-PCR testing in coronavirus disease 2019 (COVID-19) in China: a report of 1014 cases. *Radiology.* 2020:200642.
15. Di Gennaro F, Pizzol D, Marotta C, et al. Coronavirus diseases (COVID-19) current status and future perspectives: a narrative review. *Int J Environ Res Public Health.* 2020;17(8):4.
16. Zhou Z, Guo D, Li C, et al. Coronavirus disease 2019: initial chest CT findings. *Eur Radiol.* 2020:1–9.
17. Shi H, Han X, Jiang N, et al. Radiological findings from 81 patients with COVID-19 pneumonia in Wuhan, China: a descriptive study. *Lancet Infect Dis.* 2020;20(4):425–434.