

Bilateral Orbital Cavernous Hemangioma

Abstract

Cavernous hemangioma of the orbit (CHO) is a benign slow-growing lesion of intracanal space. Bilateral orbital cavernous hemangiomas are extremely rare, so that only a few cases have been reported in scientific literature. A 54-year-old patient presented a 1-year history of impaired visual acuity of the left eye. Physical examination showed a left axial proptosis. Orbital magnetic resonance imaging showed a 28 mm diameter intraconal space mass of the left orbit, as well as another 11 mm diameter lesion in the right eye, in the superomedial extraconal space. A superior wall left orbitotomy was performed with a total removal of the tumor. The right lesion was respected. Histopathological examination confirmed the diagnosis of CHO. Bilateral cavernous hemangiomas are extremely rare. Orbital imaging guides the diagnosis. The neurosurgeons prefer craniotomy while ophthalmologists favor various modifications of orbitotomies.

Keywords: *Bilateral, cavernous hemangioma, orbit*

Introduction

Cavernous hemangioma of the orbit (CHO) is a benign slow-growing lesion of intraconal space.^[1] It consists of large dilated venous channels with fibrous, well-delineated capsule, and hemosiderin deposition.^[2] Its most common presentation is an unilateral mass in the lateral part of the middle third of the orbit.^[1,2]

Cavernous hemangioma is considered to be almost always unilateral and bilateral cases have been rarely reported.^[3]

In this paper, we report a new case of a bilateral orbital cavernous hemangioma.

Case Report

A 54-year-old male presented to the hospital, with a 1-year history of impaired visual acuity and proptosis of the left eye. Visual acuity was 8/10 in the left eye and 10/10 in the right eye. There was 8 mm of left axial proptosis. No ocular deviation or restriction in motility was observed in ophthalmic examination. Both eyes had unremarkable anterior segments and normal intraocular pressure. Orbital magnetic resonance imaging (MRI) showed a round and well-defined homogenous mass, 28 mm in diameter in intraconal space of the left orbit, and a similar lesion making 11 mm in diameter in the superomedial extraconal

space of the right eye. These lesions were hypointense on T1-weighted images and isointense on T2-weighted images with marked uniform enhancement after gadolinium injection [Figure 1]. These were compatible with bilateral orbital cavernous hemangiomas.

A supraorbital craniotomy was performed for the left side, using an eyebrow incision. We found that the lesion consisted of large encapsulated raspberry-colored soft mass. The tumor was totally removed [Figure 2]. The right lesion was respected since the patient was totally asymptomatic of the right eye.

Histopathological examination confirmed the diagnosis of cavernous hemangioma.

Discussion

Cavernous hemangiomas are the most common intraorbital vascular lesions in adults.^[1] They are benign vascular malformation characterized by multiple large vascular channels covered by endothelial cells and abundant stroma.^[4] The vascular lumen is filled with blood and variable regions of intralumenal thrombosis, reflecting vascular stasis/extremely slow flow. Endothelial cells appear as mature vascular elements. The stromal structure shows perivascular hypercellularity or hyperplastic elements related to neovascular activity.^[4] Therefore, relatively little literature is dedicated to

**Aslam Hentati,
Nidhal Matar,
Hadhemi Dridi,
Soufien Bouali,
Hafedh Jemel**

Department of Neurosurgery, El Manar-Tunis university, Faculty of Medicine of Tunis, National Institute of neurology, Tunis, Tunisia

Address for correspondence:
Dr. Nidhal Matar,
University El Manar of
Tunis, Tunis, Tunisia.
E-mail: matarnidhal2007@
yahoo.fr

Access this article online

Website: www.asianjns.org

DOI: 10.4103/ajns.AJNS_96_17

Quick Response Code:



How to cite this article: Hentati A, Matar N, Dridi H, Bouali S, Jemel H. Bilateral orbital cavernous hemangioma. *Asian J Neurosurg* 2018;13:1222-4.

This is an open access journal, and articles are distributed under the terms of the Creative Commons Attribution-NonCommercial-ShareAlike 4.0 License, which allows others to remix, tweak, and build upon the work non-commercially, as long as appropriate credit is given and the new creations are licensed under the identical terms.

For reprints contact: reprints@medknow.com

describe their pathophysiology. They occur most often in women (60%–70%), during the fourth to fifth decades of life and slowly enlarge with a progressive proptosis, frequently associated with diplopia.^[1] Cavernous hemangiomas are usually solitary and most often occur in the lateral part of the retrobulbar intraconal space. Rarely do they present as unilateral multiple lesions, while bilateral lesions seem to be extremely rare. To our knowledge, 11 cases have been reported about bilateral CHOs, so far all those cases are resumed in the [Table 1].^[2,3,5-11]

Neither paper nor literature review evaluated until now the incidence of such bilateral lesions and was considered as rare.^[10] However, Paonessa *et al.* reported that 3 out of the 14 patients in their series (more than 21%) had bilateral lesions. That could suggest that bilateral cavernous hemangioma may not be that uncommon.^[2] In all reported

cases, the symptoms were unilateral and interested only the orbit harboring the larger mass.

The diagnosis of cavernous hemangiomas is highly suggested in computed tomography (CT) and MRI images. It is typically well-circumscribed, round, or ovoid, homogeneously hyper-attenuating, intraconal lesions. They occasionally contain microcalcifications (phleboliths) and may produce expansion of the orbital walls.^[12] The lesions may displace adjacent structures but do not invade them. At multiphase dynamic contrast material – enhanced CT, poor enhancement is noted in the early arterial phase because of the low-flow arterial supply; contrast material does not fill the central part of the lesion until the late venous phase. At MRI, the signal in cavernous malformations usually appears isointense to that of muscle on T1-weighted images and hyperintense to that of muscle on T2-weighted images. It also demonstrates progressive accumulation of contrast material on

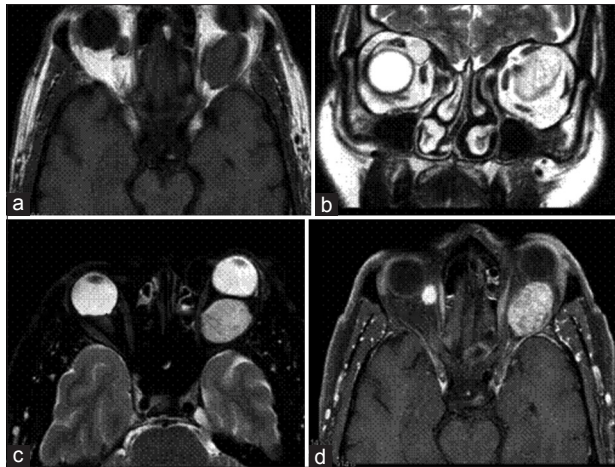


Figure 1: (a) T1-weighted magnetic resonance imaging shows a well-defined mass hypointense in the orbital cavity on both sides. (b and c) T2-weighted shows lesions isointense relative to muscle (d) T1-weighted image after gadolinium injection shows marked uniform enhancement of the masses

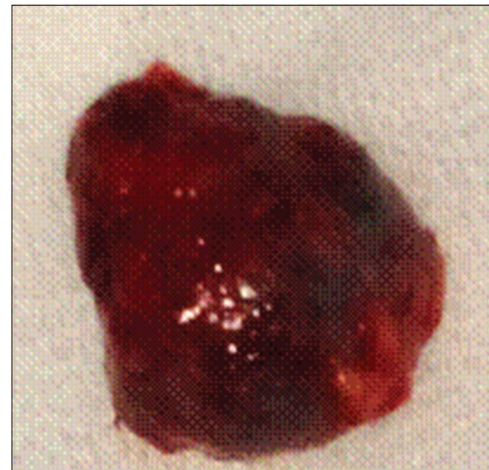

Figure 2: The specimen of the orbital tumor after resection

Table 1: Literature review of cases reporting bilateral orbital cavernous hemangioma

Authors	Year	Gender	Age	Association with other disease	Treatment	Postoperative course
Fries and Char ^[3]	1988	Male	48	No	Unilateral orbitotomy	Good
Ohbayashi <i>et al.</i> ^[5]	1988	Female	45	No	Right subfrontal extradural approach, left resection by Krönlein-Berke method	Good
Char <i>et al.</i> ^[11]	1989	Not mentioned	Not mentioned	Not mentioned	Not mentioned	Not mentioned
Johnson <i>et al.</i> ^[6]	1990	Male	34	Maffucci's syndrome	Not mentioned	Not mentioned
Sullivan <i>et al.</i> ^[7]	1992	Female	41	No	Left resection 7 years after right resection	Good
Shields <i>et al.</i> ^[8]	2000	Male	37	No	Left superolateral extraperiosteal approach	Good
Chang and Rubin ^[9]	2002	Female	36	Blue rubber bleb nevus syndrome	Surgical debulking of multiple lesions	Good
Paonessa <i>et al.</i> ^[2]	2008	3 cases (not mentioned)	Not mentioned	Not mentioned	Not mentioned	Not mentioned
Aletaha <i>et al.</i> ^[10]	2010	Female	42	No	Right orbitotomy left resection after 1 month	Good

late-phase dynamic and delayed images.^[12] Some differential diagnoses should not be forgotten in case of bilateral cavernous hemangiomas. Orbital vascular tumors (capillary hemangiomas, hemangiopericytomas, and hemangioendotheliomas) are irregular, less defined, and more commonly extraconal in comparison to orbital cavernous hemangiomas and have an important arterial supply which translates into rapid contrast enhancement in the early arterial/early venous phase using multiphase dynamic contrast CT and/or MRI.^[12] Orbital pseudotumor and lymphoma are hypovascular so that multiphase dynamic contrast CT and/or MRI again facilitates the differentiation of these lesions from orbital cavernous hemangiomas, which uniquely exhibit a persistent homogeneous enhancement pattern throughout the delayed equilibrium phases without washout.^[12] Wegener's granulomatosis could be easily recognized as causing osseous destruction seen on CT and/or MRI.^[13]

CHO is usually managed conservatively, and surgical excision is reserved for those that cause severe proptosis or optic nerve compression, like for the unilateral hemangioma.

Conclusion

Bilateral cavernous hemangiomas are rarely reported although it could be more frequent as it was thought. Usually, the clinical manifestation is due to one of the two lesions, so that the correct diagnosis is made when MRI and CT are performed. Surgical management is the same as for unilateral cavernous hemangioma and should be limited to the symptomatic lesion.

Acknowledgment

The patient is consent to be enrolled and have their data published. Furthermore, our institute approves this study and publication.

Financial support and sponsorship

Nil.

Conflicts of interest

There are no conflicts of interest.

References

1. Rootman J. Vascular malformations of the orbit: Hemodynamic concepts. *Orbit* 2003;22:103-20.
2. Paonessa A, Limbucci N, Gallucci M. Are bilateral cavernous hemangiomas of the orbit rare entities? The role of MRI in a retrospective study. *Eur J Radiol* 2008;66:282-6.
3. Fries PD, Char DH. Bilateral orbital cavernous haemangiomas. *Br J Ophthalmol* 1988;72:871-3.
4. Rootman DB, Heran MK, Rootman J, White VA, Luensamran P, Yucel YH. Cavernous venous malformations of the orbit (so-called cavernous haemangioma): A comprehensive evaluation of their clinical, imaging and histologic nature. *Br J Ophthalmol* 2014;98:880-8.
5. Ohbayashi M, Tomita K, Agawa S, Sichiyo F, Shinno K, Matsumoto K. Multiple cavernous hemangiomas of the orbits. *Surg Neurol* 1988;29:32-4.
6. Johnson TE, Nasr AM, Nalbandian RM, Cappelen-Smith J. Enchondromatosis and hemangioma (Maffucci's syndrome) with orbital involvement. *Am J Ophthalmol* 1990;110:153-9.
7. Sullivan TJ, Aylward GW, Wright JE, Moseley IF, Garner A. Bilateral multiple cavernous haemangiomas of the orbit. *Br J Ophthalmol* 1992;76:627-9.
8. Shields JA, Hogan RN, Shields CL, Eagle RC Jr., Kennedy RH, Singh AD. Bilateral cavernous haemangiomas of the orbit. *Br J Ophthalmol* 2000;84:928.
9. Chang EL, Rubin PA. Bilateral multifocal hemangiomas of the orbit in the blue rubber bleb nevus syndrome. *Ophthalmology* 2002;109:537-41.
10. Aletaha M, Erfanian-Salim R, Bagheri A, Salour H, Abrishami M. Bilateral orbital cavernous hemangiomas. *J Ophthalmic Vis Res* 2010;5:65-7.
11. Char DH, Fries PD, Fohrman DS, Norman D. Orbital cavernous hemangioma: Unusual presentations and simulating lesions. *Orbit* 1989;8:205-11.
12. Ansari SA, Mafee MF. Orbital cavernous hemangioma: Role of imaging. *Neuroimaging Clin N Am* 2005;15:137-58.
13. Muhle C, Reinhold-Keller E, Richter C, Duncker G, Beigel A, Brinkmann G, *et al.* MRI of the nasal cavity, the paranasal sinuses and orbits in Wegener's granulomatosis. *Eur Radiol* 1997;7:566-70.