

Covid-19 and leptospirosis, pulmonary involvement and response to steroids: A comparative observational study from a rural Tertiary care center in Kerala

Vinod Xavier, Binitha Baby, Joemon M. George, Abraham M. Ittyachen

Department of Medicine, M.O.S.C Medical College and Hospital, Kolenchery, Ernakulam District, Kerala, India

ABSTRACT

Background: COVID-19 is an emerging infectious disease with a global outreach. Leptospirosis is a zoonotic disease mainly confined to tropical areas. In both cases, most of those affected are asymptomatic or have only mild respiratory disease. Those who turn critical develop acute respiratory distress syndrome (ARDS) and/or multiple-organ failure occurs rapidly, with high fatality. **Methodology:** This is a retrospective observational study from 2020 involving COVID-19 and leptospirosis patients. The data were collected using a semi-structured proforma, and analysis was performed using Easy R (EZR) software. **Results:** There were five patients with COVID-19 and four patients with leptospirosis; with pulmonary involvement. All the patients were males. There was no significant difference in age, the onset of pulmonary involvement, time of initiation of steroids, duration of steroids, and outcome between the two groups. However, in the case of COVID-19, it took a longer period for clearing of infiltrates. **Conclusion:** Though COVID-19 and leptospirosis are two different diseases, both of them show a similar life-saving response to steroids, the common factor in the pathogenesis being cytokine storm. Primary care physicians in tropical areas of the world should be aware of the similarities between these two diseases, especially the initial clinical presentation, the pathogenesis, and the response to steroids.

Keywords: ARDS, Covid-19, leptospirosis, steroids

Introduction

COVID-19 is an emerging infectious disease caused by the coronavirus, severe acute respiratory syndrome coronavirus 2 (SARS CoV-2). Though described as early as 2019 from China,^[1] it continues to overwhelm mankind in its outreach. Major illness occurs in around 14%, and 5% develop life-threatening disease;^[2] fortunately, most of those affected (81%) are asymptomatic or have only mild respiratory disease. In those who develop life-threatening illness, a majority^[3] develop acute respiratory distress syndrome (ARDS) and/or multiple-organ failure occurs

swiftly, with a high mortality rate. ARDS is reported at around 15.6%–31%^[4] and in whom mortality may reach 50%.^[5,6]

Leptospirosis, a disease mainly confined to tropical regions of the world, is a zoonotic disease caused by contact with the urine of animals, especially rats; pathogenic *Leptospira* are shed in the urine of these animals.^[7] Humans are unintentional hosts and could face a potentially lethal outcome; rats on the other hand are immune to fatal infection and serve as natural reservoirs. The majority of human leptospiral infections are mild or asymptomatic^[7] like COVID-19. In those who develop the illness, the disease generally presents with an abrupt onset of fever, rigors, myalgias, and headache. The first phase consists of an acute febrile bacteremia phase lasting 2 to 9 days, after which there may be a period with little or no fever and apparent improvement. The second phase consists of an “immune”

Address for correspondence: Prof. Abraham M. Ittyachen, Department of Medicine, M.O.S.C Medical College and Hospital, Kolenchery - 682 311, Ernakulam District, Kerala, India. E-mail: abyiliz@rediffmail.com

Received: 15-07-2021

Revised: 05-12-2021

Accepted: 07-12-2021

Published: 31-01-2022

Access this article online

Quick Response Code:



Website:
www.jfmpc.com

DOI:
10.4103/jfmpc.jfmpc_1414_21

This is an open access journal, and articles are distributed under the terms of the Creative Commons Attribution-NonCommercial-ShareAlike 4.0 License, which allows others to remix, tweak, and build upon the work non-commercially, as long as appropriate credit is given and the new creations are licensed under the identical terms.

For reprints contact: WKHLRPMedknow_reprints@wolterskluwer.com

How to cite this article: Xavier V, Baby B, George JM, Ittyachen AM. Covid-19 and leptospirosis, pulmonary involvement and response to steroids: A comparative observational study from a rural tertiary care center in Kerala. *J Family Med Prim Care* 2022;11:294-8.

phase characterized by renewed fever and the development of complications.^[8] Around 5%–15% of patients develop Weil's disease.^[9–11] And, pulmonary involvement is a salient feature of Weil's disease (20%–70%),^[12] Pulmonary involvement may manifest as mild cough to severe hemoptysis and ARDS. ARDS carries a high mortality rate, around 50%.^[13]

As COVID-19 spreads into every nook and corner of the world, it will have further ramifications in tropical regions where it will compete as a confounder with other established tropical illnesses making clinical diagnosis more challenging. And, primary care providers and family physicians, especially those in the tropical setting will have another differential diagnosis in their list to consider when a patient presents with an acute febrile-like illness (AFI) or a seemingly mild respiratory tract infection.

This study describes the similarity between COVID-19 and leptospirosis in an area endemic for leptospirosis, especially pulmonary involvement and response to steroids.

Materials and Methods

This is a retrospective observational study from 2020 involving COVID-19 patients and leptospirosis patients; in whom, there was pulmonary involvement. The study was done in a tertiary care reference center situated in a rural area in the state of Kerala in southern India. The area is humid with abundant rainfall, especially between early June and late September when the monsoon sets in. Tropical diseases, especially leptospirosis and dengue are endemic to this area.^[14,15] The research was approved by the institutional ethics committee (IEC) of the hospital (No: MOSC/IEC/549/202) on 17/03/2021.

A semi-structured proforma meeting the objective of the study was prepared for the collection of data. Details including baseline demographic data, the onset of pulmonary infiltrate, time of initiation of steroids, and time to achieve recovery were documented among COVID-19 and leptospirosis patients.

The onset of pulmonary involvement was defined by the appearance of infiltrates on the Chest X-ray and resolution by clearing of the infiltrates. Only subjects 18 years and above were included in the study.

Diagnosis of leptospirosis

The diagnosis of leptospirosis was made on the basis of IgM positivity in a patient with a risk for the disease and presenting with the typical clinical manifestations.

Diagnosis of Covid-19

The diagnosis of COVID-19 was made on the basis of clinical suspicion together with confirmation by Reverse Transcription-Polymerase Chain Reaction (RT-PCR) test, Antigen test, or TrueNat test.

Treatment strategies

Patients with leptospirosis were treated primarily with ceftriaxone; and other symptomatic measures. Acute lung injury (ALI)/acute respiratory distress syndrome (ARDS) was treated with injection methylprednisolone, and the respiratory distress was supported with noninvasive ventilation (NIV). The basis of this strategy was a study done in the same institution.^[15] COVID-19 was treated as per the guidelines of the government of Kerala. According to set protocol, patients received injection Remdesivir and injection Dexamethasone. Respiratory support was given with high-flow nasal oxygen (HFNO) or NIV.

Data analysis

The data were entered into an Excel spreadsheet, and analysis was performed using EZR software. Mann–Whitney U test was performed to check if there was any significant difference between the two groups. A *P* value of <0.05 was considered significant.

Results

There were five patients with COVID-19 and four patients with leptospirosis during this period with pulmonary involvement. All the patients were males. All patients with leptospirosis had liver involvement (defined as a mild elevation of liver enzymes), whereas only one patient with COVID-19 had liver involvement. The same was true for renal involvement also, all patients with leptospirosis had acute kidney injury (AKI), whereas only one patient with COVID-19, had renal involvement. None of the patients required renal replacement therapy (dialysis). The median age was found to be 65 among COVID-19 patients and 44 among leptospirosis patients. There was no significant difference in age, the onset of pulmonary involvement, time of initiation of steroids, duration of steroids, and outcome between the two groups [Table 1]. However, in the case of COVID-19 it took a longer period for the clearing of infiltrates.

All the patients survived to discharge and were followed up in the outpatient 1 week after discharge with no significant residual abnormalities in the case of leptospirosis patients. But in the case of COVID-19, infiltrates persisted though to a lesser degree compared to their discharge X-rays. And this could be corroborated clinically; saturations were maintained on ambient air with only mild breathlessness on exertion. For further follow-up, the patients were directed to the nearest primary physician.

Chest radiographs

X-rays of one patient from each group (representative of that group) are described.

Leptospirosis

Chest X-ray taken on the first day was normal [Figure 1a]. On the third day, there was a florid increase in infiltrates in all lung fields [Figure 1b] (the patient was immediately started on

Table 1: Comparison of different variables between Covid-19 and Leptospirosis

Variables	Median and IQR (Q1, Q3)		Mann Whitney U statistic	P
	COVID-19 Infection (n=5)	Leptospirosis with MODS (n=4)		
Age	65 (48,73)	44 (39, 53)	3	0.086
Onset of pulmonary involvement	6 (4, 12)	6 (4, 8)	8	0.617
Time of initiation of steroids	6 (4, 12)	5 (4, 6)	7.5	0.530
Duration of steroid course	13 (12, 22)	11 (8, 13)	5	0.217
Final outcome	11 (10, 16)	10.5 (8, 13)	9	0.804

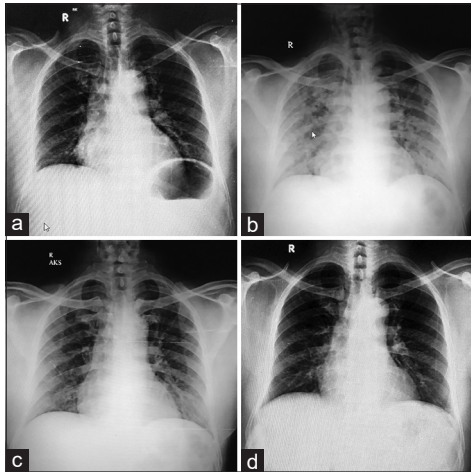


Figure 1: (a) Chest X-ray of Leptospirosis patient - day 1. (b) Chest X-ray of Leptospirosis patient - day 3. (c) Chest X-ray of Leptospirosis patient - day 5. (d) Chest X-ray of Leptospirosis patient - day 8

methylprednisolone). There was a partial clearing of infiltrates on the fifth day [Figure 1c]. By day eight, the X-ray was normal [Figure 1d].

Covid-19

Chest X-ray taken on the day of admission itself showed few infiltrates developing bilaterally [Figure 2a] (dexamethasone was started on the same day). Within 24 h the infiltrates had become widespread [Figure 2b]. On day six, a partial clearing was noted [Figure 2c]. By day 10, there was a substantial clearing of infiltrates though it had not fully resolved [Figure 2d], and the patient continued to require minimal amounts of oxygen (2 L/min) delivered by nasal prongs to maintain adequate oxygen saturation and a normal breathing rate. The patient was discharged in the third week on domiciliary oxygen therapy.

Discussion

Leptospirosis is a zoonotic disease caused by a bacterium, whereas COVID-19 is an air-borne viral disease. But surprisingly they produce illnesses with similar features, and cytokine storm is the common triggering factor.^[16]

Cytokine storm has been described in various tropical illnesses (leptospirosis, kala-azar, plague).^[17-19] It has also been described in two viral infections described from the tropical regions of the world (dengue and ebola).^[20,21] In fact, there is also a historical connection; a reconstructed H1N1 virus isolated

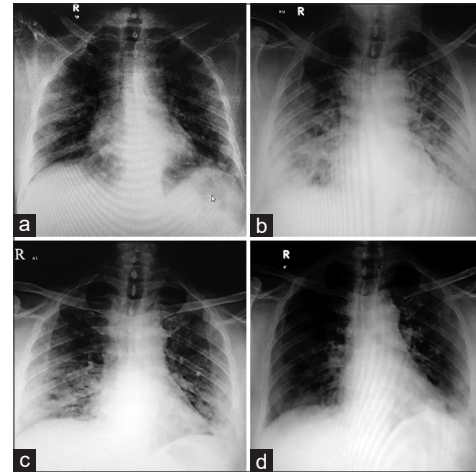


Figure 2: (a) Chest X-ray of Covid-19 patient - day 1. (b) Chest X-ray of Covid-19 patient - day 2. (c) Chest X-ray of Covid-19 patient - day 6. (d) Chest X-ray of Covid-19 patient - day 10

from the 1918 pandemic, as compared with common reference strains of the virus that causes influenza A, has been found to trigger marked pulmonary inflammation in mice.^[22]

The role of the cytokine storm in the pathogenesis of leptospirosis has been well established.^[23] During infection, there is an inflammatory response, especially through the production of cytokines which is essential for the early elimination of pathogens. However, uncontrolled cytokine production can result in a cytokine storm, which can lead to multi-organ dysfunction and death. In such cases, pulmonary involvement can be prominent^[12] with ARDS and a high mortality rate.^[13] The initiation of antibiotics can also trigger a cytokine storm in leptospirosis and clinically manifests as an acute febrile inflammatory reaction known as the Jarisch–Herxheimer (JH) reaction;^[24] JH reaction was first described in the treatment of syphilis with mercury.^[25,26] A similar pathophysiology has been described in COVID-19 also.^[27] Several studies analyzing cytokine profiles from COVID-19 patients suggested that the cytokine storm correlated directly with lung injury, multiorgan failure, and unfavorable prognosis of severe COVID-19.^[28,29] Pulmonary involvement in the form of acute lung injury (ALI)/acute respiratory distress syndrome (ARDS) was found in all the patients in this case series.

With the publication of the RECOVERY trial, steroids became one of the first immunomodulatory agents to be used in COVID-19;^[30] though gaps remain in its final verdict.^[31] There are

other studies too, involving steroids and other immunomodulatory agents.^[32] None of these interventions are universally helpful in all patients in all circumstances, but steroids still remain the best option in COVID-19. Predating COVID-19, in leptospirosis, an observed survival gain was seen when steroids were used to dampen the deleterious consequences of the cytokine storm.^[15] However, no effort has been made to conduct a fool-proof trial to produce sound evidence.^[33] Nevertheless, from information gathered over the years, high dose steroids in early ARDS in leptospirosis are now recommended by several nations in their guidelines.^[34,35] In this comparative series, there was a definite response to steroids in the form of clearing of pulmonary infiltrates though in the case of Covid-19 the response was delayed; and there was no significant difference in the duration of steroid use.

A drawback of this study has been the small sample size which in epidemiological terms translates into weak evidence. In the case of leptospirosis, historical end-to-end comparison is also not possible because of the poor quality of data or the total absence of data in the literature regarding the onset of pulmonary involvement, duration of steroid usage, and the time it takes for clearing of pulmonary infiltrates. COVID-19 translates better when the aforementioned particulars are considered; in those with lung involvement, radiographic features progress with the disease and peak 10–12 days from symptom onset.^[36] Resolution is however prolonged unlike leptospirosis; even 1 and a 1/2 months after discharge close to fifty percent of patients have an abnormal chest radiograph.^[37] And in the long term, the prevalence of radiological abnormalities following COVID-19 remains unknown.^[37] Regarding the duration of steroids, most studies recommend short-term usage of not more than 10 days.^[30,38]

Primary care providers and family physicians working in the tropical setting will have to consider COVID-19 too when they encounter a case with AFI. A high index of clinical suspicion will be required due to the clinical similarities, especially in the initial stages. In the case of leptospirosis, effective antibiotics are available and have to be used early in the illness itself to offset the onset of complications. Likewise, in the appropriate clinical setting, early use of monoclonal antibodies will be life-saving in the case of COVID-19.^[39] The challenge before the primary physician will be to distinguish between the two, early in the illness itself.

Conclusion

COVID-19 is not going to go any too soon. And, physicians practicing in tropical regions have yet another disease to decipher in the setting of AFI. Leptospirosis is a disease that causes AFI and in the initial stages of illness, the clinical picture may mimic COVID-19; and vice versa too. Though these are two different diseases, one of which has a virus and the other a bacterium as its cause, both of them show a similar life-saving response to steroids, the common factor in the pathogenesis

being the cytokine storm. Primary care physicians in tropical areas of the world should be aware of the similarities between these two diseases, especially the initial clinical presentation, the pathogenesis, and the response to steroids. And, it need not be emphasized more how important it is to distinguish between these two illnesses in the initial phase of the illness itself.

Acknowledgements

The authors wish to thank Dr. Kalesh M Karun for conducting the data analysis.

Financial support and sponsorship

Nil.

Conflicts of interest

There are no conflicts of interest.

References

- Zhu N, Zhang D, Wang W, Li X, Yang B, Song J, *et al.* A novel coronavirus from patients with pneumonia in China, 2019. *N Engl J Med* 2020;382:727-33.
- Wu Z, McGoogan JM. Characteristics of and important lessons from the corona virus disease 2019 (COVID-19) outbreak in China: Summary of a report of 72314 cases from the Chinese center for disease control and prevention. *JAMA* 2020;323:1239-42.
- Zhou F, Yu T, Du R, Fan G, Liu Y, Liu Z, *et al.* Clinical course and risk factors for mortality of adult inpatients with COVID-19 in Wuhan, China: A retrospective cohort study. *Lancet* 2020;395:1054-62.
- Li X, Ma X. Acute respiratory failure in COVID-19: Is it “typical” ARDS? *Crit Care* 2020;24:198.
- Wu C, Chen X, Cai Y, Xia J, Zhou X, Xu S, *et al.* Risk factors associated with acute respiratory distress syndrome and death in patients with coronavirus disease 2019 pneumonia in Wuhan, China. *JAMA Intern Med* 2020;180:934-43.
- Qin C, Zhou L, Hu Z, Zhang S, Yang S, Tao Y, *et al.* Dysregulation of immune response in patients with COVID-19 in Wuhan, China. *Clin Infect Dis* 2020;71:762-8.
- Haake DA, Levett PN. Leptospirosis in humans. *Curr Top Microbiol Immunol* 2015;387:65-97.
- Sanford JP. Leptospirosis--time for a booster. *N Engl J Med* 1984;310:524-5.
- Doudier B, Garcia S, Quennee V, Jarno P, Brouqui P. Prognostic factors associated with severe leptospirosis. *Clin Microbiol Infect* 2006;12:299-300.
- Spichler AS, Vilaça PJ, Athanzio DA, Albuquerque JO, Buzzar M, Castro B, *et al.* Predictors of lethality in severe leptospirosis in urban Brazil. *Am J Trop Med Hyg* 2008;79:911-4.
- Hinjoy S, Kongyu S, Doung-Ngern P, Doungchawee G, Colombe SD, Tsukayama R, *et al.* Environmental and behavioral risk factors for severe leptospirosis in Thailand. *Trop Med Infect Dis* 2019;4:79.
- O'Neil KM, Rickman LS, Lazarus AA. Pulmonary manifestations of leptospirosis. *Rev Infect Dis* 1991;13:705-9.
- Vieira SR, Brauner JS. Leptospirosis as a cause of acute respiratory failure: Clinical features and outcome in 35

- critical care patients. *Braz J Infect Dis* 2002;6:135-9.
14. Ittyachen AM, Ramachandran R. Study of acute febrile illness: A 10-year descriptive study and a proposed algorithm from a tertiary care referral hospital in rural Kerala in Southern India. *Trop Doct* 2015;45:114-7.
 15. Ittyachen AM, Lakshmanakumar VK, Eapen CK, Joseph MR. Methylprednisolone as adjuvant in treatment of acute respiratory distress syndrome owing to leptospirosis: A pilot study. *Indian J Crit Care Med* 2005;9:133-6.
 16. Ittyachen AM. Covid-19 and leptospirosis: Cytokine storm and the use of steroids. *Trop Doct* 2021;51:128-30.
 17. Senavirathna I, Rathish D, Agampodi S. Cytokine response in human leptospirosis with different clinical outcomes: A systematic review. *BMC Infect Dis* 2020;20:268.
 18. Costa DL, Rocha RL, Carvalho RM, Lima-Neto AS, Harhay MO, Costa CH, *et al.* Serum cytokines associated with severity and complications of kala-azar. *Pathog Glob Health* 2013;107:78-87.
 19. Pechous RD, Sivaraman V, Price PA, Stasulli NM, Goldman WE. Early host cell targets of *Yersinia pestis* during primary pneumonic plague. *PLoS Pathog* 2013;9:e1003679.
 20. Srikiatkhachorn A, Mathew A, Rothman AL. Immune-mediated cytokine storm and its role in severe dengue. *Semin Immunopathol* 2017;39:563-74.
 21. Falasca L, Agrati C, Petrosillo N, Di Caro A, Capobianchi MR, Ippolito G, *et al.* Molecular mechanisms of Ebola virus pathogenesis: Focus on cell death. *Cell Death Differ* 2015;22:1250-9.
 22. Kash JC, Tumphey TM, Proll SC, Carter V, Perwitasari O, Thomas MJ, *et al.* Genomic analysis of increased host immune and cell death responses induced by 1918 influenza virus. *Nature* 2006;443:578-81.
 23. Cagliero J, Villanueva SY, Matsui M. Leptospirosis pathophysiology: Into the storm of cytokines. *Front Cell Infect Microbiol* 2018;8:204.
 24. Pound MW, May DB. Proposed mechanisms and preventative options of Jarisch-Herxheimer reactions. *J Clin Pharm Ther* 2005;30:291-5.
 25. Jarisch A. Therapeutische versuche bei syphilis. *Wien Med Wochenschr* 1895;45:721-4.
 26. Herxheimer K, Krause D. Ueber eine bei syphilitischen vorkommende quecksilberreaktion. *Dtsch Med Wochenschr* 1902;28:895-7.
 27. Ragab D, Salah Eldin H, Taeimah M, Khattab R, Salem R. The COVID-19 cytokine storm; What we know so far. *Front Immunol* 2020;11:1446.
 28. Chen G, Wu D, Guo W, Cao Y, Huang D, Wang H, *et al.* Clinical and immunological features of severe and moderate coronavirus disease 2019. *J Clin Invest* 2020;130:2620-9.
 29. Ruan Q, Yang K, Wang W, Jiang L, Song J. Clinical predictors of mortality due to COVID-19 based on an analysis of data of 150 patients from Wuhan, China. *Intensive Care Med* 2020;46:846-8.
 30. RECOVERY Collaborative Group; Horby P, Lim WS, Emberson JR, Mafham M, Bell JL, *et al.* Dexamethasone in hospitalized patients with Covid-19. *N Engl J Med* 2021;384:693-704.
 31. Johnson RM, Vinetz JM. Dexamethasone in the management of covid-19. *BMJ* 2020;370:m2648.
 32. Rello J, Waterer GW, Bourdieu A, Roquilly A. COVID-19, steroids and other immunomodulators: The jigsaw is not complete. *Anaesth Crit Care Pain Med* 2020;39:699-701.
 33. Rodrigo C, Lakshitha de Silva N, Goonaratne R, Samarasekara K, Wijesinghe I, Parththipan B, *et al.* High dose corticosteroids in severe leptospirosis: A systematic review. *Trans R Soc Trop Med Hyg* 2014;108:743-50.
 34. Leptospirosis CPG 2010. Available from: <http://philchest.org/v3/wp-content/uploads/2013/05/Leptospirosis-CPG-2010.pdf>. [Last accessed on 2021 May 1].
 35. National Guidelines on Management of Leptospirosis 2016. Available from: www.epid.gov.lk/web/images/pdf/Publication/leptospirosis/lepto_national_guidelines.pdf. [Last accessed on 2021 May 1].
 36. Wong HY, Lam HY, Fong AH, Leung ST, Chin TW, Lo CS, *et al.* Frequency and distribution of chest radiographic findings in patients positive for COVID-19. *Radiology* 2020;296:E72-8.
 37. Mallia P, Meghji J, Wong B, Kumar K, Pilkington V, Chhabra S, *et al.* Symptomatic, biochemical and radiographic recovery in patients with COVID-19. *BMJ Open Res* 2021;8:e000908.
 38. Tomazini BM, Maia IS, Cavalcanti AB, Berwanger O, Rosa RG, Veiga VC, *et al.* COALITION COVID-19 Brazil III Investigators. Effect of dexamethasone on days alive and ventilator-free in patients with moderate or severe acute respiratory distress syndrome and COVID-19: The CoDEX randomized clinical trial. *JAMA* 2020;324:1307-16.
 39. Deeks ED. Casirivimab/Imdevimab: First approval. *Drugs* 2021;81:2047-55.