

Cryptococcus gattii infection in an immunocompetent host in Greece

Marina Andreou^a, Massimo Cogliati^b, Fevronia Kolonitsiou^c, Charalampos Stroumpou^d, Vasiliki Stamouli^c, Panagiota Ravazoula^e, Dimitrios Siagris^a, Helen Papadogeorgaki^f, Myrto Christofidou^c, Alexandra Lekkou^{g,*}

^a Department of Internal Medicine, University Hospital of Patras, Patras, Greece

^b Department of Biomedical Sciences for Health, Università degli Studi di Milano, Milano, Italy

^c Department of Microbiology, University Hospital of Patras, Patras, Greece

^d Department of Cardiothoracic Surgery, University Hospital of Patras, Patras, Greece

^e Department of Pathology, University Hospital of Patras, Patras, Greece

^f Microbiology Laboratory, Hygeia General Hospital, Athens, Greece

^g Division of Infectious Diseases, Department of Internal Medicine, University Hospital of Patras, Patras, Greece

ARTICLE INFO

Keywords:

Cryptococcus gattii
Cryptococcal meningitis
Pulmonary cryptococcoma
Cryptococcosis
Greece

ABSTRACT

We report a case of a 31-year-old otherwise healthy female with pulmonary cryptococcoma along with cryptococcal meningitis due to *Cryptococcus gattii* molecular type VGI, in Greece. Combined antifungal treatment and surgical excision of pulmonary cryptococcoma yielded a good response.

1. Introduction

Cryptococcosis is a life-threatening fungal disease affecting both immunosuppressed and immunocompetent hosts. Etiological agents known to cause infection in humans are the two species complexes *Cryptococcus neoformans* and *Cryptococcus gattii*. Although in the past they were classified as two varieties of *C. neoformans* species, further studies confirmed that *C. neoformans* and *C. gattii* actually differ in geographical distribution, genetic characteristics, and virulence. *C. gattii* species complex contains five molecular types AFLP4/VGI, AFLP6/VGII, AFLP10/VGIV, AFLP5/VGIII and AFLP7/VGIV [1,2].

Primary infection is thought to be caused by the inhalation of basidiospores or small-sized blastospores. After lung penetration, cryptococcal yeasts can enter the bloodstream and cross blood-brain-barrier causing central nervous system infection. Interestingly *Cryptococcus gattii* is more likely to cause lung or brain cryptococcomas, while *Cryptococcus neoformans* causes more disseminated disease [3]. *Cryptococcus neoformans* species complex has a worldwide distribution affecting predominantly immunocompromised hosts. Host risk factors for infection include underlying HIV infection, solid organ transplantation, idiopathic CD4⁺ lymphopenia, corticosteroid or immunosuppressive drugs use and other immunosuppressive states such as diabetes, autoimmune diseases [3,4]. In contrast, *C. gattii* has been found mainly in

tropical and subtropical areas and molecular types VGI and VGII have been shown to be able to infect otherwise healthy immunocompetent individuals. Recent data show a change in ecological distribution of *C. gattii* species complex to temperate non-endemic areas worldwide, including Europe and Mediterranean basin [5–8]. In Greece, previous reports with clinical cases of *C. gattii* infection were reported only in immunocompromised patients [9,10]. Here we present a case of *C. gattii* VGI infection in an immunocompetent host in our country.

2. Case

A 31-year-old woman from a rural area of southwestern Peloponnese in Greece was transferred to our hospital, a tertiary care hospital facility, with a two-week history of mild headache and low-grade fever. Three days prior admission she experienced vomiting, fever up to 38.5 °C, and mental confusion. She had no prior medical history and had never been abroad.

On examination (day 0) she was afebrile, hemodynamically stable, mildly confused with Glasgow coma scale: 13/15 and no focal neurologic deficits. Brain computed tomography (CT) and magnetic resonance imaging (MRI) depicted multiple small nodular lesions at peripheral sites of cerebellar hemispheres, small focal lesions in the posterior limb of internal capsule and in the left hypothalamic nucleus.

* Corresponding author. Division of Infectious Diseases, Department of Internal Medicine, Patras University Hospital, 26504, Patras, Greece.
E-mail address: alekkou@yahoo.gr (A. Lekkou).

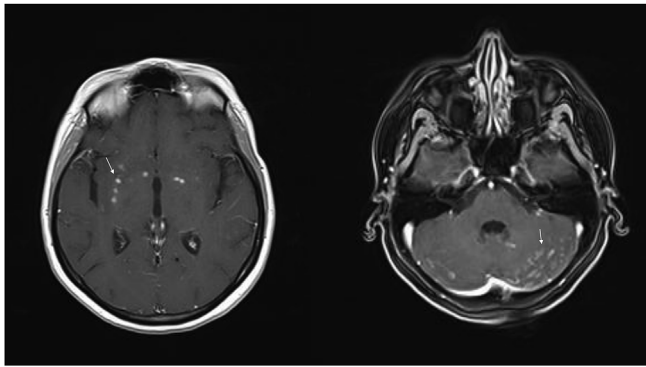


Fig. 1. Magnetic resonance imaging: Multiple cryptococcoma lesions in the cerebellar hemispheres, the internal capsule and the left hypothalamic nucleus (arrows). After the administration of paramagnetic drug, meningeal enhancement was detected.

After the administration of paramagnetic drug, meningeal enhancement was detected (Fig. 1).

Initial cerebrospinal fluid (CSF) analysis showed lymphocytic pleocytosis (white cell count: 670 cells/mm³, 96% lymphocytes, 3% neutrophils), protein of 82.6 mg/dl and glucose of 36 mg/dl (blood glucose 90 mg/dl). CSF opening pressure was 36 cm H₂O. Latex agglutination test for *Cryptococcus* was positive while CSF cryptococcal antigen (CrAg) titer was 1:20. After 48 h incubation at 37 °C, *Cryptococcus* grew in the CSF culture. *Cryptococcus gattii* was identified by matrix-assisted laser desorption/ionization time of flight mass spectrometry (MALDI-TOF Vitek MS Biomerieux, database IVD). Antifungal susceptibility test was performed by E-test. The MICs of the antifungals were: 0.25 µg/ml for amphotericin B, 0.016 µg/ml for flucytosine, 4 µg/ml for fluconazole and 0.125 µg/ml for voriconazole. The fungal isolate was sent to the Medical Mycology Laboratory at Università degli Studi di Milano for further molecular characterization, where it was identified as molecular type VGI, mating type αB by multiplex PCR [11] and sequence type ST197 by standard multi-locus sequence type (MLST) analysis [12]. Chest x-ray (day 0) and CT (day +4) revealed a well-defined, non-enhancing, of low-density mass lesion in the left lower lobe.

The patient received combined regimen with liposomal amphotericin B (LAmB) 4 mg/kg/d and flucytosine 100 mg/kg/d in four divided doses IV. Two days after starting treatment she complained of sudden onset of acute retrosternal chest pain and ECG showed T wave depression in V1 – V3 and flattened T waves in V4 – V6, but no cardiac enzymes elevation was observed, as flucytosine adverse reaction. Treatment was changed to LAmB and fluconazole 800 mg/d IV and she improved steadily through first 3 weeks. The patient underwent bronchoscopy (day +14) and bronchoalveolar lavage did not evidence acid-fast bacilli, fungi or bacteria.

On week 4, patient's symptoms relapsed as well as MRI findings, showing increased enhancement of the lesions in cerebellar hemispheres and basal ganglia bilaterally. *C. gattii* was isolated from CSF. We continued treatment with daily fluconazole 800 mg, increased dose of LAmB (5 mg/kg/d IV) and repeated lumbar punctures demonstrated persistent high opening pressure (42 cm H₂O) which improved with large volume drainage.

A complete microbiological and immunological evaluation was performed, detecting no any underlying immunosuppression state. Initial low CD4⁺ levels (332 cells/µl) were restored (1185 cells/µl) after 6 weeks of treatment. HIV serology tests and HTLV-I/II antibody were negative.

On week 9, CSF analysis confirmed sterility and CrAg titre 1:10, concurrently with improvement of clinical presentation. Follow-up chest CT revealed unchanged lung lesion and the patient was submitted to an exploratory thoracotomy, which depicted a solid mass adhered to

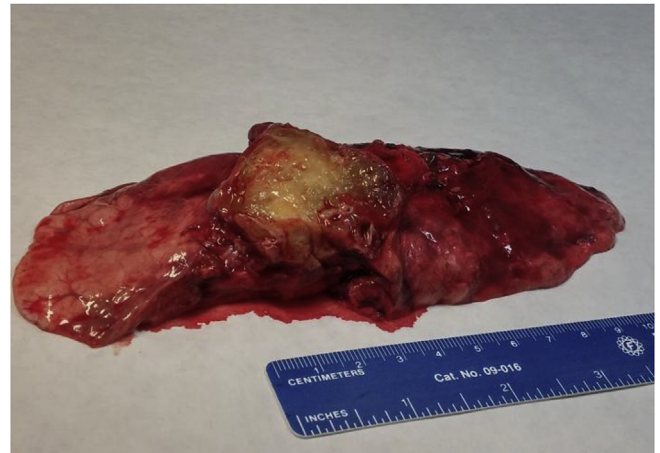

Fig. 2. Pulmonary cryptococcoma: A well circumscribed mass of the left inferior lung lobe.

the parietal pleura involving the left inferior lobe. An inferior lobectomy was undertaken and the post-operative outcome was good (Fig. 2). Histology demonstrated foamy histiocyte infiltration, necrotic areas surrounded by granulomas with epithelioid histiocytes and giant cells besides the presence of numerous birefringent structures and no evidence of malignancy. Grocott methenamine silver and Mayer's mucicarmine stainings were positive and diagnosed the structure as *Cryptococcus* spp. (Fig. 3).

The patient was transitioned to oral fluconazole 800 mg daily but, on week 12, she came back with left VI nerve palsy. Brain MRI findings showed disease exacerbation and lumbar puncture revealed a CSF opening pressure 38 cm H₂O, pleocytosis (107 cells/µl, lymphocytes 68%), normal glucose and protein concentrations and CSF CrAg titre 1:10. Treatment with LAmB 4 mg/kg/d and voriconazole (6 mg/kg/bid initially and then 4 mg/kg/bid) was initiated with frequent CSF drainages. CSF culture was negative but, on week 13, further deterioration occurred with enhancement of existing hyper-intensities on repeat MRI imaging. She was commenced on high-dose steroids for immune reconstitution inflammatory syndrome (IRIS) 0.5 mg/kg twice daily for two days followed by 0.5 mg/kg/d oral prednisolone for four weeks, which was weaned over further five months. After clinical improvement, she was discharged on salvage consolidation and suppressive therapy with voriconazole 200 mg/bid per os and 18 months later she is in a good clinical condition without neurological deficits.

3. Discussion

C. gattii was known to be endemic in subtropical and tropical regions but since 1999, when Vancouver Island outbreak occurred, increasing numbers of cases have been reported in the Pacific Northwest of the United States and in other temperate regions worldwide [5,13,14]. A European survey carried out during 1997–1999 reported *C. gattii* serotype B isolates from Germany, France and Greece, and one *C. gattii* serotype C in an HIV patient in the UK [15]. Subsequently, a review on the global distribution of molecular types reported cases in Portugal, Spain, Italy and the Netherlands all of VGI molecular type, as well as few VGII isolates in Greece, Switzerland, the Netherlands and Denmark and one VGIII isolate in Greece. The three cases from Greece were all in immunocompromised patients, two HIV/AIDS patients and one patient with systematic lupus erythematosus receiving immunosuppressive therapy [9,10].

C. gattii species complex isolates were also recovered in autochthonous Mediterranean trees. Recently, investigators concluded that the probability of presence for *C. gattii* drastically dropped when exposed to environments with a minimum temperature in winter of few degrees below 0 °C whereas the presence of the pathogen was higher in

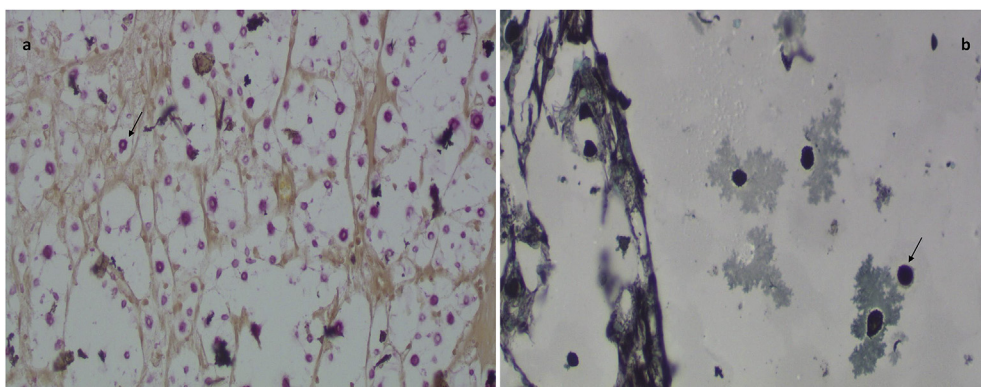


Fig. 3. a Mayer's mucicarmine stain of lung tissue: encapsulated yeasts of *Cryptococcus* spp. presenting carminophilic capsule are intensely stained with magenta color by mucicarmine. b Grocott's methenamine silver stain: fungal cells stained in black.. (For interpretation of the references to color in this figure legend, the reader is referred to the Web version of this article.)

the areas where rainfall was scarce during summer. On the basis of these findings Mediterranean climate is potentially optimal for *C. gattii* colonization [7].

We report a case in an immunocompetent female in Greece with combined lung cryptococcoma and central nervous system disease due to *C. gattii*. She was infected by a *Cryptococcus gattii* strain, molecular type VGI, mating type α B, and belonging to genotype ST197, which is one of the autochthonous VGI genotypes forming a larger cluster present in the Mediterranean area [5,10]. Since the patient had never travelled abroad, the infection was acquired in Greece. Initial low CD4⁺ levels were a manifestation of relative immunosuppression possibly induced by the cryptococcal capsule and restored after treatment [16].

Recommendations for the treatment of *C. gattii* central nervous system infection are the same as for *C. neoformans*. Amphotericin B plus flucytosine are proposed as first-line treatment but in our case, because of flucytosine adverse reaction, treatment switched to liposomal amphotericin and fluconazole regimen. After relapse and taking into account the new therapeutic options of the disease, salvage consolidation therapy with voriconazole was initiated [16].

Currently, surgery is not routinely recommended for lung cryptococcomas, except in case of mass-lesion effects or failure of treatment after four weeks [17]. A few studies show favorable outcome in cases with combined pulmonary and CNS cryptococcosis, after surgical resection of lung cryptococcomas [18,19].

In our case, we assumed that the presence of pulmonary cryptococcoma was associated with recurrent relapses and treatment failure. Surgical removal of lung lesion appeared to favor treatment response. After an initial clinically favorable response, the delayed worsening of our patient was due to IRIS, as occurred in 11% of patients in a large case series from Australia [3]. Systemic corticosteroid use is a potentially life-saving intervention to be considered for the management of IRIS in cryptococcal meningitis, however, precision of dosing and duration of therapy are uncertainties that require further study [16].

Global climatic changes expect to play a major role in the distribution of *C. gattii* species complex worldwide. As cryptococcosis is a life-threatening disease and *C. gattii* is a pathogen with increasing incidence in Europe and Mediterranean area, more research need to be done for early detection of outbreaks.

Declaration of competing interest

There are none.

Acknowledgements

None.

References

- [1] K.J. Kwon-Chung, J.E. Bennett, B.L. Wickes, W. Meyer, C.A. Cuomo, K.R. Wollenburg, et al., The case for adopting the "species complex" nomenclature for the etiologic agents of cryptococcosis, *mSphere* 2 (1) (2017), <https://doi.org/10.1128/msphere.00357-16>.
- [2] F. Hagen, K. Khayhan, B. Theelen, A. Kolecka, I. Polacheck, E. Sionov, et al., Recognition of seven species in the *Cryptococcus gattii*/*Cryptococcus neoformans* species complex, *Fungal Genet. Biol.* 78 (2015) 16–48, <https://doi.org/10.1016/j.fgb.2015.02.009>.
- [3] S.C.-A. Chen, M.A. Slavin, C.H. Heath, E. Geoffrey Playford, K. Byth, D. Marriott, et al., Clinical manifestations of *Cryptococcus gattii* infection: determinants of neurological sequelae and death, *Clin. Infect. Dis.* 55 (6) (2012) 789–798, <https://doi.org/10.1093/cid/cis529>.
- [4] L. MacDougall, M. Fyfe, M. Romney, M. Starr, E. Galanis, Risk factors for *Cryptococcus gattii* infection, British Columbia, Canada, *Emerg. Infect. Dis.* 17 (2) (2011) 193–199, <https://doi.org/10.3201/eid1702.101020>.
- [5] F. Hagen, M.F. Colom, D. Swinne, K. Tintelnor, R. Iatta, M.T. Montagna, et al., Autochthonous and dormant *Cryptococcus gattii* infections in Europe, *Emerg. Infect. Dis.* 18 (10) (2012) 1618–1624, <https://doi.org/10.3201/eid1810.120068>.
- [6] A. Chowdhary, H.S. Randhawa, T. Boekhout, F. Hagen, C. H. Klaassen, J.F. Meis, Temperate climate niche for *Cryptococcus gattii* in northern Europe, *Emerg. Infect. Dis.* 18 (1) (2012) 172–174, <https://doi.org/10.3201/eid1801.111190>.
- [7] M. Cogliati, E. Puccianti, M.T. Montagna, A. De Donno, S. Susever, C. Ergin, et al., Fundamental niche prediction of the pathogenic yeasts *Cryptococcus neoformans* and *Cryptococcus gattii* in Europe, *Environ. Microbiol.* 19 (10) (2017) 4318–4325, <https://doi.org/10.1111/1462-2920.13915>.
- [8] E.S. Acheson, E. Galanis, K. Bartlett, S. Mak, B. Klinkenberg, Searching for clues for eighteen years: deciphering the ecological determinants of *Cryptococcus gattii* on Vancouver Island, British Columbia, *Med. Mycol.* 56 (2) (2018 Feb 1) 129–144, <https://doi.org/10.1093/mmy/myx037>.
- [9] A. Velegriaki, V.G. Kioussis, H. Pitsouni, D. Toukas, V.D. Daniilidis, N.J. Legakis, First report of *Cryptococcus neoformans* var. *gattii* serotype B from Greece, *Med. Mycol.* 39 (5) (2001) 419–422 <http://www.ncbi.nlm.nih.gov/pubmed/12054052>.
- [10] M. Cogliati, M. Desnos-Ollivier, I. McCormick-Smith, V. Rickerts, K. Ferreira-Paim, W. Meyer, et al., Genotypes and population genetics of *Cryptococcus neoformans* and *Cryptococcus gattii* species complexes in Europe and the Mediterranean area, *Fungal Genet. Biol.* 129 (2019 Apr 3) 16–29, <https://doi.org/10.1016/j.fgb.2019.04.001>.
- [11] M. Cogliati, R. D'Amicis, A.M. Tortorano, *Cryptococcus gattii* sero-mating type allelic pattern determined by multiplex PCR, *Clin. Microbiol. Infect.* 21 (2015) 190.e1–190.e4 <https://doi.org/10.1016/j.cmi.2014.09.003>.
- [12] W. Meyer, D.M. Aanensen, T. Boekhout, M. Cogliati, M.R. Diaz, M.C. Esposto, et al., Consensus multi-locus sequence typing scheme for *Cryptococcus neoformans* and *Cryptococcus gattii*, *Med. Mycol.* 47 (6) (2009) 561–570 <https://doi.org/10.1080/13693780902953886>.
- [13] J.R. Harris, S.R. Lockhart, G. Sondermeyer, D.J. Vugia, M.B. Crist, M.T. D'Angelo, et al., *Cryptococcus gattii* infections in multiple states outside the US Pacific Northwest, *Emerg. Infect. Dis.* 19 (10) (2013) 1620–1626, <https://doi.org/10.3201/eid1910.130441>.
- [14] D.M. Engelthaler, N.D. Hicks, J.D. Gillece, C.C. Roe, J.M. Schupp, E. M. Driebe, et al., *Cryptococcus gattii* in north American Pacific Northwest: whole-population genome analysis provides insights into species evolution and dispersal, *mBio* 5 (4) (2014), <https://doi.org/10.1128/mbio.01464-14> e01464-14.
- [15] M.A. Viviani, M. Cogliati, M. C. Esposto, K. Tintelnor, M.F. C. Valiente, et al., Molecular analysis of 311 *Cryptococcus neoformans* isolates from a 30-month ECMM survey of cryptococcosis in Europe, *FEMS Yeast Res.* 6 (4) (2006) 614–619, <https://doi.org/10.1111/j.1567-1364.2006.00081.x>.
- [16] A. Mourad, J.R. Perfect, Present and future therapy of *Cryptococcus* infections, *J Fungi* (4) (2018) 79 <https://doi.org/10.3390/jof4030079>.
- [17] J.R. Perfect, W.E. Dismukes, F. Dromer, D.L. Goldman, J.R. Graybill, R.J. Hamill, et al., Clinical practice guidelines for the management of cryptococcal disease: 2010 update by the infectious diseases society of America, *Clin. Infect. Dis.* 50 (3) (2010) 291–322, <https://doi.org/10.1086/649858>.
- [18] N. Haddad, M.C. Cavallaro, M.P. Lopes, J.M.J. Fernandez, L.S. Laborda, J.P. Otoch, et al., Pulmonary *Cryptococcoma*: a rare and challenging diagnosis in immunocompetent patients, *Autopsy and Case Reports* 5 (2) (2015) 35–40, <https://doi.org/10.4322/acr.2015.004>.
- [19] Y. Tanaka, K. Satomi, Surgical resection during chemotherapy of pulmonary *Cryptococcoma* in a patient with *Cryptococcal meningitis*, *Internal Medicine* 56 (1) (2016) 91–93, <https://doi.org/10.2169/internalmedicine.56.7056>.