

## Case Report

# Dry cough in a middle-aged man

Sheetu Singh, Nishtha Singh<sup>1</sup>, Arpita Jindal<sup>2</sup>

Departments of Chest and Tuberculosis and <sup>2</sup>Pathology, SMS Medical College, <sup>1</sup>Department of Pulmonary Medicine, Asthma Bhawan, Jaipur, Rajasthan, India

## ABSTRACT

Cough is often a distressing feature and may be caused due to varied reasons. A 39-year-old man presented with complaints of cough and had significant pigeon exposure. His chest X-ray revealed mediastinal enlargement and computed tomography chest revealed air trapping and mediastinal lymphadenopathy. Both endobronchial and transbronchial biopsies revealed granulomas. Thus, the patient was diagnosed as a case of sarcoidosis and started on steroids. Hypersensitivity pneumonitis may often mimic sarcoidosis; however, the presence of endobronchial granulomas will diagnose the latter condition.

**KEY WORDS:** Cough, hypersensitivity pneumonitis, sarcoidosis

**Address for correspondence:** Dr. Sheetu Singh, 167-Officers Campus Extension, Sirsi Road, Jaipur - 302 012, Rajasthan, India.  
E-mail: sheetusingh@yahoo.co.in

## INTRODUCTION

Cough is a common presenting complaint in the respiratory clinic and is described by a sudden forceful expiration. An excessive cough can become distressing for the patient and can lead to complications such as cough syncope and pneumothorax. Therefore, treating cough becomes a vital parameter in the treatment of respiratory diseases. Interstitial lung diseases (ILDs) are an important cause of cough and the associated cough is usually dry in nature. Hypersensitivity pneumonitis (HP) and sarcoidosis are two important types of ILDs. HP is caused due to exposure to organic dust and presents in acute, subacute, and chronic forms of cough and dyspnea. The radiology shows an upper lobe predominant pattern with centrilobular nodules and air trapping. Histopathology suggests loosely formed granulomas in transbronchial or open lung biopsy specimens. Sarcoidosis may present with similar respiratory symptoms, radiology, and histopathology.

We present a case of dry cough which was unique because it presented with features suggestive of these two important

ILDs. The subsequent course of investigations helped confirm the diagnosis.

## CASE REPORT

A 39-year-old male presented with complaints of dry cough for 4 months. It was insidious in onset, progressive in nature, and had no aggravating and relieving factors. The cough was distressing and was interfering with the day-to-day activities of the patient. He also developed joint pains in both small and large joints of the body for 1 month. He gave a history of feeding pigeons on his terrace daily for an hour or so. He was a nonsmoker and worked as a distributor in a pharmacy company.

On examination, his pulse rate was 90/min, blood pressure was 140/90 mmHg, respiratory rate was 12/min, and body mass index was 32 kg/m<sup>2</sup>. His respiratory system examination was within normal limits. Complete blood count, blood sugar, liver function tests, and renal function tests were within normal limits. His chest X-ray showed mediastinal widening and normal lung fields [Figure 1].

### Access this article online

Quick Response Code:



Website:

www.lungindia.com

DOI:

10.4103/0970-2113.192870

This is an open access article distributed under the terms of the Creative Commons Attribution-NonCommercial-ShareAlike 3.0 License, which allows others to remix, tweak, and build upon the work non-commercially, as long as the author is credited and the new creations are licensed under the identical terms.

**For reprints contact:** reprints@medknow.com

**How to cite this article:** Singh S, Singh N, Jindal A. Dry cough in a middle-aged man. Lung India 2016;33:657-60.

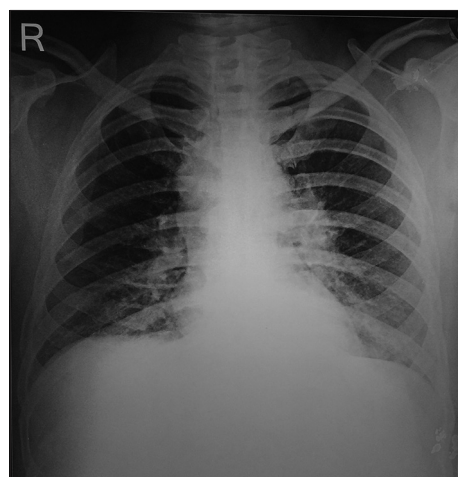
Six min walk test (6MWT) was done in which the patient walked a distance of 528 m and desaturated from 95% to 92%. Lung function tests showed moderate obstruction with diffusing capacity of carbon monoxide (DLCO) of 76% predicted [Table 1]. High-resolution computed tomography (HRCT) chest revealed multiple areas of air trapping with mediastinal and hilar lymphadenopathies in the expiratory scans [Figure 2a and b]. Fiberoptic bronchoscopy showed nodular lesions spread throughout the bronchial tree. Biopsies of the nodular lesions and transbronchial lung biopsies (TBLBs) were conducted and they revealed noncaseating discrete granulomas [Figure 3]. Mycobacterial and fungal culture of the biopsy specimens failed to reveal any organism. Serum angiotensin-converting enzyme (ACE) levels were found to be 103 U/L, and Mantoux test was negative.

The patient was diagnosed as a case of sarcoidosis and graded as stage 2 according to the Scadding criteria. The patient was started on oral prednisolone 40 mg/day (the weight of patient being 98 kg). He was continued on oral prednisolone 40 mg/day for 4 weeks. His cough gradually disappeared and he improved clinically. After 4 weeks, his steroid dose was tapered to maintenance dose (0.25 mg/kg) while maintaining remission. However, 6 months in the maintenance treatment, the patient developed diabetes mellitus and he refused to take steroids any further. The patient was switched to oral methotrexate 7.5 mg per week supplemented with folic acid. CBC and LFT were monitored for methotrexate-induced bone marrow and hepatic toxicity. The patient responded to treatment and maintained remission. He was followed up with repeat lung function, diffusion, and 6MWT which were within normal limits [Table 1]. Repeat CT chest after 1 year of maintaining remission showed resolution of disease. The treatment was stopped, and thereafter patient was followed up six monthly.

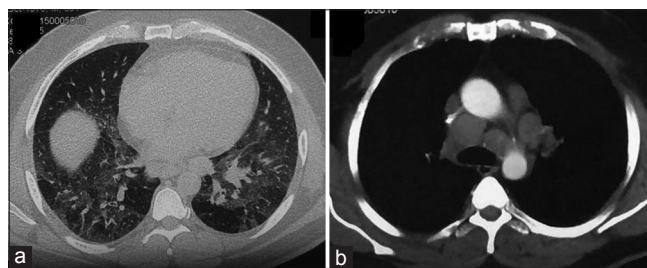
## DISCUSSION

Sarcoidosis is a disease that primarily affects lungs, but in 30% cases, also involves extrathoracic organs.<sup>[1-3]</sup> It typically affects women in the age group from 20 to 60 years. It is diagnosed pathologically by the presence of noncaseating granulomas on biopsy of the lesion and presents in one or more of the following ways - pulmonary involvement in the form of hilar adenopathy or reticular shadows or extrapulmonary involvement in the form of

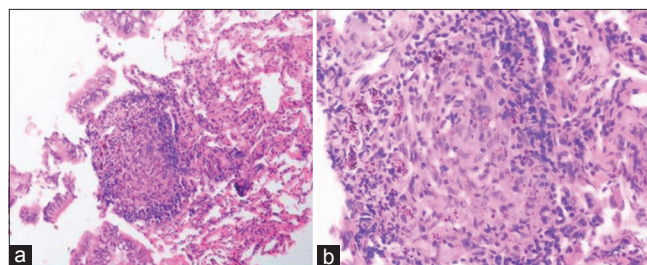
eye/joint/skin/cardiac/central nervous system lesions. In few cases, the patient may be asymptomatic and is diagnosed incidentally on chest X-ray. The common respiratory complaints include breathlessness, cough, and chest pain. Other associated systemic symptoms are fever, fatigue, exercise intolerance, weight loss, muscle weakness, and malaise.<sup>[4-6]</sup> A detailed clinical history, examination, tuberculin skin test, chest X-ray, high-resolution CT scan, pulmonary function tests, and electrocardiogram are relevant in making the diagnosis.<sup>[7]</sup> Serum ACE is raised in 60–70% of patients and correlates with disease severity.<sup>[8]</sup> Hypercalcemia and hypercalciuria are seen in 10–20% of patients. The most common CT findings in sarcoidosis are



**Figure 1:** Chest radiograph reveals left hilar enlargement and ground glass haziness in the left lower lung zone



**Figure 2:** (a) High-resolution computed tomography scan (expiratory) shows multiple lobular areas of air trapping in the lung window, (b) mediastinal window shows prominent hilar and mediastinal lymphadenopathies



**Figure 3:** (a) Photomicrograph of transbronchial lung biopsy specimen showing a discrete, well-defined granuloma, (b) high-power view of granuloma composed of lymphocytes, epithelioid cells, and other inflammatory cells

**Table 1: Lung function parameters of the patient before and after treatment**

	Before treatment	After treatment
6 min walk distance (m)	528	550
SpO <sub>2</sub> before and after 5 min walk test (%)	95→92	97→95
Forced vital capacity (L)	3.8	4.1
DLCO (ml/mmHg/min) (%)	24.73 (76)	27.80 (86)

SpO<sub>2</sub>: Saturation of peripheral oxygen, DLCO: Diffusing capacity of carbon monoxide

perilymphatic nodules, reticular shadows, air trapping, and hilar lymphadenopathy.<sup>[9]</sup>

Bronchoscopy is a useful tool to diagnose sarcoidosis; TBLB provides tissue for diagnosis and bronchoscopy can also detect endobronchial abnormality. Endobronchial sarcoidosis occurs rarely and it may manifest with areas of edema, erythema, nodules, stenosis, and plaques. These nodules give rise to cobblestoning or pebbly mural appearance.<sup>[10]</sup> Biopsy from these nodules demonstrates noncaseating granulomas. In cases of normal endobronchial tree also, biopsies from secondary and tertiary carina may yield the diagnosis in 30% of cases.<sup>[11,12]</sup> Transbronchial fine-needle aspiration (TBNA) and/or endobronchial ultrasound-guided fine-needle aspiration cytology (EBUS-FNAC) are techniques to access the mediastinal lymph nodes. Thus, with a combination of techniques of TBLB, endobronchial biopsies and EBUS-FNAC tissue can be obtained for diagnosis.

An important differential in our case was HP as it presents with exposure history to birds, HRCT suggestive of air trapping, and granulomas in TBLB. Bilateral hilar adenopathy, which was a feature in our case, is not seen in HP and seen in 80–90% cases of sarcoidosis.<sup>[13]</sup> Histopathology in sarcoidosis is characterized by discrete noncaseating granulomas and HP is characterized by loose, poorly formed granulomas. Previous studies have been done to study the pattern of disease in both sarcoidosis and HP, and they have inferred that biopsy of the involved lesion remains the gold standard for differentiating the two conditions.<sup>[14,15]</sup> Moreover, endobronchial granulomas are characteristic of sarcoidosis and not HP. This was a differentiating feature in our case.

Certain other causes of noncaseating granulomas are also important differential diagnosis in our case. Infective diseases (tuberculosis, histoplasmosis, and atypical mycobacteria), rheumatoid arthritis, granulomatosis with polyangiitis, and berylliosis are some of the causes of noncaseating granulomas.<sup>[16]</sup> A negative tubercular and fungal culture of the biopsy specimen, no history suggestive of rheumatoid arthritis, granulomatosis with polyangiitis, beryllium exposure, and presence of endobronchial granulomas in our case are diagnostic of sarcoidosis.

Steroids are the first line of drugs that are used to treat symptomatic patients of sarcoidosis. In cases of steroid intolerance, the second line drugs are methotrexate, azathioprine, leflunomide, and infliximab. Our patient had an initial response to steroids and due to intolerance, he was switched to methotrexate. He responded to both drugs clinically. Steroids have been shown to improve forced vital capacity (FVC) in few retrospective studies.<sup>[17]</sup> However, in placebo-controlled trials, no significant difference has been found in FVC as compared to the placebo-controlled group.<sup>[18]</sup> DLCO has also been shown to improve with therapy in some studies but not in others.<sup>[19]</sup> The possible

hypothesis of no improvement in DLCO is that irreversible fibrosis develops in cases of sarcoidosis. In our case, DLCO may have improved because the initial diffusion defect was only mild in nature. Other factors may be the lack of fibrosis and resolution of granulomas with steroid therapy in our case which lead to improvement in DLCO.

## CONCLUSION

Sarcoidosis and HP many a times present in a similar way. Differentiating between these two conditions is important to decide the future course of treatment and also prognosis.

## Financial support and sponsorship

Nil.

## Conflicts of interest

There are no conflicts of interest.

## REFERENCES

1. Sawahata M, Sugiyama Y, Nakamura Y, Nakayama M, Mato N, Yamasawa H, *et al.* Age-related and historical changes in the clinical characteristics of sarcoidosis in Japan. *Respir Med* 2015;109:272-8.
2. Rizzato G, Tinelli C. Unusual presentation of sarcoidosis. *Respiration* 2005;72:3-6.
3. Rao DA, Dellaripa PF. Extrapulmonary manifestations of sarcoidosis. *Rheum Dis Clin North Am* 2013;39:277-97.
4. Strookappe B, De Vries J, Elfferich M, Kuijpers P, Knevel T, Drent M. Predictors of fatigue in sarcoidosis: The value of exercise testing. *Respir Med* 2016;116:49-54.
5. Delobbe A, Perrault H, Maitre J, Robin S, Hossein-Foucher C, Wallaert B, *et al.* Impaired exercise response in sarcoid patients with normal pulmonary function. *Sarcoidosis Vasc Diffuse Lung Dis* 2002;19:148-53.
6. Spruit MA, Thomeer MJ, Gosselink R, Troosters T, Kasran A, Debrock AJ, *et al.* Skeletal muscle weakness in patients with sarcoidosis and its relationship with exercise intolerance and reduced health status. *Thorax* 2005;60:32-8.
7. Statement on sarcoidosis. Joint Statement of the American Thoracic Society (ATS), the European Respiratory Society (ERS) and the World Association of Sarcoidosis and Other Granulomatous Disorders (WASOG) adopted by the ATS Board of Directors and by the ERS Executive Committee, February 1999. *Am J Respir Crit Care Med* 1999;160:736-55.
8. Iannuzzi MC, Rybicki BA, Teirstein AS. Sarcoidosis. *N Engl J Med* 2007;357:2153-65.
9. Terasaki H, Fujimoto K, Müller NL, Sadohara J, Uchida M, Koga T, *et al.* Pulmonary sarcoidosis: Comparison of findings of inspiratory and expiratory high-resolution CT and pulmonary function tests between smokers and nonsmokers. *AJR Am J Roentgenol* 2005;185:333-8.
10. Cho KH, Shin JH, Park SH, Kim HS, Yang SH. A case of pulmonary sarcoidosis with endobronchial nodular involvement. *Tuberc Respir Dis (Seoul)* 2013;74:274-9.
11. Shorr AF, Torrington KG, Hnatiuk OW. Endobronchial biopsy for sarcoidosis: A prospective study. *Chest* 2001;120:109-14.
12. Dziedzic DA, Peryt A, Orlowski T. The role of EBUS-TBNA and standard bronchoscopic modalities in the diagnosis of sarcoidosis. *Clin Respir J* 2015. [doi: 10.1111/crj.12304].
13. Rockoff SD, Rohatgi P. Analysis of Unusual Thoracic Manifestations of Sarcoidosis: A Review of Radiographic Features. In: Grassi C, Rizzato G, Pozzi E, editors. *Sarcoidosis and Other Granulomatous Diseases* (11<sup>th</sup> Congress). New York: Excerpta Medica, Elsevier Science Publishing; 1988.
14. Forst LS, Abraham J. Hypersensitivity pneumonitis presenting as sarcoidosis. *Br J Ind Med* 1993;50:497-500.
15. Cohen SH, Fink JN, Garancis JC, Hensley GT, Barboriak JJ, Schlueter DP. Sarcoidosis in hypersensitivity pneumonitis. *Chest* 1977;72:588-92.
16. Mukhopadhyay S, Wilcox BE, Myers JL, Bryant SC, Buckwalter SP, Wengenack NL, *et al.* Pulmonary necrotizing granulomas of unknown

- cause: Clinical and pathologic analysis of 131 patients with completely resected nodules. *Chest* 2013;144:813-24.
17. McKinzie BP, Bullington WM, Mazur JE, Judson MA. Efficacy of short-course, low-dose corticosteroid therapy for acute pulmonary sarcoidosis exacerbations. *Am J Med Sci* 2010;339:1-4.
  18. Paramothayan S, Jones PW. Corticosteroid therapy in pulmonary sarcoidosis: A systematic review. *JAMA* 2002;287:1301-7.
  19. Baughman RP, Nunes H, Sweiss NJ, Lower EE. Established and experimental medical therapy of pulmonary sarcoidosis. *Eur Respir J* 2013;41:1424-38.