

Clinical Study

Effectiveness of Sequential Viscosupplementation in Temporomandibular Joint Internal Derangements and Symptomatology: A Case Series

Roberta Maria Drumond Furtado Bossi Fonseca,¹ Eduardo Januzzi,²
Luciano Ambrosio Ferreira ,^{3,4} Eduardo Grossmann,⁵ Antonio Carlos Pires Carvalho ,³
Pedro Gonçalves de Oliveira,⁶ Érica Leandro Marciano Vieira ,⁷
Antônio Lúcio Teixeira ,^{7,8} and Camila Megale Almeida-Leite ^{1,9}

¹Programa de Pós-Graduação em Patologia, Faculdade de Medicina, Universidade Federal de Minas Gerais (UFMG), Belo Horizonte, MG, Brazil

²Faculdade Ciodonto, Sete Lagoas, MG, Brazil

³Departamento de Radiologia, Faculdade de Medicina, Universidade Federal do Rio de Janeiro, Rio de Janeiro, RJ, Brazil

⁴Hospital Maternidade Therezinha de Jesus-HMTJ/JF, Suprema-Faculdade de Ciências Médicas e da Saúde, Juiz de Fora, Brazil

⁵Departamento de Ciências Morfológicas, Instituto de Ciências Básicas da Saúde, Universidade Federal do Rio Grande do Sul, Porto Alegre, RS, Brazil

⁶Faculdade de Farmácia, Universidade Anhembi Morumbi, São Paulo, SP, Brazil

⁷Departamento de Clínica Médica, Faculdade de Medicina, UFMG, Belo Horizonte, MG, Brazil

⁸Department of Psychiatry and Behavioral Sciences, The University of Texas, Houston, TX, USA

⁹Departamento de Morfologia, Instituto de Ciências Biológicas, UFMG, Belo Horizonte, MG, Brazil

Correspondence should be addressed to Camila Megale Almeida-Leite; camila@icb.ufmg.br

Received 4 March 2018; Revised 11 June 2018; Accepted 9 July 2018; Published 31 July 2018

Academic Editor: Fabiana Ballanti

Copyright © 2018 Roberta Maria Drumond Furtado Bossi Fonseca et al. This is an open access article distributed under the Creative Commons Attribution License, which permits unrestricted use, distribution, and reproduction in any medium, provided the original work is properly cited.

Viscosupplementation is a minimally invasive technique that replaces synovial fluid by intra-articular injection of hyaluronic acid (HA). Although effective in some joints, there is not conclusive evidence regarding temporomandibular disorders. This case series described the efficacy of a viscosupplementation protocol in intra-articular temporomandibular disorders. Ten patients with a diagnosis of disc displacement and/or osteoarthritis by Research Diagnostic Criteria for Temporomandibular Disorders (RDC/TMD) were submitted to four monthly injections of low or medium molecular weight HA. Pain, mandibular function, image analysis by tomography and magnetic resonance, and quality of life were assessed at baseline and follow-ups (1 and 6 months). Pain, jaw range-of-motion, mandibular function, and quality of life improved at follow-up evaluations. Osteoarthritis changes decreased, and 20% of patients improved mandibular head excursion after treatment. Resolution of effusion and improvement in disc morphology were observed for most patients. This viscosupplementation protocol reduced pain and symptoms associated with internal derangement of temporomandibular joint, improved quality of life, and showed benefits from both low and medium molecular weight HA in alternate cycles.

1. Introduction

Temporomandibular disorders (TMDs) are a heterogeneous group of disorders involving the temporomandibular joint (TMJ), the masticatory muscles, and associated structures

[1–3]. TMD affect 5 to 12% of population [4], and their management causes high costs to public health [5]. The most common signs and symptoms include pain, TMJ sounds, and limitation of mandibular movement, which can compromise daily activities and quality of life [2, 6].

According to American Academy of Orofacial Pain (AAOP), diagnosis and classification of TMD are divided into two major groups: muscle and joint disorders, with their respective subdivisions [3]. Among intra-articular TMD, disc displacement with or without reduction and degenerative joint disorders (osteoarthritis and osteoarthritis) are the most frequent alterations. They are associated to changes in quantity and quality of synovial fluid (SF) [3, 7].

Viscosupplementation (VS) is a minimally invasive technique that involves replacement of synovial fluid by intra-articular injection of hyaluronic acid (HA) which restores its concentration and molecular weight in joint cavity [8]. HA is an important component of synovial fluid and is produced by type B synoviocytes. These molecules are involved by a large amount of water and provide suitable viscosity and elasticity for synovial fluid [9]. Studies about the effects of exogenous HA with different molecular weights have been performed. It has been suggested that high molecular weight HA is important in lubrication and protection of joint structures due to its improvement of highly hydrated and rheological environment [10, 11]. In contrast, low molecular weight HA induces its endogen production by type B synoviocytes restoring natural properties of synovial fluid [12, 13].

VS has been proven to be effective for knee and other large joints [14], and it can stimulate de novo synthesis of HA and inhibits release of inflammatory mediators by synoviocytes [8], such as cytokines and metalloproteinases that have been associated with osteoarthritis, mediating pain, and tissue damage [15–18].

Regarding TMD, there is not conclusive evidence [19–21]. Several studies have shown that VS can improve lubrication and biomechanical properties of TMJ and eliminate or reduce joint-related pain [22–26], but different concentrations and molecular weights of HA, varied number of intra-articular injections, and treatment cycles made it difficult to establish an effective approach [19–21]. Recent systematic reviews have shown that HA intra-articular injections in TMJ can be beneficial in improving pain and symptoms of TMDs and in regulating inflammatory mediators better than placebo, but they highlight that further clinical research is necessary to establish its effectiveness, mainly in comparison to corticosteroid [19–21]. Moreover, these works emphasize that an adequate protocol with number of injections, appropriate molecular weight of HA, minimum effective dose, and long-term side effects should be addressed [19–21].

Based upon clinical use of VS in joint disorders, including TMD, and the need of an efficient protocol for treatment, we describe a case series of four monthly injections of low and medium molecular weight HA in superior TMJ compartment and analyze TMJ dysfunction and quality of life through validated instruments and TMJ image analysis.

2. Materials and Methods

This study was approved by the Ethics Committee of Universidade Federal de Minas Gerais, Belo Horizonte,

Brazil (CAAE-24911314.3.0000.5149) and registered in Brazilian Registry of Clinical Trials (RBR-6759yz). All procedures were performed in accordance with the ethical standards of institutional and/or national research committee and with the principles stated in the 1964 Helsinki Declaration and its later amendments. All patients provided written informed consent before inclusion in the study and received free and unconditional treatment.

Ten consecutive patients fulfilling the following inclusion criteria were selected from university orofacial pain division or from a private orofacial pain clinic: age between 18 and 70, diagnosis of disc displacement with or without reduction, and/or osteoarthritis according to the Research Diagnostic Criteria for Temporomandibular Disorders (RDC/TMD Axis I). Patients with rheumatologic diseases, neuropathic pain, or history of previous TMJ surgery, trauma, or fractures were excluded. No other treatment for TMD (physical therapy, jaw exercises, heat pack to the jaw, and muscle relaxants) was allowed during the study period, and anamnesis before each session was performed to control it.

2.1. Viscosupplementation. All ten selected patients underwent a cycle of four injections (1 per month) of 1 mL of HA in upper joint compartment of both joints as previously described [7]. Low MW HA (500–730 kDa, Polireumin®) was used in months 1 and 3 and medium MW HA (1,000–2,000 kDa, Osteonil Mini®) was injected in months 2 and 4. All injection procedures were conducted by the same physician. Baseline evaluation and two follow-up assessments (1 month and 6 months) were performed after the end of the treatment.

2.2. Clinical Evaluation. Clinical evaluations were performed by the same experienced operator after training and calibration by RDC/TMD examination protocol [27]. The following parameters were assessed at the time of diagnosis (baseline) and at each appointment during treatment (data not shown) and follow-ups (1 and 6 months after treatment): (1) pain intensity by 0–10 numeric rating scale (NRS) (0 = no pain and 10 = worst possible pain) [28]; (2) pain quality by multidimensional McGill Pain Questionnaire (MPQ), which characterizes emotional and sensory aspects of pain with scores ranging from 1 to 78 [29]; (3) pain-related impact of life by Manchester Orofacial Pain Disability Scale (MOPDS-Brazil), a 26-item Likert scale questionnaire with scores ranging from 0 to 52 [30]; (4) jaw range-of-motion by interincisal distance; (5) severity of craniomandibular dysfunction by Clinical Dysfunction Index Craniomandibular (IDCCM), ranging from 0 to 5 [31]; (6) functional limitation by Mandibular Function Impairment Questionnaire (MFIQ), a 17-item Likert scale questionnaire with final score ranging from 0 to 5 [32]; (7) quality of life by Oral Health Impact Profile (OHIP-49) with values from 0 to 280 [33].

2.3. Image Analysis. The patients' left and right joints were examined by cone-beam computerized tomography (CBCT)

and by magnetic resonance imaging (MRI) at baseline and at final follow-up (6 months after treatment). Images were interpreted by a blind experienced radiologist and all available slices were evaluated. In CBCT, osteoarthritic (OA) changes were defined according to Ahmad et al. [34] by the presence of sclerosis (loss of convex aspect in the articular surface), osteophyte (reactive bone spurs), erosion (cortical rupture), and subchondral cyst (pseudocyst infiltrated in the subcortical region). All parameters were analyzed in sagittal and coronal views of 1 mm interval through Radiocef Studio 2 software as previously described [34]. The distance of the outmost points of detected alterations were compared between baseline and final follow-up images in the same tomographic slice. Position of mandibular head in relation to temporal bone was assessed by visual inspection of the CBCT scan slides and categorized as normal mobility, hypomobility or hypermobility. In MRI, posterior band disc joint position in sagittal and coronal views was evaluated as previously described [18], and methods of image analysis for MRI was similar of CBCT. Presence of reduction, adhesion, and effusion (inflammatory signals) was also analyzed. In addition, morphology of disc was classified as previously described [35].

2.4. Statistical Analysis. Statistical analysis was performed using MINITAB® software version 17. For clinical data, within-patient differences among baseline and follow-up values were assessed by paired *t*-tests for comparing mean change or Wilcoxon signed rank test for comparing median change. Osteoarthritic changes between baseline and final follow-up (6 months) were evaluated by paired *t*-test for comparing mean change (erosion) or by Wilcoxon signed rank test for comparing median change (sclerosis, osteophyte, and flattening). *P* values of 0.05 or less were considered significant. All graphs were created by GraphPad Prism 5.0 software.

3. Results

Demographic characteristics (age, gender, race/ethnicity, marital status, and scholary) of sample are shown in Table 1.

3.1. Clinical Evaluation. At baseline, 50% of patients ($n = 5$ patients) had myofascial pain according to RDC/TMD Axis I Group I (muscle disorders) (Table 2). In RDC/TMD Axis I Group II disorders (disc displacement), 90% ($n = 9$ patients) were diagnosed with disc displacement with reduction (ADDR). Whereas, in RDC/TMD Axis I Group III (other joint conditions), 10% ($n = 1$ patient) had arthralgia at rest and mandibular function and 20% ($n = 2$ patients) had osteoarthritis/osteoarthritis diagnosis.

One and 6 months after treatment, there was a significant change in patient diagnosis according to the RDC/TMD Axis I Group I, that is, no patient was diagnosed with myofascial pain. No changes were observed in RDC/TMD Axis I Group II, except for one patient. In RDC/TMD Axis I Group III, the patient with arthralgia became symptomless

and one of the patients formerly diagnosed with osteoarthritis was diagnosed with osteoarthritis.

Mouth opening without pain improved at 1 month after treatment in comparison to baseline (Figure 1(a)). Craniomandibular dysfunction showed significant improvement 1 and 6 months after treatment (Figure 1(b)). Pain intensity was significantly decreased at 1 and 6 months (Figure 1(c)), as well as McGill pain scores (Figure 1(d)).

Moreover, orofacial pain disability was improved at 1 and 6 months follow-up evaluations (Figure 2(a)) and better mandibular function was detected 6 months after treatment (Figure 2(b)). Quality of life reported by patients showed improvement at both follow-up evaluations in comparison to baseline (Figure 2(c)).

3.2. Image Analysis. At baseline, both TMJs of all patients were examined by CBCT and MRI. Osteoarthritic changes evaluation by CBCT showed significant decrease in presence of osteophyte, flattening, sclerosis, and erosion of mandibular head at 6 months after treatment (Table 3). Hypoplasia and hyperplasia of mandibular head, deviation in form, subcortical cysts, generalized sclerosis, loose joint body or bone ankylosis were not found at baseline or 6 months follow-up. In addition, CBCT has shown that 20% of patients (2 patients) have improved standard excursion of mandibular head in both joints after treatment.

Soft tissue evaluation by MRI before and 6 months after treatment showed the following: (1) all patients had disc displacement with reduction before and after treatment; (2) all patients had alterations in disc position in at least one of the views (sagittal and/or coronal) after treatment; (3) one patient showed remission of right disc adhesion after treatment; (4) all patients (4 joints) who had effusion signal before treatment evolved to resolution of effusion 6 months after treatment (Table 4). Regarding disc shape, all patients showed stabilization or improvement in disc morphology of both joints, except for one patient.

4. Discussion

In this case series, we evaluated the effectiveness of a protocol of four injections of low and medium MW HA on pain, mandibular function, signs of intra-articular disease by image analysis, and quality of life in ten patients with TMD.

After treatment, disc displacement diagnosis by MRI or RDC/TMD was not changed, except for one patient, which was expected since TMJ discs cannot be replaced by minimal invasive technique [36]. Disc position in coronal view was altered in 5 joints after treatment, and this may be due to better lubrication and recovery of mandibular dynamics obtained by VS. Joint sound is the clinical sign that RDC/TMD utilizes for disc displacement diagnosis, but disc position can only be determined by MRI analysis [27]. Since VS improves joint lubrication and biomechanics, joint sound may not be present even when disc is displaced. This might be the case for the patient that had a change in clinical diagnosis by RDC/TMD, although image analysis did not change.

TABLE 1: Demographic characteristics of patients.

Patient	Age	Gender	Race/ethnicity	Marital status	Education
1	35	F	Other or unstated	Never married	High school or less
2	47	F	Other or unstated	Married	High school or less
3	34	M	Other or unstated	Married	High school or less
4	66	F	White	Married	High school or less
5	20	F	White	Never married	Undergraduate degree
6	30	F	Other or unstated	Married	High school or less
7	19	F	White	Never married	Undergraduate degree
8	27	F	Other or unstated	Never married	Postgraduate degree
9	43	F	Other or unstated	Divorced	High school or less
10	37	F	White	Never married	Postgraduate degree

M: male; F: female.

TABLE 2: RDC/TMD diagnosis at baseline and follow-ups (1 and 6 months).

Patient	Research diagnostic criteria						
	Group I	Axis I				Group III	
		Group II	Right	Left	Right	Left	
1	Baseline	MPWLO	ADDR	ADDR	—	—	
	Follow-up (1 month)	—	ADDR	ADDR	—	—	
	Follow-up (6 months)	—	ADDR	ADDR	—	—	
2	Baseline	—	ADDR	ADDR	—	—	
	Follow-up (1 month)	—	ADDR	ADDR	—	—	
	Follow-up (6 months)	—	ADDR	ADDR	—	—	
3	Baseline	—	ADDR	ADDR	—	—	
	Follow-up (1 month)	—	—	—	—	—	
	Follow-up (6 months)	—	—	—	—	—	
4	Baseline	—	ADDR	ADDR	—	—	
	Follow-up (1 month)	—	ADDR	ADDR	—	—	
	Follow-up (6 months)	—	ADDR	ADDR	—	—	
5	Baseline	MP	ADDR	ADDR	Arthralgia	Arthralgia	
	Follow-up (1 month)	—	ADDR	ADDR	—	—	
	Follow-up (6 months)	—	ADDR	ADDR	—	—	
6	Baseline	MP	ADDR	ADDR	Osteoarthritis	Osteoarthritis	
	Follow-up (1 month)	—	ADDR	ADDR	Osteoarthritis	Osteoarthritis	
	Follow-up (6 months)	—	ADDR	ADDR	Osteoarthritis	Osteoarthritis	
7	Baseline	MP	ADDR	ADDR	—	—	
	Follow-up (1 month)	—	ADDR	ADDR	—	—	
	Follow-up (6 months)	—	ADDR	ADDR	—	—	
8	Baseline	—	ADDR	ADDR	—	—	
	Follow-up (1 month)	—	ADDR	ADDR	—	—	
	Follow-up (6 months)	—	ADDR	ADDR	—	—	
9	Baseline	—	—	—	Osteoarthritis	Osteoarthritis	
	Follow-up (1 month)	—	—	—	Osteoarthritis	Osteoarthritis	
	Follow-up (6 months)	*	*	*	*	*	
10	Baseline	MPWLO	ADDR	ADDR	—	—	
	Follow-up (1 month)	—	ADDR	ADDR	—	—	
	Follow-up (6 months)	*	*	*	*	*	

RDC/TMD Axis I Group I (muscle disorders): MP = myofascial pain, MPWLO = myofascial pain with limited opening; Group II (disc displacement): ADDR = disc displacement with reduction; Group III (other joint conditions). *Patient did not attend final follow-up.

All patients initially diagnosed with muscle pain (myofascial), joint pain (arthralgia), or limited mouth opening have improved pain and function and those diagnoses were not observed at follow-ups. Pain relief was observed by a significant reduction of pain intensity and scores measured by NRS, McGill, and MOPDS. This may be

attributed to different mechanisms regarding TMJ, such as anti-inflammatory effects of HA injection with consequent decrease of metalloproteinases and proinflammatory mediators in synovial fluid, as well as improvement of joint biomechanics [10–13]. In this work, measurement of synovial fluid inflammatory mediators was not performed to

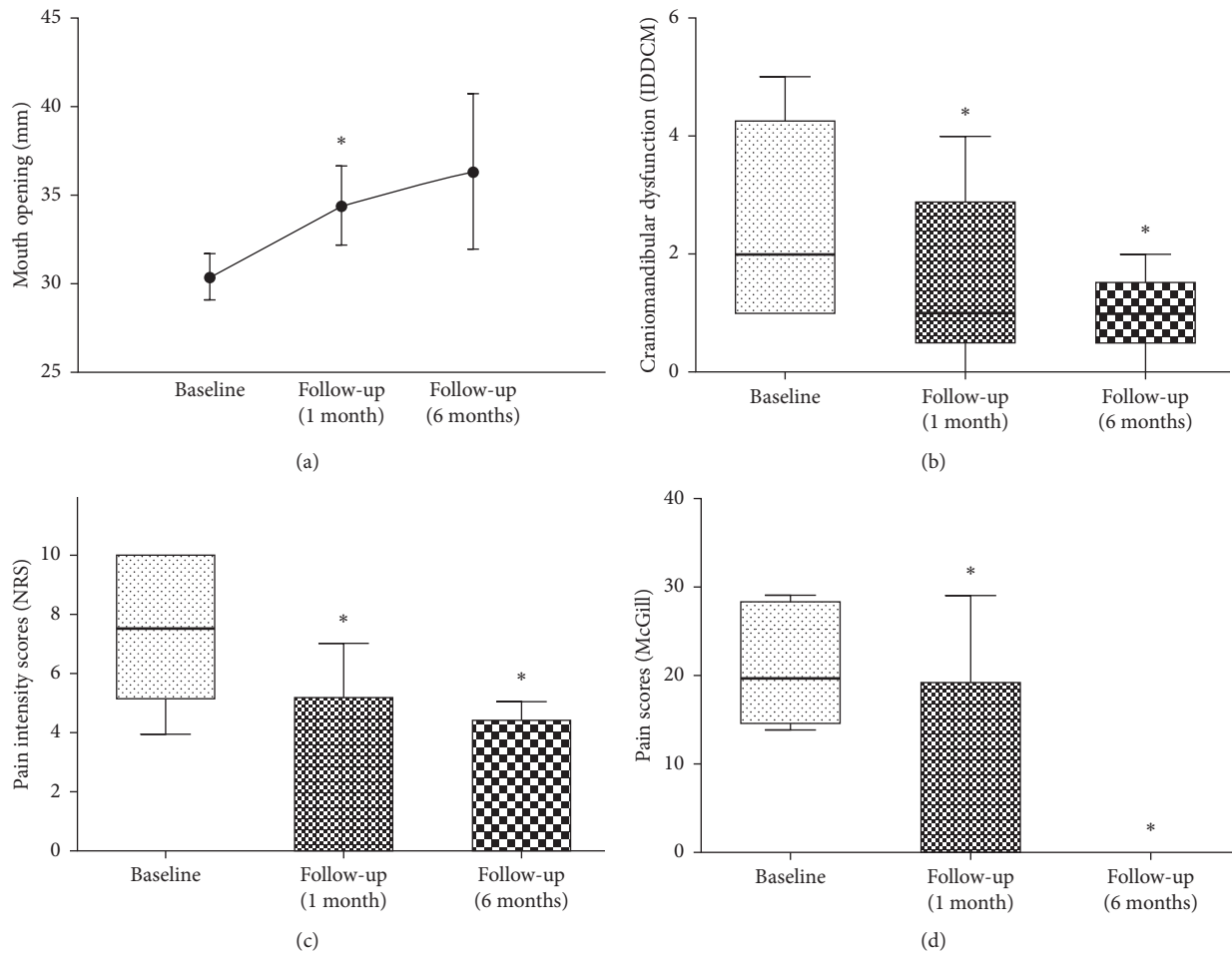


FIGURE 1: (a) Improvement on mouth opening without pain (measured in mm) at 1 and 6 months after treatment. This parameter was analyzed only on patients who showed limited mouth opening at baseline. Bars represent standard deviation (SD). Student's *t*-test; **p* = 0.039; *n* = 5 patients (1-month follow-up) and 3 patients (6-month follow-up). (b) Decrease in scores of craniomandibular dysfunction (IDDCM-Helkimo Index) at 1 and 6 months after treatment. Box and whisker show quartiles, the band inside the box is the median, and the ends of the whiskers represent minimum and maximum values. Wilcoxon signed rank test; **p* = 0.034 (1-month follow-up) and **p* = 0.038 (6-month follow-up); *n* = 10 patients (1-month follow-up) and 8 patients (6-month follow-up). (c) Decrease in NRS pain intensity at 1 and 6 months after treatment. This parameter was analyzed only on patients who showed pain at baseline. Box and whisker show quartiles, the band inside the box is the median, and the ends of the whiskers represent minimum and maximum values. Wilcoxon signed rank test; **p* = 0.018 (1-month follow-up) and **p* = 0.05 (6-month follow-up); *n* = 6 patients (1-month follow-up) and 4 patients (6-month follow-up). (d) Decrease in McGill pain scores at 1 and 6 months after treatment. This parameter was analyzed only on patients who showed pain at baseline. Box and whisker show quartiles, the band inside the box is the median, and the ends of the whiskers represent minimum and maximum values. Wilcoxon signed rank test; **p* = 0.042 (1-month follow-up) and **p* = 0.05 (6-month follow-up); *n* = 6 patients (1-month follow-up) and 4 patients (6-month follow-up).

avoid invasive technique of TMJ, which could create bias in treatment outcome. Moreover, masticatory muscles promote jaw movements and their functionality is related to structural and functional integrity of TMJ [2]. Hence, relief or improvement of joint symptoms, as well as restoration of biomechanics by VS protocol, may be associated with better function of adjacent muscles and pain relief. Moreover, diminished peripheral inputs by restored TMJ may lead to improvement of central sensitization and muscle pain [37].

VS protocol tested here showed significant improvement in mouth opening amplitude both in clinical and radiologic evaluations. This outcome in clinical examination has also been shown in other studies of VS but with different protocols

[7, 8, 24, 25] and may be due to restoration of joint lubrication. Moreover, VS was able to improve medial disc position, shown by MRI, which may have contributed to better mandible movements, TMJ biomechanics, and quality of life.

Less severe dysfunction was observed after treatment. Evaluation of mandible function by MFIQ has also shown improvement. More importantly, patients' evaluation of quality of life has improved. Other studies have also shown beneficial outcomes of VS by mouth opening, pain intensity, and subjective parameters such as satisfaction with treatment [7, 24, 25]. However, to our knowledge, objective evaluation of TMJ dysfunction, mandible function, and quality of life through validated instruments is first described here.

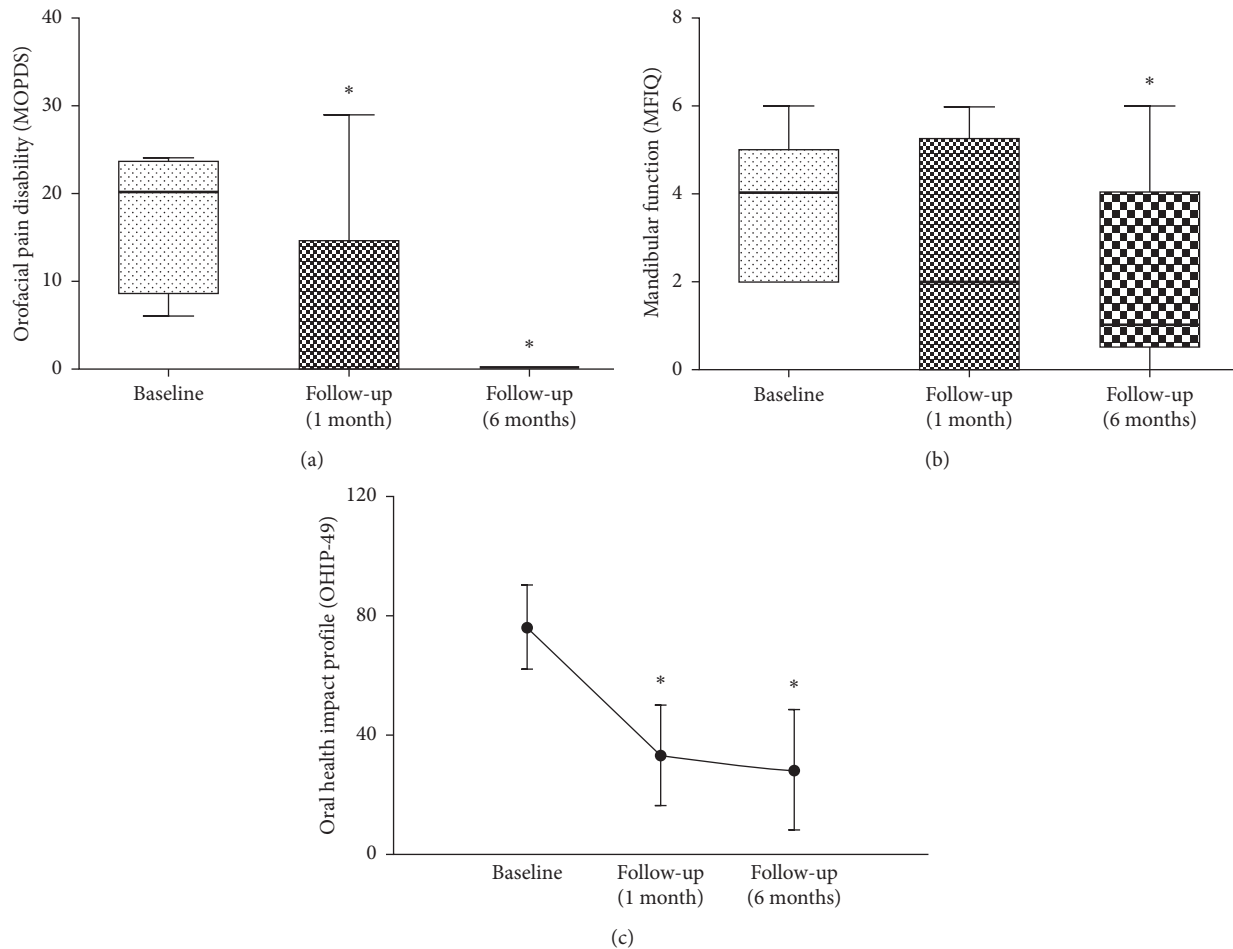


FIGURE 2: (a) Improvement on orofacial pain disability at 1 and 6 months after treatment. This parameter was analyzed only on patients who showed pain at baseline. Box and whisker show quartiles, the band inside the box is the median, and the ends of the whiskers represent minimum and maximum values. Wilcoxon signed rank test; $*p = 0.042$ (1-month follow-up) and $*p = 0.05$ (6-month follow-up); $n = 6$ patients (1-month follow-up) and 4 patients (6-month follow-up). (b) Improvement on mandibular function MFIQ at 6 months after treatment. Box and whisker show quartiles, the band inside the box is the median, and the ends of the whiskers represent minimum and maximum values. Wilcoxon signed rank test; $p < 0.05$ (1-month follow-up) and, $*p = 0.038$ (6-month follow-up); $n = 10$ patients (1-month follow-up) and 8 patients (6-month follow-up). (c) Decrease of impact on quality of life (OHIP-49) at 1 and 6 months. Bars represent standard deviation (SD). Student's t -test; $*p = 0.029$ (1-month follow-up) and $*p = 0.035$ (6-month follow-up); $n = 10$ patients (1-month follow-up) and 8 patients (6-month follow-up).

It is important to highlight that pain relief as well as improvement in mouth opening, mandibular function, and quality of life may also be a result of observed remission of myofascial pain itself. As mentioned, masticatory muscles and TMJ are structurally functionally related [2]. Moreover, reduction on pain could be also attributed to a better consciousness of mandibular function or to a placebo effect as a consequence of being under of examination and treatment for TMD. However, this hypothesis cannot be tested or excluded at this time.

Only a few studies have used image analysis to evaluate TMD treatment efficacy [18, 26]. In this work, image analysis revealed positive effects of established therapeutics in shape and function of hard and soft tissues of TMJ. VS improvement of biomechanics and lubrication seems to stabilize disc shape and avoid greater deformities, which is relevant for the course of the disease [34]. Moreover, effusion signals were not observed after treatment and our VS protocol showed

effectiveness in recovery of joint inflammation and OA degenerative changes. VS beneficial effects such as reduction of joint friction, improvement of rheological environment [10, 11], and induction of endogen production of HA [12, 13] may lead to anatomical rearrangement and can justify CBCT and MRI tissue remodeling observed here.

Among studies that have shown efficacy of VS in TMD, different methods have been described and, as a result, there is an effort of researchers and clinicians to establish an effective protocol for treatment of TMD, as already established for other joints [7, 12, 24, 38]. The present study shows a new protocol of four injections of low and medium MW HA in TMJ with relevant clinical effectiveness on pain, jaw range of motion, dysfunction degree, and quality of life. Furthermore, it is important to emphasize that VS as a single intra-articular treatment is less aggressive than other techniques such as arthrocentesis [7, 24], associated or not with VS, with safety and economic advantages.

TABLE 3: CBCT evaluation of osteoarthritis changes at baseline and at final (6 months) follow-up.

Patient		Osteoarthritis changes of TMJ (mm)							
		Sclerosis		Erosion		Osteophyte		Flattening	
		Right joint	Left joint	Right joint	Left joint	Right joint	Left joint	Right joint	Left joint
2	Baseline	2.370	1.270	1.410	0.420	1.580	0.000	4.510	0.000
	Final	1.020	1.220	0.410	0.290	1.040	0.000	3.130	0.000
3	Baseline	1.210	1.630	0.000	0.000	0.590	0.000	4.950	4.620
	Final	1.060	0.870	0.000	0.000	0.510	0.000	2.220	2.160
4	Baseline	1.800	1.400	0.000	0.000	0.000	0.000	4.070	2.910
	Final	1.280	1.100	0.000	0.000	0.000	0.000	2.000	2.470
5	Baseline	2.470	1.960	1.080	0.730	1.870	1.190	5.570	4.560
	Final	1.550	1.950	0.850	0.350	1.300	0.850	2.520	2.220
6	Baseline	1.610	1.520	0.730	0.000	2.230	0.000	6.380	3.480
	Final	1.560	1.030	0.420	0.000	1.110	0.000	2.410	3.190
7	Baseline	1.020	1.090	0.000	0.550	1.240	1.220	3.250	3.620
	Final	0.920	0.770	0.000	0.190	1.030	0.770	1.650	3.300
8	Baseline	0.880	0.680	0.000	0.000	0.430	0.430	0.460	4.140
	Final	0.690	1.630	0.000	0.000	0.000	0.410	2.220	4.110
Baseline	Mean or median	1.460		0.340		0.510		4.105	
	SD	—		0.470		—		—	
	25%	1.120		—		0.000		3.300	
	75%	1.750		—		1.230		4.600	
Final	Mean or median	1.140		0.170		0.460		2.440	
	SD	—		0.250		—		—	
	25%	0.940		—		0.000		2.220	
	75%	1.550		—		0.980		3.170	
P value	Paired <i>t</i> -test			0.022*					
	Wilcoxon test	0.041*				0.00*		0.027*	

Media and standard deviation (SD) are shown for erosion (parametric data). Median, 25th percentile (25%), and 75th percentile (75%) are shown for other parameters (nonparametric data); *p* values of 0.05 or less were considered significant.

TABLE 4: MRI evaluation of TMJ disc position and adhesion at baseline and at final (6 months) follow-up.

Patient		TMJ soft tissues evaluation							
		Right joint				Left joint			
		Sagittal plane*	Coronal plane*	Adhesion	Reduction	Sagittal plane*	Coronal plane*	Adhesion	Reduction
2	Baseline	AI	S	No	Yes	A	Lateral	No	Yes
	Final	AI	S	No	Yes	A	S	No	Yes
3	Baseline	S	Medial	Yes	Yes	S	S	No	Yes
	Final	A	S	No	Yes	A	S	No	Yes
4	Baseline	A	S	No	Yes	AI	S	No	No
	Final	A	S	No	Yes	S	S	No	Yes
5	Baseline	A	S	No	No	AI	Lateral	No	No
	Final	A	S	No	Yes	A	S	No	Yes
6	Baseline	A	Lateral	No	Yes	A	S	No	Yes
	Final	A	S	No	Yes	AI	S	No	Yes
7	Baseline	A	S	No	Yes	S	S	No	Yes
	Final	S	S	No	Yes	S	Lateral	No	Yes
8	Baseline	A	Lateral	No	Yes	A	S	No	Yes
	Final	A	S	No	No	A	S	No	Yes

* Position of disc posterior band to functional surface of the mandibular head in sagittal and coronal planes: S: superior; A: anterior; AI: anteroinferior. Two patients did not attend final follow-up and 1 could not be submitted to CBCT or MRI because of pregnancy.

The use of HA of different MW in alternated monthly injections is a new perspective of VS in TMD and allows association of biomechanical properties of high MW AH and biological effects of lower MW AH. Hence, this protocol

of treatment is able to promote fast and sustained effects, as suggested by results.

The literature describes different time intervals between applications [24, 38]. We believe that 1-month interval may

allow HA acting inside joint for longer periods, which favor the effects of the next injection and the treatment itself. In addition, treatment cycle with monthly injections may be more tolerated by patients and offer some economic benefits, as it postpones a new cycle. Improvement of pain, mandibular function, and quality of life are in accordance to this finding, and relief of TMD signs and symptoms offered by VS may have restored local and systemic functions.

Although we show promising results regarding the described protocol for TMJ VS, we are aware of the limitations of this work. We believe its greater contribution may be the description of a new perspective to be tested in a well-controlled clinical trial in future research studies. Our small number of patients and the study design as an open label noncontrolled trial does not allow inference of VS positive effects to all TMD patients. However, case series is a descriptive work that illustrates novel features in clinical practice, its sample represents common clinical population, and generates new research questions [39]. Hence, this study aimed at sharing a description of some well succeeded cases of sequential VS in TMJ internal derangements. Moreover, case series usually describes 5 to 7 cases [40], and our sample is in accordance to this type of work, even with loss of 2 patients at final follow-up.

VS protocol shown here reduced pain and symptoms associated with internal derangement of TMJ and improved quality of life of TMD patients. Randomized clinical trials of this treatment protocol should deserve attention in future researches.

Data Availability

The data used to support the findings of this study are included within the article.

Conflicts of Interest

The authors declare no conflicts of interest.

Acknowledgments

R. M. Fonseca received an MSc scholarship from Coordenação de Aperfeiçoamento de Pessoal de Nível Superior (CAPES/Brazil). C. M. Almeida-Leite was funded by Conselho Nacional de Desenvolvimento Científico e Tecnológico (CNPq) (Grant 459228/2014-5). A. L. Teixeira was supported by CNPq and Fundação de Amparo à Pesquisa de Minas Gerais (FAPEMIG). This study appreciates TRB Pharma (Brazil) for donation of hyaluronic acid for viscosupplementation (Polireumin and Osteonil Mini), Radioscan (Brazil) for cone-beam computerized tomography examination, and Hermes Pardini (Brazil) for magnetic resonance imaging.

References

- [1] C. McNeill, "Management of temporomandibular disorders: concepts and controversies," *Journal of Prosthetic Dentistry*, vol. 77, no. 5, pp. 510–522, 1997.
- [2] S. J. Scrivani, D. A. Keith, and L. B. Kaban, "Temporomandibular disorders," *New England Journal of Medicine*, vol. 359, no. 25, pp. 2693–2705, 2008.
- [3] R. De Leeuw and G. D. Klasser, *Orofacial Pain: Guidelines for Assessment, Diagnosis and Management*, Quintessence Publ. Co, Chicago, IL, USA, 5th edition, 2008.
- [4] National Institute of Dental and Craniofacial Research, November 2015, <http://www.nidcr.nih.gov/DataStatistics/FindDataByTopic/FacialPain/PrevalenceTMJD.htm>.
- [5] E. Schiffman, R. Ohrbach, E. Truelove et al., "Diagnostic criteria for temporomandibular disorders (DC/TMD) for clinical and research applications: recommendations of the International RDC/TMD Consortium Network and Orofacial Pain Special Interest Group," *Journal of Oral and Facial Pain and Headache*, vol. 28, no. 1, pp. 6–27, 2014.
- [6] N. Mobilio, I. Casetta, E. Cesnik, and S. Catapano, "Prevalence of self-reported symptoms related to temporomandibular disorders in an Italian population," *Journal of Oral Rehabilitation*, vol. 38, no. 12, pp. 884–890, 2011.
- [7] L. Guarda-Nardini, S. Masiero, and G. Marioni, "Conservative treatment of temporomandibular joint osteoarthritis: intra-articular injection of sodium hyaluronate," *Journal of Oral Rehabilitation*, vol. 32, no. 10, pp. 729–734, 2005.
- [8] R. Thein, B. Haviv, A. Kidron, and S. Bronak, "Intra-articular injection of hyaluronic acid following arthroscopic partial meniscectomy of the knee," *Orthopedics*, vol. 33, no. 10, p. 724, 2010.
- [9] H. Hempfling, "Intra-articular hyaluronic acid after knee arthroscopy: a two-year study," *Knee Surgery, Sports Traumatology, Arthroscopy*, vol. 15, no. 5, pp. 537–546, 2007.
- [10] C. Alpaslan, A. Bilgihan, G. H. Alpaslan, B. Güner, M. Özgür Yis, and D. Erbaş, "Effect of arthrocentesis and sodium hyaluronate injection on nitrite, nitrate, and thiobarbituric acid-reactive substance levels in the synovial fluid," *Oral Surgery, Oral Medicine, Oral Pathology, Oral Radiology, and Endodontology*, vol. 89, no. 6, pp. 686–690, 2000.
- [11] G. Alpaslan and C. Alpaslan, "Efficacy Of TMJ arthrocentesis with and without injection of sodium hyaluronate," *International Journal of Oral and Maxillofacial Surgery*, vol. 26, pp. 613–618, 1997.
- [12] P. Ghosh and D. Guidolin, "Potential mechanism of action intra articular hyaluronan therapy in osteoarthritis are the effects molecular weight dependent?," *Seminars in Arthritis and Rheumatism*, vol. 32, no. 1, pp. 10–37, 2002.
- [13] L. Wei, H. Xiong, B. Li et al., "Change of HA molecular size and boundary lubrication in synovial fluid of patients with temporomandibular disorders," *Journal of Oral Rehabilitation*, vol. 37, no. 4, pp. 271–277, 2010.
- [14] T. E. Clegg, D. Caborn, and C. Mauffrey, "Viscosupplementation with hyaluronic acid in the treatment for cartilage lesions: a review of current evidence and future directions," *European Journal of Orthopaedic Surgery and Traumatology: Orthopédie Traumatologie*, vol. 23, no. 2, pp. 119–124, 2013.
- [15] D. C. Bauer, D. J. Hunter, S. B. Abramson et al., "Classification of osteoarthritis biomarkers: a proposed approach," *Osteoarthritis and Cartilage*, vol. 14, no. 8, pp. 723–727, 2006.
- [16] E. B. Dam, M. Loog, C. Christiansen et al., "Identification of progressors in osteoarthritis by combining biochemical and MRI-based markers," *Arthritis Research and Therapy*, vol. 11, no. 8, p. R115, 2009.
- [17] J. C. Rousseau and P. D. Delmas, "Biological markers in osteoarthritis," *Nature Clinical Practice Rheumatology*, vol. 3, no. 6, pp. 346–356, 2007.

- [18] L. H. Cevidanes, D. Walker, J. Schilling et al., "3D osteoarthritic changes in TMJ condylar morphology correlates with specific systemic and local biomarkers of disease," *Osteoarthritis and Cartilage*, vol. 22, no. 10, pp. 1657–1667, 2014.
- [19] M. C. Goiato, E. V. da Silva, R. A. de Medeiros, K. H. Túrcio, and D. M. Dos Santos, "Are intra-articular injections of hyaluronic acid effective for the treatment of temporomandibular disorders? a systematic review," *International Journal of Oral and Maxillofacial Surgery*, vol. 45, no. 12, pp. 1531–1537, 2016.
- [20] V. Iturriaga, T. Bornhardt, C. Manterola, and P. Brebi, "Effect of hyaluronic acid on the regulation of inflammatory mediators in osteoarthritis of the temporomandibular joint: a systematic review," *International Journal of Oral and Maxillofacial Surgery*, vol. 46, no. 5, pp. 590–595, 2017.
- [21] M. A. Moldez, V. R. Camones, G. E. Ramos, M. Padilla, and R. Enciso, "Effectiveness of intra-articular injections of sodium hyaluronate or corticosteroids for intracapsular temporomandibular disorders: a systematic review and meta-analysis," *Journal of Oral and Facial Pain and Headache*, vol. 32, no. 1, pp. 53–66, 2018.
- [22] M. C. Reid, "Viscosupplementation for osteoarthritis: a primer for primary care physicians," *Advances in Therapy*, vol. 30, no. 11, pp. 967–986, 2013.
- [23] J. Escoda-Francolí, E. Vázquez-Delgado, and C. Gay-Escoda, "Scientific evidence on the usefulness of intraarticular hyaluronic acid injection in the management of temporomandibular dysfunction," *Medicina Oral, Patología Oral y Cirugía Bucal*, vol. 15, no. 4, pp. 644–648, 2010.
- [24] D. Manfredini, F. Piccotti, and L. Guarda-Nardini, "Hyaluronic acid in the treatment of TMJ disorders: a systematic review of the literature," *Cranio*, vol. 28, no. 3, pp. 166–176, 2010.
- [25] L. Guarda-Nardini, A. Rossi, R. Arboretti, S. Bonnini, E. Stellini, and D. Manfredini, "Single- or multiple-session viscosupplementation protocols for temporomandibular joint degenerative disorders: a randomized clinical trial," *Journal of Oral Rehabilitation*, vol. 42, no. 7, pp. 521–528, 2015.
- [26] C. Li, X. Long, M. Deng, J. Li, H. Cai, and Q. Meng, "Osteoarthritic changes after superior and inferior joint space injection of hyaluronic acid for the treatment of temporomandibular joint osteoarthritis with anterior disc displacement without reduction: a cone-beam computed tomographic evaluation," *Journal of Oral and Maxillofacial Surgery*, vol. 73, no. 2, pp. 232–244, 2015.
- [27] S. Dworkin and L. LeResche, "Research diagnostic criteria for temporomandibular disorders: review, criteria, examinations, and specifications, critique," *Journal of Craniomandibular Disorders: Facial and Oral Pain*, vol. 6, no. 4, pp. 301–355, 1992.
- [28] J. T. Farrar, J. P. Young Jr., L. LaMoreaux, J. L. Werth, and R. M. Poole, "Clinical importance of changes in chronic pain intensity measured on an 11-point numerical pain rating scale," *Pain*, vol. 94, no. 2, pp. 149–158, 2001.
- [29] R. Melzack, "The McGill Pain Questionnaire: major properties and scoring methods," *Pain*, vol. 1, no. 3, pp. 277–299, 1975.
- [30] V. R. Aggarwal, M. Lunt, J. M. Zakrzewska, G. J. Macfarlane, and T. V. Macfarlane, "Development and validation of the Manchester orofacial pain disability scale," *Community Dentistry and Oral Epidemiology*, vol. 33, no. 2, pp. 141–149, 2005.
- [31] M. Helkimo, "Studies on function and dysfunction of the masticatory system. 3. Analyses of anamnestic and clinical recordings of dysfunction with the aid of indices," *Svensk Tandlakare Tidskrift*, vol. 67, pp. 165–181, 1974.
- [32] B. Stegenga, L. G. de Bont, R. de Leeuw, and G. Boering, "Assessment of mandibular function impairment associated with temporomandibular joint osteoarthrosis and internal derangement," *Journal of Orofacial Pain*, vol. 7, no. 2, pp. 183–195, 1993.
- [33] G. D. Slade and A. J. Spencer, "Development and evaluation of the oral health impact profile," *Community Dental Health*, vol. 11, no. 1, pp. 3–11, 1994.
- [34] M. Ahmad, L. Hollender, Q. Anderson et al., "Research diagnostic criteria for temporomandibular disorders (RDC/TMD): development of image analysis criteria and examiner reliability for image analysis," *Oral Surgery, Oral Medicine, Oral Pathology, Oral Radiology, and Endodontology*, vol. 107, no. 6, pp. 844–860, 2009.
- [35] S. Murakami, A. Takahashi, H. Nishiyama, M. Fujishita, and H. Fuchihata, "Magnetic resonance evaluation of the temporomandibular joint disc position and configuration," *Dento Maxillo Facial Radiology*, vol. 22, no. 4, pp. 205–207, 1993.
- [36] J. R. Gonçalves, D. S. Cassano, L. Rezende, and L. M. Wolford, "Disc repositioning: does it really work?," *Oral and Maxillofacial Surgery Clinics of North America*, vol. 27, no. 1, pp. 85–107, 2015.
- [37] M. H. Ossipov, G. O. Dussor, and F. Porreca, "Central modulation of pain," *Journal of Clinical Investigation*, vol. 120, no. 11, pp. 3779–3787, 2010.
- [38] D. Manfredini, S. Bonnini, R. Arboretti, and L. Guarda-Nardini, "Temporomandibular joint osteoarthritis: an open label trial of 76 patients treated with arthrocentesis plus hyaluronic acid injections," *International Journal of Oral and Maxillofacial Surgery*, vol. 38, no. 8, pp. 827–834, 2009.
- [39] B. Kooistra, B. Dijkman, T. A. Einhorn, and M. Bhandari, "How to design a good case series," *Journal of Bone and Joint Surgery-Americanm*, vol. 91, no. 3, pp. 21–26, 2009.
- [40] F. M. Abu-Zidan, A. K. Abbas, and A. F. Hefny, "Clinical "case series": a concept analysis," *African Health Sciences*, vol. 12, no. 4, pp. 557–562, 2012.