



Prolongation of the effect of a single dose of rocuronium in a patient with postpolio syndrome under desflurane anesthesia: a case report

Yukifumi Kimura, Yukie Nitta, Makiko Shibuya, Toshiaki Fujisawa

Department of Dental Anesthesiology, Faculty of Dental Medicine and Graduate School of Dental Medicine, Hokkaido University, Sapporo, Japan

Postpolio syndrome (PPS) is widely known to manifest as muscle weakness in patients affected by poliomyelitis in early childhood. This is caused by the long-term overwork of motor nerves regenerated from surviving nerve cells. We report a characteristic delay in recovery from muscle relaxation after administering rocuronium to a patient with PPS under general anesthesia with desflurane. A 59-year-old woman was scheduled to undergo surgical debridement for jaw osteonecrosis. She had a history of poliomyelitis at the age of 2 years, and was diagnosed with PPS at the age of 51 years. General anesthesia was induced with 80 mg propofol, 50 µg fentanyl, and 30 mg (0.69 mg/kg) rocuronium, and maintained with desflurane and remifentanyl. The durations of train-of-four (TOF) count 0 and 1 were 96 and 37 min, respectively. Five minutes after discontinuing desflurane, the TOF count was 4. Three minutes after administering 200 mg sugammadex, the TOF ratio was 0.83, and the tracheal tube was subsequently removed. In summary, the effect of a single dose of rocuronium on twitch in TOF monitoring was significantly prolonged in a patient with PPS, which may have been exacerbated by desflurane.

Keywords: Desflurane; Neuromuscular Monitoring; Postpoliomyelitis Syndrome; Rocuronium.



This is an Open Access article distributed under the terms of the Creative Commons Attribution Non-Commercial License (<http://creativecommons.org/licenses/by-nc/4.0/>) which permits unrestricted non-commercial use, distribution, and reproduction in any medium, provided the original work is properly cited.



INTRODUCTION

Poliomyelitis is an acute infection of the central nervous system caused by poliovirus, which presents as flaccid paralysis on the affected side. In the acute phase, some motor neurons die, causing paralysis of the limbs, trunk (sometimes including the respiratory muscles), and/or the swallowing muscles [1,2]. There are an estimated 10–20 million people worldwide who have previously contracted poliomyelitis, including 60,000–80,000 in Korea [3].

In 2010, 12–20 million patients with poliomyelitis

sequelae were reported [4]. Postpolio syndrome (PPS) is defined as a manifestation of muscle weakness, fatigue, and pain for more than 15 years after a patient develops poliomyelitis in early childhood. Muscles that have recovered their motor ability by recontrolling nerve germination from surviving spinal motor nerves in the acute phase can become weakened again because of nerve exhaustion [1,2]. The known diagnostic criteria for PPS [1] are shown in Table 1.

The prevention of perioperative respiratory failure and aspiration and the interaction between PPS and intraoperative anesthetics and/or muscle relaxants should be considered [5,6]. A previous report documented the

Received: February 10, 2022 • Revised: April 3, 2022 • Accepted: April 5, 2022

Corresponding Author: Yukifumi Kimura, Department of Dental Anesthesiology, Faculty of Dental Medicine and Graduate School of Dental Medicine, Hokkaido University, Kita 13, Nishi 7, Kita-ku, Sapporo, 060-8586, Japan
Tel and Fax: +81-11-706-4336 E-mail: kimura@den.hokudai.ac.jp

Copyright© 2022 Journal of Dental Anesthesia and Pain Medicine

Table 1. Diagnostic criteria for PPS [1]

1. Definite history of paralytic polio
2. Partial or almost complete functional and neurological recovery
3. A period of functional and neurological stability of at least 15 years
4. At least two of the following health problems after the stabilization period
 - unusual fatigue
 - joint pain, muscle pain
 - new muscle weakness on the paralyzed or non-paralyzed side
 - decreased function
 - decreased tolerance to cold
 - new muscle atrophy
5. These problems cannot be explained by medical, orthopedic, or neurological causes.

PPS, postpolio syndrome.

case of a patient with PPS who underwent general anesthesia, in whom a sudden cardiopulmonary arrest occurred 50 min before returning to her room in the ward [7], and postoperative respiratory failure also occurred [8]. However, no previous reports have yet described a comprehensive relationship between the effects of a single dose of a muscle relaxant and those of volatile inhalation anesthetics in patients with PPS. Here, we report a case of delayed recovery from muscle relaxation after the administration of rocuronium in a patient with PPS using neuromuscular monitoring during the maintenance of general anesthesia with desflurane. This is the first report of delayed recovery of twitches with a single dose of rocuronium.

CASE REPORT

Written informed consent was obtained from the patient for publication of this case report and the accompanying images. A 59-year-old woman (height, 136.6 cm; weight, 43.4 kg) diagnosed with medication-related osteonecrosis of the jaw was scheduled to undergo surgical debridement. She had a history of poliomyelitis at the age of 2 years, and was diagnosed with PPS at the age of 51 years. She reported to the hospital in a wheelchair and was able to walk 10–12 m. Preoperative examination revealed restrictive ventilatory impairment (vital capacity: 58.7%) due to paralytic scoliosis. Chest radiography

revealed scoliosis; however, her blood tests, urinalysis, and preoperative vital signs were unremarkable. Before surgical debridement, anesthesia was induced with 80 mg propofol, 50 µg fentanyl, and 30 mg (0.69 mg/kg) rocuronium, and was maintained with desflurane, oxygen, air, and remifentanyl. After inducing anesthesia, the force of contraction of the adductor pollicis muscle was recorded by left ulnar nerve stimulation using a TOF Watch™ (Organon Ireland Limited, Dublin, Ireland). Shortly after administration of rocuronium, the TOF (train-of-four) count was 0/IV (T0), and tracheal intubation was performed. The time course of recovery for the TOF count and TOF ratio is shown in Fig. 1. T0 continued for 96 min after the administration of rocuronium, and T1 (TOF count:1/IV) continued until the end of the surgery (T1:37 min). One minute after stopping desflurane and remifentanyl, the TOF count was 3; 4 min later, it was 4. The TOF ratio is indicated for the first time. Therefore, 200 mg sugammadex was administered intravenously to antagonize the action of rocuronium. Thereafter, the TOF ratios were 0.3, 0.64, and 0.83 every minute, and the tracheal tube was removed. After extubation, the TOF ratio was 0.92, and anesthesia was terminated. The intraoperative body temperature was not remarkable, and anesthesia ended at 36.7°C. No complications due to muscle weakness occurred during the perioperative period. Hyperbaric oxygen therapy was administered 10 times postoperatively to prevent osteonecrosis of the jaw, as scheduled. The patient developed pneumonia on the 14th postoperative day, and treatment was provided for 10 days. She was discharged after completion of hyperbaric oxygen therapy on the 27th postoperative day.

DISCUSSION

In the present case, the patient had muscular weakness, scoliosis, and dysphagia; however, the scheduled treatment was successfully completed without any respiratory complications. However, a characteristic delay

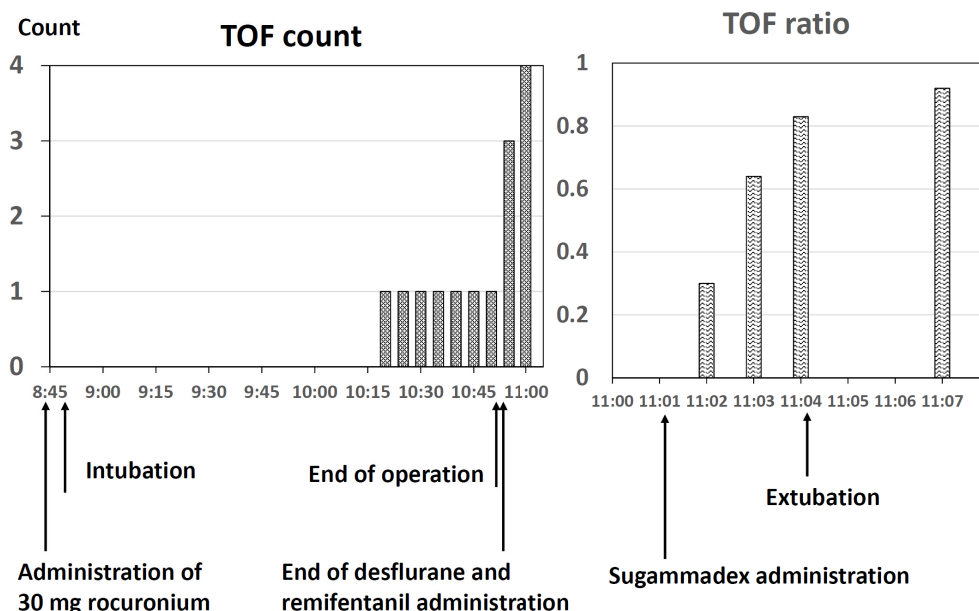


Fig. 1. Recovery from muscle relaxation. The durations of train-of-four (TOF) count 0 and 1 were 96 and 37 min, respectively. Five minutes after discontinuing desflurane, the TOF count was 4. Three min after sugammadex administration, the TOF ratio was 0.83, and the tracheal tube was removed.

in recovery was caused by the use of a non-depolarizing muscle relaxant.

1. Delayed recovery from muscle relaxation caused by rocuronium

1) PPS and recovery from muscle relaxant

In this case, the duration of T0 and T1 in TOF after rocuronium administration to induce anesthesia were extended to 96 and 37 min, respectively.

Compared to a previous report [9] that showed the recovery time of TOF ratio up to 0.7 after a single dose of 0.6 mg/kg rocuronium during desflurane anesthesia in healthy subjects as 69 ± 16 minutes, a significant delay in recovery was observed in the present case. The primary target of poliovirus in paralytic poliomyelitis is the anterior horn cells of the spinal cord. Muscle weakness in PPS is caused by exhaustion and death of nerve axons in the sprouting region (neuromuscular junction) of muscle redomination [2]. In addition, patients with PPS are highly sensitive to non-depolarizing muscle relaxants (tubocurarine and pancuronium) [10]. Therefore, in this case, PPS could have caused a delay in recovery from

muscle relaxation due to rocuronium via the axon of the ulnar nerve or neuromuscular junction connected to the adductor pollicis muscle. In this case, the usual muscle relaxant dose was used. However, Gyermek suggested that muscle relaxant doses should be reduced in patients with PPS [10]. Therefore, it may be more suitable to reduce the dose of muscle relaxants, and dosage should be carefully considered.

In addition, there was no intraoperative hypothermia, and the possibility of prolonged muscle relaxation due to hypothermia was considered to be low.

2) Involvement of desflurane

After discontinuing desflurane and remifentanil at the end of surgery, muscle recovery rapidly accelerated, and T4 appeared within 4 min.

Based on their mechanism of action, opioids can affect analgesia and the respiratory center, but not motor function. The TOF ratio in volunteers anesthetized with 1.67 minimum alveolar concentration desflurane, which is higher than the normal clinical concentration, has been reported to be reduced to 0.84 [11]. Therefore, in this case, desflurane may have promoted the effect of

rocuronium on PPS at the neuromuscular junction.

It is debatable whether the rocuronium-enhancing effect is pronounced only with desflurane, or with other volatile inhalational anesthetics as well. The degree of rocuronium-enhancing effect of volatile inhalational agents has been reported in the following order: desflurane > sevoflurane > isoflurane [12]; however, other reports have indicated their effect to be the same [13]. Regardless, the effect of desflurane is equal to or greater than that of other volatile inhalational anesthetics.

Tanabe et al. [14] reported that sevoflurane anesthesia did not require antagonistic reversal after rocuronium administration in patients with PPS. In addition, Sonobe et al. [15] reported that in a patient with PPS under sevoflurane anesthesia, recovery of twitch was delayed after the administration of rocuronium; however, it was within the limits of normal recovery after the first additional administration, and recovery was delayed after three additional administrations. To the best of our knowledge, this is the first report of an obvious delay in twitch recovery with a single dose of rocuronium. Thus, it can be inferred that there are various patterns of recovery from muscle relaxation in patients with PPS under maintenance anesthesia with volatile inhalation anesthetics.

According to our experience, while administering desflurane anesthesia in patients with PPS, it is necessary to consider the administration of muscle relaxant antagonists after confirming the initiation of recovery from muscle relaxation by continuous monitoring following the administration of rocuronium, and extubation, and the patient must leave the operating room only after confirmation of complete recovery from muscle relaxation.

In summary, the effect of even a single dose of rocuronium, a muscle relaxant, was significantly prolonged during general anesthesia in a patient with PPS, and the deterrence effect of twitch observed by TOF monitoring could have been promoted by desflurane.

AUTHOR ORCID*s*

Yukifumi Kimura: <https://orcid.org/0000-0002-7334-5179>

Yukie Nitta: <https://orcid.org/0000-0003-3177-0246>

Makiko Shibuya: <https://orcid.org/0000-0003-1476-9921>

Toshiaki Fujisawa: <https://orcid.org/0000-0001-8694-232X>

AUTHOR CONTRIBUTIONS

Yukifumi Kimura: Writing - original draft

Yukie Nitta: Writing - review & editing

Makiko Shibuya: Writing - review & editing

Toshiaki Fujisawa: Supervision, Writing - review & editing

ETHICS APPROVAL AND CONSENT TO PARTICIPATE: The patient provided consent to participate.

CONSENT FOR PUBLICATION: Written informed consent was obtained from the patient for the publication of this case report and accompanying images.

COMPETING INTERESTS: There are no conflicts of interest to declare.

ACKNOWLEDGEMENTS: We would like to thank Editage (www.editage.com) for English language editing.

REFERENCES

1. Halstead LS, Rossi CD. Post-polio syndrome: clinical experience with 132 consecutive outpatients. *Birth Defects Orig Artic Ser* 1987; 23: 13-26.
2. Gawne AC, Halstead LS. Post-polio syndrome: pathophysiology and clinical management. *Crit Rev Phys Rehabil Med* 1995; 7: 147-88.
3. Nam KY, Lee S, Yang EJ, Kim K, Jung SH, Jang SN, et al. Falls in Korean polio survivors: incidence, consequences, and risk factors. *J Korean Med Sci* 2016; 31: 301-9.
4. Gonzalez H, Olsson T, Borg K. Management of postpolio syndrome. *Lancet Neurol* 2010; 9: 634-42.
5. Schwartz A, Bosch LM. Anesthetic implications of postpolio syndrome: new concerns for an old disease. *AANA J* 2012; 80: 356-61.
6. Lambert DA, Giannouli E, Schmidt BJ. Postpolio

- syndrome and anesthesia. *Anesthesiology* 2005; 103: 638-44.
7. Magi E, Recine C, Klockenbusch B, Cascianini EA. A postoperative respiratory arrest in a post poliomyelitis patient. *Anaesthesia* 2003; 58: 98-9.
 8. Janda A, Urschütz L. Postoperative respiratory insufficiency in patients after poliomyelitis. *Anaesthesist* 1979; 28: 249.
 9. Kim KS, Yeon JT, Lee HJ. Time course of neuromuscular effects of rocuronium during desflurane anesthesia in patients with or without renal failure. *Korean J Anesthesiol* 2009; 57: 566-71.
 10. Gyermek L. Increased potency of nondepolarizing relaxants after poliomyelitis. *J Clin Pharmacol* 1990; 30: 170-3.
 11. Caldwell JE, Laster MJ, Magorian T, Heier T, Yasuda N, Lynam DP, et al. The neuromuscular effects of desflurane, alone and combined with pancuronium or succinylcholine in humans. *Anesthesiology* 1991; 74: 412-8.
 12. Wulf H, Ledowski T, Linstedt U, Proppe D, Sitzlack D. Neuromuscular blocking effects of rocuronium during desflurane, isoflurane, and sevoflurane anaesthesia. *Can J Anaesth* 1998; 45: 526-32.
 13. Bock M, Klippel K, Nitsche B, Bach A, Martin E, Motsch J. Rocuronium potency and recovery characteristics during steady-state desflurane, sevoflurane, isoflurane or propofol anaesthesia. *Br J Anaesth* 2000; 84: 43-7.
 14. Tanabe K, Takahashi H, Iida H. Safe use of rocuronium for a post-polio syndrome patient. *J Anesth* 2015; 29: 316.
 15. Sonobe S, Imashuku Y, Inamori M, Yabuta K, Hashimura T, Kura M, et al. General anesthesia for a patient with post-polio syndrome. *Masui* 2013; 62: 962-4.