



Published in final edited form as:

*Am J Med Case Rep.* 2020 ; 8(7): 210–215.

## Extrapulmonary Involvement in Sarcoidosis: A Case Report

Courtney Connelly,

Abida Hasan,

Zachary Chung,

Erli Mingomataj,

Vinodkumar Velayudhan,

Isabel M. McFarlane\*

Department of Internal Medicine, State University of New York- Downstate Health Science University, Brooklyn, NY, USA- 11203

### Abstract

Sarcoidosis is an idiopathic multisystem granulomatous disease that affects patients of all races and ethnic groups however predilection for women and African Americans is apparent. Extrapulmonary manifestations of sarcoidosis occur in up to 50% of cases. The most common sites of extrapulmonary involvement are the skin, eyes, liver, and reticuloendothelial system followed by renal, cardiac, and neurological involvement. We present the case of a middle age man with exclusive extrapulmonary sarcoidosis affecting the renal, cardiac, hepatic, splenic and central nervous system. The patient sustained a second episode of venous thromboembolism which highlights a frequently seen complication of sarcoidosis. We discuss the proposed pathophysiology for the prothrombotic state seen in sarcoidosis and imaging modalities that can be utilized to assess extrapulmonary involvement in sarcoidosis. Lastly, sarcoidosis management is reviewed, highlighting that immunosuppressants and tumor necrosis factor inhibitors are being proposed to arrest disease progression and reduce glucocorticoid doses.

### Keywords

sarcoidosis; extrapulmonary manifestations; cardiac sarcoidosis; hepatic sarcoidosis; neuro-sarcoidosis; renal sarcoidosis; venous thromboembolism; arterial aneurysm; stroke; end stage renal disease

## 1. Introduction

Sarcoidosis is an idiopathic multisystem granulomatous disease with varying presentations and an unpredictable clinical course. Affecting people of all racial and ethnic groups, incidence also varies widely throughout the world with apparent predilections towards women and African Americans [1,2,3]. The annual incidence among African Americans

This article is an open access article distributed under the terms and conditions of the Creative Commons Attribution (CC BY) license (<http://creativecommons.org/licenses/by/4.0/>).

\*Corresponding author: Isabel.McFarlane@downstate.edu.

is roughly two to four times that among white individuals with the highest rates found in African American females [1,2,4,5]. The histopathological hallmark of sarcoidosis is the presence of noncaseating granulomas in involved organ systems. The lungs are the most common site of granuloma formation, with up to 97% of patients having intrathoracic involvement. This is often noted incidentally on chest radiography as mediastinal adenopathy, as fewer than half of patients present with respiratory symptoms [6]. The disease course can vary from an acute self-limiting process to chronic disease with progressive organ dysfunction. Pulmonary sarcoidosis is a primary contributor to the morbidity and mortality associated with chronic disease [7]. Extrapulmonary manifestations of sarcoidosis occur in up to 50% of cases and vary on the basis of sex, ethnicity, and age at presentation. The most common sites of extrapulmonary involvement are the skin, eyes, liver, and reticuloendothelial system with rarer renal, cardiac, and neurologic involvement [6,8]. Only 8% of patients present with isolated extrapulmonary disease in the absence of pulmonary involvement with the most common presentation in this group being isolated cutaneous sarcoidosis [8]. The case being presented is a unique manifestation of nonpulmonary sarcoidosis with cardiac, neurologic, renal, splenic and hepatic involvement.

## 2. Case

A 39-year-old African American male presented to the emergency department with shortness of breath and chest tightness of one day duration after missing hemodialysis (HD) two days prior. His past medical history was significant for hypertension, heart failure with an ejection fraction of 23% with diffuse hypokinesis, pulmonary embolism (PE), end stage renal disease (ESRD), and sarcoidosis with cardiac, hepatic, renal, and central nervous system (CNS) involvement (Figure 1, Figure 2).

The patient reported that he was diagnosed with sarcoidosis nine years before by undergoing liver and kidney biopsies at another Institution. At the time of diagnosis, imaging revealed an inoperable 2-millimeter left frontal lobe brain aneurysm. The patient was started on prednisone, methotrexate, and adalimumab. Over the next several years his disease was complicated by worsening hypertension, chronic kidney disease (CKD), and heart failure with a reduced ejection fraction (HFrEF).

The patient suffered from three cerebrovascular accidents (CVA) which occurred 5–8 years after the confirmed diagnosis, resulting in left lower extremity weakness and a tonic-clonic seizure disorder. He had also undergone biliary duct stent placement due to obstruction likely provoked by granuloma expansion. The year prior to presentation, the patient developed *Staphylococcus aureus* bacteremia complicated by sepsis and endocarditis requiring cardiothoracic intervention with the placement of a bioprosthetic heart valve in mitral position. His immunosuppressant medications were stopped at that time. Four months before the current presentation, the patient was admitted for management of hypertensive emergency, a computed tomography (CT) and magnetic resonance angiography (MRA) of the head revealed high T2 and prominent brainstem signaling, suspicious for neuro-sarcoidosis (Figure 3). Additionally, the imaging noted a partially empty sella and left ophthalmic artery aneurysm (Figure 4). During the following months, the patient

commenced regular HD sessions due worsening of his renal disease. He was also started on azathioprine for management of his sarcoidosis.

Upon arrival to the emergency department, the patient's temperature was 97.8 degrees Fahrenheit, blood pressure 185/106, heart rate 61 beats per minute, respiratory rate 18 breaths per minute, and oxygen saturation 100% on ambient air. The patient appeared uncomfortable lying in bed without increased work of breathing or use of accessory muscles. Cardiac, respiratory, abdominal, and extremity exams were unremarkable. During the interview, the patient reported being noncompliant with all of his medications including his immunosuppressors and those for his chronic medical conditions.

Given the underlying diagnosis, the patient received a CT angiography of the pulmonary artery, which elucidated an acute PE to the left lower lobe, branching to the anterior medial and posterior lateral basilar segments. Laboratory test results obtained on admission are shown in Table 1. He was admitted to the medicine service for management of a sub-massive PE and started on warfarin with a heparin bridge of 1000 units/hour. On hospital day 2, the patient was found to be fluid overloaded likely due to an acute exacerbation of his HFrEF, radiocontrast received and previously missed HD. He was emergently dialyzed, placed on a 1 liter per day fluid restriction, and started on isosorbide mononitrate 60 mg daily and carvedilol 12.5 mg bidaily. For management of his hypertensive emergency, he started clonidine 0.1 mg bidaily and hydralazine 50 mg tridaily. He was continued on phenytoin 50 mg bidaily and levetiracetam 750 mg bidaily for management of his seizure disorder.

The patient continued his regularly scheduled HD. During HD on the fifth day of hospitalization, he became hypertensive to 175/120 and acutely dyspneic with decreased mentation. He was intubated for airway protection and placed on mechanical ventilation for two days while being cared in the intensive care unit. This event of dyspnea was likely due to acute pulmonary edema and managed accordingly. After successful extubation, the patient's international normalized ratio (INR) stabilized to 2.4 and he was discharged on warfarin 5 mg daily. The patient was lost to follow up.

### 3. Discussion

Although noncaseating granulomas are a histopathological hallmark of sarcoidosis, they are nonspecific for the disease and not always required for diagnosis. Sarcoidosis is largely a diagnosis of exclusion. It is important to first eliminate other identifiable causes of similar presentations or granulomatous inflammation including infections, malignancy, vasculitis, and hypersensitivity-induced lung disorders. Sarcoidosis is frequently asymptomatic, and thus a high level of suspicion is required which prolongs time until biopsy and/or diagnosis. Diagnostic delay is emphasized by this patient's presentation. At the time of our patient's sarcoidosis diagnosis, he already had significant disease burden with renal, hepatic, and CNS involvement.

A considerable percentage of patients are diagnosed after mediastinal lymphadenopathy is incidentally discovered on chest radiography. Over 90% of patients have pulmonary

involvement upon diagnosis [8]. The most common clinical manifestations are pulmonary in nature and include dry cough, dyspnea, and chest pain. Constitutional symptoms, such as fever, unintentional weight loss, and fatigue, are also seen in about one-third of patients. Extent of pulmonary involvement has been shown to correlate indirectly with the rate of spontaneous disease resolution [3]. Spontaneous remissions occur in nearly two-thirds of patients. Unfortunately, 10–30% of patients, such as the one being discussed, have a chronic or progressive clinical course [9]. This patient uniquely has had isolated extrapulmonary involvement throughout the course of his disease.

It is estimated that 5–15% of patients with sarcoidosis have neurologic involvement. The actual prevalence of neurosarcoidosis is likely higher due to subclinical disease and nonspecific CNS signs and symptoms [10]. The most common CNS manifestations of sarcoidosis are cranial nerve-palsies, but sarcoidosis can affect any part of the nervous system leading to basilar meningitis, seizures, neuroendocrine dysfunction, parenchymal brain lesions, peripheral neuropathy, and cognitive and behavioral problems [10]. This patient's magnetic resonance imaging (MRI) showing basilar meningitis is consistent with the diagnosis of neuro-sarcoidosis. Additionally, his magnetic resonance angiogram (MRA) depicted a left ophthalmic artery aneurysm (Figure 4). In association with more common brainstem involvement in neuro-sarcoidosis, cerebrovascular involvement has been reported previously as a rare disease manifestation and confers an increased risk for brain hemorrhage and resultant complications.

The patient presented to this visit with an established history of extrapulmonary sarcoidosis, PE, and CVA. Upon initial clinical assessment, his shortness of breath and chest tightness were consistent with a congestive heart failure (CHF) exacerbation secondary to missing HD. The patient appeared to be in moderate distress even with an oxygen saturation of 100% on room air. Thus, the concern for PE could not be overlooked. Sarcoidosis has repeatedly been associated with increased risk for venous thromboembolic events (VTEs) [11,12,13]. This is likely due to a growing collection of evidence that chronic inflammation, like that seen in autoimmune diseases, may be an independent risk factor for developing VTE [14,15]. VTEs usually occur in the setting of Virchow's triad, which describes endothelial dysfunction, hemodynamic stasis, and hypercoagulability as being important contributors to thromboses and also notable consequences of chronic inflammation. Upon presentation, this patient had multiple comorbid conditions outside of his extrapulmonary sarcoidosis that increased his risk of VTE. These comorbidities, such as HTN, HFrEF, and ESRD, were likely consequences of his chronic and progressive sarcoidosis with renal and cardiac involvement. The role of active inflammation contributing to a hypercoagulable state is being increasingly recognized as an important process involved in thrombus formation and raises the importance of further elucidating the mechanism of hypercoagulability in sarcoidosis [14].

The heavy disease burden upon this patient's presentation raises the question of when during disease progression a patient's hypercoagulability becomes clinically apparent. This patient's hypercoagulable state has played a major role in clinical presentation throughout his disease course considering he already had history of PE and multiple CVAs. Previous case reports have proposed that the inflammation caused by sarcoidosis increases

coagulability prior to clinical manifestations of the disease, and thus prior to diagnosis [13]. Thus, it is likely that this patient had increased coagulability even prior to diagnosis of sarcoidosis. This is an important point to consider as he did not have typical signs and symptoms of sarcoidosis, such as respiratory dysfunction or skin manifestations. With an atypical presentation such as this one, it is important to have sarcoidosis on the list of differentials as diagnosing the disease earlier may help to prevent sequelae and improve a patient's quality of life.

The prognosis of sarcoidosis is variable and difficult to predict in individual patients. The multicenter ACCESS (A Case Controlled Etiologic Study of Sarcoidosis) study was unable to elucidate any specific risk factors as a dominant influencer of disease [16]. It did though suggest African Americans being more likely to develop new organ involvement with sarcoidosis compared to Caucasians, consistent with other studies supporting a greater extent of extra-thoracic involvement in African Americans compared to Caucasians [16,17]. Additionally, the ACCESS study found an association between low socioeconomic status and increased organ involvement, suggesting that socioeconomic factors play a role in clinical progression and outcome of sarcoidosis [16]. Being an African American patient of low socioeconomic status with CHF and ESRD, the patient in this case is another example that such factors may influence disease progression and extent.

### 3.1. Imaging Modalities for Selected Organ Involvement

Sarcoidosis may produce different imaging findings depending on the imaging modality used and the type of organ affected. Imaging features are non-specific and confirmation of diagnosis may necessitate biopsy when plausible.

**Cardiac Sarcoidosis**—Cardiac Involvement can affect up to a quarter of the sarcoid patients however, only 5% of the cases have clinically significant cardiac disease [18].

It should be noted that up to 40% sarcoidosis patients are asymptomatic despite the indicative imaging findings encountered [19]. Electrocardiogram findings include atrioventricular or bundle branch blocks [20,21,22]. Echocardiogram may show an array of abnormalities from wall motion defects and thinning of the ventricular wall and interventricular septum to heart failure with reduced ejection fraction and ventricular aneurysms. None of which are non-specific for cardiac sarcoidosis [21].

In terms of MR imaging, cardiac sarcoidosis is usually associated with patchy and multifocal late gadolinium enhancement in the septum and lateral wall, more commonly involving the basal segments of the heart; and, in contrast to some other etiologies, tends to affect the mid- and epicardium but spares the sub-endocardium [20,23,24,25].

Fluorodeoxyglucose F 18 positron emission tomography (<sup>18</sup>F-FDG PET) has been endorsed by the Society of Nuclear Medicine and Molecular Imaging (SNMMI) and American Society of Nuclear Cardiology (ASNC) in detection and assessment of treatment in cardiac sarcoidosis [26].

Focal <sup>18</sup>F-FDG uptake with or without perfusion defects on resting images are suggestive active inflammatory sarcoidosis. Fused PET/MR imaging may also be useful as well considering MR imaging is more sensitive for scarring, while PET may be helpful for identification of the early inflammatory stage without scarring. However, the diagnostic accuracy can vary based on report and drugs/dietary conditions prior to study [27,28,29].

**Neurosarcoidosis**—Between 5%–15% of the sarcoid patients have central nervous system (CNS) involvement which usually is seen as part of multi-organ involvement [5]. Only 1% of the cases present with exclusive CNS sarcoid [30]. Active CNS sarcoidosis lesions commonly show enhancement and/or diffuse or nodular thickening of the areas involved on MRI with gadolinium [31]. Cranial nerve involvement has been described as abnormal enlargement and enhancement on MR imaging [27]. Leptomeningeal disease may be seen in up to 30% of the patients as diffuse or small nodular lesion that tend to coalesce over time, resulting in intra-axial masses with surrounding edema [31]. On MRI, sarcoid granulomas lesions may appear as T1 isointense or T2 hypointense and may show marked enhancement [32]. With involvement of the cerebral white matter, cerebellum, and brainstem, T2-hyperintense and T1-hypointense periventricular white matter lesions can be appreciated [33]. Spinal cord involvement may show a wide spectrum of MRI findings from enhancement to enlargement to atrophy depending on the region involved [32].

Cerebrovascular involvement can lead to transient ischemic attacks, strokes, sometimes even intracranial hemorrhage [27]. The role of PET/CT may be useful in neurosarcoidosis but results from larger cohorts of data are necessary before its use can be considered standard of care in clinical practice [27].

**Abdominal Involvement**—Any intra-abdominal organ can be involved in sarcoidosis being the liver affected in up to 80% of the patients [34,35]. Ultrasound (US), computerized tomography (CT), and MR imaging are the most common modalities used to assess the extent of hepatic sarcoidosis which may reveal hepatomegaly, heterogeneous liver parenchyma, increased liver echogenicity, and innumerable small hypoechoic lesions [36,37]. CT and MR modalities allow the identification of heterogeneous hypointense nodules, that measure a few millimeters, at first, but then tend to coalesce into larger lesions [35,36,38]. On MRI, granulomas in the portal tracts can be seen as increased signal intensity on T2-weighted imaging; however, the typical “halo sign” of biliary cirrhosis can also be seen in hepatic sarcoidosis (T2-hypointense zones surrounding portal triads) [37]. Splenic sarcoidosis can manifest as nodules, similar to the hepatic ones although tend to be larger, and appear as hypoechoic on US images, hypointense on CT images and appear hypointense on T1 and T2-weighted MR imaging [35,36,38]. Pancreatic involvement is rare and imaging findings are non-specific and indistinguishable from pancreatitis or pancreatic carcinoma [39]. Gastric involvement is manifested by nodular mucosa, thick gastric folds, polypoid filling defects on barium swallow and abnormal heterogenous thickening and enhancement on MRI [27,35]. Small bowel and colon involvement may also be seen as coarse granular filling defects, mass-like lesions, or circumferential narrowing of the bowel lumen [27]. Renal involvement in sarcoidosis can present as hypovascular lesions on CT images and cause a wide range of enhancement patterns ranging from speckled or

striated to mass like areas [27]. The testes and epididymis may also be affected and US studies may show multiple unilateral or bilateral hypoechoic lesions [27]. Clinicians should exclude lymphoma, leukemia, metastases, and other granulomatous disease when working up testicular lesions on a known sarcoidosis patient [27].

### 3.2. Sarcoidosis Management

Corticosteroids (e.g. prednisone) remain the first line of treatment although specific doses and tapers remain controversial [40]. Second line therapies such as immunomodulating therapy with hydroxychloroquine, methotrexate, azathioprine, mycophenolate mofetil, leflunomide, and cyclophosphamide are occasionally used as corticosteroid sparing therapies to lower the risk of adverse events associated with long term steroid use [41]. Recently, a retrospective multicenter study conducted from June 2014-June 2015 analyzed the records of 132 patients, 122 of whom had cases of severe sarcoidosis refractory to 1<sup>st</sup> and 2<sup>nd</sup> line treatments with corticosteroids and 1 immunosuppressive drug and demonstrated significant clinical improvement for those with extrapulmonary manifestations of sarcoidosis as well as a modest reduction in the concurrent mean daily prednisone dosage with anti-TNF therapy [42]. It should be noted, however, that 52% of patients in this study experienced adverse events while on anti-TNF therapy, the most common being infection with some subjects requiring hospitalization or treatment interruption; allergic reactions, paradoxical granulomatous reactions, antibody development against anti-TNF, demyelinating lesions, and serum sickness reactions were among some of the minority of other adverse events reported [42].

## 4. Conclusion

Sarcoidosis can affect adult patients of various racial backgrounds typically presenting with respiratory symptoms. Mediastinal adenopathy and pulmonary involvement are commonly encountered however extra-pulmonary sarcoidosis are also reported in up to 50% of the cases. Diagnosis is confirmed by pathologic demonstration of noncaseating granulomas and extent of the disease can be ascertained by tissue diagnosis and imaging modalities. Neurological, cardiac, renal and liver involvement carry an increased morbidity and mortality with data suggesting that African American tend to suffer a more aggressive disease than Caucasians. The elevated risk of VTE in sarcoidosis is also another relevant feature that clinicians should keep in mind as chronic anticoagulation might mitigate VTE risk.

## Acknowledgements

This work is supported, in part, by the efforts of Dr. Moro O. Salifu M.D., M.P.H., M.B.A., M.A.C.P., Professor and Chairman of Medicine through NIH Grant No. S21MD012474.

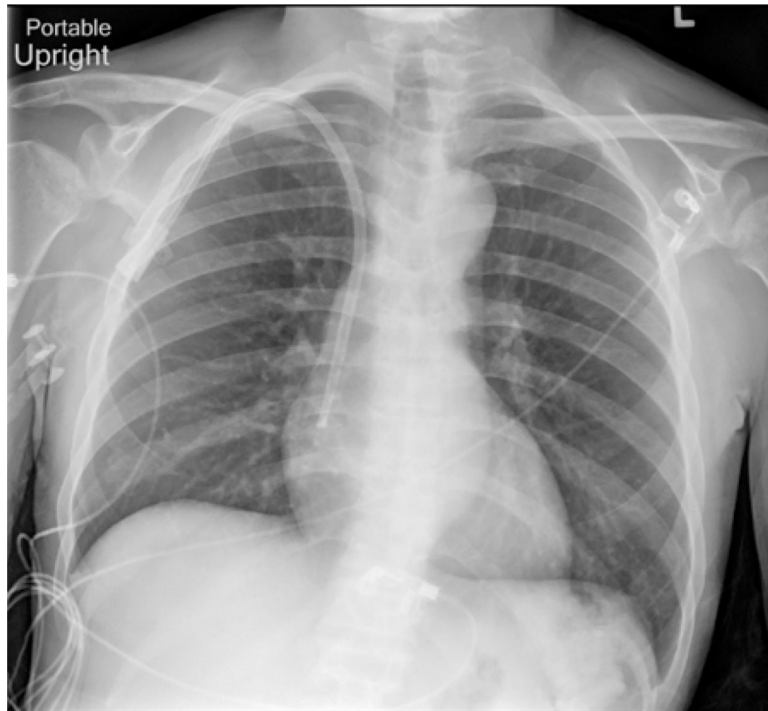
## References

- [1]. Iannuzzi MC, Rybicki BA, and Teirstein AS, Sarcoidosis. *N Engl J Med*, 2007. 357(21): p. 2153–65. [PubMed: 18032765]
- [2]. Rybicki BA, et al. , Racial differences in sarcoidosis incidence: a 5-year study in a health maintenance organization. *Am J Epidemiol*, 1997. 145(3): p. 234–41. [PubMed: 9012596]

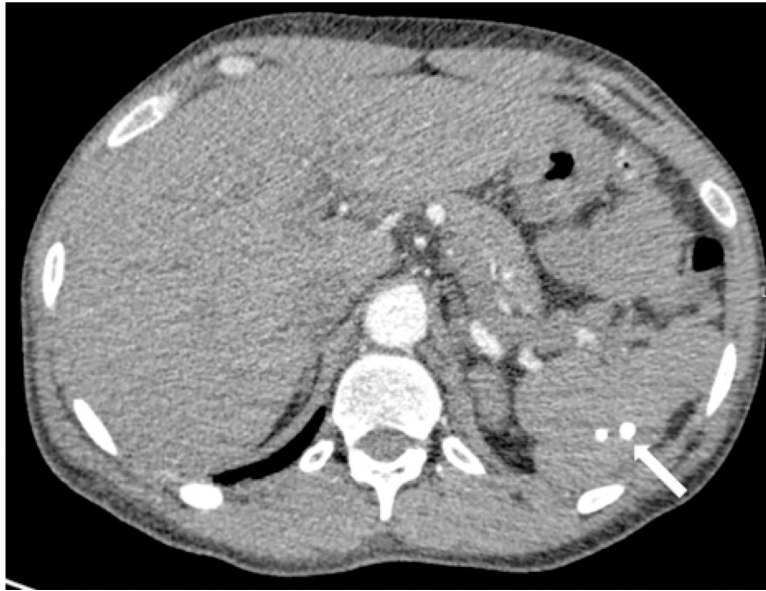- [3]. Ungprasert P, Crowson CS, and Matteson EL, Epidemiology and clinical characteristics of sarcoidosis: an update from a population-based cohort study from Olmsted County, Minnesota. *Reumatismo*, 2017. 69(1): p. 16–22. [PubMed: 28535617]
- [4]. Arkema EV and Cozier YC, Epidemiology of sarcoidosis: current findings and future directions. *Ther Adv Chronic Dis*, 2018. 9(11): p. 227–240. [PubMed: 30364496]
- [5]. Baughman RP, et al. , Sarcoidosis in America. Analysis Based on Health Care Use. *Ann Am Thorac Soc*, 2016. 13(8): p. 1244–52. [PubMed: 27509154]
- [6]. Carmona EM, Kalra S, and Ryu JH, Pulmonary Sarcoidosis: Diagnosis and Treatment. *Mayo Clin Proc*, 2016. 91(7): p. 946–54. [PubMed: 27378039]
- [7]. Gerke AK, Morbidity and mortality in sarcoidosis. *Curr Opin Pulm Med*, 2014. 20(5): p. 472–8. [PubMed: 25029298]
- [8]. James WE, et al. , Clinical Features of Extrapulmonary Sarcoidosis Without Lung Involvement. *Chest*, 2018. 154(2): p. 349–356. [PubMed: 29453944]
- [9]. Soto-Gomez N, Peters JI, and Nambiar AM, Diagnosis and Management of Sarcoidosis. *Am Fam Physician*, 2016. 93(10): p. 840–8. [PubMed: 27175719]
- [10]. Terushkin V, et al. , Neurosarcoidosis: presentations and management. *Neurologist*, 2010. 16(1): p. 2–15. [PubMed: 20065791]
- [11]. Ungprasert P, Crowson CS, and Matteson EL, Association of Sarcoidosis With Increased Risk of VTE: A Population-Based Study, 1976 to 2013. *Chest*, 2017. 151(2): p. 425–430. [PubMed: 27687848]
- [12]. Ungprasert P, et al. , Sarcoidosis and risk of venous thromboembolism: A systematic review and meta-analysis. *Sarcoidosis Vasc Diffuse Lung Dis*, 2015. 32(3): p. 182–7. [PubMed: 26422561]
- [13]. Yaqoob ZJ, Al-Kindi SG, and Zein JG, Sarcoidosis and Risk of VTE: Validation With Big Data. *Chest*, 2017. 151(6): p. 1398–1399. [PubMed: 28599933]
- [14]. Lee JJ and Pope JE, A meta-analysis of the risk of venous thromboembolism in inflammatory rheumatic diseases. *Arthritis Res Ther*, 2014. 16(5): p. 435. [PubMed: 25253302]
- [15]. Ramagopalan SV, et al. , Risk of venous thromboembolism in people admitted to hospital with selected immune-mediated diseases: record-linkage study. *BMC Med*, 2011. 9: p. 1. [PubMed: 21219637]
- [16]. Judson MA, et al. , Two year prognosis of sarcoidosis: the ACCESS experience. *Sarcoidosis Vasc Diffuse Lung Dis*, 2003. 20(3): p. 204–11. [PubMed: 14620163]
- [17]. Johns CJ, et al. , Longitudinal study of chronic sarcoidosis with low-dose maintenance corticosteroid therapy. Outcome and complications. *Ann N Y Acad Sci*, 1986. 465: p. 702–12. [PubMed: 3460404]
- [18]. Birnie DH, et al. , HRS expert consensus statement on the diagnosis and management of arrhythmias associated with cardiac sarcoidosis. *Heart Rhythm*, 2014. 11(7): p. 1305–23. [PubMed: 24819193]
- [19]. Ipek E, et al. , Sarcoidosis and the heart: A review of the literature. *Intractable Rare Dis Res*, 2015. 4(4): p. 170–80. [PubMed: 26668777]
- [20]. Nagai T, et al. , Incidence and prognostic significance of myocardial late gadolinium enhancement in patients with sarcoidosis without cardiac manifestation. *Chest*, 2014. 146(4): p. 1064–1072. [PubMed: 24853830]
- [21]. Mehta D, et al. , Cardiac involvement in patients with sarcoidosis: diagnostic and prognostic value of outpatient testing. *Chest*, 2008. 133(6): p. 1426–1435. [PubMed: 18339784]
- [22]. Nery PB, et al. , Prevalence of cardiac sarcoidosis in patients presenting with monomorphic ventricular tachycardia. *Pacing Clin Electrophysiol*, 2014. 37(3): p. 364–74. [PubMed: 24102263]
- [23]. Cummings KW, et al. , A pattern-based approach to assessment of delayed enhancement in nonischemic cardiomyopathy at MR imaging. *Radiographics*, 2009. 29(1): p. 89–103. [PubMed: 19168838]
- [24]. Ichinose A, et al. , MRI of cardiac sarcoidosis: basal and subepicardial localization of myocardial lesions and their effect on left ventricular function. *AJR Am J Roentgenol*, 2008. 191(3): p. 862–9. [PubMed: 18716120]



- [25]. Vogel-Claussen J, et al. , Delayed enhancement MR imaging: utility in myocardial assessment. *Radiographics*, 2006. 26(3): p. 795–810. [PubMed: 16702455]
- [26]. Chareonthitawee P, et al. , Joint SNMMI-ASNC Expert Consensus Document on the Role of (18)F-FDG PET/CT in Cardiac Sarcoid Detection and Therapy Monitoring. *J Nucl Med*, 2017. 58(8): p. 1341–1353. [PubMed: 28765228]
- [27]. Ganeshan D, et al. , Sarcoidosis from Head to Toe: What the Radiologist Needs to Know. *Radiographics*, 2018. 38(4): p. 1180–1200. [PubMed: 29995619]
- [28]. Blankstein R, et al. , Cardiac positron emission tomography enhances prognostic assessments of patients with suspected cardiac sarcoidosis. *J Am Coll Cardiol*, 2014. 63(4): p. 329–36. [PubMed: 24140661]
- [29]. Mc Ardle BA, et al. , The role of F(18)-fluorodeoxyglucose positron emission tomography in guiding diagnosis and management in patients with known or suspected cardiac sarcoidosis. *J Nucl Cardiol*, 2013. 20(2): p. 297–306. [PubMed: 23288545]
- [30]. Iwai K, et al. , Pathological studies on sarcoidosis autopsy. I. Epidemiological features of 320 cases in Japan. *Acta Pathol Jpn*, 1993. 43(7–8): p. 372–6. [PubMed: 8372682]
- [31]. Shah R, Roberson GH, and Cure JK, Correlation of MR imaging findings and clinical manifestations in neurosarcoidosis. *AJNR Am J Neuroradiol*, 2009. 30(5): p. 953–61. [PubMed: 19193748]
- [32]. Smith JK, Matheus MG, and Castillo M, Imaging manifestations of neurosarcoidosis. *AJR Am J Roentgenol*, 2004. 182(2): p. 289–95. [PubMed: 14736648]
- [33]. Zajicek JP, et al. , Central nervous system sarcoidosis--diagnosis and management. *QJM*, 1999. 92(2): p. 103–17. [PubMed: 10209662]
- [34]. Koyama T, et al. , Radiologic manifestations of sarcoidosis in various organs. *Radiographics*, 2004. 24(1): p. 87–104. [PubMed: 14730039]
- [35]. Warshauer DM and Lee JK, Imaging manifestations of abdominal sarcoidosis. *AJR Am J Roentgenol*, 2004. 182(1): p. 15–28. [PubMed: 14684507]
- [36]. Britt AR, et al. , Sarcoidosis: abdominal manifestations at CT. *Radiology*, 1991. 178(1): p. 91–4. [PubMed: 1984330]
- [37]. Kessler A MDG, Israel HL, Goldberg BB, Hepatic and Splenic Sarcoidosis: Ultrasound and MR Imaging. *Abdom Imaging*, 1993. 18(2): p. 159–163. [PubMed: 8439757]
- [38]. Folz SJ, Johnson CD, and Swensen SJ, Abdominal manifestations of sarcoidosis in CT studies. *J Comput Assist Tomogr*, 1995. 19(4): p. 573–9. [PubMed: 7622687]
- [39]. Kim JS, et al. , Cardiac sarcoidosis. *Am Heart J*, 2009. 157(1): p. 9–21. [PubMed: 19081391]
- [40]. Judson MA, Advances in the diagnosis and treatment of sarcoidosis. *F1000Prime Rep*, 2014. 6: p. 89. [PubMed: 25374667]
- [41]. Prasse A, The Diagnosis, Differential Diagnosis, and Treatment of Sarcoidosis. *Dtsch Arztebl Int*, 2016. 113(33–34): p. 565–74. [PubMed: 27598883]
- [42]. Jamilloux Y, et al. , Efficacy and safety of tumor necrosis factor antagonists in refractory sarcoidosis: A multicenter study of 132 patients. *Semin Arthritis Rheum*, 2017. 47(2): p. 288–294. [PubMed: 28392046]



**Figure 1.** Portable AP view of the chest demonstrates clear lungs with no evidence of hilar adenopathy. Right internal jugular dialysis catheter is seen in place



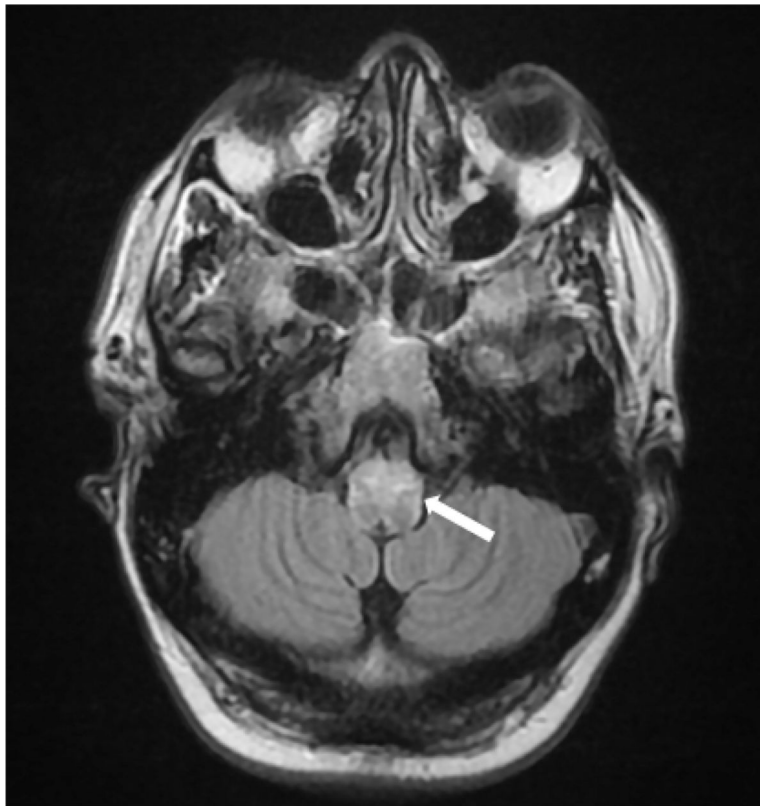
**Figure 2.** Axial CT with contrast demonstrates calcified granulomas in the spleen consistent with known sarcoidosis

Author Manuscript

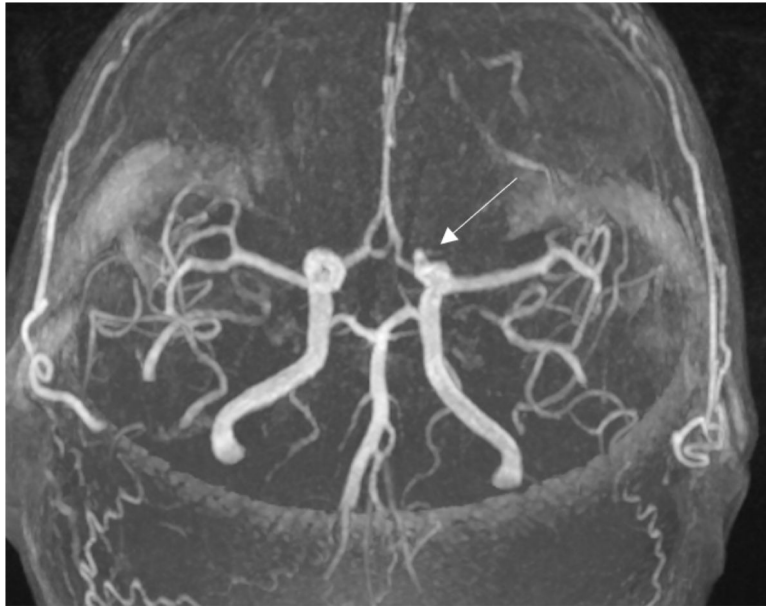
Author Manuscript

Author Manuscript

Author Manuscript



**Figure 3.** Axial FLAIR image demonstrates abnormal signal involving the ventral aspect of the medulla (arrow). Sarcoid classically results in basilar meningitis, which may affect cranial nerves and the brainstem



**Figure 4.**  
3D MRA Image demonstrates a 3mm aneurysm at the origin of the left ophthalmic artery

Author Manuscript

Author Manuscript

Author Manuscript

Author Manuscript

**Table 1.**

Laboratory Data

Serum	Patient	Reference Range
WBC (K/uL)	8.22	4.5–10.9
RBC (M/uL)	3.53	4.2–5.4
Hemoglobin (g/dL)	10.9	12.0–16.0
Hematocrit (%)	32.0	37.0–47.0
Platelets (K/uL)	250	130–400
Sodium (mmol/L)	137	136–146
Potassium (mmol/L)	4.1	3.5–5.0
Chloride (mmol/L)	99	98–106
BUN (mg/dL)	36	6–20
Creatinine (mg/dL)	5.56	0.4–1.2
Calcium (mg/dL)	8.9	8.4–10.3
Total Protein (g/dL)	8.2	6.0–8.5
Albumin (g/dL)	3.95	2.8–5.7
AST (U/L)	26	10–35
ALT (U/L)	28	0–31
Alk Phos (U/L)	311	25–125
Total Bilirubin	0.40	0.0–1.2
Glucose (mg/dL)	106	70–99
Lactate (mmol/L)	3.60	0.5–2.2
Brain Natriuretic Peptide (pg/ml)	461	< 64
Troponin I (ng/mL)	< 0.02	0.15
Cardiolipin Ig G Ab (GPL)	< 14	0–14
Cardiolipin IgM Ab (MPL)	< 12	0–12
Activated partial thromboplastin time (s)	48.1	30.0–40.0
Prothrombin time (s)	29.7	11.0–13.5
International Normalized Ratio	2.4	0.8–1.1

Author Manuscript

Author Manuscript

Author Manuscript

Author Manuscript