

Correspondence ▼

***Rickettsia parkeri* spotted fever and toxicosis by *Ornithodoros*: other tick bite-related entities to be known by dermatologists**

Stefan Vilges de Oliveira¹
 Álvaro A. Faccini-Martínez²

DOI: <http://dx.doi.org/10.1590/abd1806-4841.20198389>

Dear editor,

We have read with great interest the recent review written by Haddad *et al.* (2018), regarding skin manifestations caused by tick bites, published in *Anais Brasileiros de Dermatologia*, in which the authors propose a clinical classification of these manifestations considering “primary lesions” (PL) and “secondary lesions” (SL).¹ To their list, we would like to suggest the inclusion of two other emerging clinical entities, still little known to health professionals in Brazil: *Rickettsia parkeri* spotted fever (RPSF) as a SL and toxicosis by *Ornithodoros* as a PL.

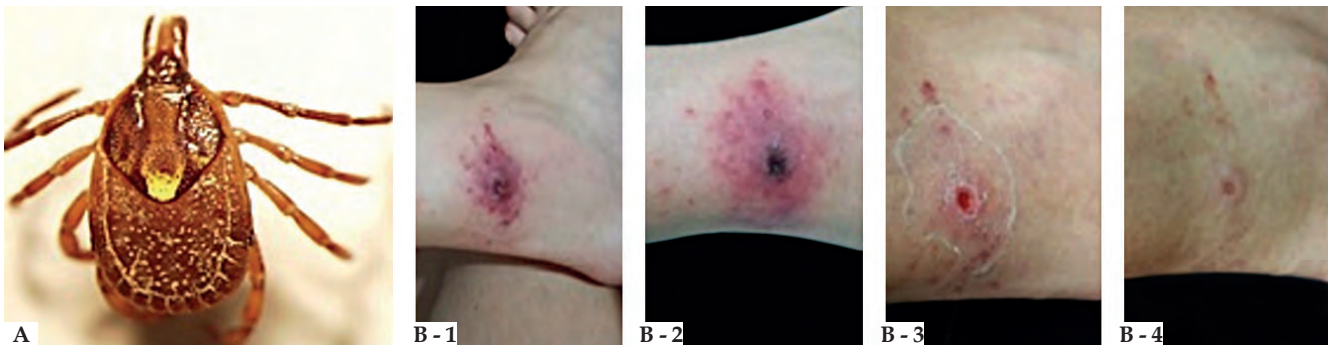


FIGURE 1: A - A female of *Amblyomma ovale* (Source: Álvaro A. Faccini-Martínez). B - Inoculation eschar in a patient with spotted fever caused by *Rickettsia parkeri* strain Atlantic rainforest. (B - 1) 12 days after the tick bite (DATB). (B - 2) 14 DATB. (B - 3) 23 DATB. (B - 4) 30 DATB (Source: Krawczak, *et al.*, 2016³)

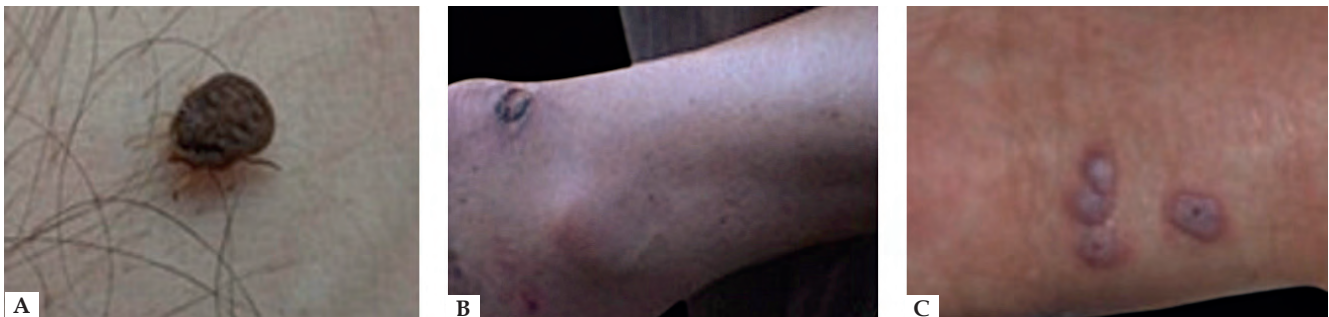

FIGURE 2: A - A female of *Ornithodoros rietcorraei* associated to human parasitism and toxicosis, collected in residences in the urban area of Russas, State of Ceará (Source: Stefan Vilges de Oliveira). B - Skin lesion (heel) by *Ornithodoros brasiliensis* bite, State of Rio Grande do Sul (Source: José Reck Jr., *et al.*, 2013⁷) C - Bullous lesion on the wrist caused by *O. mimon* bite, State of Minas Gerais (Source: Labruna, *et al.*, 2014⁸; by permission of Oxford University Press journal)

Received 24 April 2018.

Accepted 26 July 2018.

* Work performed at the Department of Collective Health, Faculdade de Medicina, Universidade Federal de Uberlândia (MG), Brazil; Health Sciences Center, Universidade Federal do Espírito Santo, Vitória (ES), Brazil.

Financial support: None.

Conflict of interest: None.

¹ Department of Collective Health, Faculdade de Medicina, Universidade Federal de Uberlândia (MG), Brazil.

² Postgraduate Program in Infectious Diseases, Health Science Center, Universidade Federal do Espírito Santo, Vitória (ES), Brazil.

MAILING ADDRESS:

Stefan Vilges de Oliveira

E-mail: stefanbio@yahoo.com.br

©2019 by Anais Brasileiros de Dermatologia



RPSF occurs predominantly in Atlantic rainforest areas of South, Southeast, and Northeast Brazilian regions. *R. parkeri* strain Atlantic rainforest is the causative agent of this condition, which is transmitted to humans by *Amblyomma ovale* ticks. (Figure 1A).² Clinical manifestations of *R. parkeri* infection tend to be less severe than *R. rickettsii* rickettsiosis, associated with fever, inoculation eschar, rash, lymphadenopathy, malaise, headache, myalgia, and arthralgia.² Inoculation eschar (main sign) is defined as a painless ulcer lesion with a crusty-necrotic center and a surrounding erythematous halo, measuring 0.5 - 2 cm in diameter, which indicates the site of the tick bite (Figure 1B).^{2,3} Doxycycline is the drug of choice for all suspected spotted fever cases, regardless of age group and disease severity.²

Ornithodoros ticks, in turn, is a genus in the soft-bodied tick family (Argasidae) that has gained medical importance for their ca-

capacity to cause toxicosis,⁴ or for being borreliosis (relapsing fever) vectors.⁵ These ticks are natural parasites of mammals (mainly rodents) and birds living in caves, tree hollows, nests, and attics of houses. Ticks become infected when they feed on animals (primary hosts) that carry the bacterium in their blood. The disease is transmitted to humans by the bite of infected ticks.⁶ In Brazil, toxicosis in humans has been reported in the states of Rio Grande do Sul, Minas Gerais, Goiás, Pernambuco, Rio Grande do Norte, and Ceará, with *Ornithodoros brasiliensis*, *O. mimon*, and *O. rietcorrei* as the related tick species (Figure 2A).⁷⁻⁹ The most common clinical manifestations included local pruritus, edema and erythema, blister lesions, and systemic involvement (transient fever, dyspnea, and malaise) (Figure 2B- C).^{4,7} Topical or systemic corticosteroids and antihistamines may be used as treatment options.⁴


Both clinical entities presented here should be considered in the medical evaluation of tick bite-associated lesions. In such cases, dermatologists may contribute to the diagnosis of these diseases. □

REFERENCES

- Haddad V Jr, Haddad MR, Santos M, Cardoso JLC. Skin manifestations of tick bites in humans. *An Bras Dermatol*. 2018;93:251-5.
- Faccini-Martínez AA, de Oliveira SV, Cerutti Junior C, Labruna MB. Febre maculosa por *Rickettsia parkeri* no Brasil: Conduas de vigilância epidemiológica, diagnóstico e tratamento. *J. Health Biol Sci*. 2018;6:299-312
- Krawczak FS, Muñoz-Leal S, Guztzaky AC, Oliveira SV, Santos FC, Angerami RN, et al. *Rickettsia* sp. strain Atlantic rainforest infection in a patient from a spotted fever-endemic area in Southern Brazil. *Am J Trop Med Hyg*. 2016;95:551-3.
- McGinley-Smith DE, Tsao SS. Dermatoses from ticks. *J Am Acad Dermatol*. 2003;49:363-92.
- Muñoz-Leal S, Faccini-Martínez AA, Costa FB, Marcili A, Mesquita ETKC, Marques EP Jr, et al. Isolation and molecular characterization of a relapsing fever *Borrelia* recovered from *Ornithodoros ruidis* in Brazil. *Ticks Tick Borne Dis*. 2018;9:864-71
- Estrada-Peña A, Jongejan F. Ticks feeding on humans: a review of records on human-biting Ixodoidea with special reference to pathogen transmission. *Exp Appl Acarol*. 1999;23:685-715.
- Reck J, Marks FS, Guimarães JA, Termignoni C, Martins JR. Epidemiology of *Ornithodoros brasiliensis* (mouro tick) in the southern Brazilian highlands and the description of human and animal retrospective cases of tick parasitism. *Ticks Tick Borne Dis*. 2013;4:101-9.
- Labruna MB, Marcili A, Ogrzewalska M, Barros-Battesti DM, Dantas-Torres F, Fernandes AA, et al. New records and human parasitism by *Ornithodoros mimon* (Acar: Argasidae) in Brazil. *J Med Entomol*. 2014;51:283-7.
- de Oliveira SV, Bitencourth K, Borsoi ABP, de Freitas FSS, Castelo Branco Coelho G, Amorim M, et al. Human parasitism and toxicosis by *Ornithodoros rietcorrei* (Acar: Argasidae) in an urban area of Northeastern Brazil. *Ticks Tick Borne Dis*. 2018.

AUTHORS' CONTRIBUTIONS

Stefan Vilges de Oliveira

 ORCID 0000-0002-5493-2765

Approval of the final version of the manuscript; conception and planning of the study; elaboration and writing of the manuscript; Obtaining, analyzing and interpreting the data; critical review of the literature; and critical review of the manuscript

Álvaro A. Faccini-Martínez

 ORCID 0000-0002-1127-0132

Approval of the final version of the manuscript; conception and planning of the study; elaboration and writing of the manuscript; Obtaining, analyzing and interpreting the data; intellectual participation in the propaedeutic and/or therapeutic approach of the studied cases; critical review of the literature; and critical review of the manuscript

How to cite this article: de Oliveira SV, Faccini-Martínez AA. *Rickettsia parkeri* spotted fever and toxicosis by *Ornithodoros*: other tick bite-related entities to be known by dermatologists. *An Bras Dermatol*. 2019;94(1):122-3.

Reply/ Correspondence ▼

Answer from the authors of the article “Skin manifestations of tick bites in humans” to Dr. Stefan Vilges de Oliveira and Dr. Álvaro A. Faccini-Martínez

Vidal Haddad Junior¹
Michel Raineri Haddad²
Mônica Santos^{3,4}
João Luiz Costa Cardoso⁵

DOI: <http://dx.doi.org/10.1590/abd1806-4841.2019940102>

We are grateful for the comments which will certainly enrich the ever-evolving knowledge about tick-borne diseases, both those caused by parts of the tick's mouth remaining in the skin after the bite and the infectious diseases transmitted by the arthropods. We are sure that the letter will draw readers' attention and will fulfill the function intended by the authors. However, it should be clear that the purpose of the article was not to exhaust the subject, but, as a medical text, to propose a practical classification so that dermatologists and other professionals in the field of Tropical Medicine know more about the problem and know how to evaluate later complications caused by the bites. However, due to the constant evolution of studies on tick-borne diseases, the scientific significance of this type of text may be limited (although the most frequent diseases are all approached by the study). On the other hand, the idea of classification based on a clinical observation and consequent therapeutic indication, the primary objective of the work remains – and will remain – current.¹ □

Received 20 July 2018.
Accepted 28 October 2018.

¹ Department of Dermatology and Radiotherapy, Faculdade de Medicina de Botucatu, Universidade Estadual Paulista, Botucatu (SP), Brazil.

² Department of Internal Medicine, Faculdade de Medicina de São José do Rio Preto, São José do Rio Preto (SP), Brazil.

³ Department of Dermatology, Universidade Estadual do Amazonas, Manaus (AM), Brazil.

⁴ Outpatient Clinic of Tropical Dermatology, Fundação Alfredo da Matta (FUAM) – Manaus (AM), Brazil.

⁵ Ubatuba Dermatology Clinic, Ubatuba (SP), Brazil.

MAILING ADDRESS:





Vidal Haddad Junior
E-mail: haddadjr@fmb.unesp.br

©2019 by Anais Brasileiros de Dermatologia



REFERENCES

- Haddad V Jr, Haddad MR, Santos M, Cardoso JLC. Skin manifestations of tick bites in humans. *An Bras Dermatol*. 2018;93:251-5.

Vidal Haddad Jr.  ORCID 0000-0001-7214-0422
Michel Raineri Haddad  ORCID 0000-0002-0978-9525
Mônica Santos  ORCID 0000-0003-0578-3270
João Luiz Costa Cardoso  ORCID 0000-0003-4138-0866