



# Extracorporeal Shock Wave Therapy for Hypertrophic Scars

Apirag Chuangsuwanich, MD<sup>1</sup> Natthapong Kongkunnawat, MD<sup>1</sup> Malika Kamanamool, MD<sup>1</sup>  
 Gulradar Maipeng<sup>2</sup> Nanticha Kamanamool, MD<sup>3</sup> Warangkana Tonaree, MD<sup>1</sup>

<sup>1</sup>Division of Plastic Surgery, Department of Surgery, Faculty of Medicine Siriraj Hospital, Mahidol University, Bangkok, Thailand

<sup>2</sup>Perioperative Nurse Division, Department of Surgery, Faculty of Medicine Siriraj Hospital, Mahidol University, Bangkok, Thailand

<sup>3</sup>Department of Preventive and Social Medicine, Faculty of Medicine Srinakharinwirot University, Ongkharak, Thailand

Address for correspondence Warangkana Tonaree, MD, Division of Plastic Surgery, Department of Surgery, Faculty of Medicine Siriraj Hospital, Mahidol University, 2 Wanglang Road, BangkokNoi, Bangkok 10700, Thailand (e-mail: Teenybd@gmail.com).

Arch Plast Surg 2022;49:554–560.

## Abstract

**Background** Hypertrophic scars cause aesthetic concerns and negatively affect the quality of life. A gold standard treatment for hypertrophic scars has not been established due to various responses of modalities. Extracorporeal shock wave therapy (ESWT) is a noninvasive and affects scar remodeling by fibroblast regulation. This study investigated the effectiveness of ESWT for hypertrophic scars.

**Methods** Twenty-nine patients were enrolled. All patients underwent ESWT once a week for 6 consecutive weeks. Their scars were assessed using the Patient and Observer Scar Assessment Scale (POSAS), erythema index, melanin index, and scar pliability before treatment and again 4 weeks after treatment completion.

**Results** Thirty-four hypertrophic scars in this study had persisted for between 6 months and 30 years. Most scars developed after surgical incision (55.88%). The chest and upper extremities were the predominant areas of occurrence (35.29% each). Most of the POSAS subscales and total scores were significantly improved 4 weeks after treatment ( $p < 0.05$ ). Furthermore, the pain, itching, and pigmentation subscale were improved. The pliability, melanin index, and erythema index were also improved, but without significance. The patients were satisfied with the results and symptoms alleviation, although subjective score changes were insignificant. No serious adverse events were found. The patients reported pruritus in 62.5% and good pain tolerance in 37.5%. Subgroup analyses found no differences in scar etiologies or properties at different parts of the body.

**Conclusion** The ESWT is a modality for hypertrophic scar treatment with promising results. Most of POSAS subscales were significantly improved.

## Keywords

- ▶ extracorporeal shock wave
- ▶ hypertrophic scar
- ▶ wound healing
- ▶ scar prevention

DOI <https://doi.org/10.1055/s-0042-1751027>.  
 ISSN 2234-6163.

© 2022. The Korean Society of Plastic and Reconstructive Surgeons. All rights reserved.

This is an open access article published by Thieme under the terms of the Creative Commons Attribution-NonDerivative-NonCommercial-License, permitting copying and reproduction so long as the original work is given appropriate credit. Contents may not be used for commercial purposes, or adapted, remixed, transformed or built upon. (<https://creativecommons.org/licenses/by-nc-nd/4.0/>)

Thieme Medical Publishers, Inc., 333 Seventh Avenue, 18th Floor, New York, NY 10001, USA

## Introduction

Hypertrophic scar occurs from an abnormal wound healing process that involves excessive dermal collagen production. It may affect patients in several ways, such as pruritic sensation, scar tenderness, and limited range of motion. These negatively impact the quality of life of patients.<sup>1</sup>

The reported incidences of hypertrophic scars following surgical incision wounds ranged from 40 to 70%. However, incidences of up to 90% have been reported after burns, especially in individuals with a higher Fitzpatrick skin tone.<sup>2</sup> Approximately 1,200 patients seek hypertrophic scar treatment annually at our outpatient plastic surgery department.

Currently, there is no established gold standard for hypertrophic scar treatment since the responses to treatment and recurrence rates have varied. Several treatment modalities have been combined for hypertrophic scar treatment, such as intralesional steroid injections, pressure dressings, surgical excision, pulsed dye lasers, and radiation therapy. However, no combination proved to be successful curative therapy. Furthermore, most modalities require multiple treatment sessions and have adverse effects associated with their use. Therefore, a noninvasive treatment modality with good efficacy could be a preferable treatment option.<sup>2,3</sup>

Extracorporeal shock wave therapy (ESWT) has been widely used as a noninvasive and well-tolerated treatment for tendinopathy in general. It is also used for other orthopaedic diseases, nephroureterolithiasis, ischemic cardiovascular disease, burn wound scars, acute and chronic wounds. The wide range of applications highlights the versatile benefits and regenerative potential of ESWT.<sup>4-11</sup> ESWT transmits a mechanical force via an acoustic wave to facilitate wound healing. The force stimulates the release of neuropeptides from nerve endings and improves wound healing. Furthermore, it also stimulates fibroblasts, which are mechanoresponsive cells and play a role in remodeling of the extracellular matrix in wound healing and scars.<sup>12-20</sup>

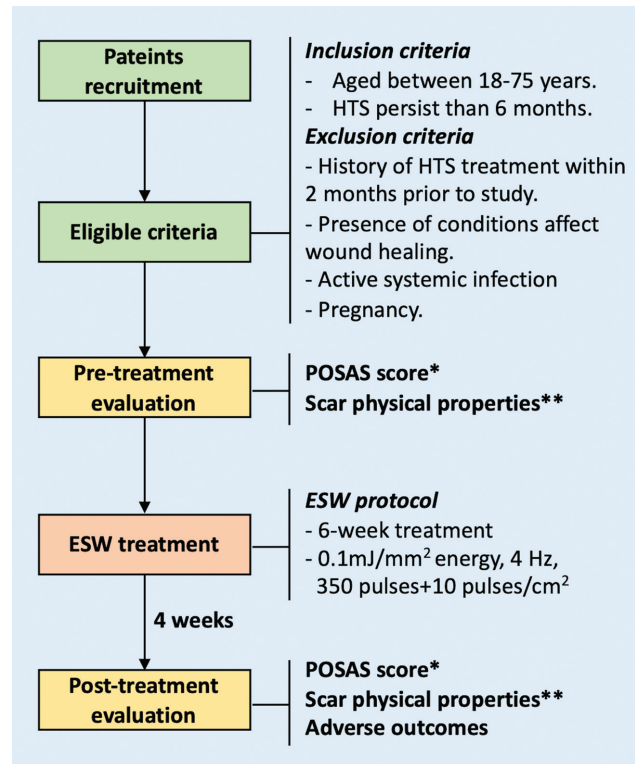
The molecular mechanism of ESWT has not yet been fully identified. However, induction of angiogenesis via stimulation of toll-like receptor 3 during ESWT was proposed in the literatures, possibly indicating the benefits of soft tissue regeneration.<sup>21,22</sup> In the research by Fioramonti et al, the effectiveness of ESWT for burn scars was found to be promising, with no adverse events observed.<sup>4</sup> This study aimed to investigate the effectiveness of ESWT for hypertrophic scars.

## Methods

### Study Design

This study was approved by the Institutional Review Board (approval number 295/2016). The Declaration of Helsinki protocol was followed. The study was conducted at the outpatient department of plastic surgery unit from September 2016 to November 2017. Twenty-nine patients were enrolled and gave written informed consent.

Patients aged between 18 and 75 years old and had persistent hypertrophic scars for more than 6 months prior



**Fig. 1** Study design, treatment protocol, and treatment evaluation. \*The POSAS consisted of a patient scar assessment and an observer scar assessment. \*\*Physical properties of the scar, such as elasticity index, erythema index, scar area and thickness. ESW, extracorporeal shock wave; HTS, hypertrophic scars; POSAS, Patient and Observer Scar Assessment Scale.

to the study were included. Exclusion criteria were a history of hypertrophic scar-related treatment within 2 months prior to enrolment; conditions or risk factors for impaired wound healing (such as an immunocompromised state, connective tissue disease, and smoking); a concurrent active systemic infection; and pregnancy.

### Study Protocol

All patients underwent preoperative assessments of their hypertrophic scars. They involved the determination of the Patient and Observer Scar Assessment Scale (POSAS), the erythema index and the melanin index; evaluation of scar pliability; and photographic documentation (► Fig. 1).

ESWT was performed once a week for 6 consecutive weeks by using Dermagold 100 (MTS Europe GmbH, Konstanz, Germany). The settings were 0.1 mJ/mm<sup>2</sup> energy, 4Hz frequency, and 350 pulses + 10 pulses/cm<sup>2</sup>.

At 4 weeks after completion of treatment, hypertrophic scars were reassessed with the POSAS, the erythema index, the melanin index, the pliability of the scars, and photographic documentation. Evaluation was performed in the same manner as for preoperative assessments.

### Hypertrophic Scar Evaluation

Hypertrophic scars were evaluated with POSAS, a validated assessment tool for scar treatment. It consists of two

numerical scales: patient-scar assessment and observer-scar assessment.<sup>23–26</sup>

The patient scar assessment scale includes pain, pruritic sensation, dyspigmentation, pliability, thickness, irregularity, and overall opinion of scar. The parameters in observer scar assessment scale consist of vascularity, pigmentation, thickness, relief, pliability, and surface area.

To assess the physical properties of scars, their areas were measured using the widest part of each scar as the scar width and the most extended section as the scar length. In addition, the thickness of the scars was measured three times to establish the average value of the thickest part of each scar. The measurement points were noted, and the calculations at subsequent visits used the same points. The same portion of each scar was documented, measured, and evaluated before and after each ESWT session to ensure that comparisons were accurate.

The erythema and melanin indices were measured with a Mexameter MX 18 (Courage + Khazaka Electronic GmbH, Cologne, Germany). The erythema index has an arbitrary number of 0 to 999. The higher the value is, the greater the degree of erythema present. The melanin index also has a scale number and a similar interpretation guide. The greater the melanin index value is, the greater the melanin content present.<sup>27</sup>

For the scar pliability, the Cutometer dual MPA 580 (Courage + Khazaka Electronic GmbH, Cologne, Germany) was used. The elasticity index of the R2 parameter represents the gross elasticity of a hypertrophic scars. It is one of the most widely used parameters in the literatures.<sup>27–29</sup>

### Statistical Analysis

The primary outcome was the improvement in hypertrophic scars, indicated by the POSAS. All other results were defined as secondary outcomes. To estimate the sample size, we relied on the work of Fioramonti et al.<sup>4</sup> The sample size was calculated using the PS Power and Sample Size Calculation program at an  $\alpha$  level of 0.05, a maximum tolerated error of 0.15, and a 10% dropout. According to the calculation, 30 patients were needed. A paired *t*-test was used for continuous data with normal distribution. However, an independent *t*-test was used for continuous data in the subgroup analyses.

All statistical data were analyzed by PASW Statistics for Windows, version 18.0 (SPSS Inc., Chicago, IL). A *p*-value less than 0.05 was considered statistically significant.

### Results

Twenty-nine patients with 34 hypertrophic scars were enrolled. Their average age was  $42.06 \pm 15.57$  years. The scars had persisted for between 6 months and 30 years. Most had developed after surgical incision wounds (55.88%) following by traumatic wounds (20.59%), burn wounds (11.76%), and infected wounds (11.76%). The chest and upper extremities were the main areas of scar occurrence (each was 35.29%), followed by the face, abdomen, and lower extremities (each was 8.82%; ▶ **Table 1**). The surgical incision wounds and

**Table 1** Demographic profile of patients

Number of cases	<i>n</i>
Number of patients	29
Number of lesions	34
	Mean $\pm$ SD
Age, years	42.06 $\pm$ 15.57
Sex	<i>n</i> (%)
Female	29 (85.29%)
Male	5 (14.71%)
	Mean (range)
Duration of scar, years	4 (0.5–30)
	<i>n</i> (%)
Causes of HTS	
Surgical wound	19 (55.88%)
Traumatic wound	7 (20.59%)
Burn wound	4 (11.76%)
Infected wound	4 (11.76%)
Site of HTS	
Chest	12 (35.29%)
Upper extremity	12 (35.29%)
Lower extremity	3 (8.82%)
Face	3 (8.82%)
Abdomen	3 (8.82%)
Back	1 (2.94%)

Abbreviations: HTS, hypertrophic scars; SD, standard deviation.

traumatic wounds were all closed primarily. Burn wounds were healed by secondary intention or skin grafts if indicated. The infected wounds were healed by delayed primary closure or secondary intention if indicated.

At 4 weeks after completion of treatment, almost of POSAS subscales and total scores had improved from both the patients' and observers' aspects. The scar color, scar stiffness, scar thickness, scar irregularity, overall scar, and total score of POSAS patient scale were significantly improve ( $p < 0.01$ ). Improvements were also observed in the pain and pruritic subscale of POSAS patient scale, but the differences were not statistically significant ( $p = 0.66$  and  $0.34$ , respectively). The scar vascularity, scar thickness, relief, pliability, and total score of POSAS observer scale were significantly improved ( $p < 0.01$ ). The observer-evaluated surface area improvement in POSAS observer scale was also significantly improved ( $p < 0.05$ ). However, the observer-evaluated scar pigmentation also displayed improvement without significance ( $p = 0.09$ ) (▶ **Table 2**).

For the physical properties of the scars, the pliability (represented by the R2 parameter) improved from  $0.61 \pm 0.02$  to  $0.63 \pm 0.02$  ( $p = 0.48$ ). Likewise, the melanin index improved from  $285.65 \pm 24.88$  to  $283.83 \pm 23.24$  ( $p = 0.87$ ). Although the erythema index also improved from  $439.18 \pm 14.92$  to  $435.16 \pm 14.74$ , the difference was

**Table 2** Comparison of the results of the parameters of the hypertrophic scars

	Before treatment (mean ± SD)	After treatment (mean ± SD)	p-Value
POSAS patient scale			
Pain sensation	4.41 ± 0.43	4.16 ± 0.48	0.66
Pruritic sensation	5.53 ± 0.38	5.03 ± 0.49	0.34
Scar color	8.00 ± 0.37	5.40 ± 0.44	<0.01 <sup>a</sup>
Scar stiffness	7.88 ± 0.37	5.31 ± 0.45	<0.01 <sup>a</sup>
Scar thickness	8.00 ± 0.33	6.06 ± 0.45	<0.01 <sup>a</sup>
Surface irregularity	8.09 ± 0.41	6.22 ± 0.44	<0.01 <sup>a</sup>
Overall scar	9.00 ± 0.28	6.22 ± 0.48	<0.01 <sup>a</sup>
Total score	49.36 ± 2.20	38.42 ± 2.43	<0.01 <sup>a</sup>
POSAS observer scale			
Scar vascularity	5.18 ± 0.41	3.35 ± 0.35	<0.01 <sup>a</sup>
Scar pigmentation	3.18 ± 0.31	2.76 ± 0.31	0.09
Scar thickness	5.41 ± 0.39	4.38 ± 0.36	<0.01 <sup>a</sup>
Relief	4.94 ± 0.41	3.76 ± 0.30	<0.01 <sup>a</sup>
Pliability	5.38 ± 0.36	4.24 ± 0.35	<0.01 <sup>a</sup>
Surface area	4.56 ± 0.37	3.94 ± 0.27	<0.05 <sup>a</sup>
Total score	28.65 ± 1.49	22.44 ± 1.52	<0.01 <sup>a</sup>
Physical properties			
R2 parameter	0.61 ± 0.02	0.63 ± 0.02	0.48
Melanin index	285.65 ± 24.88	283.83 ± 23.24	0.87
Erythema index	439.18 ± 14.92	435.16 ± 14.74	0.70
Scar area (cm <sup>2</sup> )	24.83 ± 6.58	25.25 ± 6.74	0.60
Scar thickness (cm)	0.81 ± 0.20	0.84 ± 0.26	0.88
		<i>n</i> (%)	
Adverse events		8 (23.53%)	
Pruritic sensation		5 (62.50%)	
Well-tolerated pain		3 (37.50%)	

Abbreviations: POSAS, Patient and Observer Scar Assessment Scale; SD, standard deviation.

<sup>a</sup>Nearly all results of POSAS subscales were statistically significantly improved ( $p < 0.05$ ).

insignificant ( $p = 0.70$ ). The scar area went up from of the scars increased from  $24.83 \pm 6.58 \text{ cm}^2$  to  $25.25 \pm 6.74 \text{ cm}^2$ , and the thickness rose from  $0.81 \pm 0.20 \text{ cm}$  to  $0.84 \pm 0.26 \text{ cm}$ . However, neither increase was statistically significant ( $p = 0.60$  and  $0.88$ , respectively; ► **Figs. 2** and **3**).

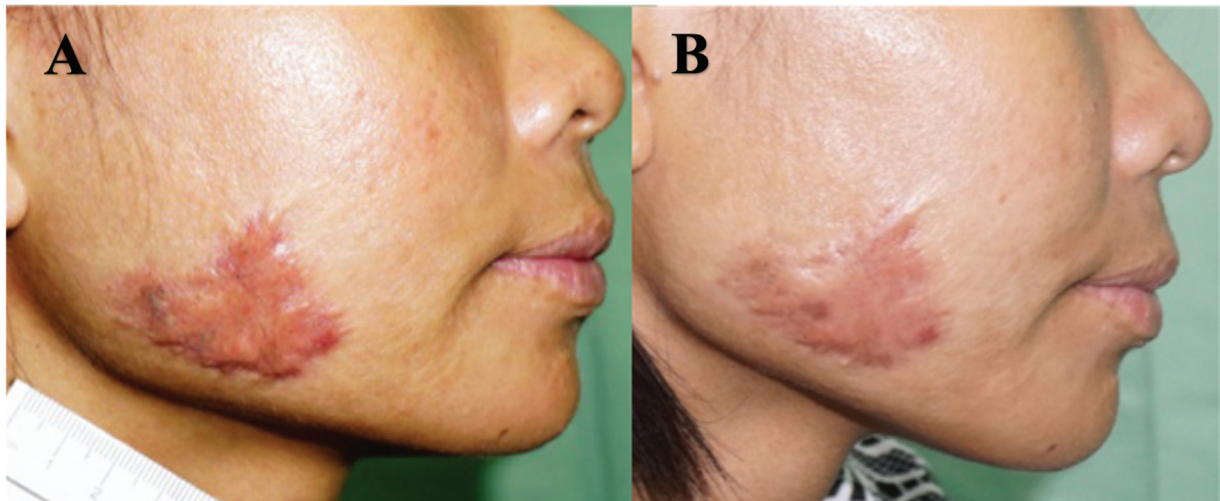
Adverse events, which were short-term temporary symptoms occurring only during ESWT sessions, were found in 23.5% of the cases. About 62.5% of the patients experienced the pruritic sensation when applied the ESWT to the hypertrophic scars and well-tolerated pain was reported by 37.5% of patients during application of ESWT. No serious adverse effects were found.

Subgroup analyses were performed to compare the etiology of scars and differences by the location on the body. The POSAS, scar pliability, melanin index, and erythema index of each subgroup were compared. There was no statistically significant difference in the etiology of scars resulting from

surgical and nonsurgical wounds. Additionally, the hypertrophic scar properties were not different between body locations (chest and back versus other areas). The subgroup analysis data are detailed in ► **Supplementary Table S1** (available in the online version).

## Discussion

Hypertrophic scarring is an abnormal wound healing process in which fibroblasts and excessive collagen production play roles. Most hypertrophic scars are self-limiting. However, they appear to be persistent for patients susceptible to hypertrophic scarring. The scars can limit the range of motion, initiate pruritic sensations, and decrease patients' quality of life. Although several treatment modalities have been used, their response rates have not been consistent. Therefore, a gold-standard treatment for hypertrophic scars



**Fig. 2** Improvement in a hypertrophic scar after extracorporeal shock wave therapy (ESWT). The hypertrophic scar at the right jawline; note the redness, vascularity, and thickness before treatment (A). Improvement in redness, vascularity, and thickness of the hypertrophic scar 4 weeks after the completion of ESWT (B).

has not yet been established. Furthermore, current treatments have adverse events associated with their use.<sup>2,3</sup>

An ideal properties of hypertrophic scar treatment should be easy-to-use, noninvasive, well-tolerated, available at out-patient setting, and less adverse events. ESWT meets all of these attributes.<sup>4,30-32</sup> ESWT is a noninvasive modality for hypertrophic scar treatment. Although its mechanism of action is still under investigation, complex biological responses are known to be activated by ESWT. Among them are the release of growth factors, cytokines, and chemokines, and the regulation of fibroblasts. These responses lead to wound and scar remodeling.<sup>12,13,16,17,31</sup>

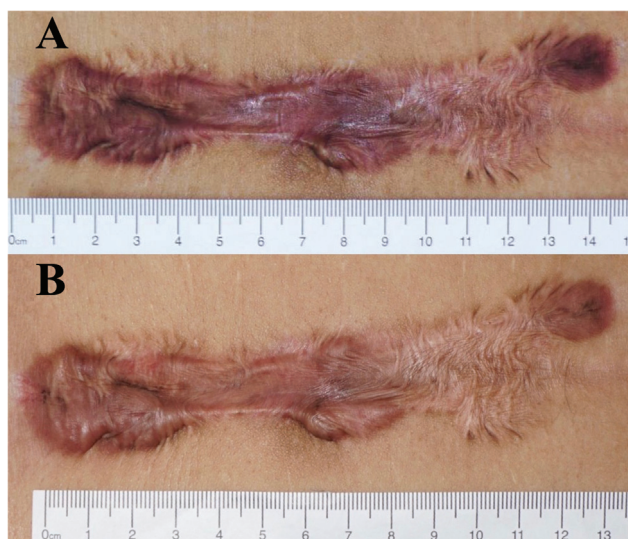
Fioramonti et al examined the use of ESWT for hypertrophic scars following burn wounds. The researchers found an

improvement in the visual analog scales used for scar assessment.<sup>4</sup> However, as the scores of visual analog scale represent subjective evaluations, they vary with the observer. In this study, we used both subjective and objective evaluations. The POSAS, which is validated scale in both patient and observer aspect, was used for subjective evaluation. To evaluate hypertrophic scars objectively, we used a Cutometer for pliability evaluations and Mexameter to assess melanin and erythema indices. The results showed a significant improvement in almost all POSAS subscales for both the patient and observer aspects, but no significant improvements in size, thickness, scar pliability, and erythema and melanin indices. The underlying cause of the nonsignificant improvements in some parameters could be the effect of the irregularity of the scar surface, confounding the results.<sup>4</sup>

In addition, there were several studies about the mechanism of improvement in hypertrophic scars after ESWT.<sup>2-6</sup> We transformed the effects of ESWT on hypertrophic scars into the clinical results as POSAS scores, and most of the POSAS subscales were significantly improved after treatment. Apart from the previous studies, which included only the hypertrophic scars following burn wounds,<sup>4,8,15</sup> the current study also included the various etiologies of hypertrophic scars to extend the indications of using ESWT in other causes of hypertrophic scars.

For further study improvement, errors in area measurements might be resolved using a computer-assisted method. The use of ultrasound might also reduce thickness measurement errors. Ultrasound is consistent due to its accuracy and reproducibility.<sup>33</sup>

As to the nature of hypertrophic scars, some parts of the scars had more stiffness than the surrounding skin, whereas other parts demonstrated more noticeable deformation than the nearby skin. Heterogeneity within lesions results in lower reliability of scar pliability measurements.<sup>34</sup> Results might not represent the properties of the whole scar, leading to inconsistent measurements.



**Fig. 3** Improvement in a hypertrophic scar after extracorporeal shock wave therapy (ESWT). The hypertrophic scar had erythema and hyperpigmentation at before treatment (A). Improvement in erythema and hyperpigmentation of the hypertrophic scar 4 weeks after the completion of ESWT (B).

This study observed outcomes 4 weeks after treatment. However, this time point might not capture the maximum efficacy or long-term effects of hypertrophic scar treatment with ESWT. Further research on the long-term effects might be considered.

In conclusion, ESWT demonstrated promising improvements in hypertrophic scars, as evaluated by POSAS. This study served as support data for further investigations of the use of ESWT for the treatment of hypertrophic scars.

#### Author Contributions

Conceptualization: A.C., M.K., and W.T. Data curation: G. M., N. Kongkunnawat, N. Kamanamool, and W.T. Formal analysis: M.K., G.M., N. Kongkunnawat, N. Kamanamool, and W.T. Methodology: A.C., M.K., G.M., N. Kamanamool, and W.T. Project administration: A.C. and W.T. Visualization: N. Kongkunnawat, N. Kamanamool, and W.T. Writing-original draft: A.C., N. Kongkunnawat, M.K., G.M., N. Kamanamool, and W.T. Writing-review & editing: A.C., N. Kongkunnawat, W.T. All authors read and approved the final manuscript.

#### Ethical Approval

This study was approved by the Institutional Review Board of Faculty of Medicine Siriraj Hospital (approval number 295/2016). The Declaration of Helsinki protocol was followed.

#### Patient Consent

Informed consent was obtained from all individual participants included in the study.

#### Conflict of Interest

A.C. is an editorial board member of the journal but was not involved in the peer reviewer selection, evaluation, or decision process of this article. No other potential conflicts of interest relevant to this article were reported.

#### References

- Lorenz P, Bari AS. Scar prevention, treatment, and revision. In: Neligan PC, ed. *Plastic Surgery* 3rd ed. London: Elsevier Saunders; 2012:297–318
- Gauglitz GG, Korting HC, Pavicic T, Ruzicka T, Jeschke MG. Hypertrophic scarring and keloids: pathomechanisms and current and emerging treatment strategies. *Mol Med* 2011;17(1-2):113–125
- Rabello FB, Souza CD, Farina Júnior JA. Update on hypertrophic scar treatment. *Clinics (São Paulo)* 2014;69(08):565–573
- Fioramonti P, Cigna E, Onesti MG, Fino P, Fallico N, Scuderi N. Extracorporeal shock wave therapy for the management of burn scars. *Dermatol Surg* 2012;38(05):778–782
- Qureshi AA, Ross KM, Ogawa R, Orgill DP. Shock wave therapy in wound healing. *Plast Reconstr Surg* 2011;128(06):721e–727e
- Speed C. A systematic review of shockwave therapies in soft tissue conditions: focusing on the evidence. *Br J Sports Med* 2014;48(21):1538–1542
- Cui HS, Joo SY, Cho YS, et al. Effect of extracorporeal shock wave therapy on keratinocytes derived from human hypertrophic scars. *Sci Rep* 2021;11(01):17296
- Joo SY, Lee SY, Cho YS, Seo CH. Clinical utility of extracorporeal shock wave therapy on hypertrophic scars of the hand caused by burn injury: a prospective, randomized, double-blinded study. *J Clin Med* 2020;9(05):E1376
- Ito K, Fukumoto Y, Shimokawa H. Extracorporeal shock wave therapy for ischemic cardiovascular disorders. *Am J Cardiovasc Drugs* 2011;11(05):295–302
- Li H, Liu ML. Cardiac shock wave therapy: an alternative non-invasive therapy for refractory angina. *Eur Rev Med Pharmacol Sci* 2018;22(16):5402–5410
- Wang W, Liu H, Song M, Fang W, Yuan F. Clinical effect of cardiac shock wave therapy on myocardial ischemia in patients with ischemic heart failure. *J Cardiovasc Pharmacol Ther* 2016;21(04):381–387
- d'Agostino MC, Craig K, Tibalt E, Respizzi S. Shock wave as biological therapeutic tool: from mechanical stimulation to recovery and healing, through mechanotransduction. *Int J Surg* 2015;24(Pt B):147–153
- Frairia R, Berta L. Biological effects of extracorporeal shock waves on fibroblasts. A review. *Muscles Ligaments Tendons J* 2012;1(04):138–147
- Ogawa R. Mechanobiology of scarring. *Wound Repair Regen* 2011;19(Suppl 1):s2–s9
- Pinheiro NM, Melo PR, Crema VO, Mendonça AC. Effects of radio-frequency procedure on hypertrophic scar due to burns. *J Eur Acad Dermatol Venereol* 2015;29(01):187–189
- Sukubo NG, Tibalt E, Respizzi S, Locati M, d'Agostino MC. Effect of shock waves on macrophages: a possible role in tissue regeneration and remodeling. *Int J Surg* 2015;24(Pt B):124–130
- Wang JH, Thampatty BP, Lin JS, Im HJ. Mechanoregulation of gene expression in fibroblasts. *Gene* 2007;391(1-2):1–15
- Cui HS, Hong AR, Kim JB, et al. Extracorporeal shock wave therapy alters the expression of fibrosis-related molecules in fibroblast derived from human hypertrophic scar. *Int J Mol Sci* 2018;19(01):E124
- Moortgat P, Anthonissen M, Van Daele U, et al. The effects of shock wave therapy applied on hypertrophic burn scars: a randomised controlled trial. *Scars Burn Heal* 2020;6:2059513120975624
- Wang CJ, Ko JY, Chou WY, Cheng JH, Kuo YR. Extracorporeal shockwave therapy for treatment of keloid scars. *Wound Repair Regen* 2018;26(01):69–76
- Gollmann-Tepeköylü C, Nägele F, Graber M, et al. Shock waves promote spinal cord repair via TLR3. *JCI Insight* 2020;5(15):134552
- Holfeld J, Tepeköylü C, Kozaryn R, et al. Shockwave therapy differentially stimulates endothelial cells: implications on the control of inflammation via toll-like receptor 3. *Inflammation* 2014;37(01):65–70
- Draaijers LJ, Tempelman FR, Botman YA, et al. The patient and observer scar assessment scale: a reliable and feasible tool for scar evaluation. *Plast Reconstr Surg* 2004;113(07):1960–1965
- Durani P, McGrouther DA, Ferguson MW. The Patient Scar Assessment Questionnaire: a reliable and valid patient-reported outcomes measure for linear scars. *Plast Reconstr Surg* 2009;123(05):1481–1489
- Durani P, McGrouther DA, Ferguson MW. Current scales for assessing human scarring: a review. *J Plast Reconstr Aesthet Surg* 2009;62(06):713–720
- Nicholas RS, Falvey H, Lemonas P, et al. Patient-related keloid scar assessment and outcome measures. *Plast Reconstr Surg* 2012;129(03):648–656
- Verhaegen PDHM, van der Wal MBA, Middelkoop E, van Zuijlen PPM. Objective scar assessment tools: a clinimetric appraisal. *Plast Reconstr Surg* 2011;127(04):1561–1570
- Fearmonti R, Bond J, Erdmann D, Levinson H. A review of scar scales and scar measuring devices. *Eplasty* 2010;10:e43
- Neto P, Ferreira M, Bahia F, Costa P. Improvement of the methods for skin mechanical properties evaluation through correlation

- between different techniques and factor analysis. *Skin Res Technol* 2013;19(04):405–416
- 30 Antonic V, Mittermayr R, Schaden W, Stojadinovic A. Evidence supporting extracorporeal shock wave therapy for acute and chronic soft tissue wounds. *Wounds* 2011;23(07):204–215
- 31 Mittermayr R, Antonic V, Hartinger J, et al. Extracorporeal shock wave therapy (ESWT) for wound healing: technology, mechanisms, and clinical efficacy. *Wound Repair Regen* 2012;20(04):456–465
- 32 Romeo P, Lavanga V, Pagani D, Sansone V. Extracorporeal shock wave therapy in musculoskeletal disorders: a review. *Med Princ Pract* 2014;23(01):7–13
- 33 van Zuijlen PP, Angeles AP, Kreis RW, Bos KE, Middelkoop E. Scar assessment tools: implications for current research. *Plast Reconstr Surg* 2002;109(03):1108–1122
- 34 Draaijers LJ, Botman YA, Tempelman FR, Kreis RW, Middelkoop E, van Zuijlen PP. Skin elasticity meter or subjective evaluation in scars: a reliability assessment. *Burns* 2004;30(02):109–114