

# Treatment of Oligometastatic Disease in Squamous Cell Carcinoma of the Head and Neck

Aurora G. Vincent, MD, FACS ; Weitao Wang, MD ; Tom Shokri, MD; Yadranko Ducic, MD, FACS

**Objective:** No surgical or radiotherapeutic treatment guidelines exist for oligometastatic head and neck squamous cell carcinoma (oHNSCC), and only recently have interventions with curative intent been studied. Herein, we sought to elucidate survival rates among patients with oHNSCC to determine if treatment with curative intent is warranted in this population.

**Study Design:** Retrospective chart review.

**Methods:** We retrospectively reviewed cases of oHNSCC treated between March 1998 and March 2018. Fisher's exact test was used to compare patients treated with radiotherapy (RT) to those who underwent surgical excision and to compare outcomes of patients with oligometastases at the time of initial presentation to those that developed oligometastatic disease after primary treatment.

**Results:** Eighty one patients with metastases to the lungs, ribs, pelvis, vertebral column, liver, clavicle, and sternum were included. Overall, 32 patients (40%) were alive 5 years post-treatment. The site of metastasis, the modality of treatment, and the time of development of oligometastatic disease did not significantly affect 5-year survival.

**Conclusion:** Herein, we demonstrate that multi-modality treatment of oHNSCC is warranted for some patients with an estimated 40% 5-year survival. Aggressive treatment of the primary and regional sites is necessary in addition to treatment of the metastatic site and incurs a survival benefit compared to patients with metastatic HNSCC treated with systemic therapy alone. oHNSCC should be approached separately from polymetastatic disease. Patients should be counseled about the possibility for long-term survival, and aggressive initial treatment with the intention for cure should be considered in this population.

**Key Words:** Head and neck cancer, squamous cell carcinoma, oligometastatic disease, radiotherapy, chemotherapy.

**Level of Evidence:** 4

*Laryngoscope*, 131:E1476–E1480, 2021

## INTRODUCTION

Head and neck cancers are estimated to become metastatic in 15% to 20% of cases.<sup>1,2</sup> Historically, treatment of distantly metastatic head and neck squamous cell carcinoma (HNSCC) has involved chemotherapy,<sup>1</sup> but survival rates with chemotherapeutic treatment of metastatic HNSCC have been low; 10% to 15% of patients have been estimated to be alive at 5 years after diagnosis.<sup>1</sup> Currently, the median survival of patients with recurrent or metastatic HNSCC has been estimated at 10 months.<sup>3</sup> The EXTREME trial provided guidelines for chemotherapeutic treatment of metastatic HNSCC. Also, recently pembrolizumab immunotherapy has shown efficacy in treating numerous types of malignancy including advanced melanoma and recurrent or metastatic HNSCC (Burtneš et al.

2019; Ott et al. 2016). However, no surgical or radiotherapeutic guidelines exist for these patients,<sup>4</sup> and only recently have these interventions been studied.

Hellman and Weichselbaum first suggested that oligometastatic disease may be a different entity than polymetastatic disease, distinguishing the two in terms of potential treatment benefit and survivability.<sup>5</sup> Following, cancers outside the head and neck have demonstrated that oligometastatic disease can act very differently from polymetastatic disease.<sup>6</sup> Subsequently, treatment of oligometastatic colorectal cancer has been thoroughly studied, and consensus guidelines have been developed.<sup>7</sup> The survival rate of HNSCC with distant metastases have historically been considered to be low enough to preclude attempted treatment with the intention of cure, but the actual rates are unknown. A few recent studies have demonstrated that survival among patients with polymetastatic HNSCC is significantly worse than those with oligometastatic HNSCC (oHNSCC),<sup>6,8</sup> reinforcing Hellman and Weichselbaum's idea that oligometastatic disease should be approached as a different entity than polymetastatic disease. To date, however, no consensus guidelines exist for oHNSCC, and studies of the treatment of oHNSCC are still few.

Herein, we sought to elucidate survival rates among patients with HNSCC and a single site of distant metastasis to determine if therapeutic treatment is warranted in this population.

This is an open access article under the terms of the Creative Commons Attribution-NonCommercial-NoDerivs License, which permits use and distribution in any medium, provided the original work is properly cited, the use is non-commercial and no modifications or adaptations are made.

From the Facial Plastic Surgery Associates (A.G.V., W.W., Y.D.), Fort Worth, Texas, U.S.A.; Pennsylvania State Hershey Medical Center, Otolaryngology – Head and Neck Surgery (T.S.), Hershey, Pennsylvania, U.S.A.

Editor's Note: This Manuscript was accepted for publication on September 3, 2020.

The authors have no financial or other conflicts of interest to disclose. The work herein does not necessarily represent the views of the United States Army or Department of Defense.

Send correspondence to Yadranko Ducic, MD, FACS, Facial Plastic Surgery Associates, 923 Pennsylvania Avenue, Suite 100, Fort Worth, TX 75106. E-mail: yducic@sbcglobal.net

DOI: 10.1002/lary.29115

## METHOD

We retrospectively reviewed cases of squamous cell carcinoma of the head-and-neck treated by the senior author (YD) over a 20-year span between March 1998 and March 2018. Approval for our study was granted by the John Peter Smith Hospital institutional review board, Fort Worth, TX. We included in our study adult patients with a single site of distantly metastatic head-and-neck cancer, who underwent treatment of the primary site, neck, and distant site with the intention of cure. Patients with widely metastatic or polymetastatic disease were excluded. Patients with only regional metastases and no distant metastases were excluded as were patients that were lost-to-follow-up or those that did not pursue or complete a therapeutic regimen with the intention of cure. All distant disease underwent biopsy and histologic evaluation, even among patients pursuing non-surgical options, to confirm malignancy before proceeding with cancer therapy.

Of note, patients with a single site of malignancy in the lungs may have metastatic head and neck cancer, or they may have a second primary cancer presenting at the same time. The classic risk factors for head and neck cancer, smoking and alcohol use, also increase the risk of developing lung cancer, for example. Thus, it is important to obtain a histologic confirmation of suspected distant disease. In some cases, it can be very difficult or impossible to histologically determine if squamous disease in the lungs represents a metastasis or a second primary, however. Thus, in our practice over the past 2 decades, we have approached patients with a single focus of malignancy in the lungs as though their lung disease is a second primary, and we have treated both their HNSCC and their lung disease separately. Squamous cancer does not present primarily in the liver, ribs, or other bony sites, so these lesions represent metastatic disease.

Statistical analysis was completed with GraphPad Prism version 8.0 (GraphPad Software Inc., San Diego, CA). Patients treated with radiotherapy (RT) were compared to patients treated by surgical excision with Fisher's exact testing. Similarly, outcomes of patients with oligometastases at the time of initial presentation were compared to those that developed oligometastatic disease after primary treatment with Fisher's exact testing. An alpha value of 0.05 was assumed significant for all testing.

## RESULTS

We identified 81 patients to include in our study; no patients were excluded due to loss of follow-up, but some refused to complete the recommended treatment due to side-effects of the therapy itself. Fifty-eight patients were male and 23 were female. The average age at treatment was 59.8 years (range 46–69). All patients had stage 4 squamous cell carcinoma due to positive distant metastases. Primary sites of malignancy included the larynx, base-of-tongue, hypopharynx, and cervical esophagus. Primary sites were treated with surgical excision, RT, or a combination of the two. Patients who received RT as

primary therapy to the primary site also received chemotherapy in the form of a platinum derivative and 5FU or Erbitux. Immunotherapy in the form of Keytruda or Opdivo was given to only a few patients and only as salvage therapy.

Patients were initially evaluated for distant disease with a computed tomography (CT) scan of the chest and a magnetic resonance imaging (MRI) scan of the liver and spine. More recently, however, some patients were evaluated for distant disease with positron-emission tomography (PET) scanning. The sites of distant metastasis of disease included the lungs, ribs, pelvis, vertebral column, liver, clavicle, and sternum (Fig. 1). Pulmonary metastases were the most common, affecting 66 (82%) patients in our study. In these cases, metastases were confirmed histologically with biopsy from open thoracoscopy, CT-guided, or transbronchial. Bony metastases were the second most common. Four patients (5%) had metastases to the ribs, three (4%) to the pelvis, and three (4%) to the vertebral column. Additionally, there were two patients (2%) with metastases to the clavicle and one patient (1%) with a sternal metastasis. Finally, 2 patients (2%) experienced metastases to the liver. Figure 1 displays the different sites of metastases in our study.

Among the 66 patients with single pulmonary metastases, 52 (79%) were present at the time of initial evaluation and diagnosis; 14 (21%) developed after initial treatment of the primary and regional disease. Of the 52 patients with metastatic disease at the time of presentation, 44 (85%) underwent external beam radiotherapy (EBRT) alone to treat the metastasis with doses of 74-86Gy. Eight patients (15%) underwent surgical excision (lobectomy), one of whom subsequently underwent EBRT as well. Of the 44 patients who underwent EBRT to the lung metastasis, 20 (45%) developed recurrence in the lung leading to their demise. Twenty-four patients

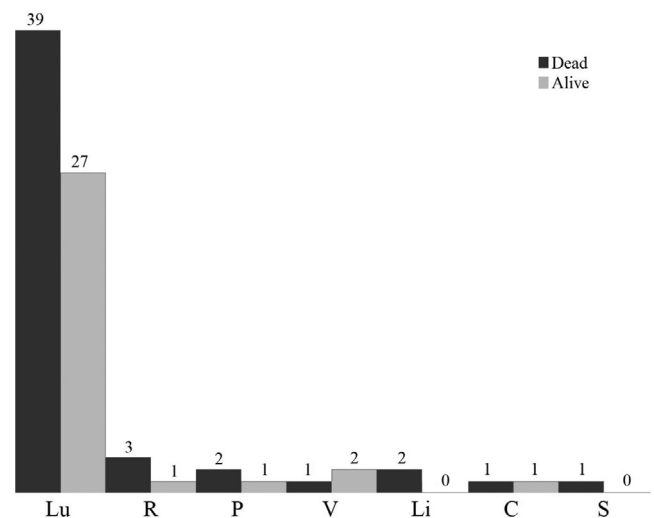


Fig. 1. Sites of distant oligometastasis and respective 5-year survival. Lu = Lung; R = Rib; P = Pelvis; V = Vertebral Column; Li = Liver; C = Clavicle; S = Sternum. Survival rates were not significantly different among different sites of metastasis. Overall 5-year survival was 40%.

(55%) did not develop recurrence in the lung. Of these 24 patients, 19 (79%) were disease-free 5 years after initial therapy. Five patients (21%) developed recurrence of disease at other sites leading to their demise. Of these, three had developed polymetastatic disease involving the liver, lungs, and bones, while two developed recurrent disease at the primary site, in the radiated neck, and in the lungs. Among the eight patients who had surgical treatment of lung disease, five (62%) developed recurrence in the lung and subsequent death. Three patients (38%) did not recur in the lung. Two of these three patients experienced disease recurrence elsewhere leading to their demise, and one patient was disease-free at 5 years after initial treatment.

Fourteen patients (21%) developed a single metastasis in the lungs after initial treatment of the head and neck. The mean time to diagnosis of distant disease was 7.2 months (range 4–14 months) after completion of treatment of the primary site. Seven of these patients (50%) underwent initial surgical resection of pulmonary disease; two had subsequent EBRT. Four patients (57%) who underwent surgical resection experienced recurrence in the lungs, two with additional liver metastases, and eventually died of disease. Seven patients (50%) underwent initial EBRT, and three of these patients (43%), all of whom had a base-of-tongue primary site, later developed disease recurrence in the lung and bones leading to their demise.

Overall, of the 66 patients with single metastases to the lungs, 27 (41%) were alive 5 years after initial diagnosis. Of the patients with lung metastases at the time of initial diagnosis, 20 (38%) survived, whereas 7 (50%) of the patients who developed lung disease after initial treatment of the primary and regional sites survived. Twenty-four (47%) of the 51 patients who underwent EBRT as initial therapy for lung disease, regardless of when it developed, survived to 5 years post-treatment. Of the 15 patients who underwent initial surgical resection of lung disease, four (27%) survived to 5 years. There was no statistically significant difference in survival between treatment modality groups ( $P = .24$ ).

Single metastases to the ribs developed in four patients. Two of these (50%) were present at the time of initial diagnosis, and two (50%) developed after completion of therapy to the head-and-neck, local and regional sites. All rib metastases were treated with EBRT. One patient (25%) who had a metastasis at the time of initial presentation survived to 5 years post-treatment. The other three patients succumbed to disease with multiple rib and lung metastases.

Metastases to the pelvis developed in three patients. One of these was identified at the time of presentation, and two developed after initial treatment of the head and neck. All underwent EBRT. The patient with a distant metastasis at the time of initial diagnosis succumbed to the disease, as did one patient with a pharynx primary who developed pelvic metastases after initial treatment. One patient, however, was alive 5 years post-treatment.

Metastases to the vertebral column were identified in three patients. Specifically, all metastases occurred in a transverse process of a vertebra. None of these patients

had apparent distant disease at the time of initial diagnosis; all developed after the completion of primary treatment. One metastasis was treated with surgical excision followed by EBRT, and this patient was alive 5 years post-treatment. The other two patients underwent surgery for diagnosis only without oncologic resection. They were both treated with EBRT. One of these patients was alive and well 5 years post-treatment. The other did not develop recurrence in the vertebra but did succumb to disease with multiple pulmonary metastases. Thus, of all patients who developed metastases to the vertebral column, two (67%) were alive at 5-year follow-up. There was no statistically significant difference in survival between patient treated with EBRT and those treated with initial surgical resection ( $P = 1.0$ ).

Metastases to the liver developed in two patients. None of these were present at initial diagnosis, but rather they both developed after initial treatment of the head and neck. One patient underwent EBRT, while the other underwent surgical resection. Both patients eventually succumbed to disease with multiple liver metastases and perished.

Clavicular metastases developed in two patients. One was identified at the time of initial diagnosis, and the other developed after initial treatment of the head and neck. Both were treated with surgical resection followed by EBRT. The patient who had disease at the time of initial presentation was disease-free 5 years post-treatment. The other, however, died of disease with multiple bony and pulmonary metastases.

Lastly, one patient experienced a distant metastasis to the sternum, and it developed after initial treatment of the head and neck. It was treated with EBRT, however the patient succumbed to disease and perished with multiple pulmonary and liver metastases.

Table I details the number of patients with single distant metastases by site, time of diagnosis of distant metastases, and survival at 5 years. Table II compares survival between patients with distant disease on initial presentation and those that developed after initial treatment. Overall, 32 patients (40%) were alive 5 years post-treatment. There was no particular site with statistically significantly better 5-year survival than any other site. Also, among the sites in which patients underwent different modalities of therapy, surgery or EBRT, neither modality demonstrated better survival at 5 years ( $P > .05$  in both cases). Further, the time of diagnosis did not convey a statistically significant survival advantage for any site or overall ( $P > .05$ ). Figure 1 depicts 5-year outcomes by site.

## DISCUSSION

Herein, we demonstrate a 40% survival rate 5 years post-treatment for patients with squamous cell carcinoma of the head and neck and a single focus of distant metastasis. Further, this survival rate did not vary by the site of metastasis, the type of treatment (surgery or RT), or whether the distant metastasis was present at the time of initial diagnosis or developed later.

Our study is the largest to evaluate survival of patients with oHNSCC, but it is not without limitations.

TABLE I.  
Site of Oligometastasis, Time of Development, and Survival Rates 5 Years After Initial Treatment.

| Site of Distant Oligometastasis | Overall # of Patients | # Present at Initial Diagnosis | # Developing After Initial Treatment | # Alive 5 Years Post-Treatment |
|---------------------------------|-----------------------|--------------------------------|--------------------------------------|--------------------------------|
| Lung                            | 66                    | 52                             | 14                                   | 27 (41%)                       |
| EBRT                            | 51                    | 44                             | 7                                    | 24 (47%)                       |
| Surgery                         | 15                    | 8                              | 7                                    | 4 (27%)                        |
| Rib                             | 4                     | 2                              | 2                                    | 1 (25%)                        |
| Pelvis                          | 3                     | 1                              | 2                                    | 1 (33%)                        |
| Vertebral Column                | 3                     | 0                              | 3                                    | 2 (67%)                        |
| EBRT                            | 2                     | 0                              | 2                                    | 1 (50%)                        |
| Surgery                         | 1                     | 0                              | 1                                    | 1 (100%)                       |
| Liver                           | 2                     | 0                              | 2                                    | 0 (0%)                         |
| Clavicle                        | 2                     | 1                              | 1                                    | 1 (50%)                        |
| Sternum                         | 1                     | 0                              | 1                                    | 0 (0%)                         |
| <b>Total</b>                    | <b>81</b>             | <b>56</b>                      | <b>25</b>                            | <b>32 (40%)</b>                |

Metastases to the lungs and vertebral column were treated initially with either EBRT or surgical resection; metastases to the other sites were all treated primarily with EBRT. There was no statistically-significant difference in survival between patients with the same site of metastasis treated by different modalities ( $P = .24$  for lung, and  $P = 1.0$  for vertebral column).

EBRT = external beam radiotherapy.

Bold highlights the overall survival rate.

TABLE II.  
Five-Year Survival by Time of Distant Oligometastasis Identification and Site.

| Site of Distant Oligometastasis | # Who Survived after Distant Oligometastasis Identification at the Time of Initial Presentation | # Who Survived after Developing Distant Oligometastasis after Completion of Initial Treatment | Fisher's Exact Test Comparison |
|---------------------------------|---|---|--------------------------------|
| Lung                            | 20 (38%)  | 7 (50%)   | $P = .54$                      |
| Rib                             | 1 (50%)   | 0 (0%)  | $P = 1.0$                      |
| Pelvis                          | 0 (0%)  | 1 (50%)   | $P = 1.0$                      |
| Vertebral Column                | —   | 2 (66%)   | N/A                            |
| Liver                           | —   | 0 (0%)  | N/A                            |
| Clavicle                        | 1 (100%)  | 0 (0%)  | $P = 1.0$                      |
| Sternum                         | —   | 0 (0%)  | N/A                            |
| <b>Total</b>                    | <b>22 (39%)</b>   | <b>10 (40%)</b>   | $P = 1.0$                      |

There was no statistically-significant difference in survival at any site or overall between metastases present at the time of initial diagnosis and those that developed after completion of initial therapy ( $P = 1.0$ ). Overall, 40% of patients who developed distant oligometastasis survived to 5 years post-treatment.

Bold highlights the overall survival rate.

First, all of our patients were treated by the same surgical team, and many were treated by similar radiation oncologists and medical oncologists with similar treatment regimens that may not be generalizable across the country. Next, we are unable to report specific radiation and chemotherapeutic regimens, and whether patients received a short course of chemotherapeutic treatment or were maintained on therapy for several years. Next, given the many years over which our patient cohort was treated and the multiple different medical record system changes during that time, we have been unable to report full details of patient smoking status and comorbidities which can influence their responses to therapy. Also, our data lack a control group; it is assumed that all patients who presented with oHNSCC who did not pursue therapeutic treatment eventually succumbed to their disease, but we do not have the data to verify this assumption. Our comparisons of treatment modalities, time of diagnosis of distant disease,

and survival across different sites of metastasis are limited and underpowered given their sample sizes; all sites other than the lungs had included fewer than five patients. Finally, our study does not address quality of life after therapeutic treatment, which can be of major importance to patients and affect their decision to pursue therapy. To best elucidate the true risk and benefits of treatment of oHNSCC, a prospective, randomized-controlled trial is needed that incorporates recent developments in immunotherapy and the influence of human papilloma virus (HPV) status of the tumor on treatment regimen.

Our results are in line with previous reports and smaller studies. Pulmonary metastases of HNSCC have been reported as the most common,<sup>1,3,7,9</sup> accounting for 70% to 85% of all HNSCC distant metastases,<sup>7</sup> and they made up 82% in our study. Further, bony metastases are reportedly the second most common site of oHNSCC, with the liver being the third most common,<sup>7</sup> and this was also

true in our study. In a systematic review and meta-analysis from 2015, 5-year survival after treatment of pulmonary metastases from HNSCC was estimated to be 29%,<sup>10</sup> though some estimates of surgical treatment of pulmonary oligometastases suggest 5-year survival is higher, at 50%.<sup>1</sup> In our study, survival from all sites was 40% at 5 years.

Our study did not find a difference between treatment of distant metastases via surgical excision or RT. Classically, oligometastases have undergone surgical excision. Stereotactic body radiotherapy (SBRT) and stereotactic ablative body radiotherapy (SABR) have been investigated recently, however, in the treatment of oHNSCC and have been shown to be effective in treating and delaying the need for systemic therapy in both oHNSCC and other types of cancers.<sup>1,9,11–14</sup> Recent data suggests survival after treatment of pulmonary metastases with surgical excision, radiofrequency ablation, or stereotactic radiotherapy is similar,<sup>1</sup> as each modality has been shown to achieve cure of distant disease. Similarly, SBRT/SABR has been used successfully for the treatment of bony metastases in addition to pulmonary metastases.<sup>15</sup> SBRT has not been well studied for liver metastases, and surgical resection remains the most common option. Tang et al. (2019) developed a treatment algorithm for patients with metastatic HNSCC suggesting that patients with three or fewer metastases may still benefit from treatment with a curative intent, whereas patients with more than three metastases should receive chemotherapy and palliative radiotherapy.<sup>15</sup>

Recent advances in immunotherapy have demonstrated efficacy in the treatment of advanced and recurrent cancers of many origins. The Keynote 048 trial, for example, a recent phase three randomized-controlled trial demonstrated improved survival among patients with HNSCC treated with pembrolizumab monotherapy and pembrolizumab combined with platinum / 5-FU compared to traditional therapies. It has altered the standard-of-care guidelines for systemic treatment of HNSCC. This trial and other recent developments in immunotherapy will change future outcomes of patients with metastatic and recurrent HNSCC; they are not accounted for in our current study but must be considered in future studies and treatments.

## CONCLUSION

In sum, multi-modality treatment of oHNSCC is warranted for some patients with an estimated 40% 5-year survival. Aggressive treatment of the primary and regional sites is necessary in addition to treatment of the metastatic site and incurs a survival benefit compared to patients with metastatic HNSCC treated with systemic therapy alone.<sup>7</sup> Pulmonary metastases are the most common site of oligometastases for HNSCC, and, importantly, one cannot

exclude the possibility of a single pulmonary “metastasis” instead being a second primary.<sup>14</sup> Carcinomas in the lung can be difficult to define as lung primaries or metastatic disease from HNSCC on imaging and histologically.<sup>1</sup> Metastases outside the lung, however, should not be cause to forego aggressive treatment, as survival rates in our study, at 40%, are much higher than the 15% survival achieved with chemotherapy alone. Thus, our study herein justifies approaching oHNSCC as a separate entity to polymetastatic disease. Patients should be counseled about the possibility for long-term survival, and aggressive initial treatment with the intention for cure should be considered in this population.

## BIBLIOGRAPHY

1. Florescu C, Thariat J. Local ablative treatments of oligometastases from head and neck carcinomas. *Crit Rev Oncol Hematol* 2014;91:47–63.
2. Ordóñez R, Otero A, Jerez I, Medina JA, Lupiáñez-Pérez Y, Gomez-Millan J. Role of radiotherapy in the treatment of metastatic head and neck cancer. *Oncol Targets Ther* 2019;12:677–683.
3. Sun XS, Michel C, Babin E, et al. Approach to oligometastatic disease in head and neck cancer, on behalf of the GORTEC. *Future Oncol* 2018;14: 877–889.
4. Rivera F, García-Castaño A, Vega N, Vega-Villegas ME, Gutiérrez-Sanz L. Cetuximab in metastatic or recurrent head and neck cancer: the EXTREME trial. *Expert Rev Anticancer Ther* 2009;9:1421–1428.
5. Hellman S, Weichselbaum RR. Oligometastases. *J Clin Oncol* 1995;13:8–10.
6. Shirasawa M, Fukui T, Kusahara S, et al. Prognostic differences between oligometastatic and polymetastatic extensive disease-small cell lung cancer. *PLoS One* 2019;14:e0214599 Van Cutsem E, Cervantes A, Adam R, et al. ESMO consensus guidelines for the management of patients with metastatic colorectal cancer. *Ann Oncol* 2016;27(8):1386–1422. Schulz D, Wirth M, Piontek G, et al. Improved overall survival in head and neck cancer patients after specific therapy of distant metastases. *Eur Arch Otorhinolaryngol* 2018;275(5):1239–1247.
7. Bonomo P, Greto D, Desideri I, et al. Clinical outcome of stereotactic body radiotherapy for lung-only oligometastatic head and neck squamous cell carcinoma: is the deferral of systemic therapy a potential goal? *Oral Oncol* 2019;93:1–7.
8. Young ER, Diakos E, Khalid-Raja M, Mehanna H. Resection of subsequent pulmonary metastases from treated head and neck squamous cell carcinoma: systematic review and meta-analysis. *Clin Otolaryngol* 2015;40: 208–218.
9. Pasalic D, Betancourt-Cuellar SL, Taku N, et al. Outcomes and toxicities following stereotactic ablative radiotherapy for pulmonary metastases in patients with primary head and neck cancer. *Head Neck* 2020;42:1939–1953. <https://doi.org/10.1002/hed.26117>.
10. Dohopolski MJ, Horne Z, Clump D, Burton SA, Heron DE. Stereotactic body radiation therapy for pulmonary oligometastases arising from non-lung primaries in patients without extrapulmonary disease. *Cureus* 2018;10: e2167.
11. Ning MS, Gomez DR, Heymach JV, Swisher SG. Stereotactic ablative body radiation for oligometastatic and oligoprogressive disease. *Transl Lung Cancer Res* 2019;8:97–106.
12. Bates JE, De Leo AN, Morris CG, Amdur RJ, Dagan R. Oligometastatic squamous cell carcinoma of the head and neck treated with stereotactic body ablative radiotherapy: single-institution outcomes. *Head Neck* 2019; 41:2309–2314.
13. Tang E, Lahmi L, Meillon N, Pietta G, Albert S, Maingon P. Treatment strategy for distant synchronous metastatic head and neck squamous cell carcinoma. *Curr Oncol Rep* 2019;21:102.
14. Burtness B, Harrington KJ, Greil R, et al. Pembrolizumab alone or with chemotherapy versus cetuximab with chemotherapy for recurrent or metastatic squamous cell carcinoma of the head and neck (KEYNOTE-048): a randomised, open-label, phase 3 study. *Lancet* 2019;394:1915–1928. (published correction appears in *Lancet* 2020 Jan 25;395[10220]:272) (published correction appears in *Lancet* 2020 Feb 22;395[10224]:564).
15. Ott P, Felip E, Hirt S, et al. OA05.01 pembrolizumab in patients with extensive-stage small cell lung cancer: updated survival results from KEYNOTE-028. *J Thorac Oncol* 2017;12:S259.