


Combined Surgical and Medical Treatment for Vancouver B1 and C Periprosthetic Femoral Fractures: A Proposal of a Therapeutic Algorithm While Retaining the Original Stable Stem

Geriatric Orthopaedic Surgery
& Rehabilitation
Volume 12: 1–15
© The Author(s) 2021
Article reuse guidelines:
sagepub.com/journals-permissions
DOI: 10.1177/21514593211067072
journals.sagepub.com/home/gos


Nicola Mondanelli, MD, PhD^{1,2} , Elisa Troiano, MD^{1,2}, Andrea Facchini, MD^{1,2}, Martina Cesari, MD^{1,2}, Giovanni Battista Colasanti, MD³, Vanna Bottai, MD⁴, Francesco Muratori, MD⁵, Carla Caffarelli, MD^{1,6}, Stefano Gonnelli, MD^{1,6}, and Stefano Giannotti, MD^{1,2}

Abstract

Introduction: There is lack of consensus regarding best operative fixation strategy for periprosthetic femoral fractures (PFFs) around a stable stem. Evidence exists that some patterns of fracture around a stable stem are better treated with revision surgery than with standard fixation. Anyway, a more aggressive surgical procedure together with medical treatment could allow for stem retention, and reduced risk of nonunion/hardware failure, even in these cases. **Significance:** This paper is placed in a broader context of lack of studies on the matter, and its aim is to shed some light on the management of PFFs around a stable stem, when peculiar mechanical and biological aspects are present. **Results:** Based on our casuistry in the treatment of nonunions after PFF successfully treated with original stem retention, and on review of Literature about risk factors for fixation failure, an algorithm is proposed that can guide in choosing the ideal surgical technique even for first-time PFFs with a stable stem, without resorting to revision. Mechanical (major and minor) and biological (local and systemic) factors that may influence fracture healing, leading to nonunion and hardware failure, and subsequent need for re-operation, are considered. The proposed surgical technique consists of rigid fixation with absolute stability (using a plate and structural allograft) plus local biological support (structural allograft and autologous bone marrow concentrate over a platelet-rich plasma-based scaffold) at fracture site. Systemic anabolic treatment (Teriparatide) is also administered in the post-operative period. **Conclusion:** Mechanical factors are not the only issues to be considered when choosing the surgical approach to PFFs over a stable stem. Systemic and local biological conditions should be taken into account, as well. A therapeutic algorithm is proposed, given the prosthetic stem to be stable, considering mechanical and biological criteria.

¹Department of Medicine Surgery and Neurosciences, University of Siena, Siena, Italy

²Section of Orthopedics, Azienda Ospedaliero-Universitaria Senese, Policlinico Santa Maria alle Scotte, Siena, Italy

³Azienda USL della Romagna, Ospedale Santa Maria delle Croci, Ravenna, Italy

⁴Second Clinic of Orthopedic and Traumatology, University of Pisa, Pisa, Italy

⁵Section of Orthopedic Oncology and Reconstructive Surgery, Azienda Ospedaliero-Universitaria Careggi, Firenze, Italy

⁶Section of Internal Medicine, Azienda Ospedaliero-Universitaria Senese, Policlinico Santa Maria alle Scotte, Siena, Italy

Submitted April 30, 2021. Revised October 30, 2021. Accepted November 26, 2021

Corresponding Author:

Nicola Mondanelli, MD, PhD, Section of Orthopedics. Department of Medicine, Surgery and Neurosciences, University of Siena, Siena, Italy and Azienda Ospedaliero-Universitaria Senese, Viale Mario Bracci 16, 53100 Siena, Italy.

Email: nicola.mondanelli@unisi.it



Creative Commons Non Commercial CC BY-NC: This article is distributed under the terms of the Creative Commons Attribution-NonCommercial 4.0 License (<https://creativecommons.org/licenses/by-nc/4.0/>) which permits non-commercial use, reproduction and distribution of the work without further permission provided the original work is attributed as specified on the

SAGE and Open Access pages (<https://us.sagepub.com/en-us/nam/open-access-at-sage>).

Keywords

Adult reconstructive surgery, geriatric trauma, osteoporosis, trauma surgery, stable stem, Teriparatide, periprosthetic fracture, fragility fracture

Introduction

Prolonged life expectancy and the ever-expanding indications for total hip arthroplasty (THA) are leading to an increasing number of implants being placed in both young and elderly patients with high functional demands. Consequently, this increase in THAs annually performed is associated to a global raise of complications, including periprosthetic femoral fractures (PFFs) whose incidence ranges between 0.7% and 11% over a primary and between 1.2% and 18% over a revised hip stem.¹⁻⁶

The treatment of PFFs is based on level of fracture, implant stability and quality of bone-stock, and the comorbidity of the patient.^{2,7-10} The Vancouver classification,¹¹ developed by Duncan and Masri in 1995 and recently integrated into the Unified Classification System for Periprosthetic Fractures (UCS-PF),^{12,13} is the most widely used for guiding the surgeon in pre-operative planning.^{8,14-16} Specific patterns of fracture have been described, with different prevalence over uncemented or cemented stem and apparently over stem geometry,¹⁷⁻²² as well as periprosthetic atypical femoral fractures (PAFFs).^{23,24} Type B1 fractures represent 30% and type C fractures represent 10% of all PFFs, and their treatment can be associated to a higher risk of complication than other PFFs types and high risk of failure due to nonunion with implant loosening/breakage and/or re-fracture.^{9,25-31} Clearly, this entails an important economic expense,³²⁻³⁴ and a high rate of morbidity and disability for these patients; moreover, mortality after PFFs and their treatment varies with patient age and concomitant disease between 4.5% and 22%.^{29,35-39} Modified Vancouver classification and correspondent proposed treatment from Literature are shown in [Tables 1](#) and [2](#), respectively.⁴⁰ Anyway, despite periprosthetic fractures around a stable stem are typically treated with open reduction and internal fixation (ORIF), there is still a lack of consensus regarding the most appropriate method of fixation due to the scarcity of comparative studies between them.⁴¹⁻⁴³

To date, most of the studies have produced therapeutic algorithms that focus on implant stability, leaving the choice of treatment to the habit of the surgeon, not defining the best surgical strategy. Both minimally invasive plate osteosynthesis (MIPO) obtaining an elastic fixation or open reduction and internal fixation (ORIF) with plate and cerclage with or without a structural allograft (or a second plate) have been advocated, based on mechanical issues.^{8,25,26,28,44-49} Revision arthroplasty has been proposed as a valid option in

some B1 PFFs, again mainly based on mechanical issues.^{30,45,50-58} Anyway, the biological aspect of the patient has been neglected, considering it as not fundamental for the type of PFF and the surgical approach. Instead, patients with prostheses can present biological systemic and local issues that commonly include multiple medical comorbidities and long-lasting medical therapies such as glucocorticoids (GSs), and difficulties with post-operative rehabilitation.⁵⁹ Also, the PFF can happen over a bone of very poor quality and/or present a pattern such that mechanical issues are not the only local factors to consider to be deficient.

Moreover, studies are present in the Literature suggesting that the antiosteoporotic agent Teriparatide can be useful in fractures' and nonunions' management, as well.⁶⁰⁻⁶⁸ This drug works by stimulating osteoblasts and reducing osteoblast apoptosis, increasing callus formation, improving mechanical strength, and resulting in increased osteoblast life span. To date, the administration of Teriparatide is reserved for severe osteoporosis (T-score -2.5 or less plus at least one fragility fracture), but it is also prescribed to promote fracture healing, especially in atypical femoral fractures (AFFs) occurring in patients treated with bisphosphonates (BPs) for a long period.^{69,70}

The aim of this paper is to propose an algorithm of treatment of PFFs over a stable stem (Vancouver B1 and C types), considering both mechanical and biological (local and systemic) criteria that can guide the surgeon in choosing the ideal approach, based on results in the Literature and starting from our own results in the treatment of nonunions/hardware failure on PFFs. At our Institutions, no Institutional Review Board nor Ethical Committee Approval is necessary for retrospective studies and reviews of Literature. Patients gave their consent to data collection and anonymous use of them for scientific and teaching purposes.

Methods

Between January 2018 and January 2020 at our Institute we identified 3 patients who failed to heal after fixation for a PFF, classified as Vancouver type B1 or C, and whose nonunions/hardware failure were successfully treated with a combined surgical and medical approach with femoral stem retention. All patients were studied for phosphocalcic metabolism before surgery ([Table 3](#)), and patient's history was analyzed for biological impairment that could pass unadvised. In some patients, also, a histological study of the nonunion area was performed ([Figure 1](#)), showing atypical characteristics.⁷¹ All radiographs of

Table 1. Modified Vancouver Classification of PFFs.

| Modified Vancouver classification of post-operative PFF | | | | |
|---|--|----------------|---|---|
| A | Apophyseal | A _G | Around the greater trochanter | |
| | | A _L | Around the lesser trochanter | |
| B | Bed of implant | B1 | Around the stem or just below it, stable stem | |
| | | B2 | Around the stem or just below it, loose stem, good bone-stock | Burst Highly comminuted, more frequent in cemented stem Clamshell ^a Displaced fracture of medial cortex including residual neck, calcar and lesser trochanter, more frequent in uncemented stem Reverse clamshell Displaced fracture of lateral cortex with a “reverse obliquity” pattern Spiral More frequent in cemented stem |
| | | B3 | Around the stem or just below it, loose stem, poor bone-stock | |
| C | Clear of the implant | | Well below the prosthesis | |
| D | Clear of the implant, dividing two implants, a hip and a knee arthroplasty | | | |

^aThis fracture was first described as a pseudo-A_L or new-B2, with a loose stem, by Van Houwelingen and Duncan in 2011; later on, Capello et al described it as clamshell type, being the stem stable (A1) or loose (A2); clamshell (and reverse clamshell, as well) PFFs with a stable stem are included in type B1 PFFs.

Table 2. Treatment Indications for PFFs According to Modified Vancouver Classification.

| Treatment of PFFs according to modified Vancouver types & subtypes | | | | |
|--|----------------------|----------------|--|---------------------------------------|
| A | Apophyseal | A _G | A _{GU} Undisplaced | Conservative |
| | | | A _{GD} Displaced > 2.5 cm | Osteosynthesis |
| | | A _L | | Conservative |
| B | Bed of implant | B1 | B1_U Undisplaced | Conservative or osteosynthesis |
| | | | B1_D Displaced | Osteosynthesis |
| | | | B1_{TC} Transverse, comminuted, at the tip of a cemented stem | Revision or osteosynthesis |
| | | | B1_{CS} Clamshell, stable stem^a | Osteosynthesis or revision |
| | | | B1_{RS} Reverse clamshell, stable stem^a | Osteosynthesis or revision |
| | | B2 | B2 _B Burst | Revision |
| | | | B2 _{CL} Clamshell, loose stem | Revision |
| | | | B2 _{RL} Reverse clamshell, loose stem | Revision |
| | | | B2 _S Spiral | Revision |
| | | B3 | | Revision |
| C | Clear of the implant | | | Osteosynthesis |

^aClamshell and reverse clamshell are usually considered as a B2 subtype; with a stable stem, they are considered B1 PFFs. In **bold** the cases in which the proposed algorithm can apply.

patients were studied, other than current ones: pre-operative and post-operative imaging relative to the first fixation surgery were analyzed for potential bone defects, unadvised stem loosening, and possible surgical technical errors. Relevant information about patients'

medical history and management of their fractures are summarized in [Table 4](#).

A systematic literature review of studies reporting on risk factors for nonunion and hardware failure in PFFs treated by fixation was performed according to Preferred

Table 3. Suggested “short” phosphocalcic metabolic panel, including only blood testing without any precise preparation nor a 24-hour urine collection. ALP: alkaline phosphatase, Ca: calcium, P: phosphorus, PTH: Parathyroid hormone, CTX: C-telopeptide of type I collagen, PINP: aminoterminal pro-peptide of type I procollagen, 25(OH)D: cholecalciferol (vitamin D3).

Suggested “short” panel for phosphocalcic metabolism

| |
|--|
| ALP, U/L (range 55 – 142) |
| Ca, mg/dL (range 8.9 – 10.1) |
| P, mg/dL (range 2.5 – 4.5) |
| PTH, pg/mL (range 15 – 65) |
| CTX, ng/L (range 100 – 700, over 50 years) |
| PINP, µg/L (range 15 – 75, over 50 years) |
| 25(OH)D, ng/mL (range 30 – 100) |
| Creatinine, mg/dL (range 0.6 – 1.1) |

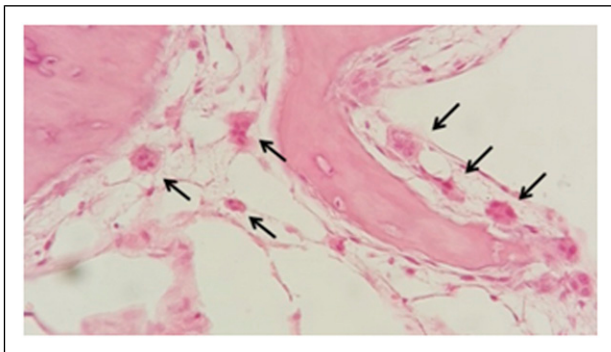


Figure 1. Histological finding of giant osteoblasts (arrows), consistent with an AFF, were found in a type C PFFs.

Reporting Items for Systematic Review and Meta-Analysis (PRISMA) guidelines, as well. Two researchers independently searched the Scholar and MEDLINE databases to identify articles published until April 2021, limited to English language. The terms used were as follows: (failure) AND (periprosthetic femoral fracture). Reference lists of related papers were manually searched to identify potential eligible studies.

Based on findings in our clinical series and on Literature review, a list of biological local and systemic criteria to be taken into consideration as risk factors for nonunion and hardware failure in PFFs treated by fixation was set up, together with already known mechanical criteria. All cases were reviewed and evaluated in the light of these proposed criteria. Biological bone healing capability was impaired in all our cases: each patient was administered long lasting BPs or GCs therapy. As regards the surgical technique, we noticed that in one case the femoral stem entirely occupied the canal and did not allow for screw fixation but cerclages only. In this scenario, the construct could have been characterized by rotational instability that led to fixation failure, and the addition of strut grafts may have improved

stability and therefore outcomes. Based on the reassessment of our case series, an algorithm has been hypothesized, considering mechanical AND biological criteria, to guide the surgeon in the therapeutic choice, given the prosthetic stem to be stable (Vancouver type B1 and C) and willing to retain it.

A correct assessment of the fracture type according to the Vancouver classification is of paramount importance. Plain radiographs alone may not be sufficient to establish a precise diagnosis, so that CT scans with metal suppression or 3D reconstruction may be able to provide additional information regarding fracture characteristics such as the medial extension of the fracture gap or the presence of comminution. However, a precise and accurate review of the patients’ medical history is also just as important.

We therefore thought to create a therapeutic algorithm and started to treat patients presenting with first-time PFF according to it.

Criteria and Proposed Algorithm

Mechanical criteria can be major or minor, biological can be local or systemic (Table 5). Mechanical major criteria are: 1) deficient medial cortex (resorption, wedge fracture or medial comminution), 2) inability to guarantee an adequate fixation around the stem with only a plate; minor criteria are: 3) a transverse fracture at the tip of a stem, 4) fracture comminution, 5) poorness of bone-stock. There are cases in which, for example, a bulky revision stem can occupy an entire osteoporotic canal, not allowing for some screw fixation but only cables (Figure 2), not guaranteeing rotational stability of the construct. Comminution of fracture is not by itself to be considered a major mechanical concern, but it can be a stigma of impaired biology (Figure 3), that may be eventually overlooked.

Biological local criteria are: 1) a fracture around a cemented stem, 2) estimated wide surgical dissection or a previous open access at the affected site, or 3) an atypical pattern of the fracture; systemic criteria are: 4) diseases affecting phosphocalcic metabolism (osteoporosis, rheumatic and/or autoimmune diseases, primary or secondary endocrinological diseases, osteomalacia, Paget’s disease, ..), 5) long lasting pharmacological therapies with GSS or BPs, 6) heavy smoking (\geq one pack/day). Some of these biological criteria can link each other (for example: an atypical pattern of fracture seems more frequent in osteoporotic patients on long lasting BPs therapy) and can coexist. As for cemented stems, in our opinion, it is more a biological issue than a mechanical one: an overlooked failure of the stem-cemented interface has been advocated as a mechanical cause of failure in PFFs around a cemented stem,^{29,72} but a reduced capability of bone healing (less viable area, no endosteal callus formation) and an absent opportunity for re-osseointegration are biological

Table 4. Patients' Medical History and Management of Their Fractures.

| Patients' clinical data and nonunion/hardware failure management | | | | Vancouver classification of fracture type | Management of PFF | Complications | Management of complications |
|--|-----|---------|--|---|--|---|--|
| Case n° | Sex | Age | Clinical history | | | | |
| 1 | F | 77 y.o. | Severe osteoporosis, Rheumatic polyarthritits, THA in 2003, BPs + vitamin D assumption > 4 years, GCs therapy for 1 year | C | ORIF with plate, screws and cables + strut allograft | Plate rupture 3 months after surgery | ORIF with plate, screws and cables and 2 strut allografts + Stop BPs and start Teriparatide |
| 2 | F | 80 y.o. | THA in 2007 for hip dysplasia BPs assumption >7 years | BI | ORIF with plate, screws and cables | Nonunion and plate rupture 9 months after surgery | ORIF with plate screws and cables and 2 strut allograft and BMC + Start Teriparatide |
| 3 | F | 76 y.o. | Severe osteoporosis, Myasthenia gravis, Thymoma, Type-2 diabetes, THA in 2008 GCs therapy ≥ 1 year | C | ORIF with plate and screws | Plate rupture 2 months after surgery | ORIF with plate, screws and cables and 2 strut allograft and BMC + Start Teriparatide 1 month after surgery (thymoma excision) |

Table 5. Criteria Used in the Proposed Therapeutic Algorithm. Mechanical Criteria can be Major or Minor, Biological Criteria can be Local or Systemic.

| Mechanical criteria | | Biological criteria | |
|---|--|---|--|
| Major | Minor | Local | Systemic |
| Deficient medial cortex ^b | Transverse fracture at the tip of a stem | Fracture around a cemented stem | Diseases affecting phosphocalcic metabolism ^c |
| Inability to guarantee an adequate fixation around the stem with only the plate | Fracture comminution | Estimated wide surgical dissection or a previous open access at the affected site | Long lasting pharmacological therapies with BPs or GCs |
| | Poorness of bone-stock | Atypical pattern of the fracture | Heavy smoking |

^bResorption, wedge fracture, or comminution.

^cOsteoporosis, rheumatic and/or autoimmune diseases, primary or secondary endocrinological diseases, osteomalacia, Paget's disease, ..

issues that are undoubtedly present. Alike, a transverse fracture at the tip of the stem has always been considered a mechanical problem but it also implies biological issues (less surface for bone healing).

Based on these criteria, an algorithm is proposed (Figure 4). If no criterion or just one minor mechanical criterion is present, a MIPO or ORIF technique achieving relative or absolute stability without adding any biological support can be indicated. If one major mechanical criterion is present, an ORIF technique with the addition of a medial cortical structural allograft, achieving absolute stability of the construct with some osteoconductive support is preferred. If one biological criterion is present, absolute stability plus osteoconductive support (ORIF with one medial or anterior structural graft) or relative stability plus anabolic support (MIPO and post-operative Teriparatide) are aimed to. If two or more criteria are present (no matter if mechanical ones are major or minor), an aggressive surgical approach is indicated: ORIF with double structural allograft plus osteoinductive/osteogenic support with apposition of autologous bone marrow cells concentrate (BMC) and platelet-rich plasma (PRP) at the site of the fracture.

Post-operative systemic anabolic pharmacological therapy with Teriparatide can be added in all cases. Anyway, being this use of Teriparatide an off-label application, we reserve it to patients with one biological criterion or with two or more criteria (or in cases of delayed union).

Proposed Surgical Technique (2 or More Criteria Present)

Surgery (whose expected duration is around 2 hours) is usually conducted under general anesthesia. Our preferred position is the lateral contralateral decubitus that allows to extend the surgical access as a posterolateral approach to the hip in case proximal extension is required. Standard

antibiotic prophylaxis is administered (usually Cefazolin 2 g 30 minutes before surgery). Antithrombotic prophylaxis is started at trauma with low-molecular weight heparin and continued until complete weight-bearing is possible. Whole blood sample from peripheral vein and percutaneous bone marrow blood samples from the ipsilateral iliac crest are collected and PRP and BMC are prepared in accordance with the recommendations of the manufacturer (Regen Lab SA, Le Mont-sur-Lousanne, CH). The massive fresh-frozen allograft is prepared on a side table by an assistant while surgery is performed. The diaphyseal allograft can be cut in halves or thirds or more tangentially then from the center, depending on dimension of both the host femur and the allograft itself. At the end of surgery, local tranexamic acid is used to reduce bleeding in the manner previously described elsewhere.⁷³

We aim to obtain a rigid construct (absolute stability) with biological (osteoconductive, osteoinductive, and osteogenic) support. Our preferred hardware is a low contact lateral plate with polyaxial angular stability screws and cerclages (NCB system, ZimmerBiomet, Warsaw, IN, USA) or a hook trochanteric plate with screws and cerclages (Cable-Ready Extended GTR Plate, ZimmerBiomet, Warsaw, IN, USA) in case a more proximal PFFs occurs, even if the latter plate does not guarantee for angular stability and requires bone-plate contact.

A double structural allograft (medially and anteriorly placed, at 90° each other) is also used. A diaphyseal fresh-frozen allograft is obtained through our Regional Bone Bank; a fresh-frozen graft is preferred to a freeze-dried one as mechanical properties are more preserved. Also, a femoral diaphysis is preferred, for size and shape, but sometimes a tibial or a humeral one is available. In our setting, they come as an entire diaphysis, so it is possible to obtain more sticks from one graft. We aim to bridge the fracture by at least 2 diaphyseal diameters per side: a minimum length of 10 cm is then required for transverse fracture, while longer struts are suggested for different

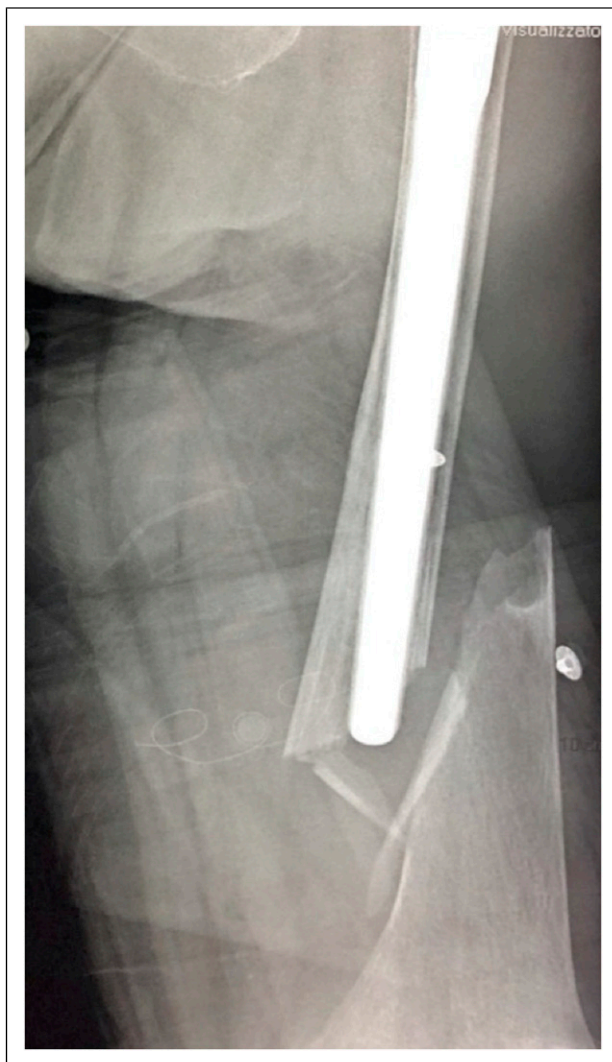

Figure 2. A fluted tapered uncemented long revision stem is occupying the entire canal in an osteoporotic patient. In such a case, there is any place not even for monocortical screws; only one bicortical screw could be used, but it would be too much close to the fracture line, therefore not guaranteeing any rotational stability to the fixation.

fracture patterns. For the anteriorly placed strut graft, a flat stick is prepared to allow for some flexion and better fit to the anteriorly bowed host diaphysis. The ends are chamfered to reduce encumbrance and to look for a smooth transition both for the medial and the anterior strut. The medial strut will take up space against the vessels, while the anterior one will stuff the extensor apparatus. Moreover, a bevel end seems to guarantee a gradual transition of forces.⁷⁴ The fracture is debrided and reduced with forceps and/os cerclages; the struts are positioned together with the lateral plate. Then cables and/or screws are used to secure the struts to the host bone and to the plate. The medial strut is secured with as much screws as indicated (tricortical

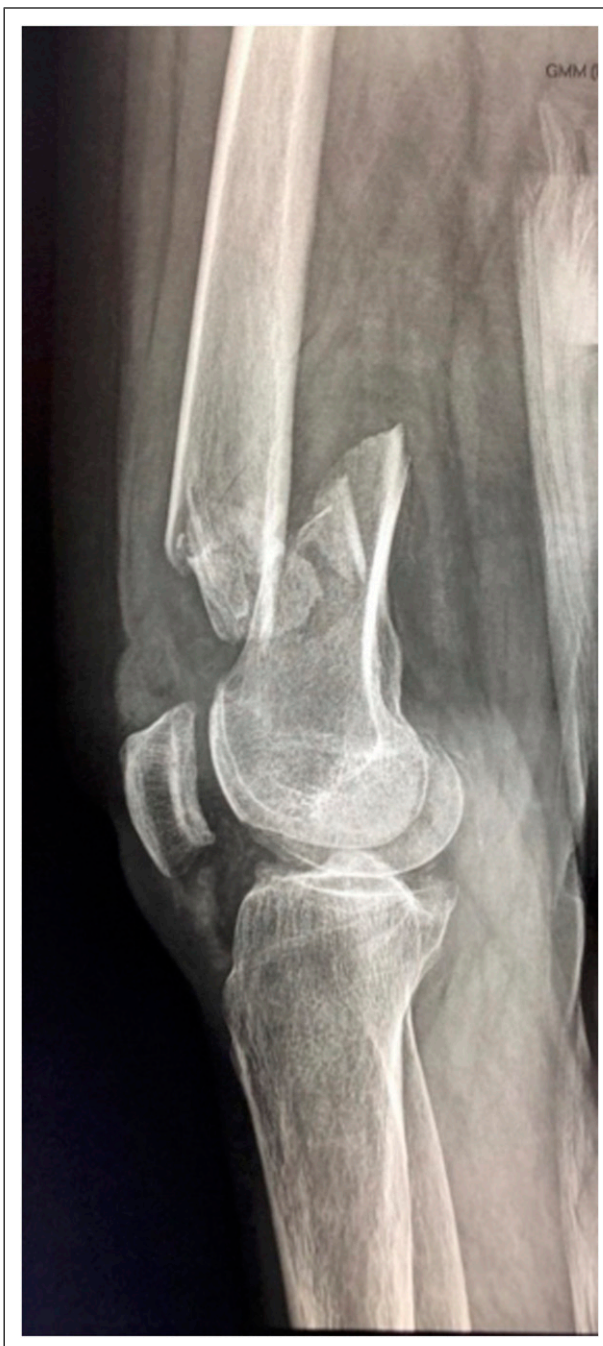

Figure 3. Comminution of fracture (over a well-fixed Zweymueller-type stem, not visible in radiographs) is a minor mechanical criterion, but it can hide impaired biology. The patient was on chronic GSs therapy for myasthenia gravis and presented secondary hypoparathyroidism, too, both due to a thymoma.

screws) and cables through the plate, while the anterior one through cables to the plate and possibly with 2 screws to the host bone. The structural grafts will carry mechanical and osteoconductive support.

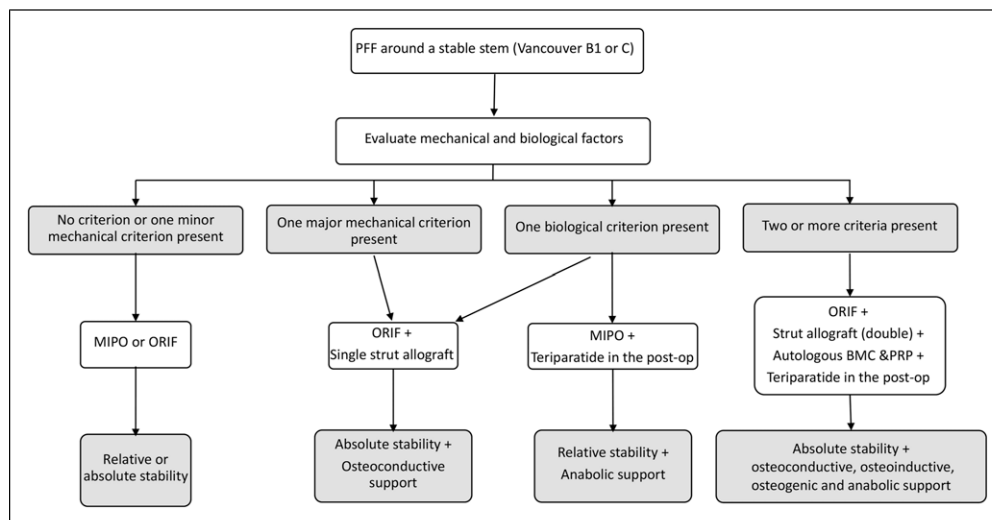


Figure 4. The proposed therapeutic algorithm for PFFs over a stable stem (Vancouver type B1 and C). In case of two or more criteria, no matter if mechanical ones are major or minor.

At the same time, autologous bone marrow aspirate is obtained from the same or contralateral iliac crest, and autologous peripheral blood is drawn in a sterile way. They are both centrifuged in the operating theater to BMC and PRP. The PRP is further prepared with fibrin to obtain a PRP-based membrane (Regenkit BMC and Regenkit Extracell Membrane glue, RegenLab). The BMC is embedded into the PRP-based scaffold, which will be placed at fracture site and between graft and host bone at the end of fixation, before wound closure (Figure 5). This will bring osteoinductive and osteogenic support.

In the post-operative period, patients are also pharmacologically treated with Teriparatide (Forsteo, Eli Lilly and Company, Indianapolis, IN, USA) for at least three months. Teriparatide is prescribed off-label after adequate informed consent is acquired and under guidance of the Bone Metabolic Unit. This will bring an anabolic support for bone healing (Figure 6).

Discussion

Limitations of the proposed algorithm are present. First, the small cohort of patients from whom the idea came out is not the index indication we would like to apply the algorithm to, and it was a small series. The proposed combined aggressive surgical and medical approach was applied to a particular group of patients presenting nonunion/fixation failure of a PFF that were treated successfully with repeated osteosynthesis and stem retention. Anyway, the retrospective evaluation of risk factors showed that all failures were related to the

presence of both mechanical and biological issues. Also, revision arthroplasty for failed osteosyntheses can guarantee good results,^{75,76} and it could be a valid surgical alternative. However, we based our proposal of such a therapeutic algorithm to reduce failures in PFFs' treatment not only on the analyses of our series but also on the review of Literature.^{25,28,34,46,77}

Fractures with a stable stem (Vancouver B1 and C) are commonly treated by ORIF or by MIPO. The variety of methods and implants used, and their combinations implies that no "gold standard" exists. Elastic fixation (relative stability) with minimal soft-tissue damage seems to be preferred,^{43,44,78,79} relying on biological potentiality of the fracture, while a rigid fixation (absolute stability) is advocate in some other cases.^{7,45,80} ORIF can be enhanced with a structural allograft or with a second plate.⁸¹ Anyway, authors have focused their attention over mechanical issues of the PFF,^{51,82,83} without taking into account patient's biological criteria.

As for mechanical criteria, these are already well known. Characteristics of the fracture and type of hardware have been evaluated, with biomechanical studies^{51,81,84-90} confirming clinical remarks.^{51,81,84-90} The use of bicortical screws around the stem is preferable over cerclages alone or cerclages plus monocortical screws, even if a recent clinical study showed no differences in results when only proximal cables were used with a non-locking plate.⁹¹ Also, it can be advisable to span the whole femur with the plate.⁹² However, there are fracture's patterns, such as the comminution/resorption of

the medial cortex, the presence of a transverse or short oblique fracture at the tip of the stem, the comminution or poorness of bone-stock at fracture site, in which an adequate torsional/sagittal and bending stiffness cannot be guaranteed by a lateral plate alone. In these cases, a second mechanical support appears useful. A structural allograft is recommended medially while anteriorly both a structural allograft or a second plate can be used,^{28,77,83,93,94} sounding better a medial than an anterior reinforcement.⁸⁶ A structural allograft is in our opinion better than a second plate as it can bring osteoconductive support as well, especially if a pharmacological anabolic treatment is performed.

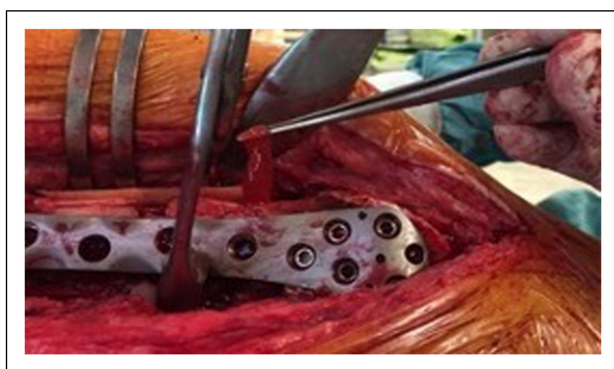

Figure 5. The PRP-based scaffold embedded with BMC is placed at fracture site and between graft and host bone before wound closure.

Mechanical elements are not the only factors that should indicate the use of a structural allograft, and biological issues must be considered, as well. A PFF around or at the tip of a cemented stem,^{21,72,95} or over an osteoporotic bone are known to have higher complication rate than other cases.⁹⁶ Conditions such as osteoporosis and rheumatoid arthritis or other autoimmune or endocrinological diseases, long lasting GCs or BPs assumption, AFFs or previous surgeries are indicators of a local and systemic biological impairment that suggest the use of structural allograft even if mechanically it would be unnecessary.^{7,10,31,97} Also, smoking is known to be a negative prognostic factor for bone healing, and it has been found in a systematic review as the only biological patient-dependent risk factor for nonunion.⁹⁸

As for fracture's healing, it is well known that an adequate environment includes mechanical stability and biological osteoconductive, osteoinductive, and osteogenic support.⁹⁹⁻¹⁰¹ Also, metabolic pharmacological therapy with Teriparatide showed promising results when mechanical issues are present.^{24,64-66}

Our initial experience on re-fractures,^{65,67,71,102} the one with AFFs when intramedullary nailing is not possible (over a deformed bone or in "periprosthetic" AFFs)⁶⁴ and with proximal femur fractures in the elderly (in whom an osteometabolic study should always be done, and eventually proposed an antiosteoporotic pharmacological treatment together to the Bone metabolism Unit) and the review of Literature,^{60,103-105} lead us to proposed such a surgical aggressive and combined pharmacological

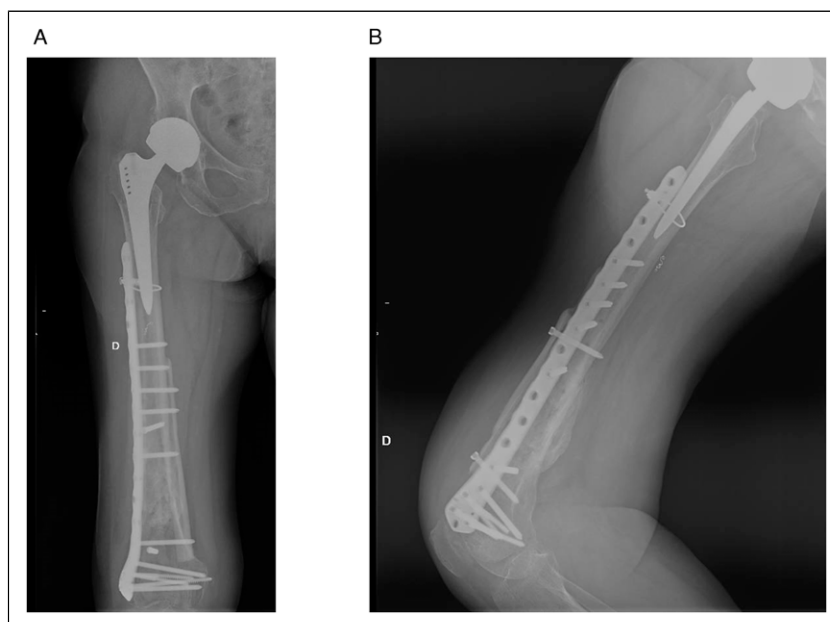


Figure 6. The final construct of case in Figure 3 (A, antero-posterior and B, lateral radiographs). Bone healing occurred at 4 months after surgery.

treatment even to some first-time PFFs. We therefore started to apply the proposed algorithm to first-time PFFs. To now, we have treated 7 PFFs with the described approach (rigid fixation + biological local support and systemic anabolic therapy), all of them presenting clinical and radiological signs of bone healing at 3 months.

In PFFs with a stable stem that may fail to heal because of mechanical or biological issues, we propose a combined mechanical-biological approach that consists in a rigid fixation (absolute stability) with a lateral plate and structural allograft (better if possible, a double structural allograft, at 90° each other, medially and anteriorly) with apposition of autologous BMC and PRP at the fracture site plus medical therapy with Teriparatide in the post-operative period. In our experience it appeared evident that patients who already failed in previous fixation are likely to achieve a complete healing without further complications.

Only cortical structural allograft is a known option for the treatment of PFFs around a stable femoral stem as adjunctive fixation when a plate is used.¹⁰⁶ A structural allograft has both mechanical and biological properties: it confers stability to fracture site, allows a longer working length of the screws if put medially, it has osteoconductive properties, and it can incorporate and ultimately increase the femoral bone-stock.¹⁰⁷ On the other hand, extensive soft-tissue dissection and longer operating time for allograft application result in decreased periosteal blood supply to the fracture site and this can be a reason for a longer time-to-heal (even to nonunion) and a higher infection rate.^{45,79,108} If we have only one structural allograft, we use to put it medially; anyway, it also depends on femoral bowing, level of fracture and length of the stem with revision stems more likely to need an anteriorly placed allograft as straight stem can head to the anterior cortex and stresses are to be counter on the sagittal plane as well. Anyway, in our hospital setting, fresh-frozen structural allograft are entire diaphyses and not emidiaphyseal, so we usually can prepare and use a double structural allograft.

To reduce such a risk of delayed union or nonunion related to extensive dissection, we look for osteoinductive ed osteogenic properties, as well.^{62,99-101} BMC is derived from autologous bone marrow, and it is composed of a variety of cells, including mesenchymal stem cells that can contribute to the regeneration of mesenchymal tissues, capable of self-renewal and differentiation into various cell types such as bone, muscle, tendon, and ligament. These properties have a positive influence on bone formation, neoangiogenesis, and fracture healing.^{64,102} Also, a PRP-based membrane as a scaffold for BMC has already shown enhanced osteogenic and angiogenic properties.¹⁰⁹

Lastly, systemic anabolic support can be of help especially in biologically impaired patients. PTH is a single-

chain 84-aminoacid secreted polypeptide that plays a critical role among the calcium regulating hormones. Although hyperparathyroidism is associated with bone loss, intermittent administration of PTH or its N-terminal 1-34 fragment (Teriparatide) is known to increase bone mass, as anabolic properties of PTH dominate over its catabolic effects. Also, PTH acts upregulating the marker genes associated with osteoblast differentiation. Physiological PTH actions include stimulation of osteogenesis by direct effects on cells responsible of bone formation (osteoblasts) and indirectly by increasing intestinal absorption of calcium and increasing the renal tubular reabsorption of calcium and elimination of phosphate. Evidence is present in the Literature that Teriparatide can be useful in the treatment of nonunions, delayed unions and AFFs.⁶⁰⁻⁶⁶ Also, in an animal model a combined administration of subcutaneous Teriparatide and systemic human mesenchymal stem cells showed a synergic positive effect on bone healing.¹¹⁰

We therefore are proposing such an anabolic medical treatment, together with the Bone Metabolic Unit, in foreseeable difficult cases or when surgical dissection is wide and devascularization is likely.

For those reasons, in our opinion, in selected cases, it is worthwhile a more aggressive and multimodal approach to avoid re-fractures in PFFs. A more invasive surgery (rigid fixation and absolute stability of the fracture) with local biological support and systemic anabolic medical therapy are key to fracture healing. The intent of our proposal is to shift attention toward biological parameters to better frame the patient and avoid failures. More studies and even multicentric evaluation can be useful to validate or to reject this algorithm, and to evaluate eventual increase in other complications such as infections.

Conclusions

Nonunions, re-fractures, and hardware failures can happen after treatment of PFFs. The choice of a correct surgical strategy is essential to reduce complications and ensure complete healing. In our experience, MIPO does not always completely meet biological or mechanical criteria such as to make treatment with locking plate alone sufficient to grant fracture healing. On the other hand, ORIF especially if associated to structural allograft can jeopardize local vascularization due to the extensive exposure needed. The proposed therapeutic algorithm is designed to have a more complete vision of the patient, and to give a more satisfactory surgical approach to these fractures. This combined biological and mechanical approach has been proven successful in re-fractures over PFFs cases and other impaired cases (such as AFFs).

In our opinion, the implementation of such a comprehensive approach even at first-time PFFs can increase

healing rates and reduce failures. Application of this algorithm in type B1 and C PFFs is ongoing at our Institution, to assess its feasibility and safety, as first evaluation point. More cases, case-control matched studies, and multicentric evaluations are needed to confirm, or reject, the hypothesis of the algorithm.

Declaration of Conflicting Interests

The author(s) declared no potential conflicts of interest with respect to the research, authorship, and/or publication of this article.

Funding

The author(s) received no financial support for the research, authorship, and/or publication of this article.

ORCID iD

Nicola Mondanelli  <https://orcid.org/0000-0002-0684-4197>

References

- Lindahl H, Malchau H, Herberts P, Garellick G. Periprosthetic femoral fractures: Classification and demographics of 1049 periprosthetic femoral fractures from the Swedish national hip arthroplasty register. *J Arthroplasty*. 2005;20(7):857-865. doi:10.1016/j.arth.2005.02.001.
- Capone A, Congia S, Civinini R, Marongiu G. Periprosthetic fractures: epidemiology and current treatment. *Clin Cases Miner Bone Metab*. 2017;14(2):189-196. doi:10.11138/ccmbm/2017.14.1.189.
- Abdel MP, Houdek MT, Watts CD, Lewallen DG, Berry DJ. Epidemiology of periprosthetic femoral fractures in 5417 revision total hip arthroplasties: a 40-year experience. *Bone Joint Lett J*. 2016;98-B(4):468-474. doi:10.1302/0301-620X.98B4.37203.
- Chatziagorou G, Lindahl H, Garellick G, et al. Incidence and demographics of 1751 surgically treated periprosthetic femoral fractures around a primary hip prosthesis. *HIP Int*. 2019;29(3):282-288. doi:10.1177/1120700018779558.
- Singh JA, Jensen MR, Lewallen DG. Patient factors predict periprosthetic fractures after revision total hip arthroplasty. *J Arthroplasty*. 2012;27(8):1507-1512. doi:10.1016/j.arth.2011.12.010.
- Meek RMD, Norwood T, Smith R, Brenkel IJ, Howie CR. The risk of peri-prosthetic fracture after primary and revision total hip and knee replacement. *J Bone Jt Surg-Ser B*. 2011;93 B(1):96-101. doi:10.1302/0301-620X.93B1.25087.
- Kim YH, Mansukhani SA, Kim JS, Park JW. Use of locking plate and strut onlay allografts for periprosthetic fracture around well-fixed femoral components. *J Arthroplasty*. 2017;32(1):166-170. doi:10.1016/j.arth.2016.05.064.
- Abdel MP, Cottino U, Mabry TM. Management of periprosthetic femoral fractures following total hip arthroplasty: a review. *Int Orthop*. 2015;39(10):2005-2010. doi:10.1007/s00264-015-2979-0.
- Chatziagorou G, Lindahl H, Kärrholm J. Surgical treatment of Vancouver type B periprosthetic femoral fractures: Patient characteristics and outcomes of 1381 fractures treated in Sweden between 2001 and 2011. *Bone Jt J*. 2019;101-B(11):1447-1458. doi:10.1302/0301-620X.101B11.BJJ-2019-0480.R2.
- Dargan D, Jenkinson MJ, Acton JD. A retrospective review of the dall-miles plate for periprosthetic femoral fractures: Twenty-seven cases and a review of the literature. *Injury*. 2014;45(12):1958-1963. doi:10.1016/j.injury.2014.08.034.
- Duncan CP, Masri BA. Fractures of the femur after hip replacement. *Instr Course Lect*. 1995;44:293-304.
- Haddad FS, Duncan CP. Classification. In: Schütz M, Perka C and Ruedi T, eds. *Periprosthetic Fracture Management*. Stuttgart, New York, Delhi, Rio: Thieme Verlagsgruppe; 2013:47-90.
- Duncan CP, Haddad FS. The unified classification system (UCS): improving our understanding of periprosthetic fractures. *Bone Jt J*. 2014;96-B(6):713-716. doi:10.1302/0301-620X.96B6.
- Masri BA, Meek RMD, Duncan CP. Periprosthetic fractures evaluation and treatment. In: *Clinical Orthopaedics and Related Research*. Philadelphia: Lippincott Williams and Wilkins; 2004:80-95. doi:10.1097/00003086-200403000-00012.
- Giannoudis PV, Kanakaris NK, Tsiridis E. Principles of internal fixation and selection of implants for periprosthetic femoral fractures. *Injury*. 2007;38(6):669-687. doi:10.1016/j.injury.2007.02.050.
- Tsiridis E, Pavlou G, Venkatesh R, Bobak P, Gie G. Periprosthetic femoral fractures around hip arthroplasty: Current concepts in their management. *HIP Int*. 2009;19(2):75-86. doi:10.1177/112070000901900201.
- Van Houwelingen AP, Duncan CP. The pseudo A(LT) periprosthetic fracture: It's really a B2. *Orthopedics*. 2011;34(9):e479-e481. doi:10.3928/01477447-20110714-27.
- Capello WN, D'Antonio JA, Naughton M. Periprosthetic fractures around a cementless hydroxyapatite-coated implant: A new fracture pattern is described. In: *Clinical Orthopaedics and Related Research*, Vol 472. New York, LLC: Springer; 2014:604-610. doi:10.1007/s11999-013-3137-x.
- Watts CD, Abdel MP, Lewallen DG, Berry DJ, Hanssen AD. Increased risk of periprosthetic femur fractures associated with a unique cementless stem design. *Clin Orthop Relat Res*. 2015;473(6):2045-2053. doi:10.1007/s11999-014-4077-9.
- Chatziagorou G, Lindahl H, Kärrholm J. The design of the cemented stem influences the risk of Vancouver type B fractures, but not of type C: an analysis of 82,837 lubinus SPII and exeter polished stems. *Acta Orthop*. 2019;90(2):135-142. doi:10.1080/17453674.2019.1574387.
- Quah C, Porteous M, Stephen A. Principles of managing vancouver type B periprosthetic fractures around cemented polished tapered femoral stems. *Eur J Orthop Surg Traumatol*. 2017;27(4):477-482. doi:10.1007/s00590-016-1883-7.

22. Fenelon C, Murphy EP, Baig MN, Kearns SR, Murphy CG, Curtin W. Breaking bad: a comparative descriptive analysis of periprosthetic fractures around cemented and uncemented femoral stems. *J Arthroplasty* 2019;34(8):1783-1786. doi:10.1016/j.arth.2019.03.051.
23. Mondanelli N, Facchini A, Troiano E, Muratori F, Bottai V, Giannotti S. Periprosthetic Atypical Femoral Fractures Exist: A Retrospective Study at a Single Institution. Prevalence on 115 Periprosthetic Femoral Fractures Around a Primary Hip Stem. *J Arthroplasty* 2021;36(6):2189-2196.
24. Troiano E, Giacché T, Facchini A et al. Surgical and pharmacological management of periprosthetic atypical femoral fractures: a narrative literature review. *Geriatr Orthop Surg Rehabil* submitted.
25. Caruso G, Milani L, Marko T, Lorusso V, Andreotti M, Massari L. Surgical treatment of periprosthetic femoral fractures: a retrospective study with functional and radiological outcomes from 2010 to 2016. *Eur J Orthop Surg Traumatol.* 2018;28(5):931-938. doi:10.1007/s00590-017-2082-x.
26. Froberg L, Troelsen A, Brix M. Periprosthetic vancouver type B1 and C fractures treated by locking-plate osteosynthesis: fracture union and reoperations in 60 consecutive fractures. *Acta Orthop.* 2012;83(6):648-652. doi:10.3109/17453674.2012.747925.
27. Lindahl H, Malchau H, Odén A, Garellick G. Risk factors for failure after treatment of a periprosthetic fracture of the femur. *J Bone Jt Surg-Ser B.* 2006;88(1):26-30. doi:10.1302/0301-620X.88B1.17029.
28. Randelli F, Pace F, Priano D, Giai Via A, Randelli P. Re-fractures after periprosthetic femoral fracture: A difficult to treat growing evidence. *Injury.* 2018;49(suppl 3):S43-S47. doi:10.1016/j.injury.2018.09.045.
29. Spina M, Rocca G, Canella A, Scalvi A. Causes of failure in periprosthetic fractures of the hip at 1- to 14-year follow-up. *Injury.* 2014;45(suppl 6):S85-S92. doi:10.1016/j.injury.2014.10.029.
30. Laurer HL, Wutzler S, Possner S, et al. Outcome after operative treatment of vancouver type B1 and C periprosthetic femoral fractures: Open reduction and internal fixation versus revision arthroplasty. *Arch Orthop Trauma Surg.* 2011;131(7):983-989. doi:10.1007/s00402-011-1272-y.
31. Zuurmond RG, van Wijhe W, van Raay JJAM, Bulstra SK. High incidence of complications and poor clinical outcome in the operative treatment of periprosthetic femoral fractures: An analysis of 71 cases. *Injury.* 2010;41(6):629-633. doi:10.1016/j.injury.2010.01.102.
32. Jones AR, Williams T, Paringe V, White SP. The economic impact of surgically treated peri-prosthetic hip fractures on a university teaching hospital in Wales 7.5-year study. *Injury.* 2016;47(2):428-431. doi:10.1016/j.injury.2015.11.012.
33. Ekegren CL, Edwards ER, de Steiger R, Gabbe BJ. Incidence, costs and predictors of non-union, delayed union and mal-union following long bone fracture. *Int J Environ Res Publ Health.* 2018;15(12):2845. doi:10.3390/ijerph15122845.
34. King SW, Lamb JN, Cage ES, Pandit H. Periprosthetic femoral fractures following total hip and total knee arthroplasty. *Maturitas.* 2018;117:1-5. doi:10.1016/j.maturitas.2018.08.010.
35. Raab GE, Davis CM. Early healing with locked condylar plating of periprosthetic fractures around the knee. *J Arthroplas.* 2005;20(8):984-989. doi:10.1016/j.arth.2005.03.040.
36. Bhattacharya T, Chang D, Meigs JB, Estok DM, Malchau H. Mortality after periprosthetic fracture of the femur. *J Bone Jt Surg.* 2007;89(12):2658-2662. doi:10.2106/JBJS.F.01538.
37. Füchtmeier B, Galler M, Müller F. Mid-term results of 121 periprosthetic femoral fractures: Increased failure and mortality within but not after one postoperative year. *J Arthroplas.* 2015;30(4):669-674. doi:10.1016/j.arth.2014.11.006.
38. Goudie ST, Patil S, Patton JT, Keating JF. Outcomes following osteosynthesis of periprosthetic hip fractures around cemented tapered polished stems. *Injury.* 2017;48(10):2194-2200. doi:10.1016/j.injury.2017.07.017.
39. Young SW, Pandit S, Munro JT, Pitto RP. Periprosthetic femoral fractures after total hip arthroplasty. *ANZ J Surg.* 2007;77(6):424-428. doi:10.1111/j.1445-2197.2007.04087.x.
40. Mondanelli N, Troiano E, Facchini A, Colasanti GB, Giannotti S. Treatment Algorithm of Periprosthetic Femoral Fractures. *Geriatr Orthop Surg Rehabil* submitted.
41. Bates BD, Walmsley DW, Vicente MR, et al. An international, cross-sectional survey of the management of Vancouver type B1 periprosthetic femoral fractures around total hip arthroplasties. *Injury.* 2018;49(2):364-369. doi:10.1016/j.injury.2017.10.034.
42. Dehghan N, McKee MD, Nauth A, Ristevski B, Schemitsch EH. Surgical fixation of vancouver type B1 periprosthetic femur fractures: A systematic review. *J Orthop Trauma.* 2014;28(12):721-727. doi:10.1097/BOT.000000000000126.
43. Stoffel K, Sommer C, Kalampoki V, Blumenthal A, Joeris A. The influence of the operation technique and implant used in the treatment of periprosthetic hip and interprosthetic femur fractures: a systematic literature review of 1571 cases. *Arch Orthop Trauma Surg.* 2016;136(4):553-561. doi:10.1007/s00402-016-2407-y.
44. Ruchholtz S, El-Zayat B, Kreslo D, et al. Less invasive polyaxial locking plate fixation in periprosthetic and peri-implant fractures of the femur-A prospective study of 41 patients. *Injury.* 2013;44(2):239-248. doi:10.1016/j.injury.2012.10.035.
45. Corten K, Vanrykel F, Bellemans J, Frederix PR, Simon J-P, Broos PLO. An algorithm for the surgical treatment of periprosthetic fractures of the femur around a well-fixed femoral component. *J Bone Joint Surg Br.* 2009;91-B(11):1424-1430. doi:10.1302/0301-620X.91B11.22292.
46. Pavone V, de Cristo C, Di Stefano A, Costarella L, Testa G, Sessa G. Periprosthetic femoral fractures after total hip arthroplasty: An

- algorithm of treatment. *Injury*. 2019;50(suppl 2):S45-S51. doi:10.1016/j.injury.2019.01.044.
47. Graham SM, Moazen M, Leonidou A, Tsiroidis E. Locking plate fixation for vancouver B1 periprosthetic femoral fractures: A critical analysis of 135 cases. *J Orthop Sci*. 2013;18(3):426-436. doi:10.1007/s00776-013-0359-4.
 48. Zdero R, Walker R, Waddell JP, Schemitsch EH. Biomechanical evaluation of periprosthetic femoral fracture fixation. *J Bone Jt Surg-Ser A*. 2008;90(5):1068-1077. doi:10.2106/JBJS.F.01561.
 49. Zhang Y, Fan X, Liu Y, et al. Limited open reduction and double plates internal fixation for treatment of Vancouver type B1 periprosthetic femoral fracture after hip arthroplasty. *Zhongguo Xiu Fu Chong Jian Wai Ke Za Zhi*. 2013;27(12):1428-1431.
 50. Park MS, Lim YJ, Chung WC, Ham DH, Lee SH. Management of periprosthetic femur fractures treated with distal fixation using a modular femoral stem using an anterolateral approach. *J Arthroplasty*. 2009;24(8):1270-1276. doi:10.1016/j.arth.2009.07.013.
 51. Moazen M, Mak JH, Etchells LW, et al. Periprosthetic femoral fracture-a biomechanical comparison between vancouver type B1 and B2 fixation methods. *J Arthroplasty*. 2014;29(3):495-500. doi:10.1016/j.arth.2013.08.010.
 52. Schmotzer H, Tehejyan GH, Dall DM. Surgical management of intra- and postoperative fractures of the femur about the tip of the stem in total hip arthroplasty. *J Arthroplasty*. 1996;11(6):709-717. doi:10.1016/S0883-5403(96)80010-6.
 53. Pavlou G, Panteliadis P, Macdonald D, et al. A review of 202 periprosthetic fractures-stem revision and allograft improves outcome for type B fractures. *HIP Int*. 2011;21(1):21-29. doi:10.5301/HIP.2011.6301.
 54. Moazen M, Mak JH, Etchells LW, et al. The effect of fracture stability on the performance of locking plate fixation in periprosthetic femoral fractures. *J Arthroplasty*. 2013;28(9):1589-1595. doi:10.1016/j.arth.2013.03.022.
 55. Oh J-K, Sahu D, Ahn Y-H, et al. Effect of fracture gap on stability of compression plate fixation: A finite element study. *J Orthop Res*. 2010;28(4):462-467. doi:10.1002/jor.20990.
 56. Briant-Evans TW, Veeramootoo D, Tsiroidis E, Hubble MJ. Cement-in-cement stem revision for vancouver type B periprosthetic femoral fractures after total hip arthroplasty: A 3-year follow-up of 23 cases. *Acta Orthop*. 2009;80(5):548-552. doi:10.3109/17453670903316827.
 57. Richards CJ, Duncan CP, Crawford RW. Cement-in-cement femoral revision for the treatment of highly selected vancouver B2 periprosthetic fractures. *J Arthroplasty*. 2011;26(2):335-337. doi:10.1016/j.arth.2010.03.014.
 58. Klasan A, Millar J, Quayle J, Farrington B, Misur PN. Comparable outcomes of in-cement revision and uncemented modular stem revision for vancouver B2 periprosthetic femoral fracture at 5 years. *Arch Orthop Trauma Surg*. Online ahead of print. doi:10.1007/s00402-021-03776-5.
 59. Gehrig LMB, Lane JM, O'Connor MI. Osteoporosis: management and treatment strategies for orthopaedic surgeons. *Instr Course Lect*. 2009;58:817-832. doi:10.1016/S0021-9355(08)72847-9.
 60. Canintika AF, Dilogo IH. Teriparatide for treating delayed union and nonunion: A systematic review. *J Clin Orthop Trauma*. 2020;11(suppl 1):S107-S112. doi:10.1016/j.jcot.2019.10.009.
 61. Mancilla EE, Brodsky JL, Mehta S, Pignolo RJ, Levine MA. Teriparatide as a systemic treatment for lower extremity nonunion fractures: A case series. *Endocr Pract*. 2015;21(2):136-142. doi:10.4158/EP14315.OR.
 62. Marongiu G, Dolci A, Verona M, Capone A. The biology and treatment of acute long-bones diaphyseal fractures: Overview of the current options for bone healing enhancement. *Bonekey Rep*. 2020;12:100249. doi:10.1016/j.bonr.2020.100249.
 63. Bottai V, Giannotti S, Dell'Osso G, et al. Atypical femoral fractures: Retrospective radiological study of 319 femoral fractures and presentation of clinical cases. *Osteoporos Int* 2014;25(3):993-997.
 64. Cesari M, Mondanelli N, Gonnelli S, Caffarelli C, Bottai V, Giannotti S. Atypical femoral fracture on a deformed bone, treated with a multimodal approach. A case report. *Clin Cases Miner Bone Metab* 2019;16(1):62-65.
 65. Giannotti S, Bottai V, Dell'Osso G, De Paola G, Pini E, Guido G. Atrophic femoral nonunion successfully treated with teriparatide. *Eur J Orthop Surg Traumatol* 2013;23(Suppl 2):S291-4.
 66. Bottai V, Gariffo G, Ipponi E, et al. Use of teriparatide in preventing delayed bone healing in complex biosoosseous leg fracture: a case report. *Int J Bone Frag* 2021;1(1):14-16.
 67. Giannotti S, Bottai V, Dell'Osso G, De Paola G, Ghilardi M, Guido G. Pseudoarthrosis in atypical femoral fracture: Case report. *Osteoporos Int* 2013;24(11):2893-2895.
 68. Giannotti S, Bottai V, Dell'osso G, et al. Current medical treatment strategies concerning fracture healing. *Clin Cases Miner Bone Metab* 2013;10(2):116-120.
 69. Im G-I, Lee S-H. Effect of teriparatide on healing of atypical femoral fractures: a systemic review. *J Bone Metab*. 2015;22(4):183. doi:10.11005/JBM.2015.22.4.183.
 70. ML C, Gupta V. Teriparatide-Indications beyond osteoporosis. *Indian J Endocrinol Metab*. 2012;16(3):343. doi:10.4103/2230-8210.95661.
 71. Bottai V, De Paola G, Celli F, et al. Histological study of atraumatic periprosthetic fractures: does atypical periprosthetic fracture exist? *Clin Cases Miner Bone Metab*. 2017;14(2):136-139. doi:10.11138/ccmbm/2017.14.1.136.
 72. Chakrabarti D, Thokur N, Ajnin S. Cable plate fixation for vancouver type-B1 periprosthetic femoral fractures-Our experience and identification of a subset at risk of non-union. *Injury*. 2019;50(12):2301-2305. doi:10.1016/j.injury.2019.10.012.

73. Rocchetti L, Evangelista E, De Falco L, et al. Intra-operative local plus systemic tranexamic acid significantly decreases post-operative bleeding and the need for allogeneic blood transfusion in total knee arthroplasty. *Med Glas*. 2021;18(1):1-6. doi:10.17392/1327-21.
74. Tower SS, Beals RK. Fractures of the femur after hip replacement: the oregon experience. *Orthop Clin North Am*. 1999;30(2):235-247. doi:10.1016/S0030-5898(05)70078-X.
75. Fink B, Oremek D. Hip revision arthroplasty for failed osteosynthesis in periprosthetic vancouver type B1 fractures using a cementless, modular, tapered revision stem. *Bone Joint Lett J*. 2017;99-B(4 suppl B):11-16. doi:10.1302/0301-620X.99B4.BJJ-2016-1201.R1.
76. Fleischman AN, Chen AF. Periprosthetic fractures around the femoral stem: Overcoming challenges and avoiding pitfalls. *Ann Transl Med*. 2015;3(16):234. doi:10.3978/j.issn.2305-5839.2015.09.32.
77. Prins J, Donders JCE, Helfet DL, et al. Periprosthetic femoral nonunions treated with internal fixation and bone grafting. *Injury*. 2018;49(12):2295-2301. doi:10.1016/j.injury.2018.10.019.
78. Ricci WM, Bolhofner BR, Loftus T, Cox C, Mitchell S, Borrelli J. Indirect reduction and plate fixation, without grafting, for periprosthetic femoral shaft fractures about a stable intramedullary implant. *J Bone Jt Surg-Ser A*. 2005;87(10):2240-2245. doi:10.2106/JBJS.D.01911.
79. Shin YS, Han SB. Periprosthetic fracture around a stable femoral stem treated with locking plate osteosynthesis: distal femoral locking plate alone versus with cerclage cable. *Eur J Orthop Surg Traumatol*. 2017;27(5):623-630. doi:10.1007/s00590-017-1900-5.
80. Bryant GK, Morshed S, Agel J, et al. Isolated locked compression plating for vancouver type B1 periprosthetic femoral fractures. *Injury*. 2009;40(11):1180-1186. doi:10.1016/j.injury.2009.02.017.
81. Wilson D, Frei H, Masri BA, Oxland TR, Duncan CP. A biomechanical study comparing cortical onlay allograft struts and plates in the treatment of periprosthetic femoral fractures. *Clin Biomech*. 2005;20(1):70-76. doi:10.1016/j.clinbiomech.2004.08.008.
82. Yassen AT, Haddad FS. The management of type B1 periprosthetic femoral fractures: when to fix and when to revise. *Int Orthop*. 2015;39(9):1873-1879. doi:10.1007/s00264-014-2617-2.
83. Tomás Hernández J, Holck K. Periprosthetic femoral fractures: When i use strut grafts and why? *Injury*. 2015;46(suppl 1):S43-S46. doi:10.1016/j.injury.2015.08.012.
84. Hoffmann MF, Burgers TA, Mason JJ, Williams BO, Sietsema DL, Jones CB. Biomechanical evaluation of fracture fixation constructs using a variable-angle locked periprosthetic femur plate system. *Injury*. 2014;45(7):1035-1041. doi:10.1016/j.injury.2014.02.038.
85. Lenz M, Stoffel K, Kielstein H, Mayo K, Hofmann GO, Gueorguiev B. Plate fixation in periprosthetic femur fractures vancouver type B1—trochanteric hook plate or subtrochanteric bicortical locking? *Injury*. 2016;47(12):2800-2804. doi:10.1016/j.injury.2016.09.037.
86. Sariyilmaz K, Dikici F, Dikmen G, et al. The effect of strut allograft and its position on vancouver type B1 periprosthetic femoral fractures: A biomechanical study. *J Arthroplas*. 2014;29(7):1485-1490. doi:10.1016/j.arth.2014.02.017.
87. Gordon K, Winkler M, Hofstädter T, Dorn U, Augat P. Managing vancouver B1 fractures by cerclage system compared to locking plate fixation—A biomechanical study. *Injury*. 2016;47(suppl 2):S51-S57. doi:10.1016/S0020-1383(16)47009-9.
88. Dennis MG, Simon JA, Kummer FJ, Koval KJ, DiCesare PE. Fixation of periprosthetic femoral shaft fractures occurring at the tip of the stem. a biomechanical study of 5 techniques. *J Arthroplas*. 2000;15(4):523-528.
89. Graham SM, Mak JH, Moazen M, et al. Periprosthetic femoral fracture fixation: a biomechanical comparison between proximal locking screws and cables. *J Orthop Sci*. 2015;20(5):875-880. doi:10.1007/s00776-015-0735-3.
90. Lewis GS, Caroom CT, Wee H, Al E. Tangential bicortical locked fixation improves stability in vancouver b1 periprosthetic femur fractures: A biomechanical study. *J Orthop Trauma*. 2015;29(10):e364-e370. doi:10.1097/BOT.0000000000000365.
91. Yang TC, Tzeng YH, Wang CS, Lin CC, Chang MC, Chiang CC. Are proximal screws necessary for osteosynthesis of stable-stem periprosthetic femoral fractures fixed with non-locking plate and cable? *Injury*. 2019;50(10):1739-1744. doi:10.1016/j.injury.2019.06.009.
92. Moloney GB, Westrick ER, Siska PA, Tarkin IS. Treatment of periprosthetic femur fractures around a well-fixed hip arthroplasty implant: Span the whole bone. *Arch Orthop Trauma Surg*. 2014;134(1):9-14. doi:10.1007/s00402-013-1883-6.
93. Buttaro MA, Farfalli G, Paredes Núñez M, Comba F, Piccaluga F. Locking compression plate fixation of vancouver type-B1 periprosthetic femoral fractures. *J Bone Jt Surg-Am*. 2007;89-(9):1964-1969. doi:10.2106/JBJS.F.01224.
94. Yeo I, Rhyu KH, Kim SM, Park YS, Lim SJ. High union rates of locking compression plating with cortical strut allograft for type B1 periprosthetic femoral fractures. *Int Orthop*. 2016;40(11):2365-2371. doi:10.1007/s00264-015-3107-x.
95. Cassidy JT, Kenny P, Keogh P. Failed osteosynthesis of cemented B1 periprosthetic fractures. *Injury*. 2018;49(10):1927-1930. doi:10.1016/j.injury.2018.07.030.
96. Lenz M, Lehmann W, Wähnert D. Periprosthetic fracture fixation in osteoporotic bone. *Injury*. 2016;47(suppl 2):S44-S50. doi:10.1016/S0020-1383(16)47008-7.
97. Khashan M, Amar E, Drexler M, Chechik O, Cohen Z, Steinberg EL. Superior outcome of strut allograft-augmented plate fixation for the treatment of periprosthetic fractures around a stable femoral stem. *Injury*. 2013;44(11):1556-1560. doi:10.1016/j.injury.2013.04.025.

98. Santolini E, West R, Giannoudis PV. Risk factors for long bone fracture non-union: A stratification approach based on the level of the existing scientific evidence. *Injury*. 2015; 46(suppl 8):S8-S19. doi:10.1016/S0020-1383(15)30049-8.
99. Andrzejowski P, Giannoudis PV. The 'diamond concept' for long bone non-union management. *J Orthop Traumatol*. 2019;20(21):1-13. doi:10.1186/s10195-019-0528-0.
100. Fayaz HC, Giannoudis PV, Vrahas MS, et al. The role of stem cells in fracture healing and nonunion. *Int Orthop*. 2011;35(11):1587-1597. doi:10.1007/s00264-011-1338-z.
101. Giannoudis PV, Einhorn TA, Marsh D. Fracture healing: The diamond concept. *Injury*. 2007;38(suppl 4):S3-S6. doi:10.1016/S0020-1383(08)70003-2.
102. Giannotti S, Parchi PD, Colasanti GB, et al. Use of autologous bone marrow cells concentrate enriched with platelet-fibrin on extensor mechanism allograft reconstruction for extensor mechanism failure following total knee arthroplasty. *J Biol Regul Homeost Agents* 2017;31(4 Suppl 1):107-111.
103. Yu W, Guo X. Teriparatide treatment of femoral fracture non-union that autogenous bone grafting failed to heal: a case report. *Arch Osteoporos*. 2017;12:15. doi:10.1007/s11657-017-0311-x.
104. Xiaofeng L, Daxia X, Yunzhen C. Teriparatide as a non-operative treatment for tibial and femoral fracture nonunion: A case report. *Med*. 2017;96(16):e6571. doi:10.1097/MD.0000000000006571.
105. Lee YK, Ha YC, Koo KH. Teriparatide, a nonsurgical solution for femoral nonunion? A report of three cases. *Osteoporos Int*. 2012;23(12):2897-2900. doi:10.1007/s00198-012-2172-x.
106. Brady OH, Garbuz DS, Masri BA, Duncan CP. The treatment of periprosthetic fractures of the femur using cortical onlay allograft struts. *Orthop Clin N Am*. 1999;30(2): 249-257. doi:10.1016/S0030-5898(05)70079-1.
107. Burchardt H. Biology of bone transplantation. *Orthop Clin N Am*. 1987;18(2):187-196.
108. Moore RE, Baldwin K, Austin MS, Mehta S. A systematic review of open reduction and internal fixation of periprosthetic femur fractures with or without allograft strut, cerclage, and locked plates. *J Arthroplas*. 2014;29(5): 872-876. doi:10.1016/j.arth.2012.12.010.
109. El Backly RM, Zaky SH, Muraglia A, et al. A platelet-rich plasma-based membrane as a periosteal substitute with enhanced osteogenic and angiogenic properties: A new concept for bone repair. *Tissue Eng*. 2013;19(1-2):152-165. doi:10.1089/ten.tea.2012.0357.
110. Cohn Yakubovich D, Sheyn D, Bez M, et al. Systemic administration of mesenchymal stem cells combined with parathyroid hormone therapy synergistically regenerates multiple rib fractures. *Stem Cell Res Ther*. 2017;8(1):1-12. doi:10.1186/s13287-017-0502-9.